

# Inflammation of the Atherosclerotic Cap and Shoulder of the Plaque Is a Common and Locally Observed Feature in Unruptured Plaques of Femoral and Coronary Arteries

Gerard Pasterkamp, Arjan H. Schoneveld, Allard C. van der Wal, Dirk-Jan Hijnen, Willem J.A. van Wolvenen, Simon Plomp, Hans L.J.M. Teepen, Cornelius Borst

**Abstract**—Retrospectively, plaque rupture is often colocalized with inflammation of the cap and shoulder of the atherosclerotic plaque. Local inflammation is therefore considered a potential marker for plaque vulnerability. However, high specificity of inflammation for plaque rupture is a requisite for application of inflammation markers to detect rupture-prone lesions. The objective of the present study was to investigate the prevalence and distribution (local versus general) of inflammatory cells in nonruptured atherosclerotic plaques. The cap and shoulder of the plaque were stained for the presence of macrophages and T lymphocytes in 282 and 262 cross sections obtained from 74 coronary and 50 femoral arteries, respectively. From most cases, 2 atherosclerotic arteries were studied to gain insight into the local and systemic distribution of the inflammatory process. In 45% and 41% of all cross sections, staining for macrophages was observed in the femoral and coronary arteries, respectively. Rupture of the fibrous cap was observed in 2 femoral and 3 coronary artery segments and was always colocalized with inflammatory cells. At least 1 cross section stained positively for CD68 or acid phosphatase in 84% and 71% of all femoral and coronary arteries, respectively. Only 1 femoral and 6 coronary arteries revealed a positive stain for CD68 in all investigated segments. Inflammation of the cap and shoulder of the plaque is a common feature, locally observed, in atherosclerotic femoral and coronary arteries. The high prevalence of local inflammatory responses should be considered if they are used as a diagnostic target to detect vulnerable, rupture-prone lesions. (*Arterioscler Thromb Vasc Biol.* 1999;19:54-58.)

**Key Words:** atherosclerosis ■ plaque vulnerability ■ plaque rupture ■ inflammation ■ macrophages

Rupture of the fibrous cap of the atherosclerotic plaque exposes the necrotic, lipid-rich core to the bloodstream and will subsequently trigger coronary thrombosis.<sup>1-3</sup> Histopathologic data have led to the concept that inflammation plays a key role in the cascade of events that eventually result in plaque erosion and fissuring.<sup>4-6</sup> This concept is supported by the observation that anti-inflammatory agents are able to reduce the risk of a first myocardial infarction.<sup>7</sup> In addition, the serum levels of acute-phase reactants are increased in patients with unstable angina and those at risk for the development of myocardial infarction or stroke.<sup>7-9</sup> It is unknown, however, whether the serum level of acute-phase reactants truly reflects plaque inflammation or whether it reflects a state of hypercoagulability by systemic inflammation.

Next to the search for a systemic serological marker for plaque vulnerability, new intravascular techniques like optical coherence tomography<sup>10</sup> and the thermistor<sup>11</sup> are being studied as potential tools to locally detect the vulnerable, rupture-prone lesion. However, the potential clinical application of plaque

inflammation detectors presumes a high specificity of arterial inflammation for the development of plaque rupture. Generally, plaque ruptures are found to be colocalized with inflammatory cells.<sup>5,6</sup> However, systematic studies on the prevalence of local inflammation in large series of lesions in atherosclerotic arteries are rare. In addition, to our knowledge, no histopathologic study has yet revealed whether plaque inflammation should be considered a local event or whether it is diffusely observed throughout the arterial system.

The aim of the present study was to investigate the prevalence of inflammatory activity in the cap and shoulder region of unruptured, atherosclerotic lesions in coronary and femoral arteries. From most cases, 2 atherosclerotic arteries were studied to gain insight into the distribution of the inflammatory process.

## Methods

Within 24 hours after death, 31 coronary arteries obtained from 11 hearts were pressure-fixed with 4% formalin at 80 mm Hg in situ (6

Received March 17, 1998; revision accepted May 27, 1998.

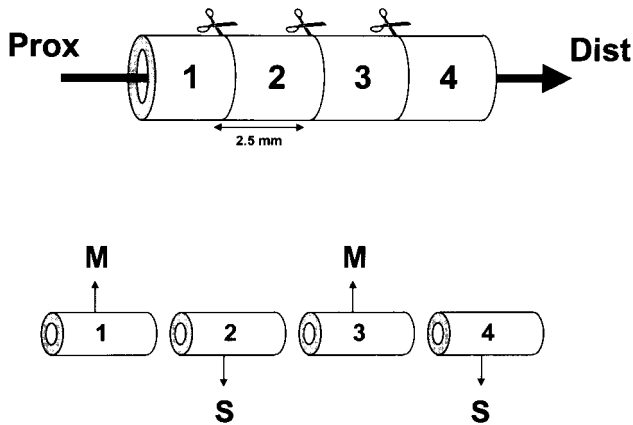
From the Departments of Cardiology (G.P., A.H.S., D.-J.H., C.B.) and Functional Anatomy (G.P., W.J.A.v.W., S.P.), Utrecht University Hospital, Utrecht; the Department of Cardiovascular Pathology (A.C.v.d.W.), Academic Medical Center, Amsterdam; the Department of Pathology (H.L.J.M.T.), Elisabeth Hospital, Tilburg; and the Interuniversity Cardiology Institute of the Netherlands (A.H.S.), Utrecht, the Netherlands.

The content of this manuscript has been reported in part at the 70th Scientific Sessions of the American Heart Association, Orlando, Fla, November 9-12, 1997, and at the American College of Cardiology, Atlanta, Ga, March 29-April 1, 1998.

Correspondence to Gerard Pasterkamp, MD, PhD, Laboratory of Experimental Cardiology, Utrecht University Hospital, Room G02-523, Heidelberglaan 100, 3584 CX Utrecht, Netherlands. E-mail g.pasterkamp@hli.azu.nl

© 1999 American Heart Association, Inc.

*Arterioscler Thromb Vasc Biol.* is available at <http://www.atvbaha.org>



**Figure 1.** Sectioning of arterial specimen. Arterial segments were cut into 2.5-mm segments. Odd-numbered segments were used for morphometry (M); even-numbered segments were stored for additional staining (S) after selection. Morphometric measurements were performed on both the proximal and distal site from each odd-numbered segment. If selected, the adjacent cutting face of the even-numbered segment was used for staining. For example, if the distal part of segment 1 was selected, then the proximal part of segment 2 was used for additional staining.

male, 5 female; mean  $\pm$  SD age,  $78.3 \pm 13.2$  years). Owing to severe calcification, 1 left anterior descending coronary artery and 1 left circumflex artery were lost to dissection. Forty-three coronary arteries obtained from 15 other hearts were freshly frozen in isopentane without prior fixation (8 male, 7 female; age,  $69.8 \pm 9.7$  years). Coronary artery segments of 5 to 10 cm were dissected starting 1 cm distal from the ostium. The arteries were cut into smaller segments of 0.25 cm that were subsequently numbered from proximal to distal. From each segment, the side of the proximal cutting face was marked with East India ink. Odd-numbered segments were stained with Lawson's elastin stain. Even-numbered segments were stored for additional immunohistological stains (Figure 1).

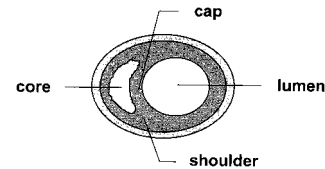
Femoral arteries from 28 donated cadavers (15 men and 13 women; age,  $80.3 \pm 8.7$  years) were pressure-fixed within 24 hours after death with formal aldehyde in situ (pressure = age + 100 mm Hg). The arteries were obtained from people who had willed their bodies to medical science after death. The femoral arteries were dissected and divided into numbered segments of 0.5 cm and processed in the same way as the coronary arteries.

The microscopic images of the cross sections stained with Lawson's elastic tissue stain were recorded on VHS videotape with a Sony video camera (3 CCD) for further image analysis. A ruler was used for distance calibration. Histological sections recorded on videotape were analyzed with a digital video analyzer as described previously.<sup>12</sup> In the pressure-perfused artery segments, the lumen area and the area circumscribed by the internal elastic lamina (IEL area) were traced. The plaque area was calculated by subtracting lumen area from the IEL area. In the freshly frozen coronary artery segments, the circumference of the internal elastic lamina was measured. Subsequently, the lumen area and IEL area were calculated after assuming that the IEL was circular.

### Selection for Staining

Selection of arterial segments for additional immunohistochemical staining was based on arterial geometry. For pressure-fixed coronary arteries ( $n=31$ ), in each artery the 0.25-cm segments that fulfilled 1 or more of the following criteria were selected, and the opposite cutting face of the stored, odd-numbered segment was used for additional staining and analysis: 1 was designated the smallest lumen area; 2, largest lumen area; 3, largest plaque area, 4, smallest IEL area; and 5, largest IEL area.

For freshly frozen coronary arteries ( $n=43$ ), in each artery, cross sections were selected that fulfilled the following criteria: 1 was designated the circumference of the IEL area that was  $>10\%$  longer than the adjacent proximal and distal segments and 2, circumference



**Figure 2.** Schematic presentation of an atherosclerotic cross section.

of the IEL area that was  $>10\%$  shorter than the adjacent proximal and distal segments.

For femoral arteries ( $n=56$ ), in each artery 6 sites were selected for additional staining that fulfilled the following criteria: 1 was designated the smallest lumen area; 2, largest lumen area; 3, smallest plaque area; 4, largest plaque area; 5, smallest IEL area; and 6, largest IEL area. Two totally occluded femoral arteries as well as 4 arteries with negligible plaque were excluded from further analysis. Eight selected femoral cross sections that contained the least amount of plaque with no or hardly any plaque were also excluded from further analysis. Thirty cross sections selected according to the 6 categories appeared to be identical for 2 categories. Thus, a total of 262 cross sections obtained from 50 femoral arteries were selected after quantitative analysis, and these sections were subsequently stained and analyzed.

### Staining

Paraffin-embedded segments were serially sectioned at  $5\text{-}\mu\text{m}$  thickness and mounted on different microscope slides. For all selected cross sections, a mouse anti-human CD68 monoclonal antibody (Dakopatts) and anti-acid phosphatase (AP) antibodies were used to visualize the presence of macrophages. Cross sections obtained from all femoral arteries and 31 of the coronary arteries were additionally stained with anti-CD45RO to visualize T lymphocytes. To render the CD68 epitope accessible to the anti-CD68 monoclonal antibody, the transverse cross sections were boiled in sodium citrate buffer (10 mmol/L, pH 6.0) for 15 minutes. Immunohistochemical detection of the preferred epitopes was performed according to the indirect horseradish peroxidase or alkaline phosphatase technique.

### Analysis

The sections stained with CD68 and AP were analyzed both quantitatively and semiquantitatively. Thrombus formation is most likely to occur due to erosion of the cap and cap rupture near the shoulder of the plaque.<sup>1-6</sup> Therefore, analyses were specifically performed in these regions within the plaque (Figure 2). In cases where plaque had accumulated along the entire circumference of the arterial wall, the location with the largest increase of plaque thickness over the circumference was considered representative for the shoulder.

SIS-ANALYSIS 2.12.1 software was used for computerized quantification. Sections were carefully studied, and color thresholds were set and adjusted until the computerized detection matched the visual interpretation. All stained cross sections were semiquantitatively analyzed by 3 observers (G.P., A.H.S., and D.-J.H.). For all stains, cross sections were semiquantitatively arranged in 3 groups: For CD68/AP-positive cells: -, absent or minor staining with negative or few scattered cells; +, moderate staining, and clusters of cells with  $>10$  cells present; and ++, heavy staining, and clusters of cells with  $>20$  cells strongly dominating over  $\alpha$ -actin-positive cells. For CD45RO-positive cells: -, no cells present; +, few scattered cells present; and ++, scattered cells and clusters with  $>10$  cells.

For the femoral artery, the extent of inflammation was expressed as follows: -, 0 or 1 cross section with signs of moderate or heavy inflammation; +, 2 through 4 cross sections with signs of heavy or moderate inflammation; and ++, 5 or 6 cross sections with signs of moderate or heavy inflammation. For the coronary artery, 3 selected segments were used for comparison of the extent of staining among arteries obtained from the same individual. Coronary arteries were not used for comparison among arterial segments when fewer than 3 segments had been selected in 1 of the coronary arteries. The latter coronary arteries were used, however, to study the prevalence of

**TABLE 1. Geometric Parameters of the Coronary and Femoral Artery Segments That Were Studied**

	Coronary Arteries				Femoral Arteries
	All	LAD	LCX	RCA	
Arteries, n	74	23	24	27	50
Cross sections, n	282	84	94	104	262
Lumen area, mm <sup>2</sup>	4.2±2.8	4.4±2.5	3.8±2.6	4.7±3.0	21.8±12.7
Plaque area, mm <sup>2</sup>	5.0±3.1	4.4±3.7	5.0±3.5	5.8±3.7	33.7±18.2
IEL area, mm <sup>2</sup>	9.2±4.5	8.8±4.2	8.8±4.0	10.5±4.9	11.9±11.1

LAD indicates left anterior descending; LCX, left circumflex; and RCA, right coronary artery.

inflammation in all arterial cross sections. A total of 50 coronary arteries (n=150 segments) obtained from 25 hearts was used to compare the degree of staining among arterial segments. The degree of inflammation per coronary artery was expressed as follows: –, no cross section with heavy or moderate inflammation in the shoulder and/or cap of the plaque; +, 1 or 2 cross sections with signs of inflammation; and ++, all 3 cross sections showed staining for inflammation.

### Statistics

All values are expressed as mean±SD. A *P* value <0.05 was considered statistically significant. Kappa statistics was used to calculate whether the number of inflamed cross sections in an artery was associated with the number of inflamed cross sections in the other (contralateral) artery obtained from the identical individual. For the coronary arteries, the degree of inflammation in the right coronary artery was compared with the degree of inflammation in the left ascending coronary artery. In cases where the left ascending coronary artery was lost during dissection or when fewer than 3 cross sections had been selected, then the left circumflex coronary artery was used for comparison. A Student's *t* test was used to compare the computer-measured degree of CD68 stain/AP stain among groups.

### Results

A total of 1521 and 1175 cross sections obtained from 50 femoral and 74 coronary arteries, respectively, were analyzed. After selection based on vascular geometry, 262 femoral and 282 coronary artery segments were stained for the presence of CD68 and AP. The lumen areas, IEL areas, and plaque areas of these selected cross sections are shown in Table 1.

Table 2 shows the prevalence of heavy and moderate staining for CD68/AP in the cap and shoulder of the atherosclerotic plaques of femoral and coronary artery segments, together with the computer-measured values of cytoplasmic CD68/AP stain. In 45% and 41% of all cross sections, moderate or heavy staining for macrophages was observed in the femoral and coronary arteries, respectively. In 29 coronary and 32 femoral artery segments, CD68- or AP-positive stain was accompanied by moderate or heavy CD45RO staining. Rupture of the fibrous cap was observed in 2 femoral and 3 coronary artery segments. These ruptured sites were always colocalized with CD68/AP-positive cells. The remaining 114 femoral and 112 coronary artery segments in which the cap and/or shoulder of the cap revealed CD68- or AP-positive staining did not show evident ruptures of the luminal border of the atherosclerotic lesion.

Figure 3 illustrates the number of cross sections with positive stain for CD68/AP and CD45RO per artery. Note that at least 1 cross section stained positively for CD68 or AP in 84% and 71% of all femoral and coronary arteries,

respectively. Thus, the absence of staining for CD68/AP in all selected segments was observed in only 16% and 29% of the femoral and coronary arteries, respectively. Inflammation was observed locally rather than generalized; only 6% and 11% of all femoral and coronary arteries revealed a positive stain for CD68 in all investigated segments (Figure 3).

Table 3 shows the association of the degree of inflammation in 2 arteries obtained from the same individual. Kappa statistics revealed that the degree of inflammation in 1 artery was independent of the degree of inflammation in the other investigated artery (for the femoral artery, kappa=0.162, *P*=0.30; for the coronary artery, kappa=0.124, *P*=0.40).

### Discussion

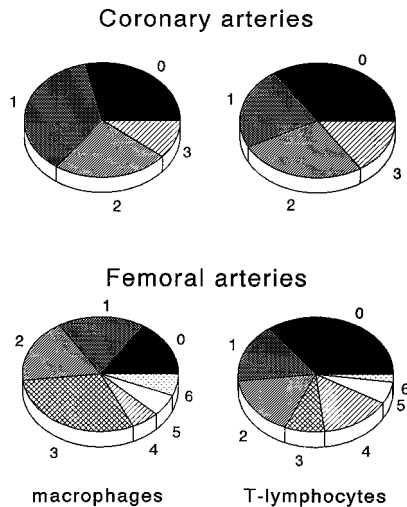
Inflammation of the atherosclerotic lesion is considered to be an obligatory feature in a cascade of events that eventually lead to plaque rupture.<sup>1-3</sup> The observation that the plaque rupture site is generally colocalized with inflammatory cells raised the hypothesis that systemic<sup>7</sup> and local<sup>5,6,11</sup> markers for inflammation may help to identify those patients at risk for the development of myocardial infarction and the lesions at risk for rupture. It is unknown, however, whether local inflammation is a reliable marker with high specificity for plaque vulnerability. In the present study, the prevalence of inflammation in the cap and shoulder of the plaque was investigated in femoral and coronary arteries obtained from

**TABLE 2. Prevalence of Heavy and Moderate Staining for CD68 and/or AP**

	Degree of CD68/AP Staining		
	Heavy	Moderate	Absent
Femoral artery			
n (%)	21 (8)	98 (37)	142 (55)
CP, μm <sup>2</sup>	233 826	2034*	
Coronary artery			
All arteries, n (%)	49 (17)	69 (24)	164 (58)
LAD, n (%)	16 (19)	26 (31)	42 (50)
LCX, n (%)	13 (14)	21 (22)	60 (64)
RCA, n (%)	20 (19)	22 (21)	62 (60)
CP all, μm <sup>2</sup>	84 611	15 994*	

Values are presented for CD68/AP staining in coronary and femoral artery segments together with the computerized-measured area of cytoplasmic CD68/AP stain. CP indicates computerized planimetry of cytoplasmic CD68 and AP stain; LAD, left anterior descending; LCX, left circumflex; and RCA, right coronary artery.

\**P*<0.05 compared with the cross sections with heavy staining.



**Figure 3.** Number of cross sections that revealed moderately or heavily positive staining for CD68/AP (left) and CD45RO (right) per artery. Top panels, coronary arteries, 3 segments per artery: 0 segments positive for CD68/AP stain in 29% of the arteries, 1 segment in 36%, 2 segments in 24%, and all 3 segments in 11% from all arteries. Bottom panels, femoral arteries, 6 segments per artery: 0 segments positive for CD68/AP stain in 16%, 1 segment in 18%, 2 segments in 18%, 3 segments in 30%, 4 segments in 6%, 5 segments in 6%, and 6 segments in 6% from all arteries.

patients who had not died of cardiovascular disease specifically. The number of plaque ruptures was therefore expected to be low.

The present study demonstrates that inflammation of the atherosclerotic cap and shoulder of the plaque is a common and locally observed phenomenon. Generalized inflammation or total lack of inflammatory cells throughout the artery was found to be rare. In addition, the degree of inflammation in 1 artery did not statistically predict the degree of inflammation in the contralateral artery obtained from the same individual.

**TABLE 3. Comparison of the Extent of CD68/AP Stain Among Arterial Segments**

Right femoral artery	Left Femoral Artery		
	—	+	++
—	9	6	1
+	2	4	2
++	0	1	0
Right coronary artery	Left Coronary Artery		
	—	+	++
—	3	4	0
+	2	11	2
++	0	3	0

For femoral arteries, — indicates 0 or 1 segment stained moderately or heavily positive per artery; +, 2 through 4 cross sections stained positive; and ++, 5 or 6 cross sections stained positive. For coronary arteries, — indicates 0 segment stained positive per artery; +, 1 or 2 segments stained positive; and ++, all 3 segments stained positive. The extent of inflammation in 1 artery was found to be independent of the extent of inflammation in the other artery obtained from the same individual.

### Previous Studies of Inflammation in Unruptured Plaques

Boyle<sup>13</sup> studied the extent of inflammation in 351 coronary ruptured and unruptured plaques obtained from 83 patients. He found a prevalence of inflammation of 5% to 10% in the superficial plaque of the control group. However, Boyle described that inflammation was common ( $\approx 40\%$ ) in the deeper layers of the atherosclerotic plaque and was associated with lipid but not with rupture. In the present study, not only the superficial plaque but also the shoulder of the plaque was taken into account, which might explain the observed differences in prevalence between our study and the study performed by Boyle. The lower prevalence in the superficial layer of the plaque as observed by Boyle may also be partially explained by differences in inclusion criteria. Our selection of patients was not based on cardiovascular history, whereas in the control group of Boyle, patients with a history of myocardial infarction were excluded.

Casscells et al<sup>11</sup> studied 50 samples of carotid artery specimens with a thermistor and found that in 37% of all plaques, a temperature rise could be observed. Temperature differences were correlated significantly with cell density in the plaques. Temperature differences could be observed very close to one another ( $<1$  mm), which might support our observation that inflammation is a very local phenomenon.

### Visualization of the Vulnerable Plaque: Is Inflammation the Right Target?

The present study demonstrates that inflammation is more of a local rather than a diffuse phenomenon. It has been shown that systemic markers for inflammation are increased in patients who develop cardiovascular events.<sup>7</sup> It is unknown, however, whether the serologically raised level of reactive proteins is a true reflection of inflammatory processes within the arterial wall. The possibility that a systemic state of inflammation in fact promotes the rupture process may also be considered.<sup>9</sup> If the level of reactive proteins is to be used for risk stratification, then one should consider that plaque inflammation is not an on-or-off phenomenon. It is likely that inflammation occurs in all individuals; only the extent of the inflammatory process may differ. It would therefore be interesting to investigate in a postmortem study the relation between the extent of inflammation within the arterial wall with serologically measured levels of reactive proteins.

Although inflammation was found to be a common feature, this study does not answer the question whether inflamed lesions are indeed at high risk of rupture with subsequent thrombosis. According to Davies et al,<sup>14</sup> “silent” plaque ruptures are frequently observed in coronary arteries. Therefore, a high prevalence of inflammation within the atherosclerotic plaque does not imply that these lesions are not prone to rupture. Prospective studies are needed to find out whether plaques that show inflammation will develop rupture and how many lesions that rupture will lead to significant luminal narrowing by thrombus formation. Until now, no diagnostic modality is commercially available that would allow such a study. One may even wonder whether a positive outcome of such a prospective study will have therapeutic consequences, since  $\approx 30\%$  to  $40\%$  of all lesions will appear to be “at risk” in probably almost 100% of the elderly population. Plaque rupture is a complex and multifactorial



process. Inflammation is an important denominator of plaque vulnerability. However, assessment of additional parameters that are related to plaque vulnerability and, probably more important, subsequent thrombus formation, may help to detect lesions that will cause clinically relevant syndromes.

Alternative markers for the vulnerable lesions at risk may be the percentage of atheroma within the plaque,<sup>15</sup> cap thickness,<sup>1,3,11</sup> and vessel geometry.<sup>16</sup> Next to plaque formation, arterial remodeling is an important determinant of luminal narrowing.<sup>17–19</sup> Recently, we observed that most immunohistological markers for plaque rupture, like inflammation, collagen and smooth muscle cell content, and the percentage of atheroma in the plaque, are more often observed in arterial segments that are compensationally enlarged<sup>20</sup> compared with arterial segments that are shrunk-en.<sup>17–19</sup> Vessel geometry can easily be studied using intravascular ultrasound. Therefore, it might be interesting to perform a serial ultrasound study in which lesion progression is related to the type of de novo atherosclerotic remodeling.

### Limitations of the Present Study

Patients were selected irrespective of their cardiovascular history and without knowledge of their cause of death. Therefore, the prevalence of inflammation within individuals could not be related to cause of death and risk factors for cardiovascular disease. Also, the age of the patients was high. We expected that at this age, the presence of macrophages reflects progression of atherosclerosis rather than initiation. The high prevalence of plaque inflammation in this very elderly population was a surprising finding and seems to indicate active progression of the disease.

Only the superficial layer and shoulder of the plaque were studied. Plaque vulnerability is thought to be related to inflammation in the cap and shoulder of the atherosclerotic plaque. Therefore, the present study did not focus on the deeper layers of the atherosclerotic plaque. However, the prevalence of inflammation in atherosclerotic plaques did exceed 60% when the deeper layers of the plaque were also taken into account (data not shown). The present descriptive study does not provide an answer to the question why inflammatory cell infiltrates are observed locally rather than generally. Future studies are necessary to understand the local enhancement of the inflammatory response.

In conclusion, in both coronary and femoral arteries, inflammation of the vulnerable regions of the atherosclerotic plaque is a common feature of old age. Inflammation was not a general feature, however, because the extent of inflammation in one artery was not significantly related to the extent of inflammation in the contralateral artery. It might be postulated that because of its high prevalence, local inflammatory responses alone may not be a specific marker to detect lesions that will become clinically relevant.

### Acknowledgments

This study was supported by the Dutch Heart Foundation (grant 94-115 to G.P. and C.B.) and the Interuniversity Cardiology Institute

of the Netherlands. G.P. is a fellow of the Catharijne Foundation, Utrecht, Netherlands.

### References

1. Fuster V, Lewis A. Connor memorial lecture: mechanisms leading to myocardial infarction: insights from studies of vascular biology. *Circulation*. 1994;90:2126–2146.
2. Falk E, Shah PK, Fuster V. Coronary plaque disruption. *Circulation*. 1995;92:657–671.
3. Davies MJ, Thomas AC. Plaque fissuring: the cause of acute myocardial infarction, sudden ischaemic death, and crescendo angina. *Br Heart J*. 1985;53:363–373.
4. Richardson PD, Davies MJ, Born GVR. Influence of plaque configuration and stress distribution on fissuring of coronary atherosclerotic plaques. *Lancet*. 1989;2:941–944.
5. van der Wal AC, Becker AE, van der Loos CM, Das PK. Site of intimal rupture or erosion of thrombosed coronary atherosclerotic plaques is characterized by an inflammatory process irrespective of the dominant plaque morphology. *Circulation*. 1994;89:36–44.
6. Moreno PR, Falk E, Palacios IF, Newell JB, Fuster V, Fallon JT. Macrophage infiltration in acute coronary syndromes: implications for plaque rupture. *Circulation*. 1994;90:775–778.
7. Ridker PM, Cushman M, Stampfer MJ, Tracy RP, Hennekens CH. Inflammation, aspirin, and the risk of cardiovascular disease in apparently healthy men. *N Engl J Med*. 1997;336:973–979.
8. Berk BC, Weintraub WS, Alexander RW. Elevation of C-reactive protein in “active” coronary artery disease. *Am J Cardiol*. 1990;65:168–172.
9. Lee RT, Libby P. The unstable atheroma. *Arterioscler Thromb Vasc Biol*. 1997;17:1859–1867.
10. Brezinski ME, Guillermo JT, Bouma BE, Izatt JA, Hee R, Swanson EA, Southern JF, Fujimoto JG. Optical coherence tomography for optical biopsy: properties and demonstration of vascular pathology. *Circulation*. 1996;93:1206–1213.
11. Casscells W, Hathorn B, David M, Krabach T, Vaughn WK, McAllister HA, Bearman G, Willerson JT. Thermal detection of cellular infiltrates in living atherosclerotic plaques: possible implications for plaque rupture and thrombosis. *Lancet*. 1996;347:1447–1449.
12. Wenguan L, Gussenhoven WJ, Zhong Y, The SHK, Di Mario C, Madretsma S, van Egmond F, de Feyter P, Pieterman H, van Urk H, Rijsterborgh H, Bom N. Validation of quantitative analysis of intravascular ultrasound images. *Int J Card Imaging*. 1991;6:247–253.
13. Boyle JJ. Association of coronary plaque rupture and atherosclerotic inflammation. *J Pathol*. 1997;181:93–99.
14. Davies MJ, Bland JM, Hangartner JRW, Angelini A, Thomas AC. Factors influencing the presence or absence of acute coronary artery thrombi in sudden ischemic death. *Eur Heart J*. 1989;10:203–208.
15. Davies MJ, Richardson PD, Woolf N, Katz DR, Mann J. Risk of thrombosis in human atherosclerotic plaques: role of extracellular lipid, macrophage, and smooth muscle cell content. *Br Heart J*. 1993;69:377–381.
16. Pasterkamp G, Schoneveld AH, van der Wal AC, Haudenschild CC, Claris RJG, Becker AE, Hillen B, Borst C. Relation of arterial geometry to luminal narrowing and histologic markers for plaque vulnerability: the remodeling paradox. *J Am Coll Cardiol*. 1998;32:655–662.
17. Pasterkamp G, Wensing PJW, Post MJ, Hillen B, Mali WPTM, Borst C. Paradoxical arterial wall shrinkage contributes to luminal narrowing of human atherosclerotic femoral arteries. *Circulation*. 1995;91:1444–1449.
18. Pasterkamp G, Borst C, Gussenhoven EJ, Mali WPTM, Post MJ, The SHK, Reekers JA, van der Berg FA. Remodeling of de novo atherosclerotic lesions in femoral arteries: impact on the mechanism of balloon angioplasty. *J Am Coll Cardiol*. 1995;26:422–428.
19. Pasterkamp G, Schoneveld AH, van Wolferen W, Hillen B, Clarijs RJG, Haudenschild CC, Borst C. The impact of atherosclerotic arterial remodeling on percentage luminal stenosis varies widely within the arterial system: a postmortem study. *Arterioscler Thromb Vasc Biol*. 1997;17:3057–3063.
20. Glagov S, Weisenberg E, Zarins CK, Stankunavicius R, Kolettis G. Compensatory enlargement of human atherosclerotic coronary arteries. *N Engl J Med*. 1987;316:1371–1375.