

Electroanatomic Mapping and Catheter Ablation of Breakthroughs From the Right Atrium to the Superior Vena Cava in Patients With Atrial Fibrillation

Masahiko Goya, MD; Feifan Ouyang, MD; Sabine Ernst, MD; Marius Volkmer, MD; Matthias Antz, MD; Karl-Heinz Kuck, MD

Background—The superior vena cava (SVC) is one of the sources of ectopies that can initiate atrial fibrillation (AF). We investigated by radiofrequency ablation the electrophysiological characteristics of the junction of the right atrium (RA) and the SVC and the feasibility of electrical disconnection of the SVC from the RA.

Methods and Results—Sixteen patients with paroxysmal AF after pulmonary vein isolation underwent electroanatomic mapping at the RA–SVC junction during sinus rhythm. Mapping showed sharp potentials (SVC potentials) inside the SVC. Activation spread from the earliest SVC potential (breakthrough) to the rest of the SVC. SVC potentials were found over a large amount of the circumference, suggesting widespread muscle coverage of the SVC. Breakthroughs from the RA to SVC were located anteriorly, laterally, posteriorly, and septally in 3, 4, 10, and 6 patients, respectively. The number of breakthroughs was 1.4 ± 0.5 per patient. Radiofrequency energy was applied with the end point of electrical disconnection. All breakthroughs were eliminated with 3.1 ± 1.7 applications per breakthrough without complications.

Conclusions—SVC potentials can be recorded inside the SVC. There are specific breakthroughs from the RA to the SVC that can be identified by electroanatomic mapping. The electrical disconnection of the SVC from the RA is feasible. (*Circulation*. 2002;106:1317-1320.)

Key Words: fibrillation ■ veins ■ catheter ablation ■ mapping

Recently, several studies reported that ectopies originating from the pulmonary veins (PVs) and superior vena cava (SVC) initiated atrial fibrillation (AF), and radiofrequency (RF) ablation at the site of ectopic foci reduced the likelihood of AF recurrence.^{1–6} The ectopic foci in the PVs can also be treated by electrical isolation of the veins from the left atrium (LA) using RF at the LA–PV junction.^{3,4} Therefore, electrophysiological and anatomic characteristics of the junctions of heart chambers and veins become important. The purpose of this study was to investigate the electrophysiological characteristics of the junction of the right atrium (RA) and SVC using electroanatomic mapping (CARTO, Biosense-Webster), as well as to determine the feasibility of the disconnection of the SVC from the RA.

Methods

Patient Characteristics

The study population consisted of 16 patients (14 male, age 58.7 ± 4.6 years) who had daily symptomatic drug-resistant AF without structural heart disease and recurrence of AF after PV isolation, with or without ectopies originating from the SVC. All procedures were performed after antiarrhythmic drug therapy had been discontinued for at least 5 half-lives.

SVC Mapping Procedure

Before electroanatomic mapping of the SVC, all patients underwent PV isolation as previously described,³ and induction of SVC ectopies by use of isoproterenol and atrial burst pacing was attempted.⁵ SVC angiography was performed by hand injection. The junction of the convex RA wall and the straight SVC wall on the angiogram was defined as the radiological RA–SVC junction.

A 7F quadripolar catheter with a location sensor (NAVI-STAR, Biosense-Webster) was used for mapping. Another electrode catheter (REF-STAR, Biosense-Webster) was used as the reference location. A bipolar electrogram from a bipole located inside the coronary sinus was used as the timing reference.

SVC mapping was performed during sinus rhythm. The radiological RA–SVC junction was used as the anatomic reference. From that point, the mapping catheter was advanced until no signals were recorded. Sequential recording was then performed at multiple points by dragging the mapping catheter along the SVC circumference to reconstruct a three-dimensional activation map.

Measurements and Definitions

The local activation time was annotated manually at the onset of the bipolar spiky component inside the SVC (filter setting 10 to 400 Hz). If double potentials were recorded at the radiological RA–SVC junction, the first and second potential represented the activation of the RA and SVC (SVC potential), respectively. This definition was based on the fact that only the second component could be traced by

Received June 12, 2002; revision received July 22, 2002; accepted July 24, 2002.

From Allgemeines Krankenhaus St Georg, 2. Med. Abteilung, Kardiologie, Hamburg, Germany.

Correspondence to Karl-Heinz Kuck, MD, Allgemeines Krankenhaus St Georg, 2. Med. Abteilung, Kardiologie, Lohmühlenstraße 5, 20099, Hamburg, Germany. E-mail mgoyamd@aol.com

© 2002 American Heart Association, Inc.

Circulation is available at <http://www.circulationaha.org>

DOI: 10.1161/01.CIR.0000033115.92612.F4

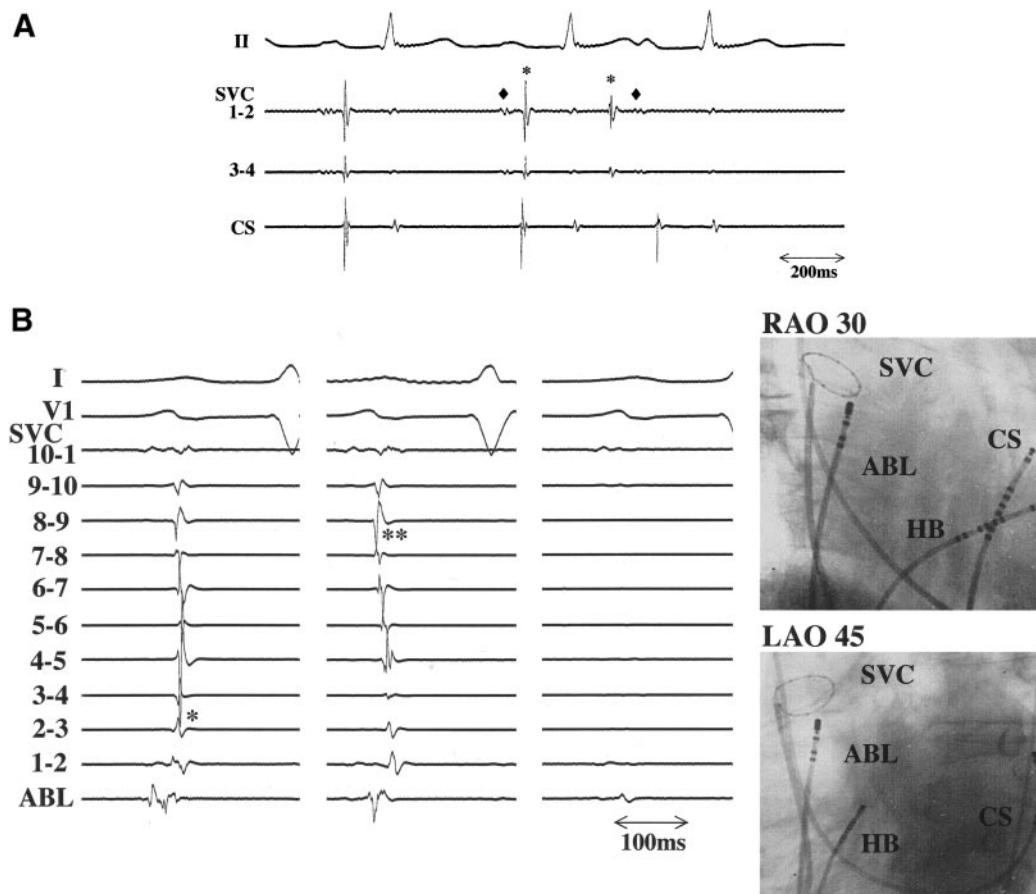


Figure 1. A, Spontaneous atrial ectopies originating from the SVC. During ectopy, there was a reversal of far-field RA activity (\diamond) and SVC spike potential (*). B, RF ablation at the RA-SVC junction performed during sinus rhythm with recordings from a loop catheter inside the SVC. First panel, radiofrequency application close to bipoles 2–3 (*) changed the activation pattern and eliminated the first breakthrough, disclosing a second breakthrough (second panel, bipoles 8–9; **). Further energy delivery at this area abolished the second breakthrough and eliminated all SVC potentials (third panel). Catheter placements in right (RAO) and left (LAO) anterior oblique views are shown (fourth panel). ABL indicates ablation; HB, His bundle; and CS, coronary sinus.

mapping into the SVC. Distally, the end of the muscle was defined by the absence of a recordable clear signal.

We measured and calculated the location of the earliest activation site (breakthrough), the total activation time (the duration from the earliest to the latest activation site), the distribution of SVC potentials, and the number of breakthroughs. If there was a second early SVC potential recording site or an apparent change of intra-SVC activation sequence after the elimination of the first breakthrough, we defined a second breakthrough. To indicate the location, we divided the SVC into four aspects: anterior, lateral, posterior, and septal. The SVC diameter was measured on the electroanatomic map and compared with that determined from SVC angiography.

Catheter Ablation

Before ablation, an additional multipolar catheter was positioned in the SVC for continuous monitoring of SVC potentials. RF applications were delivered at the junction, targeting the earliest SVC activation on the electroanatomic map. A temperature control mode with a maximum temperature setting of 50°C and maximum power setting of 30 watts was used. The end point was the elimination or dissociation of all SVC potentials.

Follow-Up and Statistical Analysis

Surface ECG, echocardiography, Holter monitoring, and clinical follow-up were obtained after the procedures. All data are expressed as mean \pm SD. Statistical comparisons were performed using Stu-

dent's *t* test for paired values. A probability value <0.05 was considered statistically significant.

Results

In 7 of 16 patients, SVC disconnection was performed immediately after primary PV isolation. In 9 patients, AF had recurred after previous PV isolation. The present procedure was the second in 5 and the third in 4 of the 16 patients.

Baseline Electrophysiological Study and PV Isolation

Before electroanatomic mapping, isolation of all PVs was confirmed. During sinus rhythm, the SVC potentials were fused with the local RA signals at some discrete part of the RA-SVC junction. From this site, the activation spread to the rest of the SVC.

Atrial ectopies originating from the SVC were recorded in 6 patients during the procedures. During ectopy from the SVC, there was a reversal of far-field RA activity and SVC spike potential (Figure 1A), resulting in an activation sequence from the distal SVC sleeve to the RA-SVC junction.

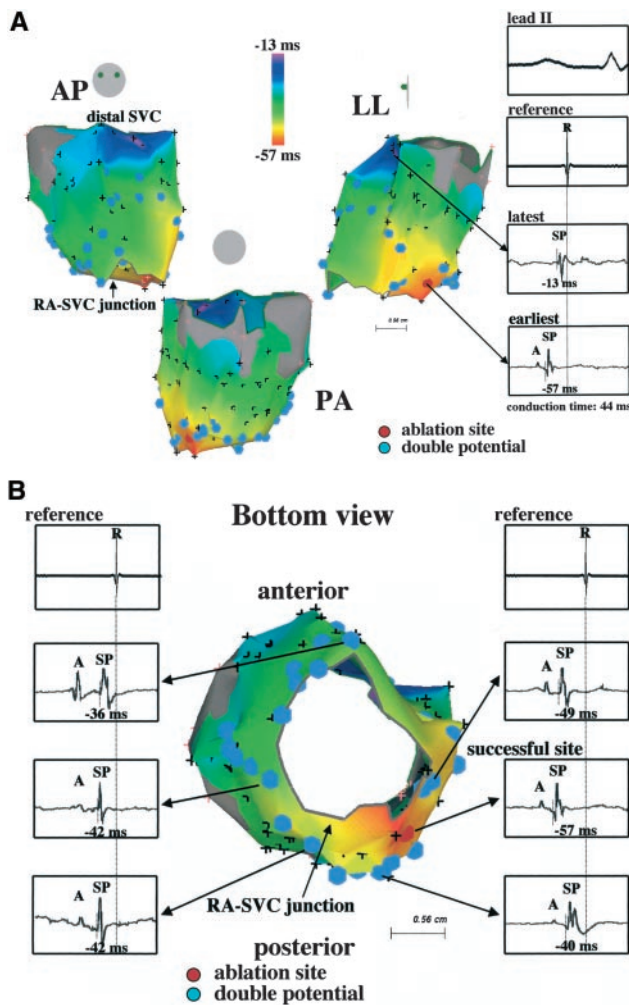


Figure 2. Three-dimensional activation map of the proximal SVC during sinus rhythm in (A) anterior-posterior (AP), posterior-anterior (PA), and left lateral (LL) projection and (B) bottom projection. The color bar indicates local activation time relative to the reference (atrial signal from the coronary sinus), from -57 ms (red) to -13 ms (purple). (A) Double potentials (light blue tag) consisting of far field atrial signals (A) and SVC potentials (SP) are seen at the junction of the RA and the SVC. The breakthrough is located at the septal aspect of the junction. Activation propagates from this breakthrough and spreads radially around the SVC circumference. (B) Radiofrequency energy application at the breakthrough (dark red tag) disconnected the entire SVC from the RA electrically. Gray represents the area where signals could not be recorded.

Electroanatomic Mapping

In 16 patients, 107 ± 32 points were sampled. In all patients, SVC potentials were recorded, and double or multiple-component potentials were recorded around the RA-SVC junction (Figure 2). SVC potentials were recordable over a large amount of the SVC circumference. Conduction time was 41.8 ± 15.6 ms (range: 23 to 75 ms). Breakthroughs were located in the anterior aspect of the RA-SVC junction in 3, lateral in 4, posterior in 10, and septal region in 6 patients. The number of breakthroughs was 1.4 ± 0.5 per patient (range: 1 to 2). The SVC diameters measured by electroanatomic mapping and angiography were 23.7 ± 3.4 mm and 22.5 ± 4.1 mm (not significant), respectively.

Catheter Ablation

Sequential RF applications that targeted the earliest SVC potential were delivered at the RA-SVC junction. RF application at the first site eliminated all SVC potentials in 11 patients. In the remaining 5 patients, a second breakthrough was observed. In these patients, ablation at the second breakthrough resulted in an abrupt disappearance of distal SVC potentials (Figure 1B). The mean number of RF applications was 4.0 ± 1.0 (range: 2 to 7) per patient and 3.1 ± 1.7 (range: 2 to 6) per breakthrough. All breakthroughs were successfully ablated by conventional RF energy.

After electrical disconnection, no ectopies conducted to the RA were observed. Independent SVC rhythms with cycle lengths of 1700 ms and 2140 ms were observed in 2 patients.

Follow-Up

Sinus rhythm was maintained in 13 of 16 patients (81%) during 12.6 ± 0.8 months of follow-up. The number of supraventricular ectopies recorded by Holter monitoring decreased from 1431 ± 1635 before ablation to 97 ± 73 after ablation. No complications occurred during and after the procedures.

Discussion

Several recent studies reported that the PVs are the dominant sources of ectopies that initiate AF.^{1,2,4} Ectopies originating from the SVC can also initiate AF.^{5,6} Haissaguerre et al³ reported that there were specific breakthroughs from the LA to the PVs, and partial perimetric ablation at the PV ostium could disconnect the veins electrically. In the present study, we observed very similar findings related to the RA-SVC junction: (1) sharp potentials (SVC potential) can be recorded inside the SVC and over a large amount of the perimeter, which suggests that muscle covers a large extent of the SVC perimeter; (2) there are specific breakthroughs from the RA to the SVC that can be identified by electroanatomic mapping; (3) the electrical disconnection of the SVC from the RA is feasible by RF energy application at breakthroughs; and (4) independent SVC rhythm was observed in some patients after electrical disconnection.

There are several reports about the extension of atrial muscle into the SVC^{7,8} and its excitability.^{9,10} The question of anatomic inputs from the RA to the SVC, however, has not been addressed. Yeh et al¹¹ described immunohistochemical and ultrastructural findings in the RA and SVC. They mentioned differences between and within the levels of the SVC, including the size and assembly of cardiomyocytes and the distribution of gap junctions. These differences, especially within the level, might create specific breakthroughs from an anatomic standpoint.

Our target of RF energy was the breakthroughs, not the crista terminalis. In some patients (Figure 1B), however, double potentials were recorded at the anterior aspect of the RA-SVC junction, which was close to the successful ablation point. It is possible that these double potential recording sites are identical to the distal crista terminalis, as described by Chen et al.⁶

According to the study by Tsai et al⁵, ectopies from the SVC contributed to the initiation of AF in 6% of their

patients. This number could be even higher after PV isolation. It has been suggested that complete isolation of the PVs is more effective than ablation of single foci inside the PVs. This suggests that complete RA–SVC disconnection may be more effective than focal ablation inside the SVC.

It was possible that far-field potentials from the right side PV could be recorded inside the SVC even after electrical disconnection, which could lead to inappropriate energy delivery. In the present study, we performed the SVC isolation after PV isolation, and therefore the likelihood of this misleading situation was minimized.

Our findings have clinical implications. Electrical disconnection of the SVC from the RA is feasible, and detailed mapping at the RA–SVC junction optimizes RF delivery by directing energy at specific segments and avoiding unnecessary applications.

Limitations

SVC angiography was used to define the junction between the RA and the SVC in the present study. Intracardiac echocardiography, however, might better define this junction. The number of the study patients was small, and therefore further larger studies and a longer follow-up are necessary to clarify the long-term effectiveness and safety of this procedure.

Conclusion

SVC potentials similar to PV potentials are observed over a large extent of the SVC circumference. Specific breakthroughs from the RA to the SVC can be identified by

electroanatomic mapping. The electrical disconnection of the SVC from the RA is feasible.

References

1. Haissaguerre M, Jais P, Shah DC, et al. Spontaneous initiation of atrial fibrillation by ectopic beats originating in the pulmonary veins. *N Engl J med*. 1998;339:659–666.
2. Chen SA, Hsieh MH, Tai CT, et al. Initiation of atrial fibrillation by ectopic beats originating from the pulmonary veins: electrophysiologic characteristics, pharmacologic responses and effects of radiofrequency ablation. *Circulation*. 1999;100:1879–1886.
3. Haissaguerre M, Shah DC, Jais P, et al. Electrophysiological breakthroughs from the left atrium to the pulmonary veins. *Circulation*. 2000;102:2463–2465.
4. Pappone C, Rosanio S, Oreto G, et al. Circumferential radiofrequency ablation of pulmonary vein ostia: a new anatomic approach for curing atrial fibrillation. *Circulation*. 2000;102:2619–2628.
5. Tsai CF, Tai CT, Hsieh MH, et al. Initiation of atrial fibrillation by ectopic beats originating from the superior vena cava: electrophysiological characteristics and results of radiofrequency ablation. *Circulation*. 2000;102:67–74.
6. Chen SA, Tai CT, Yu WC, et al. Right atrial focal atrial fibrillation: electrophysiologic characteristics and radiofrequency catheter ablation. *J Cardiovasc Electrophysiol*. 1999;10:328–335.
7. Ito M, Arita M, Saeki K, et al. Functional properties of the sinocaval conduction. *Jpn J Physiol*. 1967;17:174–189.
8. Hashizume H, Ushiki T, Abe K. A histological study of the cardiac muscle of the human superior and inferior venae cavae. *Arch Histol Cytol*. 1995;58:457–464.
9. Zipes DP, Knope RF. Electrical properties of the thoracic veins. *Am J Cardiol*. 1972;29:372–376.
10. Spach MS, Barr RC, Jewett PH. Spread of excitation from the atrium into thoracic veins in human beings and dogs. *Am J Cardiol*. 1972;30:844–854.
11. Yeh HI, Lai YJ, Lee SH, et al. Heterogeneity of myocardial sleeve morphology and gap junction in canine superior vena cava. *Circulation*. 2001;104:3152–3157.