

Long-Term Treatment With Oral Sildenafil Is Safe and Improves Functional Capacity and Hemodynamics in Patients With Pulmonary Arterial Hypertension

Evangelos D. Michelakis, MD; Wayne Tymchak, MD; Michelle Noga, MD; Linda Webster, RN, NP; Xi-Chen Wu, PhD; Dale Lien, MD; Shao-Hua Wang, MD; Dennis Modry, MD; Stephen L. Archer, MD

Background—The prognosis and functional capacity of patients with pulmonary arterial hypertension (PAH) is poor, and there is a need for safe, effective, inexpensive oral treatments. A single dose of sildenafil, an oral phosphodiesterase type-5 (PD-5) inhibitor, is an effective and selective pulmonary vasodilator in PAH. However, the long-term effects of PD-5 inhibition and its mechanism of action in human pulmonary arteries (PAs) are unknown.

Methods and Results—We hypothesized that 3 months of sildenafil (50 mg orally every 8 hours) added to standard treatment would be safe and improve functional capacity and hemodynamics in PAH patients. We studied 5 consecutive patients (4 with primary pulmonary hypertension, 1 with Eisenmenger's syndrome; New York Heart Association class II to III). Functional class improved by ≥ 1 class in all patients. Pretreatment versus posttreatment values (mean \pm SEM) were as follows: 6-minute walk, 376 ± 30 versus 504 ± 27 m, $P < 0.0001$; mean PA pressure, 70 ± 3 versus 52 ± 3 mm Hg, $P < 0.007$; pulmonary vascular resistance index 1702 ± 151 versus 996 ± 92 dyne \cdot s \cdot cm $^{-5}$ \cdot m $^{-2}$, $P < 0.006$. The systemic arterial pressure was unchanged, and no adverse effects occurred. Sildenafil also reduced right ventricular mass measured by MRI. In 7 human PAs (6 cardiac transplant donors and 1 patient with PAH on autopsy), we showed that PD-5 is present in PA smooth muscle cells and that sildenafil causes relaxation by activating large-conductance, calcium-activated potassium channels.

Conclusion—This small pilot study suggests that long-term sildenafil therapy might be a safe and effective treatment for PAH. At a monthly cost of \$492 Canadian, sildenafil is more affordable than most approved PAH therapies. A large multicenter trial is indicated to directly compare sildenafil with existing PAH treatments. (*Circulation*. 2003;108:2066-2069.)

Key Words: hypertension, pulmonary ■ sildenafil ■ potassium

The prognosis of patients with pulmonary arterial hypertension (PAH) is poor.¹ Available therapies (Ca²⁺-channel blockers, epoprostenol, and bosentan) have limited efficacy or are expensive and associated with significant complications. New, effective, well-tolerated, and cheaper alternative or adjunctive treatments are needed. It is likely that these therapies may target the NO pathway because it is depressed in a variety of models and patients with PAH (see review²) (Figure 1). Endothelium-derived or exogenous (inhaled) NO activates soluble guanylate cyclase, thereby stimulating the production of cyclic guanosine monophosphate (cGMP) in pulmonary artery (PA) smooth muscle cells (PASMCs). cGMP relaxes PASMCs through several mechanisms, including enhanced opening of large-conductance, calcium-sensitive K⁺ channels (BK_{Ca}),³ although this has not

been established in human PAs. The resulting PASMC membrane depolarization increases the open-probability of voltage-gated, L-type Ca²⁺ channels, increasing influx of Ca²⁺, thus promoting vasoconstriction and proliferation. Strategies enhancing the NO pathway in PAH² are illustrated in Figure 1. Short-term inhaled nitric oxide (iNO) reduces pulmonary vascular resistance in PAH,^{4,5} but ambulatory delivery in humans is cumbersome. Another strategy is to prolong the survival of cGMP in PASMCs by inhibiting type-5 phosphodiesterase (PD-5), an isoform that is primarily located in the penis and lungs, which rapidly degrades cGMP. Because of PD-5's tissue distribution (pulmonary > systemic vasculature), PD-5 inhibitors are attractive candidate pulmonary vasodilators that minimally decrease systemic blood pressure.² A single oral dose of the PD-5 inhibitor sildenafil

Received April 28, 2003; de novo received September 4, 2003; accepted September 9, 2003.

From the Vascular Biology Group and Pulmonary Hypertension Program, Department of Medicine (E.D.M., W.T., L.W., X.-C.W., S.L.A.), the Department of Diagnostic Imaging (M.N.), Division of Pulmonary Medicine (D.L.), and Department of Surgery (Cardiothoracic) (S.-H.W., D.M.), University of Alberta, Edmonton, Canada.

Correspondence to E.D. Michelakis, MD, University of Alberta, 2C2 Walter C Mackenzie Health Sciences Centre, 8440 112th St, Edmonton, Alberta, Canada, T6G 2B7. E-mail emichela@cha.ab.ca

© 2003 American Heart Association, Inc.

Circulation is available at <http://www.circulationaha.org>

DOI: 10.1161/01.CIR.0000099502.17776.C2

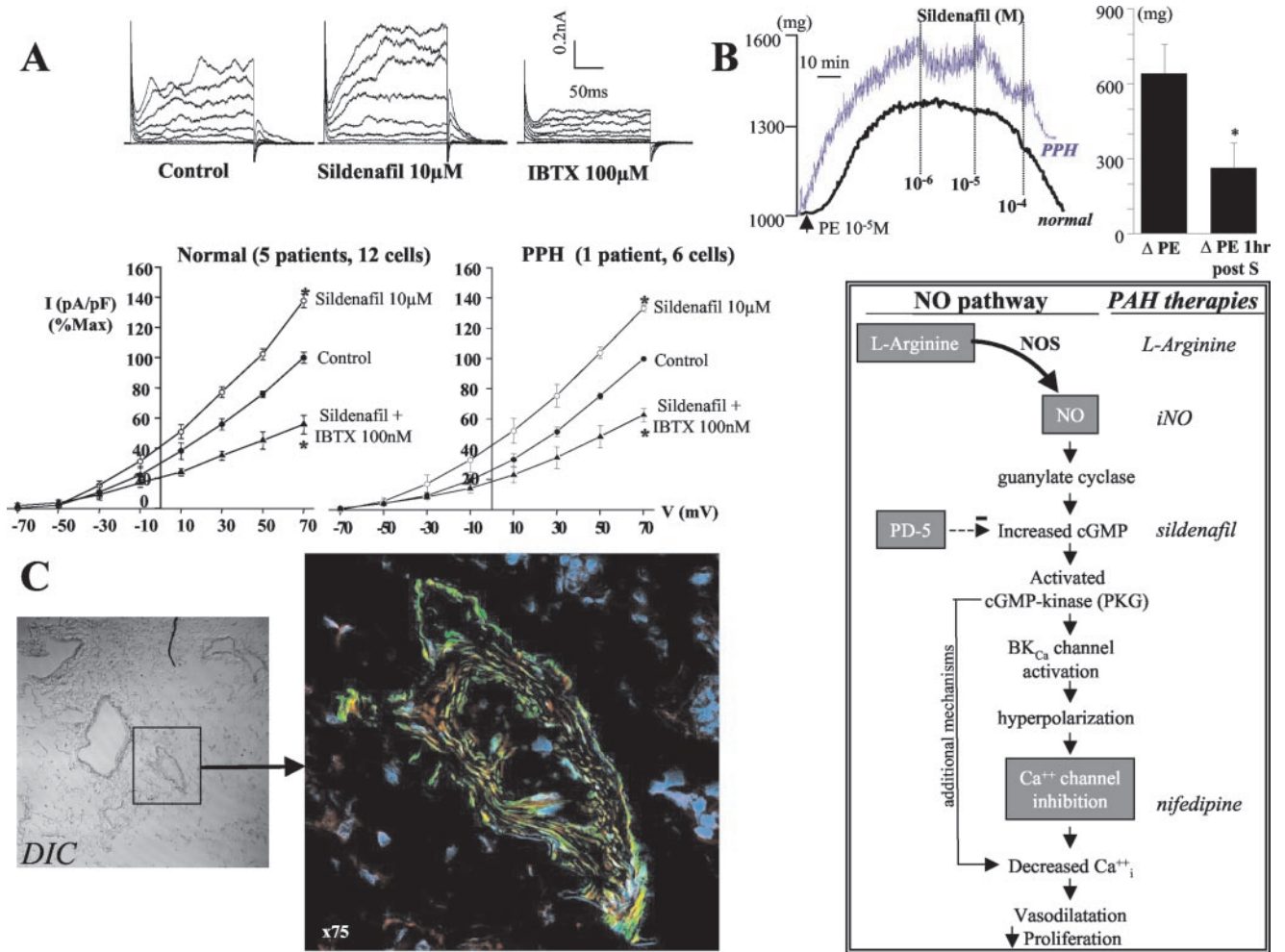


Figure 1. PD-5 is present in human PASMCs, and its inhibition by sildenafil causes activation of BK_{Ca} channels and PA vasodilatation. A, Representative traces (from a normal PA) and current density/voltage plots (current density=current amplitude/cell capacitance) from both normal (n=6) and PPH (n=1) freshly isolated PASMCs. IBTX indicates iberiotoxin. *P<0.05 vs control (repeated-measures ANOVA). B, Sildenafil causes acute vasodilatation in a dose-dependent manner (left) in both normal and PPH PAs precontracted with phenylephrine (PE). Effects of sildenafil (10⁻⁵ mol/L) persist for at least 1 hour after rinsing: Sildenafil-treated PAs (post S) constrict less on a second exposure to phenylephrine than they had before the administration of sildenafil (n=6). *P<0.02 (paired t test). C, Immunofluorescence of human PPH PA using multiphoton laser confocal imaging. Blue indicates DAPI-stained cell nuclei; green, smooth muscle actin-positive cells; and red, PD-5-positive cells. D, NO pathway and proposed targets for pharmacological intervention in the treatment of PAH. PKG indicates protein kinase G.

(75 mg) is an effective and relatively selective pulmonary vasodilator.^{4,5} We hypothesized that PD-5 inhibition acutely causes human PA dilatation, in part by opening of BK_{Ca} channels, and that it chronically improves hemodynamics and functional capacity in moderately severe PAH.

Methods

We studied 5 consecutive patients with PAH (n=4 New York Heart Association [NYHA] class III; patient 3 class II). All subjects provided informed consent. Patients with class IV PAH were excluded because they often require epoprostenol, which could confound the assessment of sildenafil's effects. All the patients had been stable for >3 months, and their standard therapy was not altered before initiation of sildenafil. All were on diuretics and coumadin, and patients 2 and 4 were on Ca²⁺ channel blockers because they had been shown to respond to iNO with >20% decrease in pulmonary vascular resistance (Figure 2). No patient was taking nitrates. All patients had primary pulmonary hypertension (PPH) except patient 2, who had Eisenmenger's syndrome (transposition of the great arteries, repaired 2 years earlier), with a residual

small ventricular septal defect (arterial O₂ saturation 90%, hemoglobin 123 g/L). PPH was a diagnosis of exclusion and required the demonstrated absence of a variety of cardiopulmonary and systemic diseases, as previously described.⁴ None of the patients had familial PAH.

Patients had a right heart catheterization and a 6-minute walk at baseline and after 3 months of treatment. Two 6-minute walks were performed before entering the study to avoid confounding training effects. The 6-minute walks were performed randomly during working hours, but the catheterizations always were performed early in the morning, before the morning dose of sildenafil. Patients 3, 4, and 5 had cardiac MRI at baseline and after 3 months of treatment. Patients 1 and 2 could not be studied because of claustrophobia and a pacemaker, respectively. MRI studies were performed on a 1.5 T Siemens Sonata unit using a body phase-array coil. The right ventricle was imaged using 8- to 9-mm contiguous, single-slice, breath-hold cine, true-FISP sequences in the short-axis plane.

Ex Vivo Mechanistic Study

PAs from 6 normal patients (transplant donors) and one patient with PPH (26 years of age, male, on epoprostenol for 1 year) were

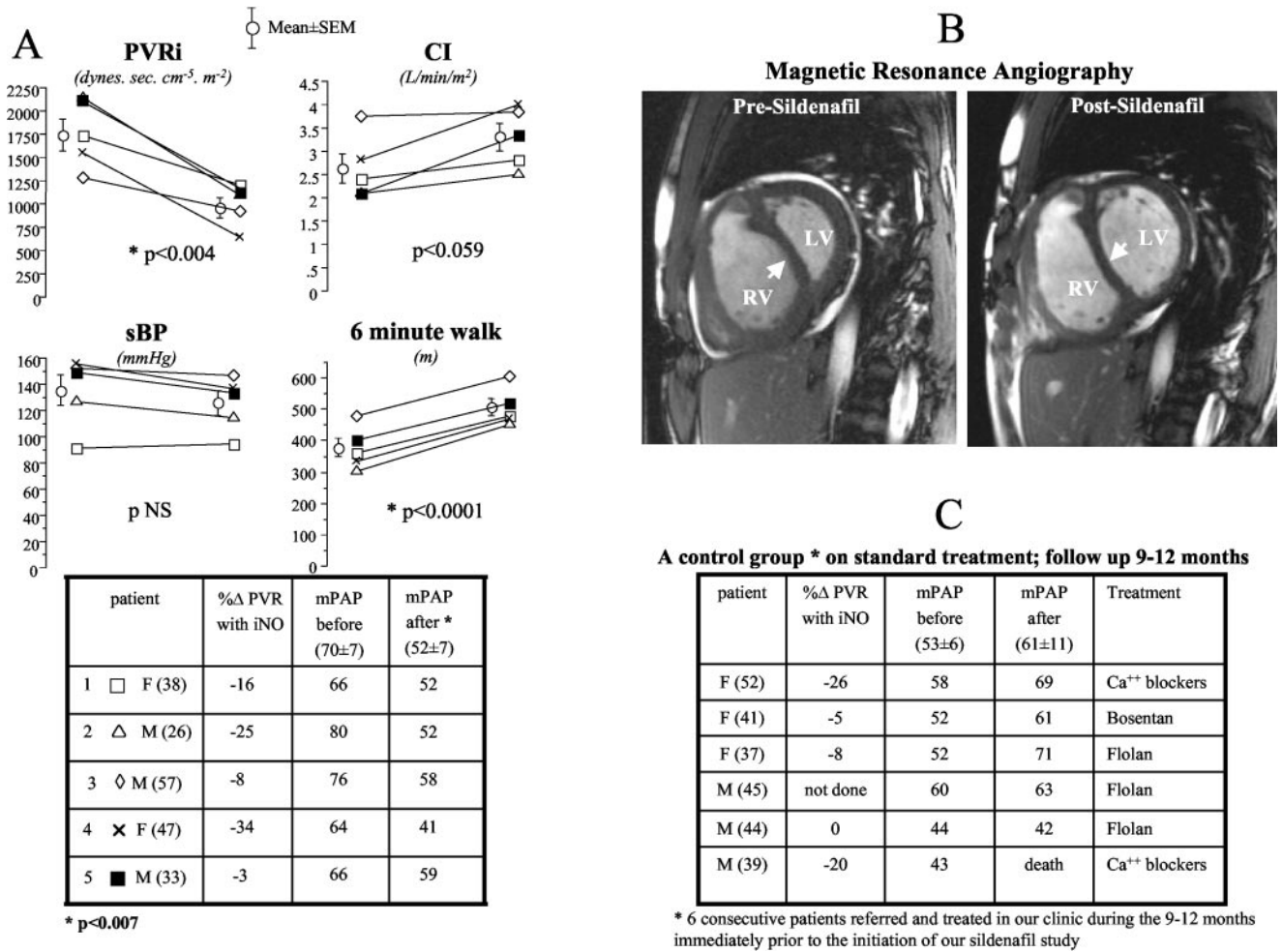


Figure 2. A, Long-term treatment with sildenafil improves hemodynamics and functional capacity (paired *t* test). B, MRI angiography shows reversal of the pathological septal shift after sildenafil treatment. C, PA pressure worsened or did not change in 6 consecutive PAH patients referred and treated in our clinic during the 9 to 12 months immediately before the initiation of our sildenafil study. PVR indicates pulmonary vascular resistance; PVRI, PVR index; CI, cardiac index; sBP, systolic blood pressure; mPAP, mean pulmonary artery pressure; RV, right ventricle; LV, left ventricle; F, female; and M, male.

harvested at the time of cardiac transplantation and studied within 1 hour in tissue baths. Freshly dispersed PASMCs were studied with whole-cell patch clamping, as previously described.⁶ PASMCs were superfused with extracellular fluid containing sildenafil or sildenafil plus the selective BK_{Ca} inhibitor iberiotoxin. The effects of sildenafil on PA tone were assessed in phenylephrine (10⁻⁵ mol/L)-precontracted human PA rings (optimal resting tension 1 g). The presence of PD-5 in resistance PAs was confirmed by immunofluorescence, using a multiphoton, confocal laser microscope (Zeiss). Antibodies for PD-5 (1:500 dilution, red fluorescence), smooth muscle actin (green), and DAPI (blue, staining nuclei) were obtained from Molecular Probes.

Results

PD-5 Is Present in Human PASMCs and Its Inhibition Relaxes Human PAs and Activates PASMC BK_{Ca} Channels

Sildenafil increases K⁺ currents in freshly isolated human PASMCs from both normal and PPH arteries (Figure 1A). A large component of the activated K⁺ current is due to activation of BK_{Ca} channels because it is inhibited by iberiotoxin. K⁺ current activation leads to PASMC vasodilatation, as shown by the dose-dependent sildenafil-induced vasodila-

tation of precontracted human normal and PPH PAs (Figure 1B). The vasodilating effects of sildenafil are sustained for at least 1 hour after sildenafil is washed off because a repeat challenge with phenylephrine causes significantly less constriction (Figure 1B). PD-5 is present in the media of both normal (not shown) and PPH PAs (Figure 1C), as shown by the colocalization of smooth muscle actin (green) and PD-5 (red).

Sildenafil Improves Hemodynamics and Functional Capacity in PAH

No visual abnormalities (blurred vision or color vision abnormalities) were observed during the 3-month period. Liver enzymes and creatinine remained unchanged for the duration of the study. The bleeding times did not change from baseline and 2 to 3 weeks after treatment were: 6, 7, 5.5, 8.5, and 6, respectively, for patients 1 to 5 (normal, <9 minutes).

After 3 months, the NYHA class improved to class II (4 patients) or class I (patient 3). Six-minute walk distances increased substantially, whereas the mean pulmonary artery pressure and the pulmonary vascular resistance index signif-

icantly decreased in all patients after treatment with sildenafil (Figure 2A). Cardiac index tended to increase after 3 months of sildenafil ($P=0.06$).

The right ventricular mass measured by MRI (Figure 2B) decreased from 102, 60, and 128 g to 95, 47, and 101 g, respectively, for patients 3, 4, and 5. The right ventricular ejection fraction improved from 31%, 49%, and 42% to 34%, 56%, and 45%, respectively, for patients 3, 4, and 5. The pathological septal shift, toward the left ventricle, that was present before treatment, was reversed by long-term sildenafil therapy (Figure 2B). Similar findings were noted echocardiographically.

Discussion

The primary finding of this study is that 3 months of treatment with oral sildenafil (50 mg orally every 8 hours) is well tolerated in PAH patients and significantly improves hemodynamics and functional capacity while causing regression of right ventricular hypertrophy. This translational, vascular biology study also demonstrates that in PAs from both normal and PPH patients, sildenafil causes vasodilation and activates PASM BK_{Ca} channels, a major mechanism by which NO has been shown to relax PAs in animal models.³

The 6-minute walk is a reliable index of functional capacity in patients with PAH and has been used as the primary end point in most PAH studies.^{7,8} In the epoprostenol study, which was not placebo controlled, a treatment-related improvement in 6-minute walk of 47 m was observed, and this was associated with improved survival.⁷ In the bosentan study, the patients on treatment walked 44 m more than those on placebo.⁸ The effects of bosentan on mortality rate were not studied. The improvement in the 6-minute walk of 128 m with sildenafil is significantly higher than the effects of both epoprostenol and bosentan.

Similarly to the epoprostenol study, our study was not placebo controlled. Although our sample size is very small, these patients were consecutive referrals. We reviewed the 6 patients with PAH that were referred to our program and followed up for the 9 to 12 months immediately before the initiation of our study (Figure 2C). These patients were all treated with standard therapy, and despite having a lower PA pressure at baseline than the sildenafil-treated group, functional class and hemodynamics worsened or did not change during the observation period (Figure 2C). In contrast, all patients treated with sildenafil significantly improved.

In contrast to the epoprostenol and bosentan studies, this series did not include class IV patients; however, the functional capacity of our patients at baseline was similar to subjects in those cohorts (mean \pm SD 6-minute walk at baseline: bosentan trial,⁸ 344 \pm 76 m; epoprostenol trial,⁷ 316 \pm 18 m; present study, 376 \pm 68 m). The improvement in functional

capacity in the present study is likely due to improvement in pulmonary hemodynamics and reduction in right ventricular afterload. In the epoprostenol study, the decrease in the mean pulmonary artery pressure was -4.8 mm Hg,⁷ whereas in the present study, the decrease was -18.0 mm Hg. Perhaps the apparent superiority of sildenafil on these end points relates to the inclusion of 2 patients who were iNO responders, although the iNO nonresponders seemed to have similar beneficial responses to sildenafil.

Although this is a small, nonrandomized single-center series, very similar results (in both 6-minute walks and hemodynamics) with long-term sildenafil therapy were recently reported in 2 open-label case series of PAH patients.^{9,10} The cost of treatment with sildenafil 50 mg orally every 8 hours is CAN \$6000 per year, which is 6 to 7 times cheaper than bosentan and 15 times cheaper than epoprostenol. The efficacy, simplicity, and potential cost savings of the oral PD-5 regimen support the need for larger trials and perhaps a head-to-head comparison of sildenafil and bosentan in PAH.

Acknowledgments

Both E.D. Michelakis and S.L. Archer are supported by the Alberta Heritage Foundation for Medical Research, Canadian Foundation for Innovation, Heart and Stroke Foundation, and the Canadian Institutes of Health Research. The Pulmonary Hypertension Program is funded by the Medical Services Delivery Innovation Fund, Alberta Department of Health (Dr Michelakis).

References

1. Archer S, Rich S. Primary pulmonary hypertension: a vascular biology and translational research "work in progress." *Circulation*. 2000;102:2781-2791.
2. Michelakis ED. The role of the NO axis and its therapeutic implications in pulmonary arterial hypertension. *Heart Fail Rev*. 2003;8:5-21.
3. Archer SL, Huang JM, Hampl V, et al. Nitric oxide and cGMP cause vasorelaxation by activation of a charybdotoxin-sensitive K channel by cGMP-dependent protein kinase. *Proc Natl Acad Sci USA*. 1994;91:7583-7587.
4. Michelakis E, Tymchak W, Lien D, et al. Oral sildenafil is an effective and specific pulmonary vasodilator in patients with pulmonary arterial hypertension: comparison with inhaled nitric oxide. *Circulation*. 2002;105:2398-2403.
5. Lepore JJ, Maroo A, Pereira NL, et al. Effect of sildenafil on the acute pulmonary vasodilator response to inhaled nitric oxide in adults with primary pulmonary hypertension. *Am J Cardiol*. 2002;90:677-680.
6. Michelakis ED, McMurtry MS, Wu XC, et al. Dichloroacetate, a metabolic modulator, prevents and reverses chronic hypoxic pulmonary hypertension in rats: role of increased expression and activity of voltage-gated potassium channels. *Circulation*. 2002;105:244-250.
7. Barst RJ, Rubin LJ, Long WA, et al. A comparison of continuous intravenous epoprostenol (prostacyclin) with conventional therapy for primary pulmonary hypertension. *N Engl J Med*. 1996;334:296-302.
8. Rubin LJ, Badesch DB, Barst RJ, et al. Bosentan therapy for pulmonary arterial hypertension. *N Engl J Med*. 2002;346:896-903.
9. Kothari SS, Duggal B. Chronic oral sildenafil therapy in severe pulmonary artery hypertension. *Indian Heart J*. 2002;54:404-409.
10. Sastry BK, Narasimhan C, Reddy NK, et al. A study of clinical efficacy of sildenafil in patients with primary pulmonary hypertension. *Indian Heart J*. 2002;54:410-414.