

# High Plasma Heparin Cofactor II Activity Is Associated With Reduced Incidence of In-Stent Restenosis After Percutaneous Coronary Intervention

Nobuyuki Takamori, MD; Hiroyuki Azuma, MD; Midori Kato, MD; Shunji Hashizume, MD; Ken-ichi Aihara, MD; Masashi Akaike, MD; Katsuya Tamura, MD; Toshio Matsumoto, MD

**Background**—Thrombin plays an important role in the development of atherosclerosis and restenosis after percutaneous coronary intervention. Because heparin cofactor II (HCII) inhibits thrombin action in the presence of dermatan sulfate, which is abundantly present in arterial wall, HCII may affect vascular remodeling by modulating thrombin action. We hypothesized that patients with high plasma HCII activity may show a reduced incidence of in-stent restenosis (ISR).

**Methods and Results**—Sequential coronary arteries (n=166) with NIR stent (Boston Scientific Corp) implantation in 134 patients were evaluated before, immediately after, and at 6 months after percutaneous coronary intervention. Patients were divided into the following groups: high HCII ( $\geq 110\%$ , 45 lesions in 36 patients), normal HCII ( $\geq 80\%$  and  $< 110\%$ , 81 lesions in 66 patients), and low HCII ( $< 80\%$ , 40 lesions in 32 patients). Percent diameter stenosis at follow-up in the high-HCII group (18.7%) was significantly lower ( $P=0.046$ ) than that in the normal-HCII group (30.3%) or the low-HCII group (29.0%). The ISR rate in the high-HCII group (6.7%) was significantly lower than that in the low-HCII group (30.0%) ( $P=0.0039$ ). Furthermore, multivariate analysis demonstrated that high plasma HCII activity is an independent factor in reducing the incidence of angiographic restenosis (odds ratio, 0.953/1% increase of HCII; 95% CI, 0.911 to 0.998).

**Conclusions**—The results demonstrate that HCII may have a hitherto unrecognized effect in inhibiting ISR. The effect of HCII may be mediated by inactivating thrombin in injured arteries, thereby inhibiting vascular smooth muscle cell migration and proliferation. (*Circulation*. 2004;109:481-486.)

**Key Words:** cardiovascular diseases ■ angioplasty ■ atherosclerosis ■ thrombin ■ dermatan sulfate

Thrombin plays a critical role in the development of atherosclerosis and restenosis after percutaneous coronary intervention (PCI) via activation of thrombin receptors (PAR-1 and -4) on endothelial cells, smooth muscle cells, macrophages, and fibroblasts.<sup>1,2</sup> Heparin cofactor II (HCII) and antithrombin (AT) serve as physiological inhibitors of thrombin actions, and inactivation of thrombin by these 2 serine protease inhibitors is accelerated  $>1000$ -fold by binding to glycosaminoglycans.<sup>3</sup> Among glycosaminoglycans, dermatan sulfate consists of  $\approx 9\%$  of all glycosaminoglycans in healthy human coronary arteries, and a significant increase in its distribution was detected in advanced atherosclerosis.<sup>4</sup> HCII binds to dermatan sulfate with high affinity and efficiently inactivates thrombin, whereas AT cannot bind to dermatan sulfate. These findings are consistent with the assumption that HCII exerts its antithrombin action by binding to dermatan sulfate at injured arterial walls, where

large amounts of thrombin are generated on the surface of smooth muscle cells, macrophages, and fibroblasts.<sup>3</sup>

Several families of congenital heterozygous HCII deficiency have been reported. Clinical characteristics of these family members were indicative of a mild increase in the risk of venous thrombosis.<sup>5-7</sup> Recently, we found a patient with congenital heterozygous deficiency of HCII caused by a missense mutation of the HCII gene showing multiple and severe atherosclerotic lesions, including coronary artery stenosis, stenosis of the internal carotid artery, renal artery stenosis, and abdominal aortic aneurysm.<sup>8</sup> Matsuo et al<sup>9</sup> also reported a patient with congenital heterozygous HCII deficiency manifesting severe coronary artery disease with recurrent angina pectoris after repeated percutaneous transluminal coronary angioplasty. Both of these patients were  $>60$  years old and had multiple risk factors for atherosclerosis. By analyzing clinical features of patients with congenital HCII

Received February 12, 2003; de novo received September 16, 2003; revision received October 24, 2003; accepted October 30, 2003.

From the Department of Medicine and Bioregulatory Sciences, University of Tokushima Graduate School of Medicine, Tokushima (N.T., H.A., M.K., S.H., K.A., M.A., T.M.), and Department of Cardiology, Health Insurance Naruto Hospital, Naruto (K.T.), Japan.

Presented in part at the 75th Scientific Sessions of the American Heart Association, Chicago, Ill, November 17–20, 2002, by Dr Takamori as a finalist for the Scientific Sessions 2002 Poster Competition in Percutaneous Coronary Intervention of the American Heart Association, and published in abstract form (*Circulation*. 2002;106[suppl II]:II-583).

Correspondence to Hiroyuki Azuma, MD, Department of Medicine and Bioregulatory Sciences, University of Tokushima Graduate School of Medicine, 3-18-15 Kuramoto-cho, Tokushima 770-8503, Japan. E-mail hiroyuki@clin.med.tokushima-u.ac.jp

© 2004 American Heart Association, Inc.

*Circulation* is available at <http://www.circulationaha.org>

DOI: 10.1161/01.CIR.0000109695.39671.37

deficiency reported thus far, we found that most of probands <40 years old suffered from deep vein thrombosis, whereas older probands >40 years old tended to manifest atherosclerotic disorders, including angina pectoris and cerebral infarction.<sup>10</sup> From these observations, we hypothesized that patients with HCII deficiency have decreased capability of thrombin inactivation, which leads to enhanced actions of thrombin in smooth muscle cells, macrophages, and fibroblasts at injured arterial walls. Thus, if a patient with HCII deficiency has risk factors for atherosclerosis, the insufficient antithrombin actions of HCII at injured arterial walls accelerate the development and aggravation of atherosclerotic lesions.

Stent implantation has become a major therapeutic procedure for percutaneous myocardial revascularization. Despite excellent immediate outcomes, 7% to 37% of patients with coronary stent implantation are reported to develop angiographic restenoses and require additional treatments.<sup>11</sup> Recent histopathologic studies after coronary stenting have shown that in-stent restenosis (ISR) results from smooth muscle cell proliferation and extracellular matrix formation.<sup>12,13</sup> Therefore, it is plausible to assume that higher plasma HCII activity represents higher inhibitory activity of HCII against thrombin at injured arterial walls, which leads to a reduced incidence of ISR after coronary stenting. Thus, the present study was undertaken to clarify whether high plasma HCII activity can reduce ISR after stent implantation.

## Methods

### Subjects

A consecutive series of patients who had had symptomatic coronary arterial disorders successfully treated with stenting and had undergone follow-up angiography in the period between April 1998 and November 2002 at Health Insurance Naruto Hospital were enrolled in this study. Exclusion criteria included target lesions with chronic total obstruction, coronary aneurysm, saphenous vein graft, and inability to perform follow-up angiography. All patients were treated with stenting using NIR stents (Boston Scientific Corp). The study followed the institutional guidelines of the University of Tokushima and Health Insurance Naruto Hospital, and informed consent was obtained from all patients according to the Declaration of Helsinki.

### Intervention Procedure

All patients received bolus heparin injections (10 000 U) before procedures, followed by continuous infusion of heparin supplements (500 U/h) for  $\geq 24$  hours. Patients were given a daily dose of aspirin (81 or 100 mg) before the procedure and an additional daily dose of ticlopidine (200 mg) for 1 month after the procedure. Intervention procedures were performed by means of the femoral approach, with arterial introducers of size 6F to 8F. Stent placement was performed according to standard methods. Success of the procedures was defined as a reduction in stenosis to <50% by quantitative coronary angiography, with a TIMI grade 3 flow without dissection.

### Quantitative Coronary Angiography

After isosorbide dinitrate administration, matched views were selected from angiograms recorded before (baseline), immediately after (post), and at 6 months (follow-up) after intervention procedures. Films at the procedure and after 6 months were read in a blinded fashion using the Cardiovascular Measurement System (CCIP-310/W, Cathex Co) at the Tokushima University Hospital. The 6-month angiographies were analyzed by side-by-side projection of treatment catheters to ensure accurate identification of stents.

Target sites were defined as segments of stent injury necessary to treat lesions. Reference diameter, minimal lumen diameter (MLD), and percent diameter stenosis (%DS) of a target site were determined. Acute lumen gain was defined as the difference in MLD between measurement at the end of intervention and before balloon dilatation. Late lumen loss was calculated as the difference in MLD between measurements immediately after procedures and at 6-month follow-up. Late loss index was expressed by dividing late lumen loss by acute lumen gain. Angiographic restenosis was defined by %DS $\geq$ 50%.

### End Points

The primary end point was the stenosis rate defined as %DS $\geq$ 50% measured by quantitative coronary angiography at 6-month follow-up. Secondary end points included major adverse clinical events, such as all-cause deaths, myocardial infarction, stroke, and target vessel revascularization (PCI or CABG) during the 6-month follow-up period. Myocardial infarction was defined by the presence of new Q waves or the elevation of the MB isoenzyme of creatine kinase level to twice the upper limit of normal values.

### Measurements of Plasma HCII and AT Activities

Blood was drawn from all patients at 6-month follow-up, collected into a tube containing 1/10 volume of 3.8% sodium citrate, and centrifuged at 2000g for 20 minutes. Plasma was stored at  $-80^{\circ}\text{C}$  until use. Plasma HCII activity was measured on the basis of AT activity in the presence of dermatan sulfate with a Stachrom HCII kit (Diagnostica Stago). The intra-assay and interassay coefficients of variation of this kit were 3.9% and 4.3%, respectively. Plasma AT activity was measured by a chromogenic method based on AT activity in the presence of heparan sulfate using a Testzyme ATIII-2 kit (Kabi Diagnostica AB).

### Statistical Analyses

Statistical analyses were performed with the StatView statistical package (StatView 5.0, SAS Institute Inc). Comparisons of continuous variables between groups were performed by repeated-measures 1-way ANOVA or Fisher's protected least significant difference test. Comparisons of noncontinuous variables between groups were performed with the Kruskal-Wallis test. Subgroup comparisons of categorical variables were assessed by the  $\chi^2$  test. Multivariate analysis (logistic regression) was performed to determine parameters that predict angiographic restenosis (%DS $\geq$ 50%).

## Results

### Study Patients

Because stent thrombosis occurred in 1 patient (1 coronary lesion) and this patient was treated with additional stent implantation, this case was excluded from the study. Therefore, a total of 166 treated lesions in 134 consecutive patients were analyzed in this study. During the 6 months, there was no clinical event such as myocardial infarction, stroke, or death.

Plasma HCII activities in 134 patients measured in this study ranged from 36.9% to 212.3% ( $97.7 \pm 24.8\%$ , mean $\pm$ SD). We tentatively classified these patients as follows, because plasma HCII activity >20% and <20% (approximately  $\pm 1$  SD) of the mean value is  $\approx 110\%$  and 80%, respectively: Patients with HCII activity >110% were classified as the high-HCII group, those with <80% as the low-HCII group, and those from 80% to 110% as the normal-HCII group. By this classification, the high-, normal-, and low-HCII groups consisted of 36 patients (45 lesions), 66

TABLE 1. Basic Clinical Characteristics

|                      | HCII Activity, % |                        |                | <i>P</i> |
|----------------------|------------------|------------------------|----------------|----------|
|                      | <80<br>(n=32)    | ≥80 and <110<br>(n=66) | ≥110<br>(n=36) |          |
| Male/female          | 25/7             | 42/24                  | 31/5           | 0.039    |
| Age, y               | 64.6±7.8         | 65.9±10.3              | 62.7±9.6       | NS       |
| Diabetes mellitus    | 10 (31.3)        | 19 (28.8)              | 14 (38.9)      | NS       |
| Hypercholesterolemia | 10 (31.3)        | 20 (30.3)              | 16 (44.4)      | NS       |
| Low HDL cholesterol  | 3 (9.4)          | 8 (12.1)               | 3 (8.3)        | NS       |
| Hypertension         | 5 (15.6)         | 12 (18.2)              | 9 (25.0)       | NS       |
| Current smoking      | 6 (18.8)         | 14 (21.2)              | 11 (30.6)      | NS       |
| Branch               |                  |                        |                | NS       |
| LAD                  | 16               | 31                     | 16             |          |
| LCx                  | 4                | 12                     | 6              |          |
| RCA                  | 12               | 23                     | 14             |          |
| Events of CHD        |                  |                        |                | NS       |
| Acute MI             | 11               | 18                     | 15             |          |
| Angina pectoris      | 17               | 40                     | 17             |          |
| Previous MI          | 4                | 8                      | 4              |          |

Values are n (%) or mean±SD. LAD indicates left anterior descending coronary artery; LCx, left circumflex artery; RCA, right coronary artery; CHD, coronary heart disease; and MI, myocardial infarction.

patients (81 lesions), and 32 patients (40 lesions), respectively. Baseline clinical characteristics of the 3 groups were well matched with regard to various parameters other than gender difference (Table 1).

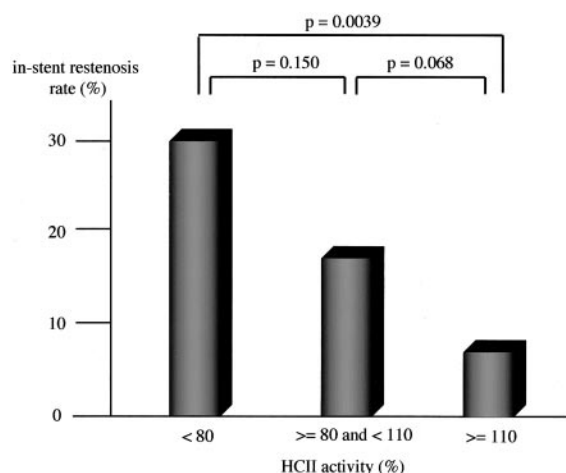
### Procedural Comparison

As shown in Table 2, quantitative coronary angiography data obtained at baseline and immediately after procedure were not significantly different among the 3 groups. However, %DS at follow-up, which indicates the degree of angio-

graphic restenosis, was significantly lower ( $P=0.046$ ) in the high-HCII group ( $18.7\pm24.3\%$ ) than in the normal-HCII ( $30.3\pm24.8\%$ ) or low-HCII ( $29.0\pm29.0\%$ ) group. In addition, the ISR rate in the high-HCII group was only 6.7% (3 of 45), whereas the values in the normal-HCII and low-HCII groups were 18.5% (15 of 81) and 30.0% (12 of 40), respectively (Figure 1). Thus, the difference of ISR rate between the high-HCII and low-HCII groups was statistically significant ( $P=0.0039$ ), and that between the high-HCII and normal-HCII groups was nonsignificant ( $P=0.068$ ).

TABLE 2. Quantitative Coronary Angiographic Data

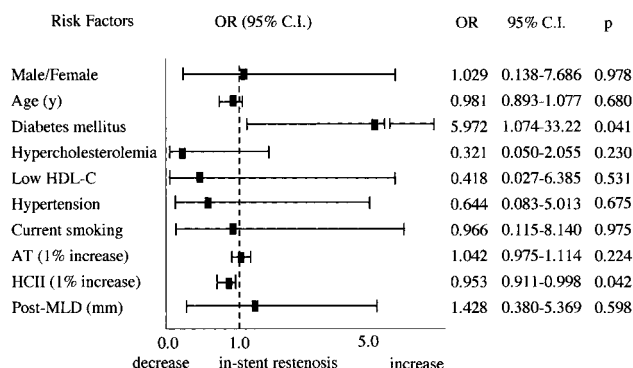
|                        | HCII Activity, % |                        |                | <i>P</i> |
|------------------------|------------------|------------------------|----------------|----------|
|                        | <80<br>(n=40)    | ≥80 and <110<br>(n=81) | ≥110<br>(n=45) |          |
| At baseline            |                  |                        |                |          |
| Reference diameter, mm | 3.09±0.74        | 2.90±0.66              | 2.99±0.67      | NS       |
| MLD, mm                | 0.48±0.54        | 0.60±0.74              | 0.60±0.49      | NS       |
| %DS                    | 84.6±16.7        | 81.0±17.9              | 80.0±16.1      | NS       |
| Post                   |                  |                        |                |          |
| Reference diameter, mm | 3.12±0.61        | 2.95±0.62              | 3.10±0.63      | NS       |
| MLD, mm                | 2.92±0.70        | 2.86±0.70              | 3.00±0.62      | NS       |
| %DS                    | 6.40±12.1        | 1.44±20.7              | 1.91±17.2      | NS       |
| Acute gain, mm         | 2.44±0.79        | 2.26±0.92              | 2.41±0.71      | NS       |
| Follow-up              |                  |                        |                |          |
| Reference diameter, mm | 3.10±0.66        | 2.90±0.67              | 3.06±0.70      | NS       |
| MLD, mm                | 2.17±1.00        | 2.04±0.86              | 2.37±0.71      | NS       |
| %DS                    | 29.0±29.0        | 30.3±24.8              | 18.7±24.3      | 0.046    |
| Late lumen loss, mm    | 0.77±1.02        | 0.82±0.79              | 0.63±0.62      | NS       |
| Late loss index        | 0.33±0.40        | 0.40±0.35              | 0.29±0.33      | NS       |



**Figure 1.** Comparison of ISR rate after coronary stenting in high-HCII, normal-HCII, and low-HCII groups. ISR rate in high-HCII group was only 6.7%, whereas values in normal-HCII and low-HCII groups were 18.5% and 30.0%, respectively. Difference of ISR rate between high-HCII and low-HCII groups was statistically significant ( $P=0.0039$ ), and that between high-HCII and normal-HCII groups was not significant ( $P=0.068$ ).

### Multivariate Analysis

As shown in Figure 2, multivariate analysis of risk factors for ISR demonstrated that plasma HCII activity is an independent factor in reducing the incidence of angiographic restenosis (odds ratio, 0.953; 95% CI, 0.911 to 0.998;  $P=0.042$ ). This value, 0.953, represents a value of a 1% increase of plasma HCII activity; thus, it is notable that the odds ratio of HCII as a predictor for ISR is calculated to be 0.786 (95% CI, 0.627 to 0.990) and 0.618 (95% CI, 0.394 to 0.980) when plasma HCII activity increases by 5% and 10%, respectively. Diabetes mellitus was significantly associated with the progression of ISR (odds ratio, 5.972; 95% CI, 1.074 to 33.221;  $P=0.041$ ). No association was observed in gender, age, hypercholesterolemia, hypertension, smoking, or plasma level of AT activity.



**Figure 2.** Multivariate analysis for risk factors that affect ISR. Multivariate analysis demonstrated that plasma HCII activity and diabetes mellitus were negatively and positively associated with angiographic restenosis, respectively. It is notable that odds ratio of HCII represents a value of 1% increase in plasma HCII activity. Other risk factors did not show significant association. HDL-C indicates HDL cholesterol.  $P<0.05$ .

### Discussion

Among risk factors identified for ISR, female gender, MLD immediately after PCI, lesion length, and presence of diabetes mellitus are well-known predictors for ISR.<sup>14-16</sup> In addition, high plasma levels of homocysteine, lipoprotein (a), insulin, insulin-like growth factor I, and soluble CD40 ligand are also reported to be associated with ISR.<sup>11,17-19</sup> All the above predictive factors for ISR are prestenotic when their plasma levels are elevated. In the present study, prospective follow-up of patients successfully treated with stent implantation demonstrated that plasma HCII activity  $>110\%$  is associated with a reduced risk for ISR at 6 months after PCI. These results suggest that HCII may be a hitherto unrecognized negative predictor for ISR.

Multivariate analysis also showed that plasma AT activity has no relationship with ISR, further supporting the notion that the locations of action of these 2 thrombin inhibitors in vascular tissues are different.<sup>20</sup> In fact, AT/heparin complex can inactivate soluble thrombin but not surface-bound thrombin, whereas HCII/dermatan sulfate complex can inhibit both forms of thrombin.<sup>3</sup> After vascular injury, expression of tissue factor on vascular smooth muscle cells, macrophages, and fibroblasts in both media and intima is upregulated, leading to overproduction of surface-bound thrombin.<sup>1,21-23</sup> In addition, vascular smooth muscle cells and fibroblasts also secrete dermatan sulfate. Because binding of HCII to dermatan sulfate greatly enhances its antithrombin action, the presence of these types of cells but not endothelial cells can activate HCII and inhibit thrombin action in arterial walls. When plasma HCII level is elevated, more HCII is expected to bind to dermatan sulfate in arterial walls. The formation of HCII/dermatan sulfate complex leads to an efficient inactivation of surface-bound thrombin, which is expected to reduce ISR by inhibiting proliferation of vascular smooth muscle cells and fibroblasts.

In our preliminary studies, we analyzed difference in restenosis rate between the high-, normal-, and low-HCII groups of patients after balloon angioplasty, which resulted in negative findings, with no significant influence of plasma HCII activity on coronary restenosis (data not shown). The pathogenesis of restenosis after balloon angioplasty is reported to be a combination of negative vascular remodeling and intimal hyperplasia. In contrast, a histopathologic study of coronary arteries from patients undergoing coronary stenting has shown that ISR is caused primarily by intimal hyperplasia composed of proliferated smooth muscle cells and increased extracellular matrix without negative vascular remodeling.<sup>12,13</sup> In addition, ISR tissue is composed of larger areas of smooth muscle cells and proliferative cells with smaller areas of macrophages and collagen deposition compared with restenotic tissues after balloon angioplasty.<sup>24</sup> Thus, it is conceivable that the reason why we could not detect a significant influence of plasma HCII activity on coronary restenosis after balloon angioplasty is a difference in the pathogenesis of restenosis after the 2 interventional procedures.



In an injury model of rabbit carotid artery, Buchanan and Brister<sup>25</sup> demonstrated that acute infusion of dermatan sulfate prevented neointimal hyperplasia by 45% and 47% after the first and second injuries, respectively. Although dermatan sulfate infusion also decreased vessel wall occlusion by 47% and 33% after the first and second injuries, respectively, heparin treatment showed no effectiveness on the prevention of neointimal hyperplasia or vessel wall occlusion.<sup>25</sup> Moreover, direct administration of HCII in a rat model prevented photochemically induced acute thrombus formation, and intimatan (dermatan 4,6-di-*O*-sulfate) administration in a canine model also significantly suppressed arterial thrombotic occlusion induced by electrolytic injury, whereas low-molecular-weight heparin had no effect.<sup>26,27</sup> In homozygous HCII-deficient mice, the time of formation of occlusive thrombus in the carotid artery after photochemically induced endothelial injury was shorter than that of wild-type mice.<sup>20</sup> Taken together, these results are consistent with the notion that thrombin activates and enhances proliferation of vascular smooth muscle cells, leading to neointimal hyperplasia, and that surface-bound thrombin can be inactivated by HCII/dermatan sulfate complex but not AT/heparin complex.

The possibility remains that the relation between high HCII activity and low incidence of ISR might be an epiphenomenon. To date, elevation of plasma HCII levels has been documented only in such physiological and pathological conditions as pregnancy, acute inflammation, nephrotic syndrome, and hemorrhagic stroke or in women taking oral contraceptives.<sup>10</sup> No patients with these conditions were included in this study; however, unknown factors involved in the reduction of ISR that concomitantly elevate plasma HCII activity may be present. If this is the case, finding factors that upregulate plasma HCII activity may lead to the identification of novel therapeutic targets for reducing ISR.

Several drugs, including probucol, cilostazol, troglitazone, valsartan, and pemirolast, have been reported to be effective in preventing ISR in randomized clinical trials.<sup>28–32</sup> In addition, recent studies with drug-eluting stents have shown excellent outcomes in reducing the restenosis rate of de novo lesions to <5%.<sup>33</sup> In particular, clinical trials with sirolimus (rapamycin)-eluting stents showed long-term inhibition of neointimal hyperplasia for up to 2 years.<sup>34,35</sup> In a rabbit model, everolimus, an orally active sirolimus, is also effective in inhibiting in-stent neointimal proliferation.<sup>12</sup> However, use of pharmacological agents is frequently associated with adverse events and drug resistance. Because HCII acts as a physiological endogenous inhibitor of in-stent neointimal proliferation and restenosis, the present results warrant further studies to examine the effect of HCII-eluting or -coated stents in inhibiting ISR. Animal studies to clarify these issues are under way.

### Acknowledgments

This study was supported in part by Grants-in-Aid for Scientific Research from the Ministry of Education, Culture, Sports, Science, and Technology of Japan.

### References

- DiCorleto PE. Cellular mechanisms of atherogenesis. *Am J Hypertens*. 1993;6:314S–318S.
- Wilensky RL, Pyles JM, Fineberg N. Increased thrombin activity correlates with increased ischemic event rate after percutaneous transluminal coronary angioplasty: lack of efficacy of locally delivered urokinase. *Am Heart J*. 1999;138:319–325.
- Tollefsen DM. Insight into the mechanism of action of heparin cofactor II. *Thromb Haemost*. 1995;74:1209–1214.
- Tammi M, Seppala PO, Lehtonen A, et al. Connective tissue components in normal and atherosclerotic human coronary arteries. *Atherosclerosis*. 1978;29:191–194.
- Sie P, Dupouy D, Pichon J, et al. Constitutional heparin co-factor II deficiency associated with recurrent thrombosis. *Lancet*. 1985;2:414–416.
- Tran TH, Marbet GA, Duckert F. Association of hereditary heparin co-factor II deficiency with thrombosis. *Lancet*. 1985;2:413–414.
- Blinder MA, Andersson TR, Abildgaard U, et al. Heparin cofactor II: mutation of Arg-189 to His decreases the affinity for dermatan sulfate. *J Biol Chem*. 1989;264:5128–5133.
- Kanagawa Y, Shigekiyo T, Aihara K, et al. Molecular mechanism of type I congenital heparin cofactor (HC) II deficiency caused by a missense mutation at reactive P2 site: HC II Tokushima. *Thromb Haemost*. 2001;85:101–107.
- Matsuo T, Kario K, Sakamoto S, et al. Hereditary heparin cofactor II deficiency and coronary artery disease. *Thromb Res*. 1992;65:495–505.
- Tollefsen DM. Heparin cofactor II deficiency. *Arch Pathol Lab Med*. 2002;126:1394–1400.
- Lowe HC, Oesterle SN, Khachigian LM. Coronary in-stent restenosis: current status and future strategies. *J Am Coll Cardiol*. 2002;39:183–193.
- Farb A, Sangiorgi G, Carter AJ, et al. Pathology of acute and chronic coronary stenting in humans. *Circulation*. 1999;99:44–52.
- Komatsu R, Ueda M, Naruko T, et al. Neointimal tissue response at sites of coronary stenting in humans: macroscopic, histological, and immunohistochemical analyses. *Circulation*. 1998;98:224–233.
- Mercado N, Boersma E, Wijns W, et al. Clinical and quantitative coronary angiographic predictors of coronary restenosis: a comparative analysis from the balloon-to-stent era. *J Am Coll Cardiol*. 2001;38:645–652.
- Kishi K, Hiasa Y, Suzuki N, et al. Predictors of recurrent restenosis after coronary stenting: an analysis of 197 patients. *J Invasive Cardiol*. 2002;14:187–191.
- Sheiban I, Leonardo F, Rosano GM, et al. Predictors of long-term clinical outcome in patients undergoing multiple vessel stenting for coronary artery disease. *Ital Heart J*. 2000;1:480–486.
- Imazu M, Sumii K, Yamamoto H, et al. Hyperinsulinemia as a risk factor for restenosis after coronary balloon angioplasty. *Jpn Circ J*. 2001;65:947–952.
- Schnyder G, Roffi M, Flammer Y, et al. Effect of homocysteine-lowering therapy with folic acid, vitamin B<sub>12</sub>, and vitamin B<sub>6</sub> on clinical outcome after percutaneous coronary intervention: the Swiss Heart study: a randomized controlled trial. *JAMA*. 2002;288:973–979.
- Frystyk J, Ledet T, Moller N, et al. Cardiovascular disease and insulin-like growth factor I. *Circulation*. 2002;106:893–895.
- He L, Vicente CP, Westrick RJ, et al. Heparin cofactor II inhibits arterial thrombosis after endothelial injury. *J Clin Invest*. 2002;109:213–219.
- Harker LA. Role of platelets and thrombosis in mechanisms of acute occlusion and restenosis after angioplasty. *Am J Cardiol*. 1987;60:20B–28B.
- Kranzhofer R, Maraganore JM, Baci R, et al. Systemic thrombin inhibition by Hirulog does not alter medial smooth muscle cell proliferation and inflammatory activation after vascular injury in the rabbit. *Cardiovasc Drugs Ther*. 1999;13:429–434.
- Wilcox JN, Blumenthal BF. Thrombotic mechanisms in atherosclerosis: potential impact of soy proteins. *J Nutr*. 1995;125:631S–638S.
- Moreno PR, Palacios IF, Leon MN, et al. Histopathologic comparison of human coronary in-stent and post-balloon angioplasty restenotic tissue. *Am J Cardiol*. 1999;84:462–466, A9.
- Buchanan MR, Brister SJ. Inhibition of chronic vessel wall intimal hyperplasia following acute anticoagulant treatment: relative effects of heparin and dermatan sulphate. *Thromb Res*. 1998;91:157–167.

26. Yamanaga K, Yuuki T, Tsukada M, et al. Heparin cofactor II inhibits thrombus formation in a rat thrombosis model. *Thromb Res.* 2000;98:95–101.
27. Hennen JK, Hong TT, Shergill AK, et al. Intimatan prevents arterial and venous thrombosis in a canine model of deep vessel wall injury. *J Pharmacol Exp Ther.* 2002;301:1151–1156.
28. Lee HS, Tardif JC, Harel F, et al. Effects of plaque composition on vascular remodelling after angioplasty in the MultiVitamins and Probucol (MVP) trial. *Can J Cardiol.* 2002;18:271–275.
29. Kamishirado H, Inoue T, Mizoguchi K, et al. Randomized comparison of cilostazol versus ticlopidine hydrochloride for antiplatelet therapy after coronary stent implantation for prevention of late restenosis. *Am Heart J.* 2002;144:303–308.
30. Muller R, Bullesfeld L, Gerckens U, et al. State of treatment of coronary artery disease by drug releasing stents [in German]. *Herz.* 2002;27:508–513.
31. Takagi T, Akasaka T, Yamamuro A, et al. Troglitazone reduces neointimal tissue proliferation after coronary stent implantation in patients with non-insulin dependent diabetes mellitus: a serial intravascular ultrasound study. *J Am Coll Cardiol.* 2000;36:1529–1535.
32. Peters S, Gotting B, Trummel M, et al. Valsartan for prevention of restenosis after stenting of type B2/C lesions: the VAL-PREST trial. *J Invasive Cardiol.* 2001;13:93–97.
33. Schwartz RS, Edelman ER, Carter A, et al. Drug-eluting stents in preclinical studies: recommended evaluation from a consensus group. *Circulation.* 2002;106:1867–1873.
34. Presbitero P, Ascoli M. Drug-eluting stents do they make the difference? [in Italian]. *Minerva Cardioangiol.* 2002;50:431–442.
35. Regar E, Serruys PW, Bode C, et al. Angiographic findings of the multicenter Randomized Study With the Sirolimus-Eluting Bx Velocity Balloon-Expandable Stent (RAVEL): sirolimus-eluting stents inhibit restenosis irrespective of the vessel size. *Circulation.* 2002;106:1949–1956.