

The Electrocardiogram 102 Years After Einthoven

Hein J.J. Wellens, MD; Anton P. Gorgels, MD

In 2002, we celebrated in the Netherlands the 100th anniversary of Einthoven's first publication on the electrocardiogram (ECG).^{1,2} During the past century, the ECG has become indispensable for rapid diagnosis and management of patients with a wide variety of cardiac diseases. As pointed out by Fisch,³ the ECG is an easily available, patient-friendly, noninvasive, inexpensive, and reproducible technique, without peer for the diagnosis of myocardial ischemia, cardiac arrhythmias, structural changes of the myocardium, drug effects, and electrolyte and metabolic disturbances.

Twenty years ago, we reviewed the advances in electrocardiology at that time.⁴ Now, we would like to discuss new information that can be obtained from the "simple" 12-lead ECG. The limited number of words allowed in an editorial makes it impossible to discuss the ionic and cellular basis of the normal and abnormal ECG and to look at recent studies that used more sophisticated and complex noninvasive techniques to obtain information about the electrical activity of the heart. We will focus on 4 areas in which new information that is useful in our daily cardiology practice has become available.

1. Acute Coronary Syndromes: Determining the Extent and Severity of Cardiac Ischemia

In recent years, rapid decision-making has become mandatory in patients presenting with symptoms of acute cardiac ischemia. In that situation, information about the size of the area at risk and the severity of ischemia is essential. The ECG can (and should) play an important role in selecting the need for and type of coronary reperfusion procedure.

Traditionally, in ST-segment-elevation myocardial infarction, the size of the area at risk can be estimated from the ST-segment deviation score.⁵ Counting the number of millimeters that the ST segment deviates (elevated or depressed) from the isoelectric line in the 12-lead ECG is an easy method to obtain information about the size of the area at risk. The higher the ST-segment deviation number, the larger the area.

More recently, it was shown that the ECG could also indicate the site of occlusion in the coronary artery tree.

Obviously, a proximal occlusion in the left anterior descending coronary artery above the first septal branch and the first diagonal branch means that a much larger part of the ventricle is at risk than during an occlusion more distal in the left anterior descending coronary artery. ECG criteria to diagnose the site of origin of occlusion in the coronary artery have been published.^{6,7} That information is of importance, not only in relation to selecting an immediate percutaneous coronary intervention versus thrombolytic therapy, but also in making decisions about an invasive procedure in case of failed thrombolysis or an early reocclusion.

In unstable angina and non-ST-segment-elevation myocardial infarction, the number and type of leads showing ST depression together with the severity of ST depression correlate with the number of coronary vessels that are critically narrowed and their site of stenosis.⁸ Such information is indispensable for selecting the appropriate mode of diagnostic intervention and treatment.⁹ After a reperfusion attempt, disappearance of or a marked reduction in ST-segment deviation indicates restoration of blood flow to the threatened myocardial area¹⁰ with consequences for prognosis of the patient. It also has been shown that reperfusion arrhythmias, such as the accelerated idioventricular rhythm, indicate not only reperfusion but also myocardial damage (as shown by an enzyme rise) and abnormal wall motion, when compared with patients not showing reperfusion arrhythmias after recanalization.^{11,12} Reperfusion arrhythmias are less common after a primary percutaneous coronary intervention.¹³

2. Cardiac Arrhythmias: Localizing the Site of Origin or Pathway of a Tachycardia

In supraventricular tachycardias, the 12-lead ECG usually allows identification of where in the heart the arrhythmia originates and frequently the mechanism.¹⁴ The 12-lead ECG during a supraventricular tachycardia often is now sufficient to differentiate among atrial tachycardia, atrial flutter, atrioventricular (AV) nodal tachycardia, and tachycardias incorporating an accessory AV pathway in the tachycardia circuit¹⁴ and to identify whether catheter ablation is possible.

In patients with the Wolff-Parkinson-White syndrome, the ECG not only helps to localize the ventricular insertion site of the accessory AV pathway by looking at the P-delta interval and the polarity of the delta wave, but also allows the location of the atrial end of the accessory pathway by analyzing the polarity of the P wave during orthodromic tachycardia (a tachycardia with AV conduction over the AV node-His pathway and ventriculoatrial conduction over the accessory pathway). When a single accessory pathway is present, the atrial and the ventricular end should be located close together, a so-called match. When they are not in the same area of the AV ring (a mismatch) more than one accessory pathway is present. In atrial flutter, specific ECG patterns are often

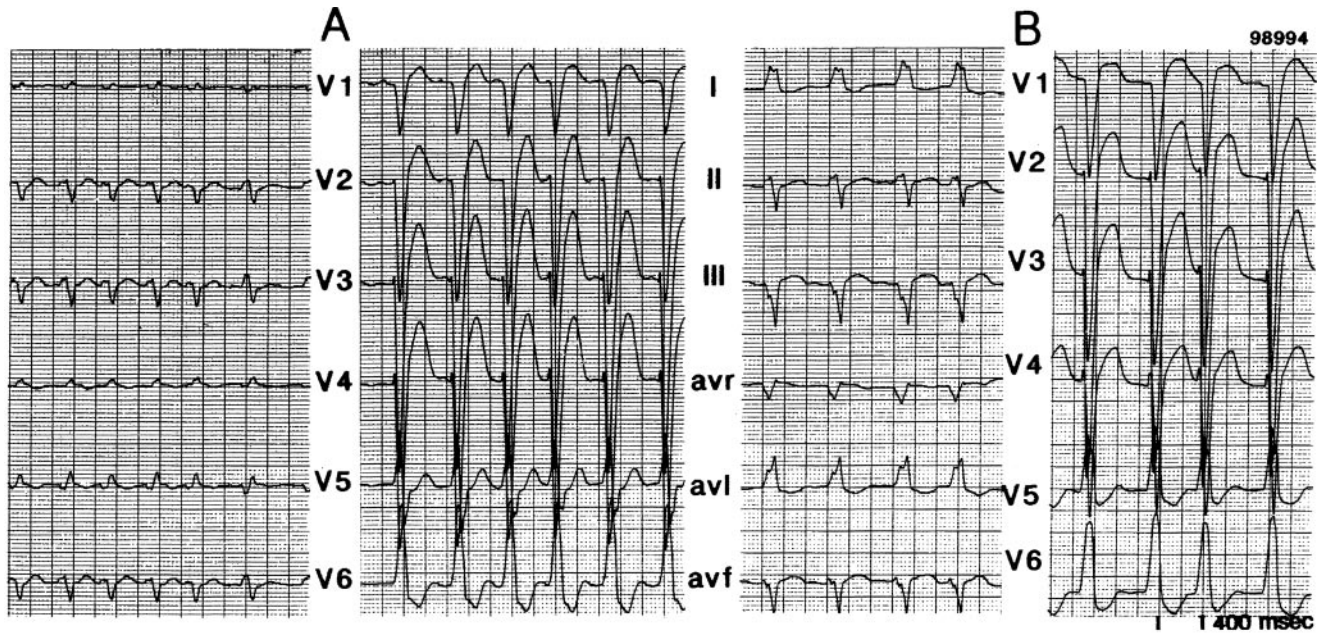
The opinions expressed in this article are not necessarily those of the editors or of the American Heart Association.

From the Cardiovascular Research Institute Maastricht (CARIM) (H.J.J.W.), and the Department of Cardiology, Academic Hospital Maastricht (A.P.G.), Maastricht, the Netherlands.

Correspondence to Hein J.J. Wellens, MD, 21, Henric van Veldekeplein, 6211 TG Maastricht, The Netherlands. E-mail hwellens@xs4all.nl (*Circulation*. 2004;109:562-564.)

© 2004 American Heart Association, Inc.

Circulation is available at <http://www.circulationaha.org>
DOI: 10.1161/01.CIR.0000117293.30403.8F



The patient was a 67-year-old woman with severe heart failure. Panel A (ECG on admission) shows atrial fibrillation with a ventricular rate of approximately 130 bpm. Left bundle-branch block (LBBB) is present with a QRS width of 180 ms, indicating additional causes for QRS widening other than LBBB alone, such as ventricular dilatation, hypertrophy, or scarring, alone or in combination. There is a marked discrepancy in voltage between the extremity (low voltage) and precordial (high voltage) leads. As described by Brody,²⁸ the decreased voltage in the bipolar limb leads is the result of an increased intracardiac blood pool, which is present between the two leads. In contrast, the precordial unipolar leads record the voltage of the tissue under the electrode. Presence of biventricular enlargement is supported by the frontal QRS axis of -90° , indicating delayed activation of the base and outflow tract of the right and left ventricle after ventricular activation starting in the apex of the right ventricle. Panel B (2 days later, after a fluid loss of 10 L) shows 2 important changes: (1) marked diminution of the voltage difference between extremity and precordial leads and (2) a shift of the frontal QRS axis to -30° . These changes indicate a marked decrease in intracardiac volume, especially of the right ventricle.

present in relation to the macroreentry circuit, which is being used during the arrhythmia.¹⁵ In atrial fibrillation, fascinating information has become available that points to the role of focal ectopic rhythms initiating a paroxysm of the arrhythmia.¹⁶ Often, these foci are located in muscle sleeves in or around cardiac vessels, which are connected with atrial tissue. They are most commonly found in or around the pulmonary veins but may also be present in the superior caval vein, the vein of Marshall, or the coronary sinus.^{16,17}

In ventricular tachycardia (VT), the ability to diagnose the site of origin on the ECG is dependent on the extent and location of additional cardiac damage. That means that in hearts with scars, such as those seen after a myocardial infarction, only gross localization is possible. In anterior wall myocardial infarction, this is more difficult than in inferoposterior myocardial infarction.¹⁸ Several factors play a role in the QRS configuration of a VT due to a myocardial infarction: the size of infarction, the site from within the infarct where the VT arises, propagation out of the infarct, and participation of the Purkinje system in global ventricular activation. In addition, other factors may be operating, like fibrosis of nonischemic origin, hypertrophy, ventricular geometry (aneurysm), and metabolic factors. Origin localization using the 12-lead ECG is easier in idiopathic VT. Both right and left ventricular idiopathic VTs have characteristic ECG patterns.¹⁹ Recently, it has become clear that the VT may originate in muscle sleeves around the root of the aorta and pulmonary artery.^{20,21}

In those patients, ectopic impulses can be conducted over the muscle bundle from the cardiac vessel to ventricular muscle. Identification of such a mechanism is of importance when catheter ablation of the arrhythmia has to be performed.

3. Heart Failure

The number of patients with heart failure is steadily increasing. The ECG in these patients may give important information in relation to prognosis and therapy. This holds for markers such as sinus tachycardia, atrial fibrillation, ventricular arrhythmias, number of leads showing QR or QS complexes, the width of the QRS complex, and a prolonged QTc interval.²² As early as 1988, Wilensky et al²³ indicated that QRS width is a useful predictor of outcome in patients with heart failure.

More recently, the QRS width, especially in patients with left bundle-branch block, has been used to select patients possibly profiting from resynchronization of ventricular activation by left ventricular pacing with or without synchronized right ventricular pacing.²⁴

Often both risk estimation and response to therapy can be derived from ECGs recorded during treatment of heart failure (Figure).

4. Genetic Arrhythmology

Our present ability to make a genetic diagnosis in patients who have certain electrocardiographic features has opened new ways to use the ECG for diagnosis, risk stratification,

Familial Diseases With a Monogenetic Basis for Cardiac Arrhythmias and Sudden Death

Hypertrophic cardiomyopathy
 Dilated cardiomyopathy
 Long-QT syndrome
 Short-QT syndrome
 Brugada syndrome
 Catecholaminergic polymorphic ventricular tachycardia
 Arrhythmogenic right ventricular dysplasia
 Wolff-Parkinson-White syndrome
 Atrial fibrillation
 Sick sinus syndrome
 Atrioventricular block
 Myotonic dystrophy

and management of carriers of monogenic diseases prone to cardiac arrhythmias and/or sudden death (Table).

The challenge will be to find out how specific and sensitive the ECG is in monogenic arrhythmic diseases. At present, the impression is that specificity may be high but sensitivity low because of marked differences in phenotypic expression.²⁵ Large databases are required to obtain that information. The experience in the long-QT syndrome and the Brugada syndrome indicates that the ECG is helpful in making decisions about management.^{26,27}

Conclusions

In recent years, important new information resulted from careful analysis of the ECG in patients with ischemic and nonischemic heart disease. The trend toward increasing specialization in cardiology threatens the implementation of this new ECG knowledge in the daily practice of the cardiologist.

It remains essential, therefore, to stress that both old and new ECG knowledge should be in the core curriculum of every cardiologist, not only during his or her training, but especially also during postgraduate education.

References

1. Einthoven W. Galvanometrische registratie van het menselijk electrocardiogram. In: *Herinneringsbundel Prof. S.S. Rosenstern* [Galvanometric registration of the human electrogram]. Leiden, the Netherlands: Eduard Ijdo; 1902;101–106.
2. Schalij MJ, Janse MJ, Van Oosterom A, et al, eds. *Einthoven 2002: 100 Years of Electrocardiography*. Leiden, the Netherlands: The Einthoven Foundation Publishers; 2002.
3. Fisch C. The clinical electrocardiogram: a classic. *Circulation*. 1989; 62(suppl III):III-1–III-4.
4. Wellens HJJ. The electrocardiogram 80 years after Einthoven. *J Am Coll Cardiol*. 1986;7:484–491.
5. Foerster JM, Vera Z, Janzen DA, et al. Evaluation of precordial orthogonal vector cardiographic lead ST-segment magnitude in the assessment of myocardial ischemia injury. *Circulation*. 1977;55: 728–735.
6. Sclarovsky S. *Electrocardiography of Acute Myocardial Syndromes*. London, UK: Martin Duntz, Ltd; 1999.

7. Wellens HJJ, Gorgels APM, Doevendans PA. *The ECG in Acute Myocardial Infarction and Unstable Angina: Diagnosis and Risk Stratification*. Boston, Mass: Kluwer Academic Publishers; 2003.
8. Gorgels APM, Vos MA, Mulleneers R, et al. Value of the electrocardiogram in diagnosing the number of severely narrowed coronary arteries in rest angina pectoris. *Am J Cardiol*. 1993;72:999–1003.
9. Holmvang L, Clemmensen P, Lindahl B, et al. Quantitative analysis of the admission electrocardiogram identifies patients with unstable coronary artery disease who benefit most from early invasive treatment. *J Am Coll Cardiol*. 2003;41:905–915.
10. De Lemos JA, Braunwald E. ST segment resolution as a tool for assessing the efficacy of reperfusion therapy. *J Am Coll Cardiol*. 2001;38: 1283–1294.
11. Gorgels AP, Vos MA, Letsch IS, et al. Usefulness of the accelerated idioventricular rhythm as a marker for myocardial necrosis and reperfusion during thrombolytic therapy in acute myocardial infarction. *Am J Cardiol*. 1988;61:231–235.
12. Engelen DJ, Gressin V, Krucoff MW, et al. Usefulness of frequent arrhythmias after epicardial recanalization in anterior wall acute myocardial infarction as a marker of cellular injury leading to poor recovery of left ventricular function. *Am J Cardiol*. 2003;92:1143–1149.
13. Wehrens XH, Doevendans PA, Oude Ophuis TJ, et al. A comparison of electrocardiographic changes during reperfusion of acute myocardial infarction by thrombolysis or PTCA. *Am Heart J*. 2000;139:430–436.
14. Wellens HJJ, Conover MB. *The ECG in Emergency Decision-Making*. Philadelphia, Pa: W.B. Saunders; 1992.
15. Bochoeyer A, Yang Y, Cheng J, et al. Surface electrocardiographic characteristics of right and left atrial flutter. *Circulation*. 2003;108: 60–66.
16. Haissaguere M, Jais P, Shaw DC, et al. Spontaneous initiation of atrial fibrillation by ectopic beats originating in the pulmonary veins. *N Engl J Med*. 1998;339:659–666.
17. Lin WS, Tai CH, Hsieh MH, et al. Catheter ablation of paroxysmal atrial fibrillation initiated by non-pulmonary vein ectopy. *Circulation*. 2003; 107:3176–3183.
18. Josephson ME. *Clinical Cardiac Electrophysiology: Techniques and Interpretations*. 3rd ed. Philadelphia, Pa: Lippincott Williams & Wilkins; 2001.
19. Wellens HJJ. Ventricular tachycardia: diagnosis of broad QRS complex tachycardia. *Heart*. 2001;86:579–585.
20. Ouyang F, Fotuhi P, Ho SY, et al. Repetitive monomorphic ventricular tachycardia originating from the aortic sinus cusp. *J Am Coll Cardiol*. 2002;39:500–508.
21. Timmermans C, Rodriguez L-M, Crijns HJGM, et al. Idiopathic left bundle-branch block-shaped ventricular tachycardia may originate above the pulmonary valve. *Circulation*. 2003;108:1960–1967.
22. Vrtvec B, Reynolds D, Zewail A, et al. Prolonged QTc interval and high B-type natriuretic peptide levels together predict mortality in patients with advanced heart failure. *Circulation*. 2003;107:1764–1769.
23. Wilensky RL, Yudelman P, Cohen AJ, et al. Serial electrocardiographic changes in idiopathic dilated cardiomyopathy confirmed at necropsy. *Am J Cardiol*. 1988;62:276–283.
24. Bradley DJ, Bradley EA, Baughman KL, et al. Cardiac resynchronization and death from progressive heart failure: a meta-analysis of randomized controlled trials. *JAMA*. 2003;289:730–740.
25. Roden DM. The problem, challenge and opportunity of genetic heterogeneity in monogenic diseases predisposing to sudden death. *J Am Coll Cardiol*. 2002;40:357–359.
26. Priori SG, Schwartz PJ, Napolitano C, et al. Risk stratification in the long QT syndrome. *N Engl J Med*. 2003;348:1866–1874.
27. Brugada J, Brugada R, Brugada P. Determinants of sudden cardiac death in individuals with the electrocardiographic pattern of Brugada syndrome and no previous cardiac arrest. *Circulation*. 2003;108:3092–3096.
28. Brody DA. A theoretical analysis of intracavitary blood mass influence on the electrocardiogram. *Circ Res*. 1956;4:731–738.

KEY WORDS: Focused Perspectives ■ electrocardiography ■ arrhythmia ■ coronary disease