

### Acknowledgment

We thank Drs. Henry McIntosh, Virendra Mathur, Robert Luchi, Alfredo Montero, Kinsman Wright and Mark Entman for advice, suggestions, and help in carrying this study, and Mrs. Charlotte Rogers for secretarial assistance.

### References

- Fortuin NJ, Friesinger GC: Exercise-induced S-T segment elevation: Clinical, electrocardiographic and arteriographic studies in twelve patients. *Am J Med* 49: 459, 1970
- MacAlpin RN, Kattus AA, Alvaro AB: Angina pectoris at rest with preservation of exercise capacity: Prinzmetal's variant angina. *Circulation* 47: 946, 1973
- Gorlin R, Klein MD, Sullivan JM: Prospective correlative study of ventricular aneurysm: Mechanistic concept and clinical recognition. *Am J Med* 42: 512, 1967
- Bruce RA, Gey GO Jr, Cooper MN, Fisher LD, Peterson DR: Seattle heart watch: Initial clinical, circulatory and electrocardiographic responses to maximal exercise. *Am J Cardiol* 33: 459, 1974
- Bruce RA, Hornsten TR: Exercise stress testing in evaluation of patients with ischemic heart disease. *Prog Cardiovasc Dis* 11: 371, 1969
- Rosenberg B, Messinger WJ: The electrocardiogram in ventricular aneurysm. *Am Heart J* 37: 267, 1949
- Ford RV, Levine HD: The electrocardiographic clue to ventricular aneurysm. *Ann Intern Med* 34: 998, 1951
- Douglas AH, Sferrazza J, Marici F: Natural history of aneurysm of ventricle. *NY State J Med* 62: 209, 1962
- Bruce RA, Fisher LD, Cooper MN, Gey GO: Separation of effects of cardiovascular disease and age on ventricular function with maximal exercise. *Am J Cardiol* 34: 757, 1974
- Master AM, Rosenfeld I: Two-step exercise test: Current status after twenty-five years. *Mod Concepts Cardiovasc Dis* 36: 19, 1967
- Redwood DR, Epstein SE: Uses and limitations of stress testing in the evaluation of ischemic heart disease. *Circulation* 46: 1115, 1972
- Kroop IG, Jaffe HL, Master AM: The significance of RS-T elevation in acute coronary insufficiency. *Bull NY Acad Med* 25: 465, 1949
- Manvi KN, Ellestad MH: Elevated ST segments with exercise in ventricular aneurysm. *J Electrocardiol* 5: 317, 1972
- Kemp GL: Value of treadmill stress testing in variant angina pectoris. *Am J Cardiol* 30: 781, 1972
- Hegge FN, Tuna N, Burchell HB: Coronary arteriographic findings in patients with axis shifts or S-T-segment elevations on exercise-stress testing. *Am Heart J* 86: 603, 1973
- Groden BM, James WB: Significance of persistent R-ST elevation after acute myocardial infarction. *Br Heart J* 31: 34, 1969

## Correlation of Pathologic Q Waves on the Standard Electrocardiogram and the Epicardial Electrogram of the Human Heart

MONTY M. BODENHEIMER, M.D., VIDYA S. BANKA, M.D.,  
ROBERT G. TROUT, M.D., HOMAYOON PASDAR, M.D.,  
AND RICHARD H. HELFANT, M.D.

**SUMMARY** To evaluate the relationship between abnormal Q waves on the standard ECG and localized ventricular excitation, unipolar epicardial electrograms were recorded over the left ventricle during aortocoronary bypass surgery in 36 patients. Of 20 without standard ECG Q waves, six had abnormal epicardial Q waves, three anteriorly and three inferiorly. Of 16 patients with standard ECG Q waves, four had both precordial and anterior epicardial Q waves while seven had Q waves in leads III and aV<sub>r</sub> and inferior epicardial Q

waves. Three of the 14 had Q waves in both precordial and inferior leads of the ECG but epicardial Q waves only from the antero-apical region in two and only from the inferior wall in one. Two patients with Q waves in both III and aV<sub>r</sub> had no epicardial Q waves. Thus, the standard electrocardiogram underestimates epicardial Q waves. If Q waves are present in the standard ECG, they correlate with the presence, although not invariably the location of Q waves on the epicardial electrogram.

ALTHOUGH PATHOLOGIC STUDIES HAVE INDICATED that a correlation exists between pathologic Q waves on the standard ECG and myocardial fibrosis, these fibrotic areas frequently do not correspond either to presence of Q waves or to the predicted site.<sup>1</sup> Recently, ventriculographic studies in living man have indicated that the presence of standard electrocardiographic Q waves correlate closely with the presence of ventricular asynergy.<sup>2,3</sup> However, although quite specific, standard electrocardi-

ogram Q waves were insensitive predictors since they were absent in approximately half of the patients with asynergic zones demonstrated ventriculographically.<sup>3</sup> These findings appeared related primarily to severity since more marked degrees of asynergy were usually associated with Q waves. In addition, the location of asynergy was an important factor in that inferior wall Q waves were both less sensitive and less specific than anterior wall Q waves.<sup>2,3</sup>

Kaiser et al. have demonstrated that intraoperative epicardial electrograms are useful in delineating zones of myocardial fibrosis.<sup>4</sup> To better define the relationship between the presence or absence of Q waves on the standard electrocardiogram and the underlying localized ventricular excitation characteristics of the left ventricular myocardium, intraoperative epicardial electrograms were obtained in 36 patients undergoing surgery for coronary artery disease and these recordings correlated with the standard ECG Q waves.

From the Division of Cardiology, Department of Medicine, and Department of Thoracic and Cardiovascular Surgery, Presbyterian-University of Pennsylvania Medical Center, Philadelphia, Pennsylvania.

Supported in part by a grant from the American Heart Association, Southeastern Pennsylvania Chapter.

Address for reprints: Richard H. Helfant, M.D., Chief, Division of Cardiology, Presbyterian-University of Pennsylvania Medical Center, 51 North 39th Street, Philadelphia, Pennsylvania 19104.

Received January 12, 1976; revision accepted March 4, 1976.

## Methods

Thirty-six patients with significant ( $\geq 75\%$ ) obstruction of one or more major coronary arteries undergoing open heart surgery (saphenous vein bypass graft and/or ventricular aneurysmectomy) form the basis of this study. Preoperative electrocardiograms were obtained on the day prior to surgery on standard electrocardiogram machines with frequency limits of 0.1 to 100 Hz and recorded at 25 mm/sec at a sensitivity of 1 mV = 10 mm.

Cardiac catheterization was performed in all patients.<sup>5</sup> Following recording of intracardiac pressures, determination of cardiac output (dye dilution method using indocyanine green) was performed. Left ventriculography was then performed in the 30° right anterior oblique projection using an injection of 30–40 cc of meglumine diatrizoate (Renografin-76) injected into the left ventricle followed by selective cine coronary arteriograms using either Sones' or Judkins' technique.

Epicardial electrograms were obtained prior to or immediately after the institution of cardiopulmonary bypass and prior to elective ventricular fibrillation.<sup>4</sup> Unipolar electrograms were obtained using three silver electrodes mounted 2 mm apart in acrylic plastic in the shape of an equilateral triangle and recorded between 0.1 to 100 Hz on a Grass model 7B polygraph at 25, 50, and 100 mm/sec paper speeds. A flat probe on a flexible handle was utilized to facilitate recordings from the posterior surface of the left ventricle.<sup>4</sup>

Epicardial electrograms were recorded from multiple sites beginning over the right ventricle and then sequentially from the region next to the ventricular septum, antero-apical, lateral wall and the inferior aspect of the left ventricle. The antero-apical area was taken as the zone between the anterior interventricular groove and a line 4–5 cm parallel and lateral to it extending up to the apex. The inferior area was taken as the epicardial surface bounded by the atrio-ventricular groove, the posterior interventricular groove and a line 3–4 cm parallel and lateral to it, extending up to the inferior aspect of the apex. The apex was further defined as the distal one-third of the left ventricle. The lateral wall was defined as the area between the anterior and inferior areas. An average of six sites was recorded from each area. All recordings were obtained during sinus rhythm.

Standard electrocardiograms were analyzed for the presence of abnormal Q waves ( $\geq 0.04$  second) in all leads (except aVR). These were then characterized as reflecting the inferior (II, III, aVF), anterior (V<sub>1</sub>–V<sub>4</sub>) or lateral (I, aVL, V<sub>5</sub>–V<sub>6</sub>) wall of the left ventricle.<sup>6</sup> If Q waves were seen in leads representative of two "walls" of standard electrocardiographic leads held to be representative of two walls of the left ventricle, then abnormalities were considered to exist in both areas.

Severity of asynergy during ventriculography was classified as hypokinesis (decreased contraction; < 25% hemiaxis shortening), akinesis (absence of contraction; 0–5% hemiaxis shortening) and dyskinesis (paradoxical systolic expansion; hemiaxis lengthening).<sup>3, 5</sup>

Epicardial electrograms were analyzed for the presence and duration of Q waves. Previous studies have indicated that Q waves are normally absent over the left ventricle immediately lateral to the septum and that Q waves of  $\leq 0.01$

second in duration are occasionally seen over the anterior free wall and initial Q waves of  $\leq 0.03$  second are seen inferiorly.<sup>7, 8</sup> Thus, anterior Q waves of  $\geq 0.03$  second and inferior Q waves of  $\geq 0.04$  second were considered abnormal. In addition, electrogram sites over each area were recorded in order to determine distribution and frequency of initial R and Q waves, so defining the boundaries and homogeneity of a specific zone.

The presence and distribution of standard electrocardiogram Q waves ( $\geq 0.04$  second) were then correlated with the presence or absence of abnormal Q waves in leads from the epicardial surface. In addition, the distribution of Q waves on the standard electrocardiogram was correlated with their epicardial location.

Statistical analysis was performed as follows:<sup>9</sup> 1) The predictive value of standard electrocardiogram Q waves was derived from the relationship between the number of patients with Q's on both standard ECG and epicardium to the total number of patients with surface Q waves; 2) The predictive value of absence of standard electrocardiogram Q waves was defined as the number of patients without Q's on either standard ECG or epicardium to the total number of patients without surface Q waves; 3) The efficiency of standard electrocardiogram Q waves was defined as the number of patients correctly diagnosed to the total number of patients.

## Results

### Predictive Value of Standard ECG Q Waves

Of the 36 patients, 16 had Q waves in the standard electrocardiogram. Fourteen of the 16 patients also had abnormal epicardial Q waves (table 1). In contrast, of 20 patients without standard electrocardiogram Q waves, 14 had normal epicardial recordings and of these only three demonstrated asynergy (two anterior hypokinesis and one inferior akinesis). Six demonstrated epicardial Q waves over at least one area (table 1). Of the six, three patients had Q waves over the antero-apical portion of the left ventricle, two anteriorly and one apically (fig. 1). All three manifested significant obstruction of the left anterior descending artery with anterior hypokinesis in one and apical dyskinesis in one. In three additional patients, pathologic epicardial Q waves were noted over the inferior portion of the left ventricle (fig. 2). All three had significant right coronary artery lesions. Two patients had apical akinesis and one anterior and inferior hypokinesis.

The predictive value of standard electrocardiogram Q waves compared to epicardial Q waves was 87% while the predictive value of their absence was only 70%. Efficiency of

TABLE 1. Two by Two Contingency Table of Standard ECG and Epicardial Q Waves

Standard ECG	Epicardial Leads	
	Q	no Q
Q	14 (12)	2 (1)
no Q	6 (5)	14 (3)

( ) indicates number with abnormal ventriculogram.

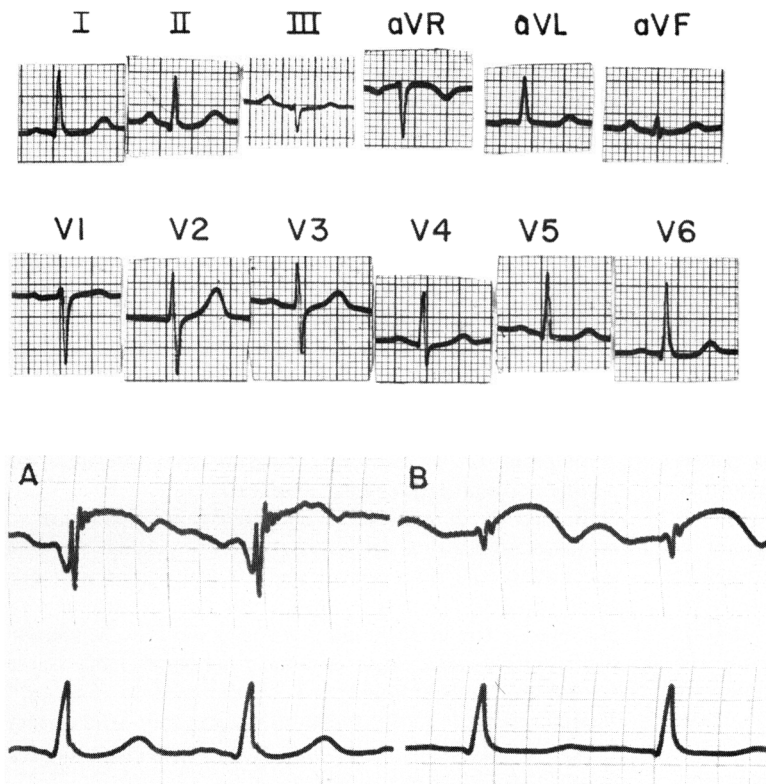


FIGURE 1. Top two panels) Standard ECG (25 mm/sec) shows normal precordial R wave progression. Third panel) Epicardial Q waves (0.04 sec) were recorded from a 2 cm area of the apex (A) with a small initial R wave (B) recorded lateral to this area. Bottom panel presents corresponding surface lead II. All standard ECG recordings are at 25 mm/sec and epicardial electrograms at 50 mm/sec.

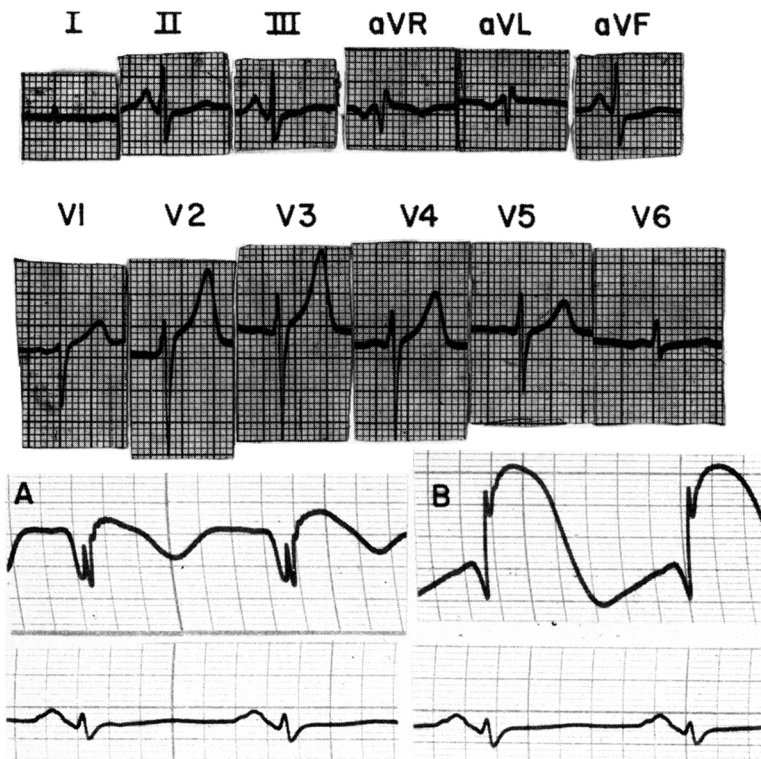


FIGURE 2. Epicardial recordings from the inferior surface demonstrate pathologic Q waves (A, B) in the absence of abnormal standard ECG Q waves. Panels represent the same leads as in figure 1.

electrocardiogram Q waves relative to epicardial recordings was 78%.

#### Site of Origin of Standard ECG Q Waves

There were 14 patients with both epicardial and standard electrocardiogram Q waves. Of four with anterior Q waves on standard electrocardiography and corresponding anterior epicardial Q waves, all had antero-apical asynergy (three dyskinetic and one akinetic) (fig. 3). Of seven patients with inferior Q waves on both standard ECG and epicardial recordings (fig. 4), five had inferior akinesis, while two had normally contracting left ventricles, despite significant obstructive lesions of the right coronary artery and left circumflex artery in both patients. Of the two patients with standard electrocardiogram Q waves in the inferior leads without epicardial Q waves, one had inferior akinesis and an isolated right coronary artery lesion, while one had a normal left ventriculogram with obstructive lesions in the right coronary artery and left anterior descending artery (fig. 5).

Three of the 14 patients had Q waves in both anteriorly and inferiorly oriented leads of the standard electrocardiogram. One patient with asynergy of both anterior and inferior walls of the left ventricle had Q waves both in leads III and aV<sub>F</sub> and in V<sub>1</sub>-V<sub>3</sub>. However, Q waves were seen only in epicardial leads from the inferior wall of the left ventricle and not in leads recorded adjacent to the septum over the anterior left ventricle (fig. 6). Two of the three patients who had Q waves in conventional leads of both inferior and anterior orientation had epicardial Q waves only over the

anterior and apical regions; initial R waves were recorded in epicardial leads from the inferior surface. Both patients had large antero-apical dyskinetic segments with normally contracting inferior areas.

#### Discussion

The present study reveals that 87% of patients who had abnormal Q waves in the standard electrocardiogram also had Q waves in leads recorded directly from the left ventricular epicardium. However, in six patients where Q waves were present in epicardial leads, no such waves were present on the electrocardiogram from precordial zones overlying portions of the left ventricle supplied by a significantly obstructed coronary artery. These observations of the specificity but relative insensitivity of standard electrocardiogram Q waves are consistent with previous experimental and pathological observations.

Studies on animals have indicated that production of localized myocardial necrosis or scar comprising less than one half of the thickness of the left ventricular wall can result in a Q wave in a lead from the epicardium.<sup>10, 11</sup> However, Cook et al. found that for Q waves to be seen on the standard electrocardiogram, more than half of the transmural myocardium must be replaced by fibrosis.<sup>12</sup> Therefore, less loss of transmural myocardium is necessary for Q waves to occur on the epicardial electrogram than on the standard electrocardiogram.

Overall, there was a good correlation between the site of Q waves on the standard electrocardiogram and the epicar-

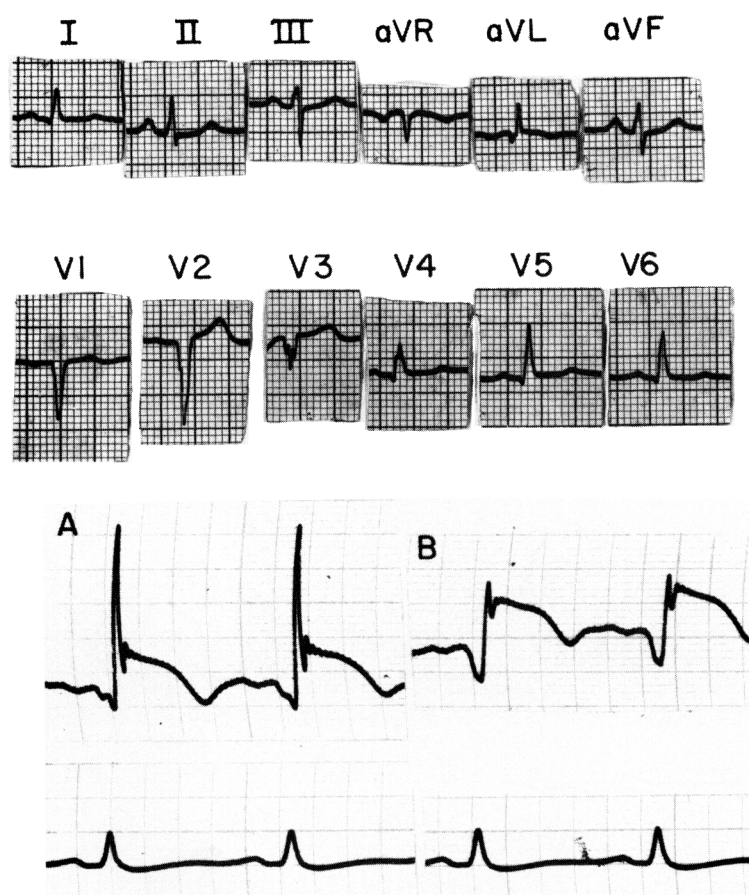


FIGURE 3. Standard ECG shows a QS from V<sub>1</sub>-V<sub>3</sub> with a 0.04 sec Q wave recorded from the anterior left ventricular wall (A, B). Bottom panel is surface lead II.

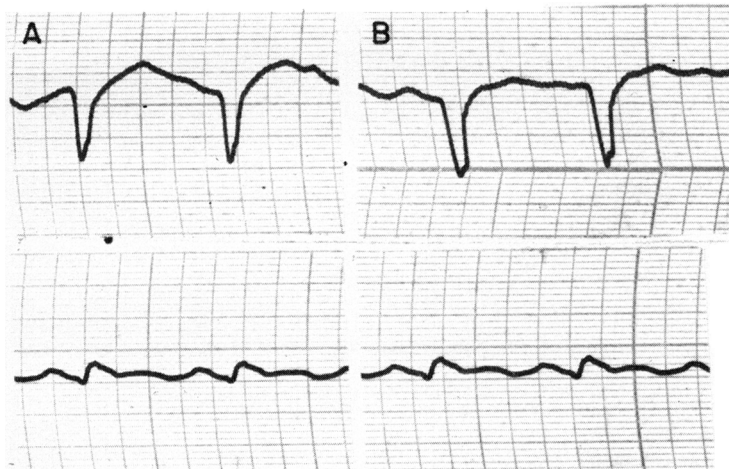
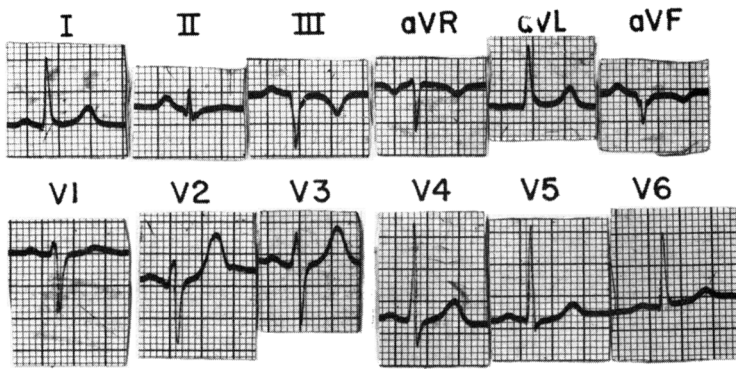


FIGURE 4. Standard ECG demonstrates a QS in III and aV<sub>F</sub> with a QS recorded over the inferior epicardial surface (A, B). Recordings from leads defined in figure 1.

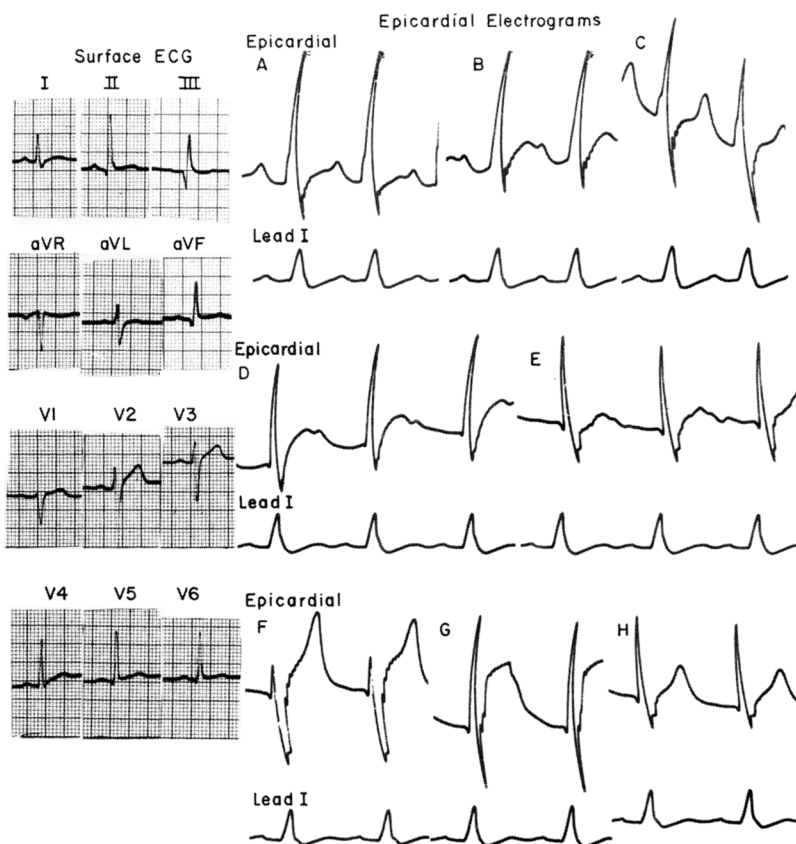


FIGURE 5. Standard ECG revealed pathologic Q waves (0.04 sec) in III and aV<sub>F</sub>. Epicardial recordings revealed initial R waves from the anterior (A, B), apical (C), lateral (D, E) and inferior surfaces (F, G, H). The initial 0.01 second Q waves in E-H are within normal range for these zones.

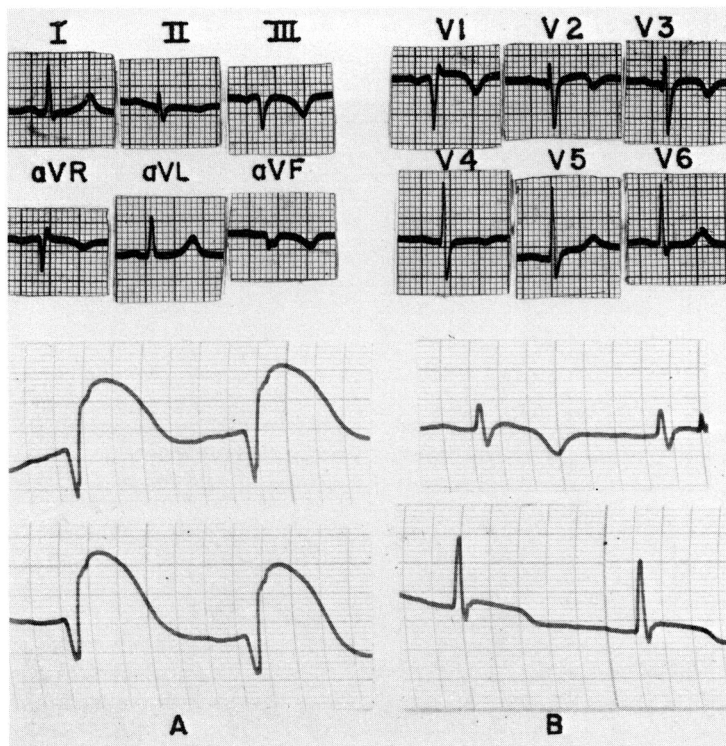


FIGURE 6. Standard ECG reveals a QS in III and aVF with a QR in V<sub>1</sub> and Q waves in V<sub>2</sub>-V<sub>3</sub> prior to the transition zone. Epicardial electrograms from the inferior surface demonstrated a QS (A); however, initial R waves (B) were recorded from the anterior left ventricle adjacent to the interventricular septum.

dial electrograms. Of 14 patients with epicardial Q waves, seven exhibited anterior and four inferior localizations on both epicardial and standard electrocardiogram recordings. However, standard electrocardiographic evidence of Q waves was found to be absent in several patients who had other and substantial evidence of myocardial scarring or injury, especially when the area of change was in the apical segment of the left ventricle.

In two patients with Q waves in both anterior and inferior leads of the standard electrocardiogram, epicardial Q waves were recorded only over the anterior epicardial surface. In a detailed pathologic study, Myers et al. found that zones of infarction confined to the apex of the left ventricle were in most cases associated with Q waves in the inferior leads of the standard electrocardiogram.<sup>13</sup> This finding is supported by results of the present study and suggests that such inferior lead Q waves seen on the standard electrocardiogram are the result of apical infarcted areas. Moreover, of the six patients in whom epicardial Q waves were found in the absence of standard electrocardiogram Q waves, three had localized apical asynergy on ventriculography. Thus, evidence from the standard electrocardiogram is misleading in certain patients with apical infarctions. In some instances it "overestimates" the area of the infarct while in others it fails to reveal the presence of a scar.

#### Acknowledgment

We wish to thank Mr. Joseph Lewandowski for his technical assistance and

Mrs. Linda Lightner and Ms. Regina Harrison for their secretarial assistance.

#### References

- Horan LG, Flowers NC, Johnson JC: Significance of the diagnostic Q wave of myocardial infarction. *Circulation* **43**: 428, 1971
- Williams RA, Cohn PF, Vokonas PS: Electrocardiographic, arteriographic and ventriculographic correlations in transmural myocardial infarction. *Am J Cardiol* **31**: 595, 1973
- Bodenheimer MM, Banka VS, Helfant RH: Q waves and ventricular asynergy: Predictive value and hemodynamic significance of anatomic localization. *Am J Cardiol* **35**: 615, 1975
- Kaiser GA, Waldo AL, Harris PD, Bowman FO, Hoffman BF, Malm JR: New method to delineate myocardial damage at surgery. *Circulation* **39**, **40** (suppl 1): I-83, 1969
- Helfant RH, Pine R, Meister SG, Feldman MS, Trout RG, Banka VS: Nitroglycerin to unmask reversible asynergy: Correlation with post coronary bypass ventriculography. *Circulation* **50**: 108, 1974
- Lipman BS, Massie E, Kleiger RE: *Clinical Scalar Electrocardiography*, ed 6. Chicago, Yearbook Medical Publishers, 1972
- Roos JP, Van Dam R, Durrer D: Epicardial and intramural excitation of normal heart in six patients 50 years of age and over. *Br Heart J* **30**: 630, 1968
- Daniel TM, Boineau JP, Cox JL, Sabiston DC: Mapping of epicardial and intramural activation of the heart. *J Thorac Cardiovasc Surg* **60**: 704, 1970
- Vecchio TJ: Predictive value of a single diagnostic test in unselected populations. *N Engl J Med* **274**: 1171, 1966
- Shaw CM, Goldman A, Kennamer R, Kimura N, Lindgren I, Maxwell MH, Prinzmetal M: Studies on the mechanism of ventricular activity. *Am J Med* **16**: 490, 1954
- Durrer D, Van Lier AAW, Buller J: Epicardial and intramural excitation in chronic myocardial infarction. *Am Heart J* **68**: 765, 1964
- Cook RW, Edwards JE, Pruitt RD: Electrocardiographic changes in acute subendocardial infarction. *Circulation* **18**: 603, 1958
- Myers GB, Klein HA, Hirtzka T: Correlation of electrocardiographic and pathologic findings in anteroposterior infarction. *Am Heart J* **37**: 205, 1948