

3. Hackel DB, Estes EH, Walston A, Koff S, Day E: Some problems concerning coronary artery occlusion and acute myocardial infarction. *Circulation* **39** & **40** (suppl IV): IV-31, 1969
4. Kravis TC, Shibel EM, Brooks JD, Moser KM: Incorporation of radio-labelled fibrinogen into venous thrombi induced in dogs. *Circulation* **49**: 158, 1974
5. Coleman RE, Harwig SSL, Harwig JF, Siegel BA, Welch MJ: Fibrinogen uptake of thrombi: Effect of thrombus age. *J Nucl Med* **16**: 370, 1975
6. Erhardt LR, Lundman T, Mellstedt H: Incorporation of ^{125}I -labelled fibrinogen into coronary arterial thrombi in acute myocardial infarction in man. *Lancet* **1**: 7800, 1973
7. Moschos CB, Oldewurtel HA, Lahiri K, Manskopf G, Regan TJ: Incorporation of ^{125}I -fibrinogen in a coronary artery thrombus detected in vivo with a scintillation camera. *Cardiovasc Res* **8**: 715, 1974
8. Coleman RE, Harwig SSL, Harwig JF, Sherman LA, Welch MJ: Radioiodinated soluble canine fibrin. Preparation and evaluation as a thrombus localizing agent in the dog. *Circ Res* **37**: 35, 1975
9. Salazar AE: Experimental myocardial infarction. Induction of coronary thrombosis in the intact closed-chest dog. *Circ Res* **9**: 1351, 1961
10. Moschos CB, Lahiri K, Peter A, Jesrani MU, Regan TJ: Effect of aspirin upon experimental coronary and non-coronary thrombosis and arrhythmia. *Am Heart J* **84**: 525, 1972
11. Weisse AB, Moschos CB, Passannante AJ, Khan MI, Regan TJ: Relative effectiveness of three antiarrhythmic agents in the treatment of ventricular arrhythmias in experimental acute myocardial ischemia. *Am Heart J* **81**: 503, 1971
12. Chandler AB, Chapman I, Erhardt LR, Roberts WC, Schwartz CJ, Sinapius D, Spain DM, Sherry S, Ness PM, Simon TL: Coronary thrombosis in myocardial infarction. *Am J Cardiol* **34**: 823, 1974
13. Chandler AB: The anatomy of a thrombus. In: *Thrombosis*, edited by Sherry S. Washington, D.C., National Academy of Sciences, 1969, p 279
14. Jorgensen L, Rowsell HC, Hovig T, Mustard JF: Resolution and organization of platelet-rich mural thrombi in carotid arteries of swine. *Am J Pathol* **51**: 681, 1967

Noninvasive Assessment of Mitral Insufficiency by Transcutaneous Doppler Ultrasound

PETER M. NICHOL, M.D., DEREK R. BOUGHNER, M.D., PH.D., AND JOAN A. PERSAUD

SUMMARY Instantaneous aortic arch blood velocity was recorded transcutaneously from the suprasternal notch, using a 2.2 MHz Doppler ultrasound unit, in 18 normals and 16 patients undergoing cardiac catheterization who had murmurs of mitral regurgitation. In normals aortic blood velocity rose rapidly in early systole to a midsystolic peak then fell to zero velocity. These roughly parabolic patterns had area ratios beneath the first and second halves of the curves measuring $52:48 \pm 3$ (SD). With increasingly severe

mitral regurgitation the pattern became skewed leftward such that the percent in the first half of systole ranged from 53–79%. From the angiograms of our sixteen patients an estimate of true percent regurgitation was made using the Fick cardiac output and ventricular volume measurements. When compared with the area under the first half of the velocity curve a strong correlation was found ($r = 0.84$) indicating that this Doppler technique can be used to evaluate mitral insufficiency.

ABNORMAL AORTIC FLOW PATTERNS in mitral insufficiency have been demonstrated by several authors.^{1,2} The usefulness of these flow changes in assessing mitral regurgitation has not been fully evaluated since those flow studies were limited to small numbers of patients and selected situations, due to the complexity of the techniques used.

In their study, Elkins et al.¹ used an electromagnetic cuff type flowmeter to measure aortic blood flow in two groups with mitral regurgitation: nine dogs with surgically induced regurgitation, and five patients with severe mitral insufficiency, at the time of mitral valve replacement. In both situations the aortic flow pattern was altered, showing a proportionately greater flow in the first half of systole than normal. Kendall et al.² obtained similar results in five patients with mitral insufficiency using the pressure gradient technique.

A simple noninvasive technique, using transcutaneous Doppler ultrasound, has been described by Light³ and Joyner et al.⁴ for recording instantaneous aortic blood ve-

locity. This report illustrates the changes that can be recorded using that method in patients with mitral regurgitation and outlines the potential value of the technique in assessing the severity of the mitral valve lesion.

Method

Aortic blood velocity patterns were obtained using a battery operated 2.2 MHz directional Doppler ultrasound unit. The ultrasound probe was a 13 mm diameter lead zirconate-lead titanate piezoceramic disc cut in two and mounted in the "double D" configuration. The two elements (transmitter-receiver) were set to focus at a depth of 10 cm, at which point the beam width was approximately 13 mm high by 7 mm wide (manufacturer's specifications). The acoustic power output was 10 mW/cm². The system was a zero crossing unit with an adjustable Schmidt trigger level to a minimum of 10 mV and had a noise figure of approximately 6 decibels. To eliminate the low frequency components of the returning signal (i.e., the heart sounds) a filter was installed which produced a band width of 300 Hz to 3.0 kHz at -3 decibels. This meant that the unit was sensitive to velocities from about 5 cm/sec to 100 cm/sec.

Each study was done with the patient supine and the transducer hand held in the suprasternal notch. When aimed downward and posteriorly toward the tip of the left scapula the beam crossed the descending aortic arch at an angle approximately parallel to blood flow (fig. 1).⁵ In this area of the arch the transluminal velocity profile was relatively flat, i.e.,

From the Cardiac Investigation Unit, Department of Medicine, University Hospital and the Department of Biophysics, University of Western Ontario, London, Ontario, Canada.

Supported by a grant from the Ontario Heart Foundation. Dr. Boughner is an Ontario Heart Foundation Senior Research Fellow.

Address for reprints: Dr. Derek Boughner, Cardiac Investigation Unit, University Hospital, P. O. Box 5339, Terminal A, London, Ontario, Canada N6A 5A5.

Received November 6, 1975; revision accepted May 4, 1976.

differed very little across the lumen, so that the velocity reading obtained approximated the overall velocity of the stroke volume.^{5,6} Since the Doppler frequency shift, and therefore the estimated blood velocity, obtained depended upon the cosine of the angle of incidence of the beam with the flowing blood, an angle of 20° from parallel produced an error of only $\pm 5\%$ in the instantaneous peak velocity reading.

In each case the beam was rotated until peak velocity away from the transducer was obtained. Simultaneous systolic flow toward the transducer was encountered in most patients and represented flow up the carotid vessels lying in the path of the beam. Subclavian artery flow was readily obtained away from the transducer by aiming the beam beneath either clavicle. The peak Doppler frequency shift obtained (i.e., the estimated peak instantaneous blood velocity) was displayed in three forms: 1) the Doppler frequency shift produced by the flowing blood was made audible via stereophonic earphones, with velocities away from and toward the transducer on separate channels; 2) the instantaneous peak velocity obtained away from and toward the transducer was indicated on two calibrated meters on the face of the equipment; 3) an output from the Doppler unit was connected directly to a Litton chart recorder such that peak "away" velocity was plotted upright and "toward" velocity inverted.

The calibration was performed using an oscillator contained within the equipment. When activated this produced a signal equivalent to a frequency shift representing 50 cm/sec. The electrocardiogram, phonocardiogram (recorded from the left sternal border, fourth interspace) and the carotid pulse tracing were recorded simultaneously with the velocity tracing at paper speeds of 50 mm/sec and 250 mm/sec.

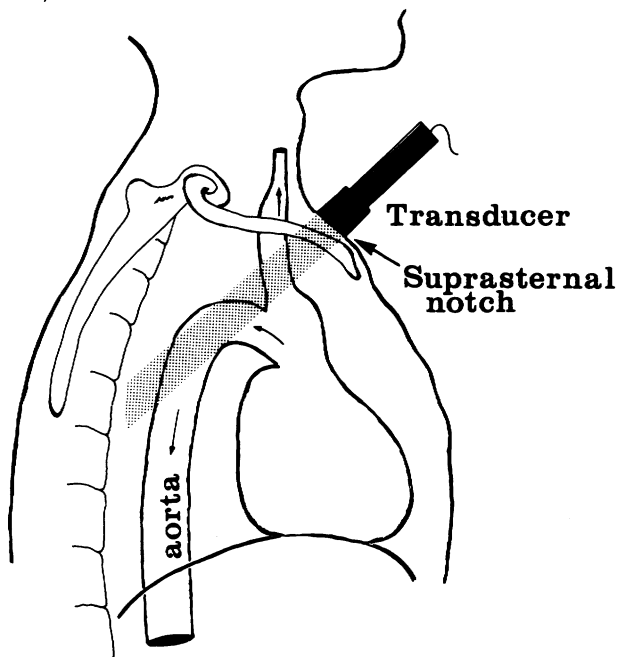


FIGURE 1. Line drawing illustrating the transducer positioned in the suprasternal notch so that the ultrasound beam crosses the descending aortic arch approximately parallel to blood flow. Aortic blood velocity is away from the transducer in this area while flow in neck vessels is toward the transducer.

In order to establish the normal aortic velocity pattern the aortic velocity tracing was recorded by the above technique in 18 individuals, 12 male and 6 female, ranging in age from 14 to 63 years. Of this group 16 had no signs or symptoms of cardiac disease. Two patients underwent catheterization for investigation of chest pain, and both were found to have mitral valve prolapse with no evidence of mitral regurgitation. The normal aortic velocity pattern (fig. 2) proved to be an essentially parabolic waveform onsetting ± 20 msec from the beginning of the carotid pulse upstroke, with a rapid rise to peak velocity. The fall to zero velocity occurred rapidly near the end of systole with the base line being reached at the dicrotic notch of the carotid pulse. A small amount of reversed flow was frequently seen at the beginning of diastole. This diastolic reversed flow was occasionally obscured by venous flow, presumably from the innominate vein.

As with other Doppler techniques, venous flow can usually be differentiated from arterial flow by the sound. The Doppler frequency shift, produced by the blood flow and made audible in the earphones, had a more prolonged rushing quality for veins while for arteries the sound was sharper and more distinct. If the ultrasound beam crossed two vessels simultaneously and if the flow in each was in the same direction relative to the transducer, the equipment simply recorded the peak velocity present overall. No indication was given which vessel that peak velocity was being recorded from, other than by differences in the timing of the flow, i.e., venous flow could overlap both systole and diastole while aortic did not.

In each case the recorded systolic velocity tracings for ten beats were divided in half; using a planimeter, the areas in the first and second halves of systole were measured. These

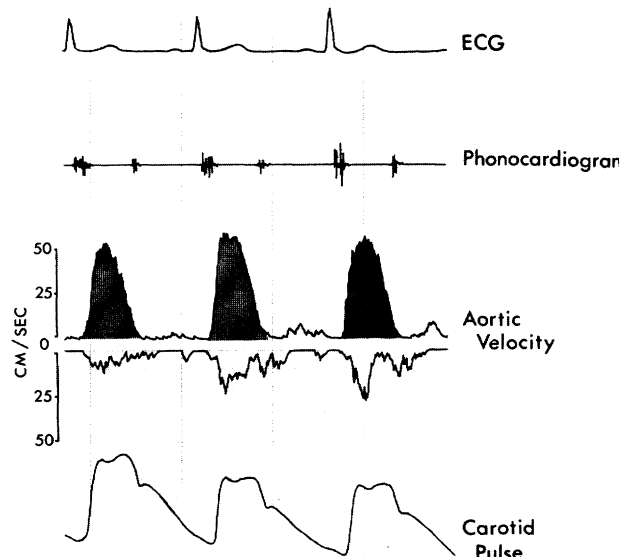


FIGURE 2. Instantaneous aortic blood velocity recording from a normal 32-year-old male. Indicated blood velocity in the aortic arch, away from the transducer, is plotted upright (shaded areas) showing a rapid rise to peak velocity with a rapid fall to baseline late in systole. Velocity toward the transducer, plotted inverted (unshaded), is from other vessels lying in the path of the ultrasound beam — likely carotid or innominate arteries in systole and innominate vein in diastole. Electrocardiogram, phonocardiogram and carotid pulse tracings are recorded simultaneously.

two measurements represented the proportion of the total stroke volume being ejected in either half of systole.

A second group of patients was then studied. This consisted of 16 consecutive patients undergoing cardiac catheterization with clinical findings of mitral regurgitation (10 male, 6 female, age range 21–68 years). Patients with additional valvular abnormalities were excluded. Following cardiac catheterization, the left ventricular cineangiograms for each patient, recorded in the right anterior oblique projection, were analyzed. The end-systolic and end-diastolic frames were selected by referring to a simultaneously recorded electrocardiogram on which the exposures of the angiograms had been marked automatically. Care was taken to avoid extrasystolic and postextrasystolic beats. These two frames were then projected and traced, the areas and long axis were measured manually with a planimeter and ruler and finally the corrected ventricular volumes at end systole and end diastole were calculated using the single plane technique outlined by Dodge.⁷ The stroke volume was thus obtained as the difference between the two volumes and when multiplied by the heart rate gave left ventricular output, i.e., the volume being ejected both into the aorta and into the left atrium. The Fick cardiac output was measured by the rebreathing technique prior to the angiogram and the difference between the two measurements of output provided a close approximation of the percent mitral regurgitation.

The aortic velocity tracing from these 18 patients was then recorded and analyzed as for the normal group above, with the ratio of flow in the two halves of systole being calculated.

In addition, the left ventricular angiograms were reviewed separately by a cardiovascular radiologist who was asked to assess the degree of mitral regurgitation and grade it on a scale of 0 (none), 1 (mild), 2 (moderate), 3 (moderately severe) and 4 (severe). This was essentially an estimate of the

regurgitation made from the degree of opacification of the left atrium, the apparent size of the left atrium and the number of cardiac cycles required for maximum opacification.

Results

In the 18 normal individuals the aortic velocity pattern was of an essentially parabolic shape with the area under the curve approximately equally divided between the first and second halves of systole. Planimetry of the two halves showed a slightly greater proportion of the stroke volume to be ejected in the first half of systole, mean $52 \pm 3\%$, than the second half.

For the 16 patients with murmurs of mitral insufficiency the area under the first half of the velocity curve was calculated and found to vary from 53% to 79% of the total area indicating, in all but two, that less of the stroke volume was being ejected in late systole than normal (table 1). These alterations in the velocity pattern were readily apparent on examining the velocity tracing, varying from mild (fig. 3) to marked (fig. 4) changes.

When the percent regurgitation calculated from the left ventricular angiograms was compared to the percent of the stroke volume ejected in the first half of systole a strong correlation was shown, figure 5 ($r = 0.84$).

Grading of the regurgitation by cineangiographic techniques (fig. 6) produced a much weaker correlation between the radiologist's impression of the degree of regurgitation and the calculated percent of regurgitation ($r = 0.47$). Patient 12, D.H., (table 1) is worthy of comment and illustrates the problems sometimes encountered with this

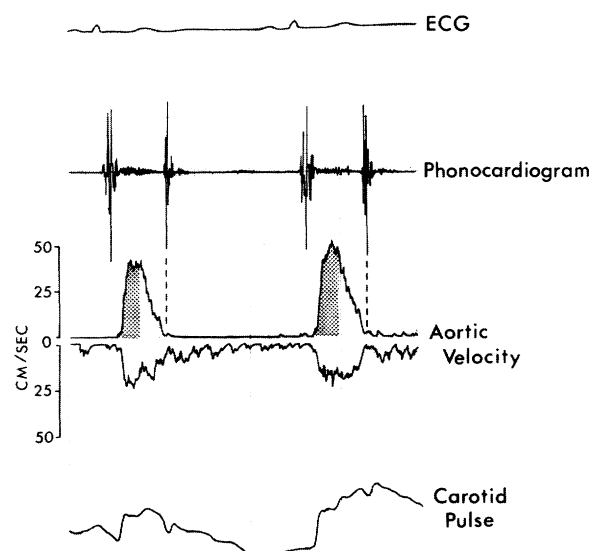


FIGURE 3. Aortic velocity tracing from a 55-year-old patient with moderate mitral regurgitation, calculated to be 39% from left ventricular angiograms and Fick cardiac output. There is a greater than normal proportion of flow occurring in early systole (shaded area) with the ratio of areas under the velocity curve in the two halves of systole being 66:34.

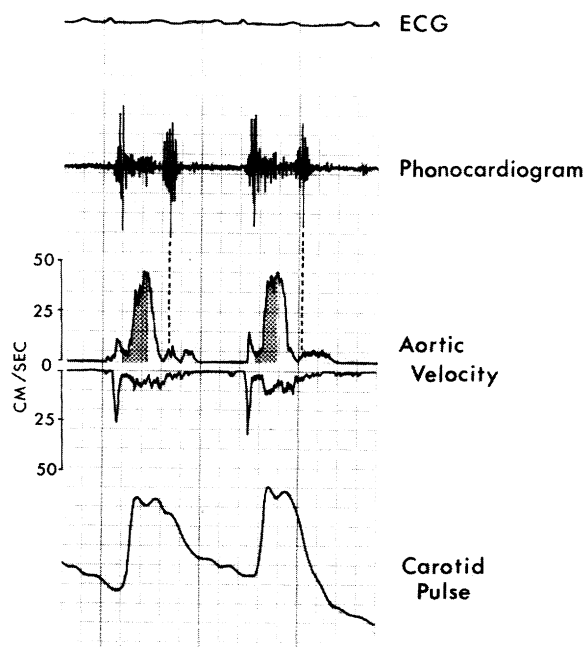


FIGURE 4. Aortic velocity tracing from a 64-year-old patient with moderately severe mitral regurgitation, calculated to be 53% from left ventricular angiograms and Fick cardiac output. There is a much greater than normal proportion of flow occurring in the first half of systole (shaded area) with the ratio of areas under the velocity curve in the two halves of systole being 73:27.

TABLE 1.

	Patient	Age	Diagnosis*	Angiographic % regurgitation	Doppler ratio†	Radiologic grading of regurgitation
1.	M.H.	44	Prolapse	2	61:39	0
2.	J.E.	41	Ischemic	4	53:47	0
3.	N.M.	53	Rheumatic	10	60:40	3
4.	M.B.	33	Vasculitis	14	53:47	0
5.	G.C.	48	Rheumatic	19	65:35	1
6.	A.G.	55	Prolapse	39	66:34	2
7.	R.L.	64	Ischemic	46	70:30	1
8.	C.J.	57	Ischemic	47	69:31	2
9.	R.B.	64	Rheumatic	53	73:27	2
10.	P.C.	55	Ruptured chordae	54	70:30	4
11.	H.F.	62	Ischemic	56	69:29	4
12.	D.H.	27	Prolapse	63	79:21	0
13.	B.T.	64	Prolapse	65	76:24	2
14.	H.J.	67	Rheumatic	67	70:30	1
15.	F.P.	68	Ischemic	69	70:30	3
16.	A.M.	43	Cardiomyopathy	73	71:29	3

*All patients clinically had an apical systolic murmur indicating the presence of mitral regurgitation. The etiology of the regurgitation as determined from the clinical findings and/or the angiogram is indicated.

†Ratio of areas under the aortic velocity curve in the first and second halves of systole, normal 52:48 \pm 3 (SD).

technique. A bout of ventricular tachycardia at the beginning of the left ventricular injection in conjunction with poor positioning of the fluoroscope led to the decision that, although contrast material did regurgitate into the left atrium, it did not represent significant mitral insufficiency. However, the pressure tracings indicated that this interpretation was incorrect and this was later supported by the volume measurements which were made using the second of two sinus beats.

Discussion

As early as 1921 an abnormal left ventricular ejection pattern was noted in the presence of severe mitral insufficiency.

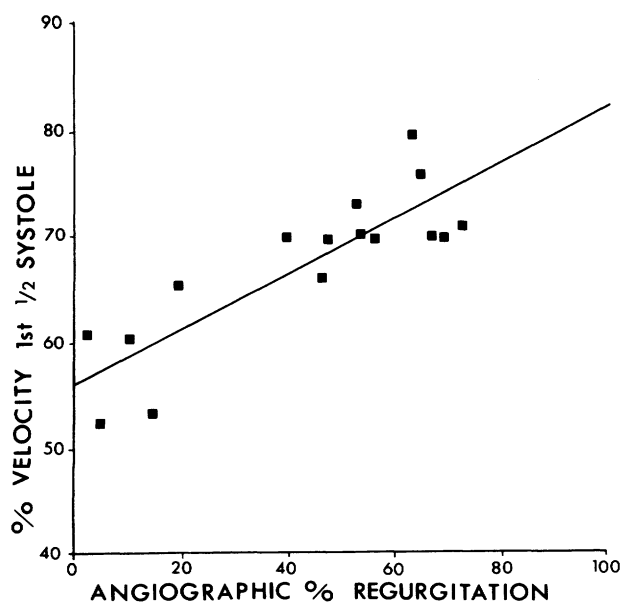


FIGURE 5. The percent regurgitation (calculated from angiographic left ventricular volume estimates and the Fick cardiac output) plotted against relative area under the first half of the systolic aortic velocity curve. With increasing regurgitation an increasing proportion of the stroke volume is ejected in the first half of systole and the velocity curve becomes skewed leftward ($r = 0.84$).

At that time, Wiggers and Feil⁸ noted that in dogs with experimentally produced mitral regurgitation there was an abnormally rapid decline in left ventricular pressure during ejection. Clinically it has been pointed out that the peripheral arterial pulses may sometimes be "water-hammer" in nature in patients with severe mitral insufficiency,⁹ and the aortic flow measurements of Elkins et al.¹ and Kendall et al.² showed the abnormal aortic flow patterns that may be encountered in such patients.

It is, therefore, not surprising that our Doppler aortic velocity patterns recorded in patients with mitral regurgitation frequently differed from normal. Since the Doppler technique used measured peak instantaneous velocity, the area under that velocity curve resulted in an approximation of the distance forward that the whole stroke volume moved

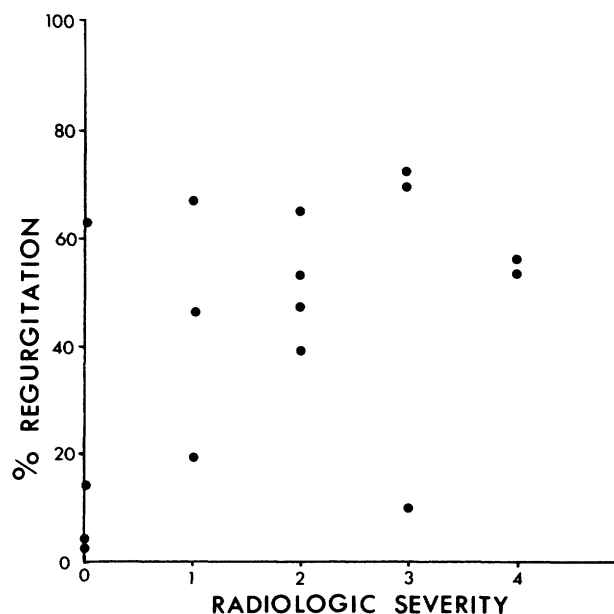


FIGURE 6. The percent mitral regurgitation plotted against the radiologic estimate of severity, i.e., degree and rate of left atrial opacification. A poor correlation is shown ($r = 0.47$).

(cm) not the stroke volume itself (cm^3), as obtained from flowmeters. It must be remembered that the accuracy of the peak velocity indicated by the Doppler unit was dependent on the angle of incidence of the ultrasound beam with the flowing blood. If the beam was not parallel to aortic arch blood flow then the indicated velocity was less than the true velocity. With angles of incidence less than 20° this error was small but above that it became increasingly significant. Since the technique was noninvasive it was impossible to determine this angle, so we could attach little significance to the actual relative velocity that we recorded. However, since we were dealing in ratios between first and second halves of systole, this was not of critical significance. We were still able to infer the proportions of the stroke volume ejected in the two halves of systole, assuming a constant aortic diameter throughout systole.

With increasingly severe regurgitation a rapid decline in left ventricular pressure can be present in late systole.⁹ Although the forward cardiac output may be normal, the left ventricular output may be greatly increased depending on the degree of regurgitation. It is the increased end-diastolic volume and the decreased late systolic pressure that have been suggested as the mechanism for changes in the aortic flow pattern.^{1, 10} As the myocardial fiber length decreased rapidly during ejection it has been postulated that this diminished shortening capacity in late systole resulted in a fall-off in the velocity of ejection, producing the changes in the aortic flow pattern seen.

Echocardiography has provided further indirect evidence of this change in the aortic flow pattern. With severe mitral regurgitation late systolic reclosure of the aortic valve has been noted.¹¹ This would be explained by the fall in late systolic flow found in such patients.

The amount of late systolic fall-off in aortic velocity appears useful in assessing the degree of mitral insufficiency.

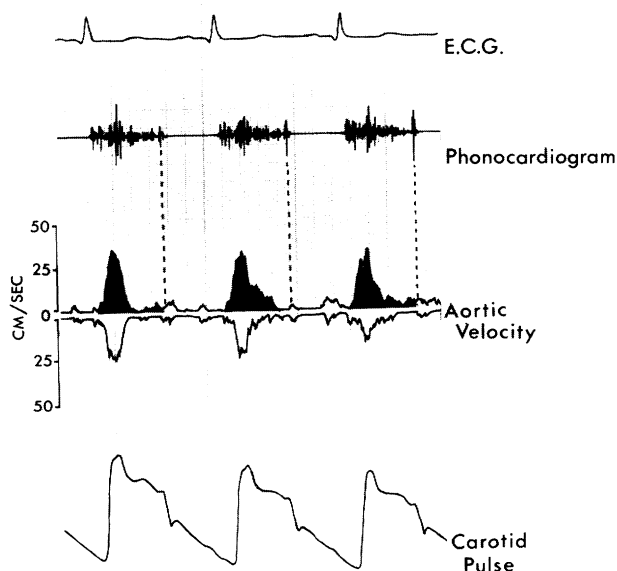


FIGURE 7. Aortic velocity tracing from a patient with idiopathic hypertrophic subaortic stenosis and a significant subaortic gradient. As obstruction developed in mid systole aortic arch blood velocity (shaded area) decreased sharply giving a pattern resembling severe mitral regurgitation.

As the proportion of stroke volume ejected in late systole falls, the proportion in early systole rises. By quantitating the amount of the shift (fig. 5) we were able to estimate the degree of mitral regurgitation. Although the correlation coefficient was good, there was considerable scatter about the regression line and we have found that, from a practical clinical standpoint, the technique provides all the information required by simply grading the regurgitation as mild, moderate or severe.

In our experience, the aortic velocity pattern can be obtained readily in over 90% of patients, and problems encountered are mainly in patients with emphysema where pulmonary tissue is interposed between the transducer and the descending arch of the aorta. Also since the beam is focused at 10 cm, very large patients or small children cannot be studied with this equipment. Transducers of different focal lengths would remedy this fault. The reason for selecting the descending aortic arch to study the aortic velocity is readily apparent. It is easy to localize, since the arch is the only major vessel in this area other than the left pulmonary artery with blood flow away from the transducer. The left pulmonary artery is apparently too distant from the suprasternal notch for recording and also tends to be hidden by the left atrium. Use of the ascending aortic arch velocity signal is impractical since this is difficult to differentiate from carotid or innominate artery flow. Since the latter two

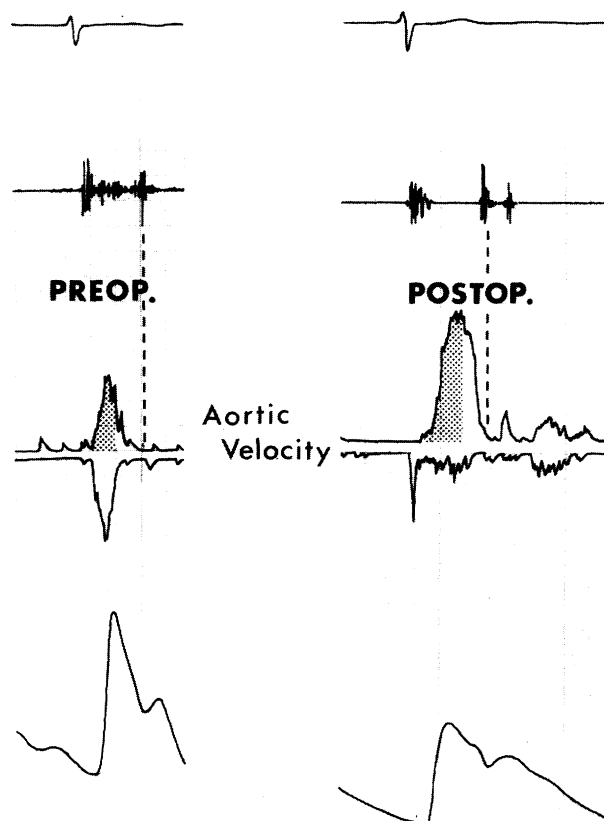


FIGURE 8. Left) Aortic velocity tracing from a patient with dehiscence of a prosthetic mitral valve resulting in severe regurgitation, 66% calculated at cardiac catheterization. There is a marked proportionate increase in flow in the first half of systole (shaded area). Right) Following replacement with a new prosthetic mitral valve, the aortic velocity tracing has returned to normal.

have blood velocity patterns that differ from aortic patterns, such "toward" signals are difficult to interpret.

Several situations can render this technique invalid for assessing mitral regurgitation. Since we depend upon a shift of aortic flow to early systole any situation that produces the reverse will interfere. The presence of significant aortic stenosis produces an unpredictable delay in the time to peak aortic velocity in the descending arch of the aorta.¹² Similarly, severe congestive heart failure will increase the time to peak velocity by decreasing the acceleration of blood from the left ventricle. In this situation, however, the peak velocity is frequently very low as well. Asymmetric septal hypertrophy with obstruction will often result in a pattern identical to that of severe mitral regurgitation (fig. 7). However, in this situation the abrupt fall in late systolic aortic velocity is due not to the presence of mitral regurgitation but to the development of outflow tract obstruction during ejection.^{13, 14} These disorders must, therefore, be ruled out before using the aortic velocity tracing to evaluate mitral regurgitation.

The assessment of prosthetic mitral valve function can be a situation in which the aortic velocity tracing is of considerable help. Patients with dehiscence and leak around a prosthetic mitral valve may have only a soft mid systolic murmur and can be difficult to assess clinically. Figure 8 (left) shows the aortic velocity tracing from such a patient with a Wada hinged disc prosthesis, congestive failure, and a low amplitude systolic murmur. The tracing indicates severe mitral insufficiency that was confirmed on the left ventricular angiogram with a calculated regurgitation of 66%. At operation, marked dehiscence of the valve was found and it was removed and replaced. The postoperative aortic blood velocity pattern then returned to normal (fig. 8 right).

Thus, our results with this transcutaneous Doppler technique not only confirm the previously reported abnormal-

ities of aortic blood flow in mitral insufficiency but indicate that the technique may be a useful method for assessing the severity of the regurgitation.

Acknowledgment

We wish to thank the Back Simpson Co. Ltd., London, Ontario for supplying the ultrasound unit and Mr. Victor Carriere for his technical advice. The continued interest and assistance of Dr. S. P. Ahuja, Dr. R.E. Gold and Dr. W. J. Kostuk is gratefully acknowledged.

References

1. Elkins RC, Morrow AG, Vasko JS, Braunwald E: The effects of mitral regurgitation on the pattern of instantaneous aortic blood flow. *Circulation* 36: 45, 1967
2. Kendall ME, Rembert JC, Greenfield JC: Pressure-flow studies in man: The nature of the aortic flow pattern in both valvular mitral insufficiency and the prolapsing mitral valve syndrome. *Am Heart J* 86: 359, 1973
3. Light LH: Non injurious ultrasonic technique for observing flow in the human aorta. *Nature* 224: 1119, 1969
4. Thompson PH, Mennel RG, MacVaugh H, Joyner CR: Evaluation of aortic insufficiency in humans with a transcutaneous Doppler velocity probe. (abstr) *Ann Intern Med* 72: 781, 1970
5. Seed WA, Wood NB: Velocity patterns in the aorta. *Cardiovasc Res* 5: 319, 1971
6. Schultz D: Pressure and flow in large arteries. In *Cardiovascular Fluid Dynamics*, vol 1, edited by Bergel DH. New York, Academic Press, 1972, p 287
7. Dodge HT: Determination of left ventricular volume and mass. *Radiol Clin North Am* 9: 459, 1971
8. Wiggers CH, Feil H: Cardiodynamics of mitral insufficiency. *Heart* 9: 141, 1921
9. Ross J Jr, Braunwald E, Morrow AG: Clinical and hemodynamic observations in pure mitral insufficiency. *Am J Cardiol* 2: 11, 1958
10. Braunwald E, Welch GH, Sarnoff SJ: Hemodynamic effects of quantitatively varied experimental mitral regurgitation. *Circ Res* 5: 539, 1957
11. Gramiak R: Echocardiography in acquired heart disease. In *Diagnostic Ultrasound*, edited by King DL. St. Louis, C.V. Mosby, 1974, p 105
12. Boughner DR: Assessment of aortic insufficiency by transcutaneous Doppler ultrasound. *Circulation* 52: 874, 1975
13. Hernandez RR, Greenfield JC, McCall BW: Pressure-flow studies in hypertrophic subaortic stenosis. *J Clin Invest* 43: 401, 1964
14. Boughner DR, Schuld RL, Persaud JA: Hypertrophic obstructive cardiomyopathy: Assessment by echocardiographic and Doppler ultrasound technique. *Br Heart J* 37: 917, 1975