

Detection of Myocardial Scar Tissue by M-Mode Echocardiography

SUSAN RASMUSSEN, R.N., M.S.N., BETTY C. CORYA, M.D.,
HARVEY FEIGENBAUM, M.D., AND SUZANNE B. KNOEBEL, M.D.

With technical assistance by Mary Jo Black, B.A.

SUMMARY Wall thicknesses were measured and echo densities were evaluated from the left ventricular echograms of 182 patients. The echogram was considered to reflect scar tissue when 1) either the interventricular septum, the posterior left ventricular wall or the anterior left ventricular wall was less than 7 mm thick in mid-diastole and was more echo-producing than its opposing wall or another area of the same wall in a sector scan, or 2) an area of myocardium was

30% less thick than an adjacent area within a sector scan.

Myocardial scarring was diagnosed by echocardiography in 52 of the 182 patients. The echocardiographic presence or absence of scarring was confirmed in 95% (173 of 182) of cases, 34 cases by microscopic examination and 139 by surgical appearance. This study shows that M-mode echocardiography is both a sensitive and specific method for detecting myocardial scar tissue.

RECENTLY WE DESCRIBED echograms in which the diastolic thickness of the interventricular septum was less than normal and more echo-producing than the opposing posterior wall.¹ When surgical or autopsy follow-up was available in those cases, septal scar tissue was found. On the basis of that work we defined myocardial scar as an area of left ventricular wall less than 7 mm in thickness and more echo-producing than other areas of myocardium in the same echogram. We also made an echocardiographic diagnosis of scar when an area of myocardium was 30% less thick than an adjacent area within a sector scan. The purpose of this study was to determine the sensitivity and specificity of these criteria in the detection of myocardial scar involving the interventricular septum, the posterior left ventricular wall, and the anterior left ventricular wall.

Materials and Methods

One hundred eighty-two patients were included in this study. Patients were selected as follows: 1) Daily logs of patient names from the echocardiographic and autopsy laboratories were reviewed in order to find cases in which a technically adequate echocardiographic examination was performed within two months of death. Fourteen cases were found. 2) Consecutive patients having an adequate echocardiographic study prior to surgery for coronary artery bypass grafting and/or ventricular resection were selected and included 168 cases. Four of these patients had postmortem examination. Seven cases were rejected due to inadequate echograms.

Echocardiograms

All echocardiograms were obtained using commercial echographs having repetition rates of 1000 pulses per second

and utilizing single element 2.25 MHz transducers, 12 or 13 mm in diameter and collimated to 7.5 cm. The echograms were recorded on Electronics for Medicine DR8, VR6, or Echo IV Multi-Channel strip chart recorders; or on a Honeywell 1856 fibroptic strip chart recorder. Prior to recording echoes, the slope of the time-gain-compensation (TGC) ramp was adjusted to insure that echoes from the interventricular septum and posterior left ventricular wall were influenced only by changes in the coarse gain. Sector scans of the left ventricle and linear scans of the anterior left ventricular wall (ALV) were obtained by previously described techniques^{2,3} and recordings were made from multiple intercostal spaces. For the purpose of this study, a technically adequate echocardiogram was defined as one from which both thickness and motion of the interventricular septum and posterior left ventricular wall were measurable in at least one sector scan recording.

Echocardiographic Measurements

All echocardiograms were interpreted without knowledge of clinical, angiographic, or pathological findings. Interventricular septal and posterior left ventricular wall measurements were taken at or just below the posterior mitral valve leaflet and at a more apical area just prior to where echoes from the posterior papillary muscle were recorded (fig. 1). Anterior left ventricular wall measurements could be made in 158 patients (87%). Left septal and posterior endocardial amplitudes of echocardiographic motion which occurred during ejection were measured. Thicknesses of the interventricular septum, posterior left ventricular wall and the anterior left ventricular wall were measured during mid diastole and at end systole (figs. 1, 2). Septal thickness was measured from the leading edge of the right septal echo to the leading edge of the left septal echo and posterior wall thickness was measured from the leading edge of the endocardial echo to the leading edge of the epicardial echo. Thickness of the anterior left ventricular wall was measured from the leading edge of the epicardial echo to the leading edge of the endocardial echo. Mid diastole was defined as the interval between completion of rapid ventricular filling and the onset of atrial filling. End systole was defined as the point in time

From the Krannert Institute of Cardiology, the Department of Medicine, Indiana University School of Medicine, and the Veterans Administration, Indianapolis, Indiana.

Supported in part by the Herman C. Krannert Fund, and by Grants HL-06308, HL-05363 and HL-07182 from the National Heart, Lung and Blood Institute, and the American Heart Association, Indiana Affiliate.

Address for reprints: Betty C. Corya, M.D., Indiana University School of Medicine, 1100 West Michigan Street, Indianapolis, Indiana 46202.

Received May 9, 1977; revision accepted September 2, 1977.

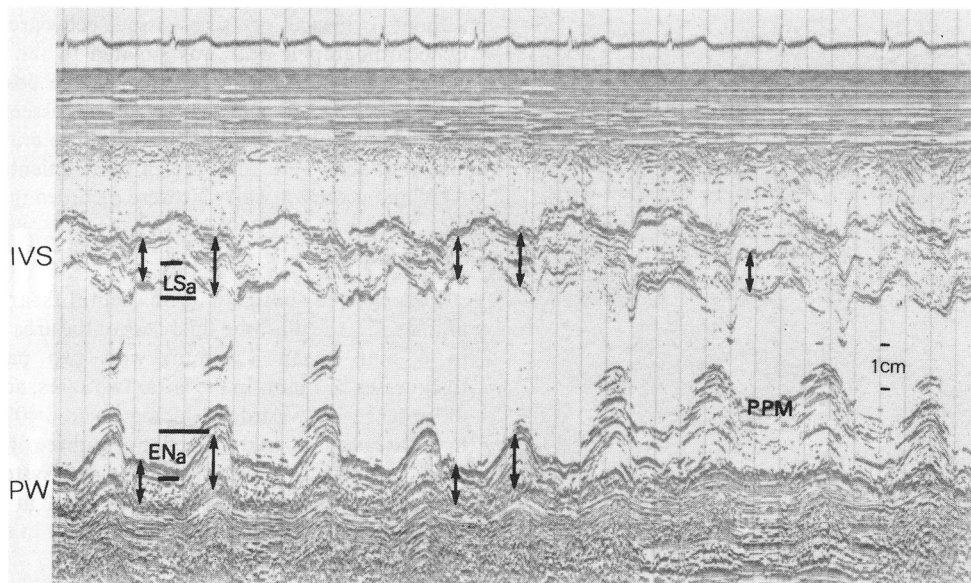


FIGURE 1. Normal left ventricular (LV) echogram obtained with sector scanning from an area where part of the mitral valve is present (on the left) to an area where echoes from the posterior papillary muscle (PPM) are recorded. Arrows indicate wall thicknesses. IVS = interventricular septum, PW = posterior LV wall, LSa = excursion of the left septal echo during ejection, ENa = amplitude of posterior endocardial echo during ejection.

when the shortest distance between the opposing left ventricular walls was reached.

Echocardiographic Scar Criteria

Myocardial scar was considered to be present when one of the following two criteria was met: 1) the myocardium measured less than 7 mm thick in mid diastole and was more echo-producing (increased density) than either its opposing wall or an adjacent area of the same wall in a sector scan; or 2) one area of myocardium was 30% less thick than an adjacent area within a sector scan.

Echocardiographic determination of left ventricular wall density was made by visual comparison of opposing and adjacent walls. In addition to appearing darker due to the in-

creased echo density, the scarred areas consisted of a thick band or multiple lines or bands of echoes rather than the speckled appearance of normal myocardium (fig. 3).

Pathology

Myocardial tissue was examined by two methodologies. In the case of autopsy (18 cases) or surgical resection (16 cases) tissue was examined grossly and microscopically. When tissue was not obtained for microscopic examination (148 cases) scar was defined at the time of surgery as a white, firm area of myocardium. For those patients in whom the heart was not opened at the time of surgery, the surgeon was not able to examine all areas of the myocardium. In such

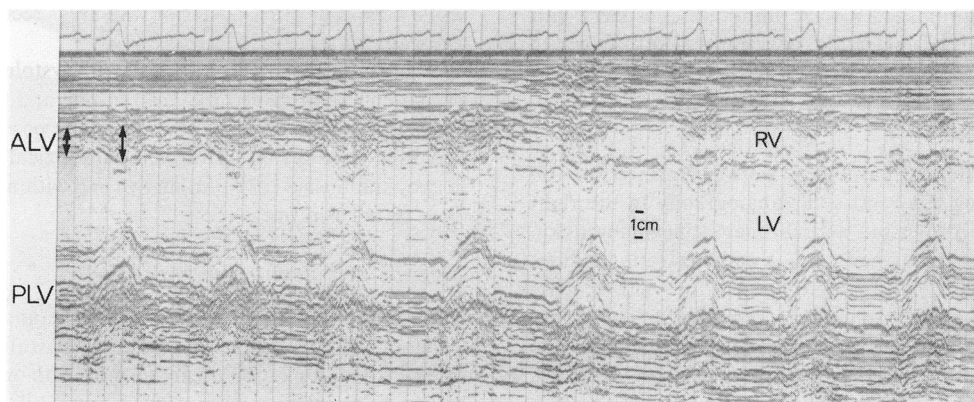


FIGURE 2. Normal anterior left ventricular wall (ALV) echogram and linear scan. Echoes from the ALV are shown on the left. With linear movement of the transducer to the parasternal region (on the right), echoes from the right ventricular wall, interventricular septum and posterior LV wall are recorded. RV = right ventricle, LV = left ventricle, PLV = posterior left ventricular wall.

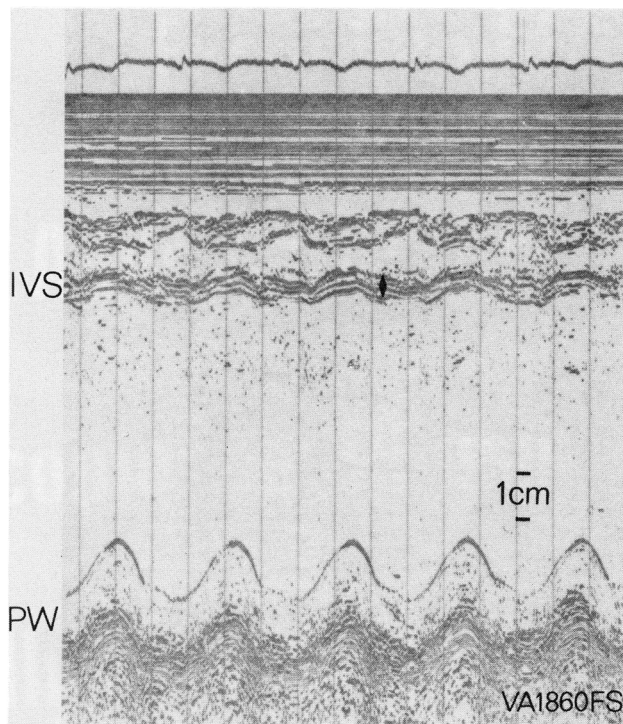


FIGURE 3. Left ventricular echogram from a patient with septal scarring. Echoes from the thin (5 mm) scarred interventricular septum (IVS) have a linear appearance and are more intense than those from the normal posterior wall (PW). Multiple fine echoes are evident within the LV cavity. Arrow indicates septal thickness.

cases, scar over the mid-ventral surface of the heart was interpreted as involving the interventricular septum.

Neither the pathologist nor the surgeon had prior knowledge of the echocardiographic findings.

Electrocardiograms

Standard electrocardiograms, recorded within 48 hours of the echocardiographic study, were analyzed and classified according to the criteria of Lipman et al.⁴ as being either normal; abnormal with nonspecific ST or T wave changes; abnormal with diminished R wave amplitude consistent with but not diagnostic of infarction; or abnormal with Q waves diagnostic of infarction.

Angiographic Studies

Cardiac catheterization studies were performed on 168 patients including left ventricular angiography in the right anterior oblique projection and coronary cineangiography. Two additional patients had cardiac catheterization studies including coronary cineangiography but not left ventriculography. A diagnosis of significant coronary artery disease was made when there was 50% or greater narrowing of one or more of the three major coronary arteries.

Results

Echocardiographic Findings

Myocardial scarring was diagnosed by echocardiography in 52 of the 182 patients. The remaining 130 patients were

without evidence of scar tissue echocardiographically. Echocardiographic scar was isolated to the septum in 28 patients; to the ALV in two; and to the posterior wall in three. Both septal and ALV scar were seen echocardiographically in 13 patients; septal and posterior left ventricular wall scar were recorded in four patients (fig. 4); and ALV and posterior wall scar were recorded in two patients.

Septal Scar

For the 45 patients with septal scar echocardiographically, the diastolic thickness of the area ranged from 2 to 8 mm (mean 4.6 mm) with two patients having thicknesses ≥ 7 mm. In the latter two cases, additional areas of septum were recorded which measured 40% thicker than in the areas considered scarred. Forty-three of the 45 scarred areas had absence of wall thickening with systole. Left septal motion during ejection was paradoxical in six of the 45 areas, absent in 23, diminished (< 3 mm) in seven and normal (3 – 9 mm) in nine.

The septal echoes indicated greater density in 41 of the 45 septal scar areas when compared to echoes from the opposing posterior wall or other septal areas seen in the sector scan. In 25 cases the septal scar area appeared to be comprised of relatively thick and dense linear echoes (fig. 3); and in 16 cases the septum appeared dense and filled solid with echoes (fig. 5). There were four instances in which septal areas were abnormally thin but without gross increase in echo density.

In 24 of the 45 patients, multiple fine echoes (fuzz) appeared just below the septum or apically within the left ventricular cavity (figs. 3 and 5).

Posterior Wall Scar

Nine patients had echocardiographic evidence of scarring of the posterior left ventricular wall (fig. 6) with diastolic thicknesses ranging from 5 to 8 mm (mean 6.4 mm) with two patients having thicknesses ≥ 7 mm. In the two cases where the thickness was ≥ 7 mm, additional areas of posterior wall measured more than 30% thicker than the areas considered to be scar. In all nine patients, echoes from the thinner areas of posterior wall appeared more dense when compared to septal echoes or other posterior wall areas recorded in a sector scan.

Thickening of the posterior wall with systole was absent in six patients, diminished ($< 21\%$) in one and within normal limits (21 – 92%) in two. Motion of the posterior wall endocardial echo during systole was paradoxical in one, absent in two, diminished (< 9 mm) in five and within normal limits (9 – 16 mm) in one.

Anterior Left Ventricular Wall Scar

Seventeen patients had scarring of the anterior left ventricular wall by echocardiography. Diastolic thicknesses ranged from 4 to 7 mm (mean 5.3 mm) with only one patient having a diastolic thickness of 7 mm. All 17 scar areas showed absence of systolic thickening. The motion during ejection was abnormal in all 17 with 12 being paradoxical and five without motion. Compared to the opposing posterior left ventricular wall, the ALV appeared dense with thick lines in 13 patients (fig. 7); only the ALV endocardial

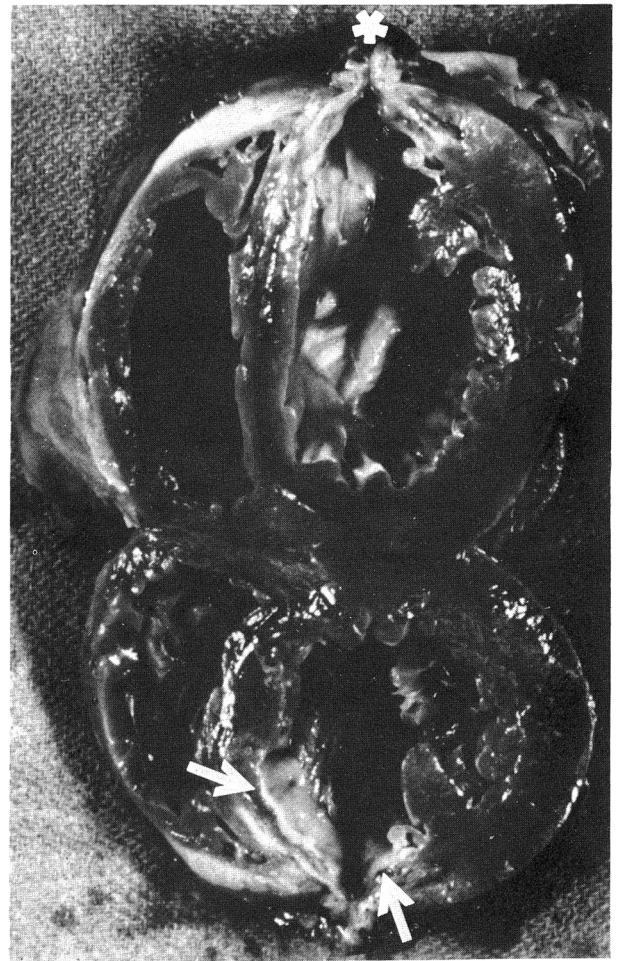
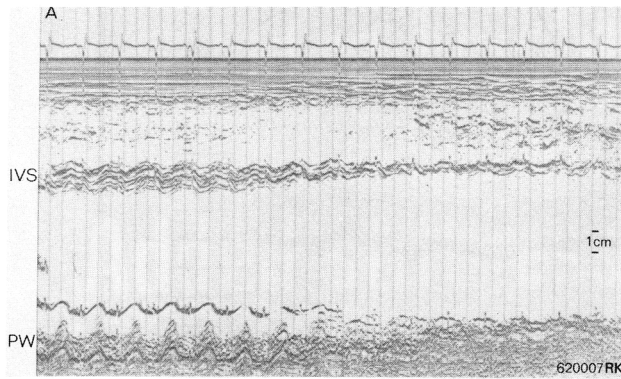


FIGURE 4. A) Left ventricular echogram showing a decrease in both septal and posterior wall thicknesses with sector scanning apically. B) Postmortem specimen from the patient whose echogram is shown in A. At autopsy an area of thin, scarred septum was present immediately adjacent to septal tissue of normal thickness as well as an area of scarred posterior wall apically. Arrows indicate scarred areas remaining following resection of a large ventricular aneurysm two days before. Following resection the remaining myocardium represented approximately 60% of the total left ventricular myocardial mass. The asterisk identifies the point at which the edges of the aneurysm were approximated.

echo was thick and dense in two patients; and in an additional two patients the ALV was denser than adjacent thicker ALV areas recorded. Five of the 17 patients had multiple fine echoes (fuzz) between the ALV and its opposing posterior wall.

Pathological Confirmation of Scar

Comparison of the echocardiographic diagnosis of myocardial scarring to the surgical and autopsy findings is shown in table 1. The specificity (percent of echocardiographic

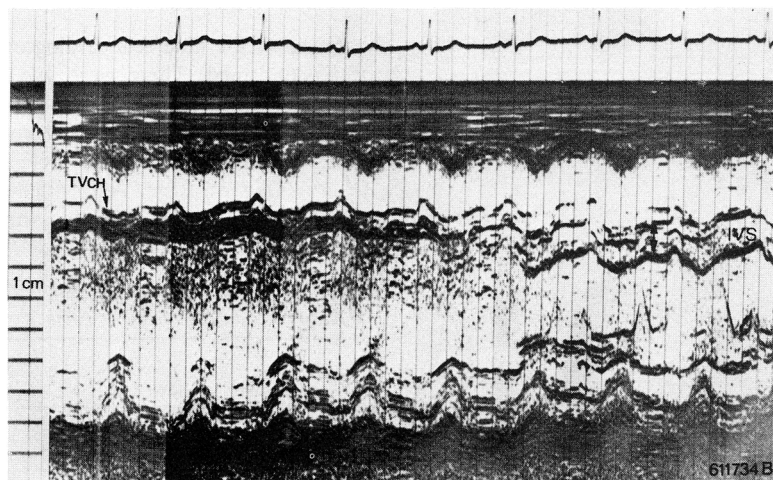


FIGURE 5. Left ventricular echogram recorded from an area near the base (on the right) to an area more apically shown on the left. Near the base, echoes from the interventricular septum (IVS) have a speckled appearance and the wall thickness measures 10 mm. With sector scanning, septal thickness progressively thinned to 3 mm and appeared dense and filled solid with echoes. Multiple fine echoes both below the septum and within the LV cavity are evident. Arrows indicate septal thickness. TVCh = tricuspid valve chorda.

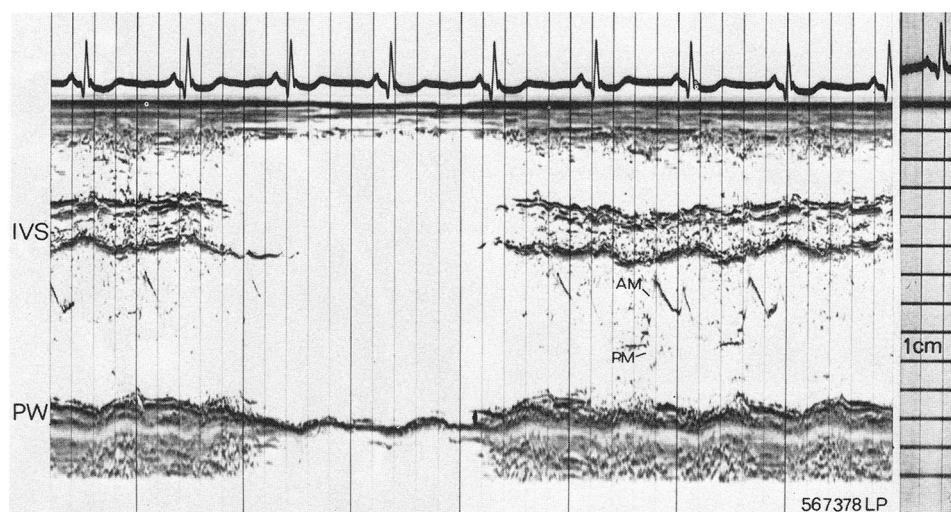


FIGURE 6. Abnormal echogram showing a thin (5 mm), scarred posterior wall (PW). IVS = interventricular septum, AM = anterior mitral valve leaflet, PM = posterior mitral valve leaflet.

graphic scars confirmed anatomically) of echocardiography in the diagnosis of scar tissue was 92% (48 of 52) and the sensitivity (percent of scars seen anatomically which were detected by echocardiography) was 91% (48 of 53). For the 34 cases in which autopsy or myocardial resection was performed, echocardiography reflected the anatomical findings in 100% of cases. For the remaining 148 cases in which the echograms were compared to surgical appearance, the echogram correctly predicted the presence or absence of scar tissue in 94% (139 of 148) of cases.

It was not possible to make precise comparisons of the

echocardiographic and anatomical findings due to difficulties in spatial orientation in M-mode echocardiography. Measurements of the thinnest areas of scar seen by both techniques were made in 10 patients. Measurements were identical in two patients. The scarred area was thinner at autopsy by 1 mm in five patients and by 2 mm in three patients. In no patient did the echocardiogram underestimate thickness.

Septal Scar

There was pathological confirmation of the echocardiographic diagnosis of septal scar in 43 of 45 cases. In one of the two patients in whom the surgical appearance failed to confirm the presence of septal scar, the electrocardiogram showed diagnostic Q waves of antero-septal infarction and the patient had a history of an anterior infarction six years prior to surgery.

Posterior Wall Scar

Seven of the nine echocardiographic posterior wall scars were confirmed. There were two echocardiographic false positives in which scarring was not seen at surgery. In each case there was angiographic evidence of extensive coronary artery disease including total occlusion of the right coronary artery. One of these two patients also had a clinically documented inferior infarction three months prior to the echocardiographic examination.

TABLE 1. Comparison of Echocardiographic Detection of Scar to Surgical and Autopsy Findings

Surgical and autopsy findings	Echocardiographic findings	
	Scar present (52 patients)	Scar absent (130 patients)
Scar present		
No. patients 53	48	5
Microscopically (29)	(29)	
Surgical appearance (24)	(19)	(5)
Scar absent		
No. patients 129	4	125
Microscopically (5)		(5)
Surgical appearance (124)	(4)	(120)

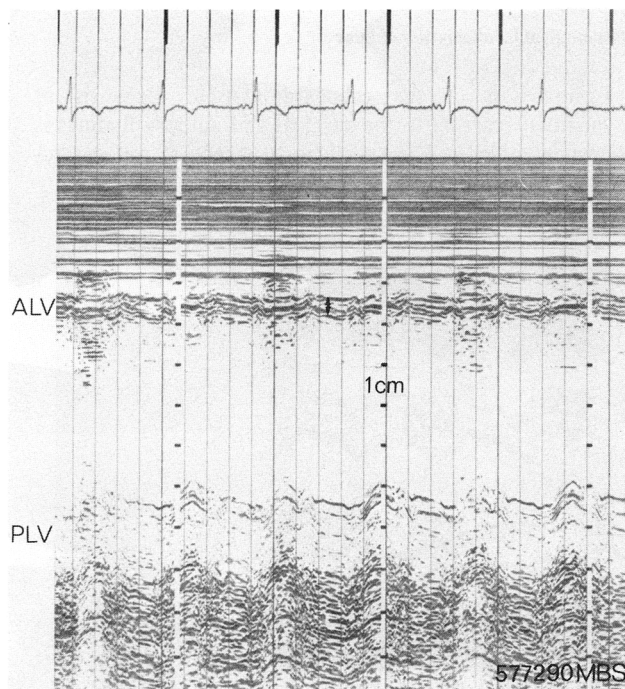


FIGURE 7. Abnormal echogram showing a thin (4 mm) scarred anterior left ventricular wall (ALV). Echoes from the scarred ALV have a linear appearance and are more intense compared to those from the posterior LV wall (PLV).

Anterior Left Ventricular Wall Scar

Sixteen of the 17 echocardiographic ALV scars were confirmed. There was one echocardiographic false positive. That patient had both a clinical history for and electrocardiographic Q waves of anterior infarction. However, no scarring was evident at surgery.

Echocardiographic False Negatives

There were no patients with pathological evidence of septal scarring and a normal septal echogram (false negative). All 43 patients with pathological evidence for scar tissue also had echocardiographic septal scarring. Three patients had posterior wall scarring present at surgery which was not detected by echocardiography. There were two patients with ALV scarring seen at surgery in whom the ALV echogram was technically inadequate.

Clinical, Electrocardiographic and Angiographic Findings

Forty-seven of the 52 patients (90%) with scar present echocardiographically had a clinical history of myocardial infarction. The electrocardiogram showed pathologic Q waves in 33 of the 52 (63%); diminished R waves consistent with but not diagnostic of prior infarction in nine (17%); nonspecific ST or T wave changes in eight (15%); and normal findings in two (4%). Fifty-one (98%) patients had angiographic or pathologic evidence of significant (> 50%) coronary artery obstruction. There was one patient with a well documented clinical history of anterior infarction in whom no significant coronary artery disease was evident angiographically.

Fifty-nine of the 130 patients (45%) without evidence of scar tissue echocardiographically had a clinical history of myocardial infarction. The electrocardiogram showed pathologic Q waves in 21 of the 130 (16%); diminished R waves consistent with but not diagnostic of prior infarction in 12 (9%); nonspecific ST or T wave changes in 22 (17%); and normal findings in 75 (58%). Significant coronary artery obstruction was evident by arteriography in 126 patients and at autopsy in two patients. An additional two patients were without significant coronary artery disease on postmortem examination. One of these two patients had died secondary to cirrhosis and acute renal failure; and the second patient had chronic obstructive pulmonary disease and died of massive pulmonary emboli.

Comparison of the echocardiographic diagnosis of myocardial scarring to the angiographic findings is shown in table 2. The patients with scarring had a higher incidence of ventriculographic abnormalities as 90% (38 of 42) had an abnormal left ventriculogram compared to 56% (71 of 126) of those patients without scarring. Also, a discrete left ventricular aneurysm was present in 29% (12 of 42) of patients with scar compared to 2% (2 of 126) of patients without scarring.

Discussion

M-mode echocardiography is both a sensitive and specific means for noninvasively detecting myocardial scar tissue using criteria based on diastolic wall thicknesses and alterations in the appearance of the recorded echoes. Echocardiographically, scarred areas appear thinner and are more echo-producing than other areas of myocardium within a

TABLE 2. Comparison of Echocardiographic Detection of Scar to Coronary Cineangiographic and Ventriculographic Findings

	Echocardiographic findings	
	Scar present (42 patients)	Scar absent (126 patients)
Coronary artery disease		
No. of Patients	167	126
Location of obstruction		
LAD + LCC + RCC	15 (36%)	58 (46%)
Left Main	2 (5%)	2 (2%)
Left Main + LAD	0	2 (2%)
LAD	7 (17%)	13 (10%)
LAD + LCC	9 (21%)	11 (9%)
LAD + RCA	5 (12%)	29 (23%)
LCC + RCA	2 (5%)	6 (5%)
RCA	1 (2%)	5 (4%)
Left ventriculogram		
Normal	4 (10%)	53 (42%)
Abnormal	38 (90%)	71 (56%)
Not done	0	2 (2%)
Aneurysm	12 (29%)	2 (2%)

*One patient had well documented anterior infarction and ventriculographic evidence of ventricular aneurysm with no significant coronary artery disease angiographically.

Abbreviations: LAD = left anterior descending coronary artery; LCC = left coronary circumflex artery; RCA = right coronary artery.

sector scan. These changes are different from the echocardiographic findings in acute myocardial infarction. It has been shown that diastolic wall thicknesses in patients with acute ischemia or infarction are not significantly different from normal.⁵ Only one of 40 patients with acute myocardial infarction showed an area of diastolic wall thickness which was less than normal in a recent study.⁵ Acute myocardial infarction or ischemia may be distinguished by systolic thinning of the myocardial wall, although this is not a consistent finding. Increased echo density has not been reported to be a feature of acute ischemia.

Normally, within a sector scan, septal and posterior wall tissue appears to produce echoes relatively equal in intensity suggesting mediums of equal density. However, in 48 of 182 patients in our study, thin areas of myocardium were more echo-producing than were thicker areas within a sector scan. Echoes from the thin areas appeared as either a single thick band or as multiple dense horizontal lines. Several factors can account for this increased density and linear appearance. The echo reflected from a scarred endocardial surface should be more intense than one from a normal endocardium because the greater the difference in density between the tissues forming the reflecting interface, the greater the intensity of the echo.^{6,7} Also, the smoother surface of the scar and the horizontal plane of the collagen bundles⁸ enhance the return of echoes to the transducer by enabling a more perpendicular relationship of the ultrasound beam to the interfaces^{6,7} and by decreasing the scatter of the ultrasound waves.

The multiple linear echoes reflected from within the scarred myocardium may be accounted for by the fact that there are islands of intact myocardium within scar tissue^{8,9} resulting in multiple interfaces between scar and normal tissue. It is interesting that in four patients there was echocardiographic evidence of tissue loss without increase in echo intensity within the myocardium although the endocardial echo appeared dense. This may be explained by the fact that in some large infarcts vascularization may not be ade-




FIGURE 8. Sector scan recording of the left ventricle showing changes in thickness, motion and appearance of adjacent segments of septum in a patient with septal scarring. On the left of panel A, diastolic thickness of the septum is normal at 8 mm, as is the 7 mm excursion of the left septal echo during ejection (LSa). An adjacent area of septum (on the right of panel A) shows less (but still normal) excursion (5 mm); however, this area was abnormally thin at 4 mm and failed to thicken with systole. More apically (panel B) multiple bands of dense septal echoes were recorded with minimum normal motion (3 mm) present.

quate to enable ingrowth of blood vessels and connective tissue cells to the center of the infarct although the periphery is well healed.⁹

Because scar tissue is noncontractile, the wall motion and thickening seen in some of our patients requires explanation. Twenty-nine of the 71 areas which fulfilled our criteria for scar tissue by echocardiography showed diminished (19) or normal (10) motion. Whereas Kerber et al.¹⁰ have shown that normally perfused areas may show abnormalities of motion when immediately adjacent to an area with severe dyskinesia, the opposite may occur when poorly or nonperfused areas are passively pulled by vigorously moving normal tissue (fig. 8). The fact that islands of normal cells are seen within margins of infarcted areas could also account for motion in some cases and for the three instances where confirmed scarred areas actually showed some degree of systolic wall thickening echocardiographically.

We cannot be certain of the origin or significance of the multiple fine echoes (fuzz) frequently seen just below scarred septum or apically within the left ventricular cavity. Since several of these patients had clots within the left ventricle, perhaps in some instances the fuzz represented stagnant or clotted blood. However, multiple echoes are occasionally seen within the cardiac chambers of normal patients and may be reflections from random or turbulent flow within the chambers since fuzz is not seen within a normal mitral valve where flow is more laminar.

Ninety percent of the patients with echocardiographic evidence of scarring had clinical histories of myocardial infarction, yet only 63% (33 of 52) had pathognomonic Q waves present electrocardiographically. While the presence of electrocardiographic Q waves has been shown to reflect fibrotic

tissue,¹¹ their absence does not rule out prior infarction. Kaplan and Berkson¹² have shown that within 18 months postinfarction, Q waves of transmural infarcts will either disappear or become of borderline significance in 30% of cases.

The sensitivity of M-mode echocardiography for detecting myocardial scar tissue is limited by the fact that not every area of the left ventricle can be examined adequately. In our study this limitation was overcome largely by routinely recording sector and linear scans from multiple chest wall locations. The specificity of the echocardiographic criteria for myocardial scar is highly dependent on the technique used to record the echograms as well as on the interpretation in regard to wall thickness and echo density. Technically the echocardiogram must be of sufficient quality to permit delineation of echoes from the right and left sides of the interventricular septum, and from the posterior wall endocardium and epicardium if thicknesses are to be accurately measured. Proper identification of these structures is difficult. Density of the recorded echoes also depends on technical factors as well as on the type of tissue examined. Because gain settings and other factors influence the overall density of an echogram, it is important that density of echoes from a cardiac structure only be compared to other echoes within the same sector scan. Both septal and posterior wall echo intensities should be controlled simultaneously by keeping the septal echoes to the right of the depth compensation ramp. Distance of the structure from the transducer and the angle between the ultrasound beam and the tissue interface may also be important. However, this study shows that these limitations do not preclude identification of scar tissue in patients with coronary artery disease.

References

1. Corya BC, Rasmussen S, Feigenbaum H, Black MJ, Knoebel SB: Echocardiographic detection of scar tissue in patients with coronary artery disease. (abstr) *Am J Cardiol* 37: 129, 1976
2. Feigenbaum H: *Echocardiography*, ed 2. Philadelphia, Lea and Febiger, 1976, pp 55-85
3. Corya BC, Feigenbaum H, Rasmussen S, Black MJ: Anterior left ventricular wall echoes in coronary artery disease. *Am J Cardiol* 34: 652, 1974
4. Lipman BS, Massie E, Kleiger RE: *Clinical Scalar Electrocardiography*, ed 6. Chicago, Year Book Medical Publishers, 1972
5. Corya BC, Rasmussen S, Feigenbaum H, Knoebel SB, Black MJ: Systolic thickening and thinning of the septum and posterior wall in patients with coronary artery disease, congestive cardiomyopathy, and atrial septal defect. *Circulation* 55: 109, 1977
6. Gregg EC, Palagallo GL: Acoustic impedance of tissue. *Invest Radiol* 4: 357, 1969
7. Wells PNT: Absorption and dispersion of ultrasound in biological tissue. *Ultrasound Med Biol* 1: 369, 1975
8. Sandritter W, Wartman WB: *Color Atlas and Textbook of Tissue and Cellular Pathology*, ed 4. Chicago, Year Book Medical Publishers, 1973, pp 40-41
9. Mallory GK, White PD, Salcedo-Salgar J: The speed of healing of myocardial infarction. *Am Heart J* 18: 647, 1939
10. Kerber RE, Marcus ML, Ehrhardt J, Wilson R, Abboud FM: Correlation between echocardiographically demonstrated segmental dyskinesia and regional myocardial perfusion. *Circulation* 52: 1097, 1975
11. Bodenheimer MM, Banka VS, Trout RG, Pasdar H, Helfant RH: Correlation of pathologic Q waves on the standard electrocardiogram and the epicardial electrogram of the human heart. *Circulation* 54: 213, 1976
12. Kaplan BM, Berkson DM: Serial electrocardiograms after myocardial infarction. *Ann Intern Med* 60: 430, 1964

Alterations in Ventricular Mass and Performance Induced by Exercise Training in Man Evaluated by Echocardiography

ANTHONY N. DEMARIA, M.D., ALEXANDER NEUMANN, B.S., GARRETT LEE, M.D.,
WILLIAM FOWLER, M.D., AND DEAN T. MASON, M.D.

SUMMARY Few data are available regarding the effects of exercise training upon cardiac structure and performance in man. We evaluated the echograms of 24 normals before (PRE) and after (POST) 11 weeks of endurance exercise training. Conditioning consisted of a walk-jog-run protocol at 70% maximal heart rate for one hour four days per week. Training reduced heart rate and increased maximal duration and estimated oxygen consumption of treadmill exercise. Compared to PRE, the echogram in the POST training period revealed an increased left ventricular (LV) end-diastolic dimension (EdD), a decreased end-systolic

dimension (EsD) and thus an increased stroke volume ($EdD^3 - EsD^3$) and shortening fraction ($(EdD - EsD)/EdD$). Cardiac output (CO) and peripheral vascular resistance ($BP/CO \times 80$) were identical PRE and POST conditioning. Importantly, an increase in mean fiber shortening velocity was observed POST training as were increases in LV wall thickness, ECG voltage of S in $V_1 + R$ in V_6 , and LV mass. Thus endurance training was accompanied by increases in both LV dimension and mass as well as LV shortening fraction and contraction velocity as observed by echocardiogram.

THE POSSIBILITY THAT PHYSICAL CONDITIONING might favorably affect the appearance and course of coronary artery disease has stimulated a resurgence of interest in exercise training programs in recent years.¹⁻⁵ However, the effects of exercise training upon intrinsic ventricular structure and performance in man remain uncertain. Thus, although nearly all investigations have demonstrated the development of ventricular hypertrophy in animals following a program of strenuous physical conditioning,⁶⁻¹¹ no data exist concerning the influence of similar exertional activities upon cardiac muscle mass in humans. Moreover, despite the constant observation of a reduced heart rate at rest and submaximal work loads and an increased maximal oxygen consumption in normal subjects who have completed an exercise conditioning program,¹²⁻¹⁴ it remains unresolved

whether these beneficial effects are the result of enhanced cardiac performance, or of improved oxygen delivery and enhanced oxygen utilization by the peripheral circulation and musculoskeletal system.^{15, 16}

The paucity of precise data regarding the effects of physical conditioning upon intrinsic cardiac function has been largely related to the necessity of utilizing invasive procedures to obtain reliable measurements of the anatomy and performance of the heart. The recent advent of echocardiography has provided an atraumatic technique which has been demonstrated to be capable of reliably evaluating several aspects of cardiac anatomy and performance. Echocardiography provides accurate measurements of left ventricular cavity size, wall thickness and wall motion.¹⁷⁻²⁵ The present study was undertaken to assess by means of echocardiography the influence of exercise training on cardiac structure and function in normal human subjects.

Methods and Materials

Twenty-six normal subjects participating in a program of endurance physical conditioning as part of the curriculum of the Sacramento Policy Academy volunteered for the present study. The group was comprised of 15 males and 11 females

From the Section of Cardiovascular Medicine, Departments of Medicine and Physiology, University of California, School of Medicine, Davis, California.

Supported in part by Research Program Project Grant HL 14780 from the National Heart and Lung Institute, Bethesda, Maryland.

Address for reprints: Anthony N. DeMaria, M.D., Section of Cardiovascular Medicine, University of California, School of Medicine, Davis, California 95616.

Received June 27, 1977; revision accepted August 29, 1977.