

# Blood Flow Reductions in Stenosed Canine Coronary Arteries: Vasospasm or Platelet Aggregation?

JOHN D. FOLTS, PH.D., KIM GALLAGHER, PH.D.,  
AND GEORGE G. ROWE, M.D.

**SUMMARY** In 67 dogs with a 60–80% coronary stenosis produced by an external constricting plastic ring, blood flow measured with an electromagnetic flowmeter showed cyclical flow reductions of varying magnitude and duration, and then an abrupt return to control flow. In 45 dogs, heparin did not prevent these flow reductions, but ibuprofen (Motrin) or indomethacin abolished them. With incremental doses of each of these drugs, the cyclical flow reductions and the platelet function *in vitro* were diminished proportionately. In 10 more dogs, during low flow, pinching or poking the narrowed vessel suddenly restored normal flow. Topical application of papaverine and nitroglycerin proximal to the stenosis did not abolish the cyclic flow reduction, although a transient fall in systemic pressure indicated that they had been absorbed.

Seven dogs had the constricting cylinder and flow probe chronically implanted for 4–6 weeks. A single oral dose of aspirin, 20 mg/kg, abolished their cyclic flow reductions for 2–4 days.

In five dogs with 70% stenosis in the circumflex coronary artery, coronary arteriography was performed before coronary flow reduction and when coronary blood flow was low. This showed that there was a considerable additional reduction in the size of the mechanically constricted lumen during spontaneous flow reduction. In one dog, a nonopacified mass was dislodged from the area of constriction in 67 msec and this restored the lumen to its control diameter. Similar rapid clearing was filmed in two more dogs. In no case was vasospasm observed. These results suggest that obstruction from platelets aggregated in the narrowed lumen caused the cyclic flow reductions.

CORONARY ARTERY DISEASE is the major cause of sudden death in the United States.<sup>1</sup> Although significant narrowing of the coronary arteries is frequent in those who die suddenly, many do not show a recent coronary thrombus or other evidence of exacerbation of their disease.<sup>2</sup> Those resuscitated after cardiac arrest often do not have myocardial infarction,<sup>3</sup> so the cause of sudden coronary death remains to be defined.

While studying the physiologic consequences of controlled coronary artery stenosis in dogs, we noted a cyclic phenomenon, in which there were periodic decreases in coronary flow over a 5–10-minute period, usually with a sudden return to control flow; but sometimes, flow stopped, leading to ventricular fibrillation and sudden death.<sup>4, 5</sup> These cyclic phenomena could be abolished with aspirin, 20 mg/kg, and Folts et al.<sup>6</sup> postulated that they were caused by platelet thrombi that formed in the narrowed lumen. An alternative hypothesis might be that they were caused by vasospasm. We designed a series of experiments to determine if these randomly occurring cyclic flow reductions could be inhibited by platelet inhibitors or by drugs that reduce vasospasm.

## Methods

Mongrel dogs that weighed 23–28 kg (average 25.5 kg) were anesthetized with sodium pentobarbital and maintained with 80% nitrous oxide and 20% oxygen. A

left thoracotomy was performed through the fifth intercostal space and the heart was exposed. The proximal left circumflex coronary artery was dissected for 20 mm and the adventia was stripped away so that a Statham electromagnetic flow probe could be placed on it, with good electrode contact. The flow probe was selected such that it produced a tight fit on the vessel, and was placed 2–3 mm proximal to the constricting cylinder. These precautions ensure good electrode contact with the vessel wall. Constriction was produced with the plastic constricting cylinder placed distal to the flow probe. These cylinders, constructed of Lexan, are 3 mm long and are made with a variety of internal diameters.<sup>5–7</sup> A cylinder with an appropriate internal diameter is selected and placed around the outside of the artery to produce a stenosis that eliminates the myocardial reactive hyperemic response observed after a temporary 20-second complete occlusion of the coronary artery. This amount of stenosis (60–80% reduction luminal diameter) does not significantly reduce mean coronary flow, although phasic flow is markedly damped.<sup>5–7</sup> In all dogs, blood pressure was measured with a catheter attached to a P23GB Statham pressure transducer. Surface ECGs were recorded from leads placed on the epicardium. The dogs were divided into five groups to compare the effects on these cyclic flow reductions of drugs that reduce platelet activity and those that reduce vasospasm.

The dogs in group 1 and group 2 also had left ventricular pressure measured with a catheter placed in the left ventricle, and left ventricular dP/dt was determined by electronic differentiation. In the group 3 dogs, myocardial segment length (MSL) was measured as a determinant of regional myocardial contractility by placing pairs of ultrasonic crystals in the stenosed circumflex bed and the normal left anterior descending coronary artery bed, respectively. A Gould

From the Cardiology Section, Department of Medicine, University of Wisconsin Medical School, Madison, Wisconsin.

Supported by a grant HL15681, NIH, and the American Heart Association.

Address for correspondence: John D. Folts, Ph.D., Clinical Science Center, H6/338, 600 Highland Avenue, Madison, Wisconsin 53792.

Received October 13, 1980; revision accepted May 15, 1981.

Circulation 65, No. 2, 1982.

eight-channel recorder was used. Cyclic reductions in coronary blood flow were noted (fig. 1).

#### Group 1

In the 30 dogs in group 1, cyclic flow reductions usually begin to appear 10–15 minutes after the stenosis is produced.

After at least three cyclic flow reductions of more than 20 ml/min, heparin, 200 U/kg, was administered i.v. to inhibit thrombin and fibrin formation. The cyclic flow reductions continued unabated for 30 minutes after the heparin, with no significant change in size or frequency of the flow reductions. Thirty dogs were subdivided into three groups after the heparin had been administered. Ibuprofen (Motrin), 5 mg/kg i.v., was administered to 10 dogs; 10 mg/kg were given to 10 other dogs; and 15 mg/kg were given to the last 10 dogs. Blood samples were obtained before and 20 minutes after ibuprofen to determine platelet aggregation<sup>8</sup> using a Sienco aggregometer and ADP as the stimulus. A final concentration of 20  $\mu$ M ADP was used to induce a secondary wave of aggregation. The light transmission units reported are the difference from baseline, before adding ADP, to the peak of the secondary wave of aggregation. Coronary flow and blood pressure were monitored for 45 minutes after ibuprofen had been given.

#### Group 2

In 15 dogs, after heparin, 200 U/kg, had been given and after a 30-minute observation period during which cyclical flow reductions were occurring, i.v. indomethacin, 20 mg/kg, was administered. Blood samples were obtained before and 20 minutes after the indomethacin to determine platelet aggregability. Coronary flow and other hemodynamic parameters

were continuously monitored for 45 minutes. Each dog served as its own control, and samples could be obtained before and after the drug administration. A paired *t* test was used to analyze the data for groups 1 and 2.

#### Group 3

In 10 dogs prepared as above with a 60–80% stenosis of the left circumflex coronary artery, cyclic flow reductions were noted (fig. 2). At point y, the blood flow recovered spontaneously without any intervention by the investigators. Sometimes, the aggregates did not break loose; if they did not, the vessel was carefully pinched or poked very briefly with a surgical instrument to suddenly restore blood flow, apparently by mechanically dislodging an obstruction. In each of these 10 dogs, three topical applications of papaverine, 0.25 mg/kg (dissolved in 5 ml of saline), were made just proximal to the stenosis at 10-minute intervals. Nitroglycerin, 0.5 mg (dissolved in 5 ml of saline), was also applied topically, three times at 10-minute intervals proximal to the area of obstruction.

#### Group 4 — Chronically Instrumented Dogs

Seven dogs were prepared as above under sterile conditions for long-range survival with the flow probes, plastic cylinder constrictor and a pressure catheter chronically implanted as previously described.<sup>8</sup> During the surgery, when the constricting cylinder was in place, cyclic reductions in coronary flow began to occur. At this time, i.v. aspirin, 10 mg/kg, dissolved in 100 ml of saline was given. This dose reduced the size and frequency of the flow reductions to levels that did not produce life-threatening degrees of ischemia. Postoperatively, there was some minimal bleeding as measured by the volume of blood

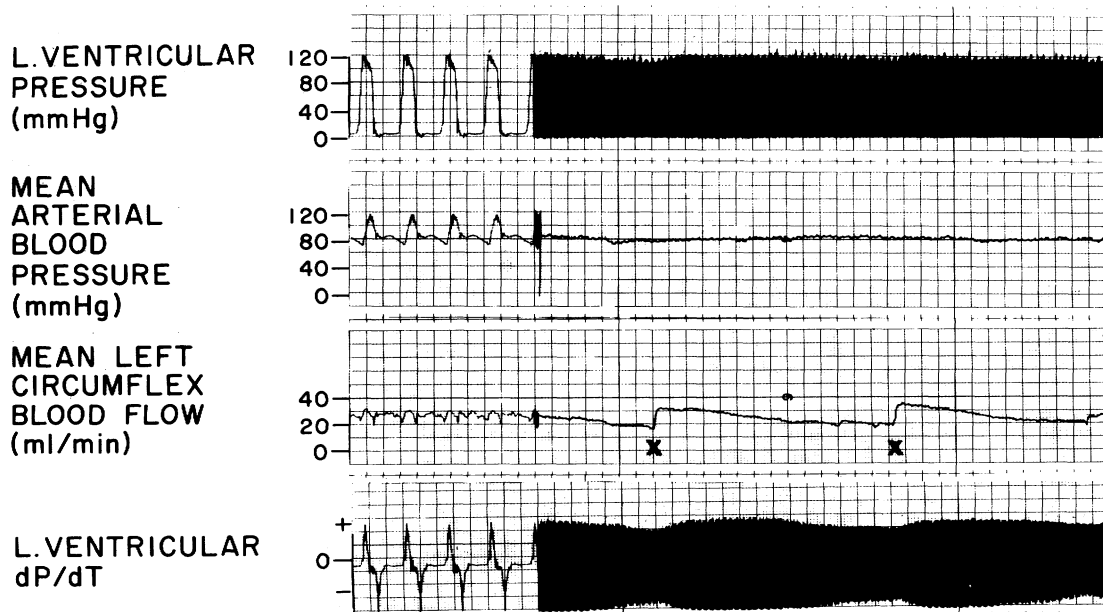


FIGURE 1. Cyclic reductions in blood flow in a coronary artery stenosed 70%. Left ventricular  $dP/dt$  is slightly impaired as the flow falls, and then improves when the blood flow is restored. Blood pressure does not change.

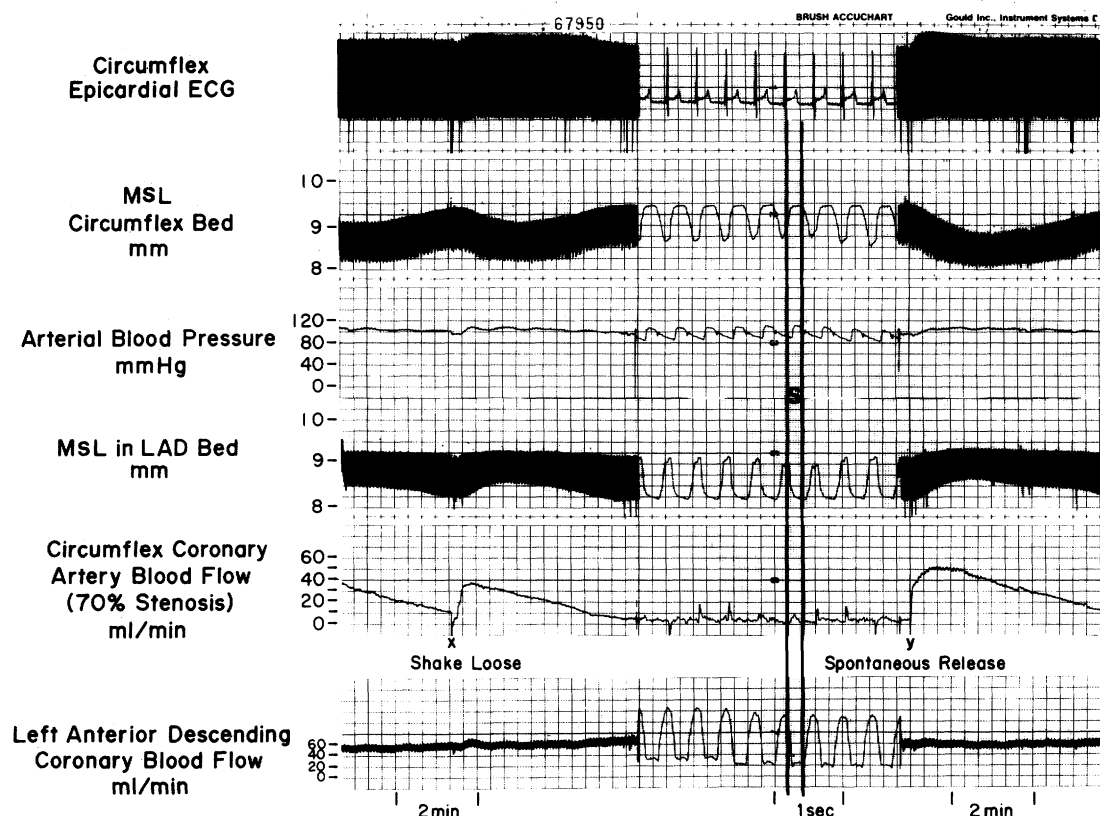


FIGURE 2. (left) Coronary blood flow is decreasing in the stenosed coronary artery on the left. The myocardial segment length (MSL) in the circumflex bed shows decreased contractility or paradoxical bulging, while the MSL in the normal left anterior descending coronary artery (LAD) bed shows compensatory increased shortening and increased contractility. At point x, the platelet thrombus is manually dislodged by shaking or poking the plastic cylinder. (right) The coronary flow has declined again. At point y, the platelet thrombus spontaneously breaks loose, restoring blood flow. Reprinted with permission from Mehta J (ed): Platelets and Prostaglandins in Cardiovascular Disease. Mt. Kisco, NY, Futura Publishing 1981.

collected from the chest tube. This was treated with blood transfusions as needed. These dogs were followed 4–12 weeks (average 9 weeks). They were given aspirin, 20 mg/kg daily, in their dog food.

### Group 5

In five more dogs prepared as described above, coronary arteriography was performed with the chest open using a coronary arteriographic catheter placed in the left circumflex coronary artery under fluoroscopic guidance, as previously described.<sup>7</sup> Coronary arteriography was performed using diatrizoate meglumine and diatrizoate sodium in the control state when coronary flow was good and when coronary blood flow had decreased to a low level. Sometimes, the contrast material was injected forcibly to try to dislodge obstructing material from the constricted area.

## Results

### Groups 1 and 2

In all the dogs in groups 1 and 2, the cyclic flow reductions continued unabated at the same frequency and size as before heparin administration for the 30-minute observation period. These reductions varied

from 10–40 ml/min and occurred at a rate of one every 20 minutes to one every 3.5 minutes, but both the magnitude and frequency were variable (fig. 3). Indomethacin and ibuprofen (Motrin), which inhibit platelet aggregation, reduced or abolished the cyclic flow reductions (tables 1 and 2) for 35–45 minutes, after which the flow reductions gradually returned. The dogs that received ibuprofen, 15 mg/kg, had some hemolysis, as evidenced by a slight red color in the plasma prepared for the platelet aggregation studies.

In group 1, the *in vitro* platelet aggregation, as measured with the platelet aggregometer, was reduced proportionately to the dose of platelet cyclooxygenase inhibitor (table 1). Also, the magnitude and frequency of the cyclic flow reductions were diminished proportionately with increasing doses of ibuprofen.

### Group 3

In group 3, mechanical agitation of the vessel appeared to restore blood flow by dislodging an obstruction, as judged by instantaneous recovery of flow to the control level and rapid restoration of impaired hemodynamics (fig. 2). Neither papaverine nor

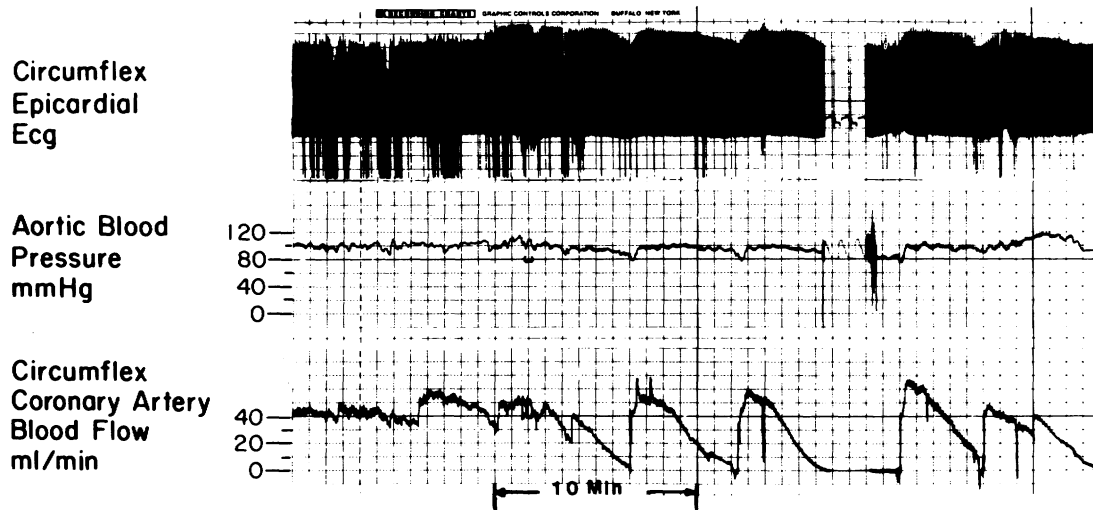


FIGURE 3. Cyclical flow reductions in a 70% stenosed canine coronary artery over a 40-minute observation period. Usually, the size and shape of the flow reductions are somewhat more uniform than these, but this pattern does occur in about 20% of the dogs. Thus, they should be observed for 30–60 minutes to detect a change resulting from a pharmacologic intervention.

nitroglycerin was effective in reducing the magnitude or frequency of the cyclic flow reductions, although they both appeared to be absorbed through the vessel wall proximal to the obstruction and were carried through the area of stenosis and beyond, since they caused mild systemic hypotension.

#### Group 4

Cyclic flow reductions occurred during surgery and during the postoperative recovery period, but could be abolished by i.v. aspirin, 10 mg/kg. This dose is lower than that which will abolish platelet agglutination in our model (20 mg/kg), but was given in this dose dur-

ing surgery in these dogs to protect them from a fatal cyclic flow reduction and to ensure that they had some platelet function to aid postoperative hemostasis. After surgery, they received a single oral dose of acetyl salicylic acid, 20 mg/kg, daily with their dog food. When the aspirin was withheld, small cyclic flow reductions reappeared within 2–3 days. These could be abolished within 2 hours by giving oral aspirin. Two dogs that received aspirin became excited during the postoperative period and showed increased cyclic flow reductions and died. This is presumed to have resulted from renewed platelet thrombus formation in the lumen; obstructing “white” platelet thrombi were

TABLE 1. Hemodynamic and Hemostatic Effects of Three Doses of Intravenous Ibuprofen (Motrin) on Platelet Thrombus Formation in Stenosed Canine Coronary Arteries

	Dose 1, 5 mg/kg (n = 10)		Dose 2, 10 mg/kg (n = 10)		Dose 3, 15 mg/kg (n = 10)	
Arterial blood pressure (mm Hg)						
Before	89 ± 10	NS	103 ± 24	NS	100 ± 17	NS
After	93 ± 9		95 ± 15		103 ± 22	
Platelet aggregation (LTU)						
Before	59 ± 11	<i>p</i> < 0.05	64 ± 9	<i>p</i> < 0.01	63 ± 13	<i>p</i> < 0.01
After	48 ± 7		45 ± 10		40 ± 7	
Heart rate (beats/min)						
Before	122 ± 28	<i>p</i> < 0.01	133 ± 18	<i>p</i> < 0.01	113 ± 15	<i>p</i> < 0.01
After	104 ± 26		111 ± 29		91 ± 19	
Cyclical flow reductions						
Before						
Frequency (cycles/30 min)	6 ± 3		7 ± 4		5 ± 2	
Average size (ml/min)	14 ± 9		19 ± 10		15 ± 11	
After						
Frequency (cycles/30 min)	6 ± 5	NS	4 ± 2	<i>p</i> < 0.05	0 ± 0	<i>p</i> < 0
Average size (ml/min)	19 ± 11	NS	13 ± 9	<i>p</i> < 0.05	0 ± 0	<i>p</i> < 0

Values are average ± SEM.

TABLE 2. *Hemodynamic and Hemostatic Effects of Intravenous Indomethacin (Indocin), 20 mg/kg, on Platelet Thrombus Formation in Stenosed Canine Coronary Arteries*

Arterial blood pressure (mm Hg)			
Before	100 ± 19	NS	
After	95 ± 15		
Platelet aggregation (LTU)			
Before	68 ± 14	<i>p</i> < 0.01	
After	39 ± 11		
Heart rate (beats/min)			
Before	114 ± 29	<i>p</i> < 0.01	
After	94 ± 14		
Cyclical flow reductions			
Before			
Frequency (cycles/30 min)	9 ± 5		
Average size (ml/min)	22 ± 8		
After			
Frequency (cycles/30 min)	0 ± 0	<i>p</i> < 0	
Average size (ml/min)	0 ± 0	<i>p</i> < 0	

Data are average ± SEM.

found in the stenosed coronary artery lumen of both dogs at necropsy. We have shown that epinephrine infusions can temporarily reinduce the platelet thrombus formation despite pretreatment with aspirin until the epinephrine is metabolized.<sup>9</sup>

### Group 5

In five dogs, coronary arteriography was performed when the coronary blood flow had reached a low point, as determined with the electromagnetic flowmeter. There was marked further reduction of the size of the lumen where the constrictor was applied when flow was reduced and total occlusion was observed when flow was stopped. In the three dogs that had the largest flow decreases from control level (45 ml/min, 55 ml/min and 70 ml/min), a non-opacified mass was dislodged from the area of constriction during forcible injection of contrast material. This cleared the passage through the area of stenosis so that its lumen returned to the control state, and flow rapidly returned to normal since the localized obstruction was sharply decreased. A continuous sequence of single frames from one of the arteriograms, taken at 60 frames/sec, is shown in figure 4. The non-opacified mass can be seen almost obstructing the lumen in frames 6–12 and can be noted to clear the lumen in frame 13. The width of the vessel lumen just distal to the stenosis in frame 12 increased by 38% one frame later, when the mass left the area of stenosis. Careful study of the distal branches did not reveal any obstructed vessels. There are so many branches, however, that we cannot state with confidence that no single small vessel became obstructed.

### Discussion

In none of the dogs in groups 1 and 2 did the heparin treatment abolish the cyclic flow reductions. Heparin is effective against fibrin clot formation, but

not platelet aggregation. Indeed, in some cases, eight brands of heparin have been shown to actually promote platelet aggregation in an in vitro test.<sup>10</sup> We did not see any enhancement of the platelet thrombus formation in our model with heparin. Furthermore, in a previous study, when the coronary blood flow had declined to zero, we ligated the stenosed vessel first distally and then proximal to the plastic constrictor. The vessel was then removed, fixed, sectioned and stained for light microscopy. Platelet thrombi were always found in the narrowed lumen.<sup>5, 11</sup> In dogs that had the cyclic flow reductions abolished with aspirin, when the coronary artery was ligated and removed as above, we rarely saw platelet thrombi in the narrowed lumen.<sup>5</sup> However, there is always some endothelial damage. The plastic cylinder constricts the vessel and produces wrinkling and cracking of the endothelium as the coronary artery is compressed into a smaller space.<sup>7, 11</sup> We cannot measure PGI<sub>2</sub> in this model and can only speculate whether the endothelial damage may decrease the production of PGI<sub>2</sub> in the area of the stenosis.

All of the dogs showed total inhibition of the spontaneous flow reductions with the highest doses of the platelet inhibitors and almost total inhibition with the second highest dose of ibuprofen (tables 1 and 2). The results of the effects of ibuprofen (Motrin) on the platelet activity are shown in table 1. Those results and the hemodynamic observations suggest that platelet thrombi are the primary causes of cyclic flow reductions. Platelets gather in areas where they are mechanically damaged, as they could be by the shear forces created by the narrowed lumen.<sup>12</sup> Endothelial damage is also produced by constricting the coronary artery,<sup>7</sup> and this would enhance platelet aggregation at the point of stenosis. We initially chose to study aspirin, indomethacin and ibuprofen, which are cyclooxygenase inhibitors. In a previous study we demonstrated that sulfinpyrazone, which acts in part by inhibiting cyclooxygenase, also abolishes these cyclic flow reductions.<sup>13</sup> We are studying an experimental thromboxane A<sub>2</sub> synthetase inhibitor that also appears to block the cyclic flow reductions (unpublished observations).

These cyclic flow reductions vary considerably in magnitude and rate of flow decline (fig. 3), probably for many reasons. The amount of damaged intima and exposed collagen could differ considerably between experiments. The level of circulating catecholamines varies considerably in an anesthetized animal, depending in part on the depth of anesthesia and the amount of surgical stress (unpublished observations), which are known to enhance platelet aggregation.<sup>9</sup> Finally, some dogs appear to have impaired platelet function.<sup>14</sup>

More convincing data suggesting that periodic formation of platelet thrombi is the primary cause of the flow reductions, however, come from the chronically instrumented dog experiments. Aspirin remains in the plasma for only a few hours, but has a permanent effect on the aggregation of platelets that are exposed to it, possibly by acetylation and some inactivation of the cyclooxygenase enzyme.<sup>15</sup> It is not known how

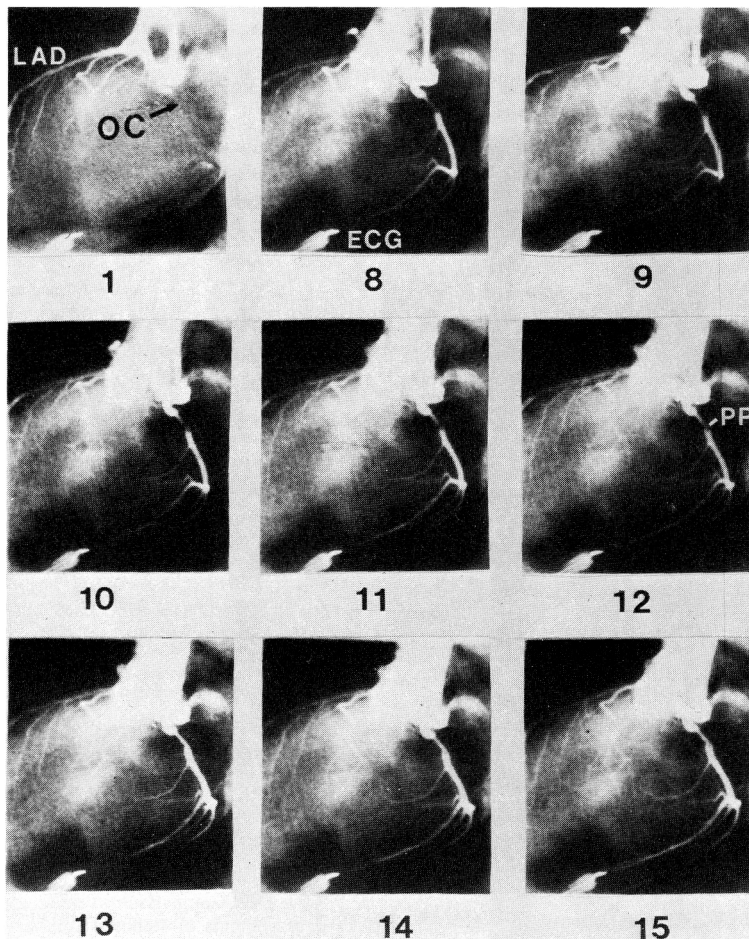


FIGURE 4. Serial frames (60 frames/sec) from circumflex coronary injection of contrast material. In frame 1, the circumflex artery, which has been given a 70% reduction in diameter by a fixed mechanical means initially, is nearly totally occluded (OC), while the left anterior descending coronary artery (LAD) fills normally. In frames 9–11, contrast material is more obvious in the constricted segments as a non-opacified mass is pushed ahead of it, and in frame 12, there appears to be a platelet thrombus (PP). Note the sharp difference between frame 12 and frame 13 as the plug leaves the obstructed segment. The platelet thrombus has apparently been forced distally, permitting a significant reduction of the obstruction at the site of the fixed mechanical stenosis, and much better filling of the circumflex at the area of stenosis and distally as well.

many other cellular functions may be impaired by inhibiting the cyclooxygenase known to be active in other parts of the body, but it seems unlikely that aspirin, which had been gone from the plasma for several days, could still prevent vasospasm in the stenosed arteries of these chronically instrumented dogs. Studies of blood platelets, however, indicate that it would take several days for the marrow to release enough new platelets unaffected by the aspirin to cause the flow reductions to come back. The cyclic flow reductions in these dogs did return after 2–3 days, as expected. The two dogs that became excited and died in the early postoperative period had platelet aggregates in the stenosed coronary artery despite pretreatment with aspirin. We have shown that elevating plasma catecholamines with i.v. epinephrine can reactivate the platelet aggregation after aspirin administration,<sup>9</sup> thus, we assumed that catecholamines were secreted when the dogs became excited and produced fatal platelet thrombi.

Because an amount of stenosis is chosen which eliminates a reactive hyperemic response to a temporary complete 20-second occlusion, the coronary arterioles distal to the stenosis are assumed to be nearly maximally dilated. It is unlikely that endogenously released catecholamines would cause significant additional coronary vasodilation. Recent experiments by Wolinsky *et al.*<sup>16</sup> indicate a reduction

in coronary flow subsequent to distal vasodilatation in a critically stenosed vessel. Although this mechanism is poorly understood, perhaps it partly explains the present observations.

Mechanical agitation of a vessel seems more likely to suddenly restore blood flow by dislodging a luminal obstruction than by relieving vasospasm. A pressure gradient gradually builds up as the platelets accumulate in the narrowed lumen. The pressure gradient finally becomes so large (50–60 mm Hg) that it dislodges or forces the platelet thrombus out of the narrowed segment of the lumen and washes it distal.<sup>5</sup> This provides a sudden restoration of flow. If vasospasm caused decreased flow in our model, it seems likely that it would be relieved more gradual and flow would be gradually restored rather than suddenly return to the control value. Also, antispasmodic agents should have restored blood flow and at least temporarily prevented the flow reductions if vasospasm were primarily responsible for the flow changes. These agents were ineffective in preventing or relieving the flow reductions.

We have occasionally observed vasospasm in the internal mammary artery and the coronary artery during and after an internal mammary-to-circumflex coronary artery bypass graft.<sup>17</sup> This could be relieved with the same doses of papaverine used in the present study, applied topically, but took 2–3 minutes to be



effective. Nitroglycerin may not relieve ergonovine-induced spasm in a coronary artery unless it is given directly into the coronary artery.<sup>18</sup> This clinical observation is not carefully controlled and doses may not have been comparable. We applied the nitroglycerin topically proximal to the stenosis, and it must have entered the thin-walled coronary artery and passed distally as it produced a transient decrease in aortic blood pressure. This is similar to an intracoronary infusion, but did not abolish the flow reductions.

Coronary arteriography showed considerable reduction in the size of the constricted lumen when the flow had declined to a low level. During the forcible injection of contrast material, blood flow measured with the flowmeter suddenly returned to control levels as the arteriograms showed equally sudden clearing of the lumen of the constricted segment with an immediate increase in lumen size. Figure 4 shows a mass, thought to be a platelet thrombus, clearing from the lumen in 67 msec. We do not know the fate of the platelet thrombus once it breaks loose. We are developing an indium-III labeling technique which should aid us in locating the labeled thrombus as it moves distally.

The platelet thrombus formation may have additional significance in some instances as a source of vasoconstrictors. The fact that we do not recognize coronary vasospasm in adult dogs despite platelet thrombus formation (which may release thromboxane A<sub>2</sub>) may be because adult dogs are reported not to have functioning thromboxane A<sub>2</sub> receptors in their coronary arteries, whereas 3–6-month-old puppy coronary arteries respond to exogenous thromboxane A<sub>2</sub> by showing contraction.<sup>19</sup>

Vasospasm has been reported in human coronary arteries and is thought, when severe, to decrease coronary flow and to cause angina and, possibly, sudden coronary death.<sup>20, 21</sup> Maseri et al. suggested that repetitive severe vasospasm may result in endothelial damage, plaque hemorrhage with consequent platelet aggregation and release of thromboxane A<sub>2</sub> and further vasoconstriction.<sup>21</sup> Perhaps also, endothelial damage and developing atherosclerotic plaques lead to platelet aggregation at the site, with decreased blood flow and subsequent release of thromboxane A<sub>2</sub> and other potent vasoconstricting agents. This might lead to distal vasospasm, which could produce further vascular damage in a vicious cycle.

The clinical observation of transient reduction of coronary artery luminal size may also occur from accumulation of platelets on the vessel wall as well as from vasospasm, especially when the transient luminal reduction occurs at the site of an established atheromatous plaque. As a unifying concept, if thromboxane A<sub>2</sub> were fed from aggregating platelets into the vaso vasorum of an artery at the site where they were lodged, severe localized vasospasm could occur. Such an event could be important in the poorly understood, highly localized coronary arterial constrictions in variant angina. Although the duration of the action of thromboxane A<sub>2</sub> is very short, it is so potent as a vasoconstrictor that continued accumulation of new

platelets in an aggregate might supply sufficient thromboxane A<sub>2</sub> to cause prolonged vasospasm. Thus, spasm when seen in stenosed coronary arteries of man<sup>22</sup> may be the result of an antecedent platelet plug that released thromboxane A<sub>2</sub> and produced vasospasm. This would, of course, aggravate partial fixed obstruction in coronary arteries and would enhance the effects of even moderate aggregates of platelets in narrowed coronary segments. Such lesions might very well be overlooked at postmortem examination and yet constitute an important cause of sudden unexpected death and/or myocardial infarction.

## References

1. Schaffer WA, Cobb LA: Recurrent ventricular fibrillation and modes of death in survivors of out-of-hospital ventricular fibrillation. *N Engl J Med* **293**: 260, 1975
2. Grace WJ: Sudden death and acute myocardial infarction — what are we talking about? *Am Heart J* **92**: 1, 1976
3. Cobb LA, Baum RS, Alvarez WA: Resuscitation from out-of-hospital ventricular fibrillation: 4-year follow-up. *Circulation* **52** (suppl III): III-223, 1975
4. Folts JD, Rowe GG: Cyclical reductions in coronary blood flow in coronary arteries with fixed partial obstruction and their inhibition with aspirin. (abstr) *Fed Proc* **33**: 413, 1974
5. Folts JD, Crowell EB, Rowe GG: Platelet aggregation in partially obstructed vessels and their elimination with aspirin. *Circulation* **54**: 365, 1976
6. Folts JD: Hemodynamic effects of reductions in coronary blood flow, caused by mechanical stenosis and platelet aggregates forming in dog coronary arteries. *Proceedings of the 3rd International Conference on Cardiovascular System Dynamics*. The Hague, Martinus Nijhoff Medical Division, 1980
7. Gallagher KP, Folts JD, Rowe GG: Comparison of coronary arteriograms with direct measurements of stenosed coronary arteries in dogs. *Am Heart J* **95**: 338, 1978
8. Folts JD, Gallagher KP, Rowe GG: Hemodynamic effects of controlled amounts of coronary artery stenosis in short-term and long-term studies in dogs. *J Thorac Cardiovasc Surg* **73**: 722, 1977
9. Folts JD, Gallagher KP: Epinephrine-induced platelet aggregation in mechanically stenosed dog coronary arteries occurring after aspirin administration. (abstr) *Clin Res* **26**: 231, 1978
10. Eika C: The platelet aggregation effect of eight commercial heparins. *Scand J Haematol* **9**: 480, 1972
11. Folts JD: Platelet red cell interaction proximal to an area of acute thrombosis which formed in stenosed dog coronary arteries. (abstr) *Clin Res* **28**: 756, 1980
12. Mustard JF: Platelets and thrombosis in acute myocardial infarction. *Hosp Pract* **115**: 28, 1972
13. Folts JD, Beck RA: Inhibition of platelet plugging in stenosed dog coronary arteries with sulfinpyrazone. *In Cardiovascular Actions of Sulfinpyrazone: Basic and Clinical Research*, edited by McGregor M, Mustard JF, Oliver MF, Sherry S. *Proceedings of an International Symposium*. Miami, Symposia Specialists, 1979
14. Raymond SL, Dodds WJ: Platelet membrane glycoproteins in normal dogs and dogs with hemostatic defects. *J Lab Clin Med* **93**: 607, 1979
15. Ali M, McDonald JWD: Reversible and irreversible inhibition of platelet cyclo-oxygenase and serotonin release by non-steroidal anti-inflammatory drugs. *Thromb Res* **113**: 1057, 1978
16. Wolinsky P, Santamore WP, Wiener L, Brest AN: Dynamic changes in hemodynamic severity of coronary artery stenosis in canine. *Cardiovasc Res* **13**: 113, 1979
17. Folts JD, Gallagher KP, Kroncke GM, Rowe GG: Myocardial revascularization of the canine circumflex coronary artery using retrograde IMA flow; without the use of cardiopulmonary bypass. *Ann Thorac Surg* **31**: 21, 1981
18. Buxton A, Goldberg S, Hirshfeld JW, Wilson J, Mann T,

- Williams DO, Overlie P, Oliva P: Refractory ergonovine-induced coronary vasospasm: importance of intracoronary nitroglycerin. *Am J Cardiol* 46: 329, 1980
19. Wang HH, Kulharni PS, Ealcinsk E: Effects of prostaglandins (PGE<sub>1</sub>s) and thromboxane A<sub>2</sub> on the coronary circulation of adult and puppy dogs. (abstr) *Fed Proc* 37: 731, 1978
20. Heupler FA Jr, Proudfit WL, Razavi M, Sirey EM, Greenstreet R, Sheldon SC: Ergonovine maleate provocative test for coronary arterial spasm. *Am J Cardiol* 41: 631, 1978
21. Maseri A, Severi S, DeNes M, L'Abbate A, Chiechia S, Marzilli M, Ballestra AM, Parodi O, Biagini A, Distant A: "Variant" angina: one aspect of a continuous spectrum of vasospastic myocardial ischemia. *Am J Cardiol* 42: 1019, 1978
22. Ellis EF, Oelz O, Roberts LJ II, Pryne NA, Sweetman BJ, Nies AS, Oates A: Coronary arterial smooth muscle contraction by a substance released from platelets: evidence that it is thromboxane A<sub>2</sub>. *Science* 193: 1135, 1976

## Morphologic Evidence for Coronary Artery Spasm in Eclampsia

THOMAS W. BAUER, M.D., PH.D., G. WILLIAM MOORE, M.D., PH.D.,  
AND GROVER M. HUTCHINS, M.D.

**SUMMARY** Vascular spasm has been considered to be an important component of the eclamptic state. If this abnormal vascular reactivity affects the coronary arteries in eclampsia, one might expect to find areas of myocardial contraction band necrosis, a lesion secondary to coronary reflow after periods of no flow. We reviewed the cardiac findings in the 34 patients with fatal eclampsia (hypertension, edema, proteinuria, and convulsions without evident cause) autopsied at The Johns Hopkins Hospital since 1899, and compared each with the next pregnant or puerperal nontoxic autopsied patient. The eclamptic patients were 15–45 years old (average 27 years). Convulsions began antepartum in 21 patients, intrapartum in eight, and postpartum in five. The hearts weighed 200–407 g (average 312 g). One heart had rheumatic valvular disease and one had myocarditis. Histologic study of heart sections showed the presence of contraction band necrosis in 12 cases (35%). The control cases included two patients with rheumatic valvular disease, two with endocarditis, two with myocarditis, two with pericarditis, and one with leukemic infiltration. Only one control patient (3%) had contraction band necrosis ( $p < 0.001$ ). The frequent occurrence of myocardial contraction band necrosis suggests that coronary artery spasm may be common in patients who die with eclampsia.

ECLAMPSIA is a disorder unique to pregnancy and the puerperium and is characterized by hypertension, proteinuria, edema and tonic-clonic seizures with loss of consciousness. Although the cause of eclampsia is unknown, vascular spasm plays a major role in its presentation and has been directly observed in the nail beds, bulbar conjunctivae and ocular fundi.<sup>1, 2</sup> Histologic findings in the kidney and brain from autopsied patients have been attributed, at least in part, to vasospasm.<sup>3–5</sup> Although myocardial infarction is unusual in eclampsia, symptoms of congestive heart failure, cyanosis, and postseizure hypotension are frequent, especially in fatal cases.<sup>6, 7</sup> Most pathologic studies of patients with eclampsia in which the heart has been evaluated, however, were published before 1964 and primarily described regions of myocardial

hemorrhage with occasional degenerative changes and focal necrosis.<sup>3, 6, 8–12</sup>

In 1964, Sommers and Jennings reported the presence of transverse eosinophilic contraction bands in the posterior papillary muscle of dog hearts after experimentally-induced ischemia and reperfusion.<sup>13</sup> Contraction band necrosis, which occurs with a variety of insults to the heart,<sup>14</sup> is also the morphologic manifestation of a period of myocardial ischemia followed by reperfusion.<sup>15–17</sup> In patients without evidence of fixed coronary artery obstruction or other cause of nonperfusion followed by reperfusion, the finding of contraction band necrosis has suggested the presence of coronary artery vasospasm.<sup>18, 19</sup> If contraction band necrosis is the result of coronary artery vasospasm, patients who die in the course of a generalized vasospastic disorder might be expected to have myocardial contraction band necrosis. The purpose of this investigation was to determine if patients with eclampsia have an increased incidence of contraction band necrosis in their hearts.

### Materials and Methods

We reviewed the cardiac findings in the 34 patients with fatal eclampsia who were autopsied at The Johns Hopkins Hospital between 1899 and 1979. Twenty-seven patients were studied before 1930, the approxi-

From the Department of Pathology, The Johns Hopkins Medical Institutions, Baltimore, Maryland.

Supported by NHLBI grant HL-17655.

Presented in part at the 53rd Scientific Sessions of the American Heart Association, Miami Beach, Florida, November 20, 1980.

Dr. Moore is a Research Fellow of the American Heart Association Maryland Affiliate, Inc.

Address for correspondence: Grover M. Hutchins, M.D., Department of Pathology, The Johns Hopkins Hospital, Baltimore, Maryland 21205.

Received March 4, 1981; revision accepted May 12, 1981.

*Circulation* 65, No. 2, 1982.