

Noninvasive Visualization of the Dilated Main Coronary Arteries in Coronary Artery Fistulas by Cross-sectional Echocardiography

JUNICHI YOSHIKAWA, M.D., HOROSHI KATAO, M.D., KOJI YANAGIHARA, M.D.,
YOSHIHIRO TAKAGI, M.D., FUKUMARU OKUMACHI, M.D., KIYOSHI YOSHIDA, M.D.,
YASUHIKO TOMITA, M.D., TAKASHI FUKAYA, M.D., AND KUNIZO BABA, M.D.

SUMMARY Real-time cross-sectional echocardiographic studies of the main coronary arteries were performed in 20 normal subjects, 12 patients with patent ductus arteriosus and 14 patients with coronary artery fistula in whom the diagnosis was established by angiography. In 12 patients, the coronary artery that formed the fistula was dilated: The right coronary artery was involved in eight and the left coronary artery in four. The dilated coronary artery appeared as two dominant parallel echoes of wide lumen originating from the aorta in the region of the involved artery. The echo diameter of the coronary artery correlated well with the angiographically estimated diameter of the artery. In the normal subjects and the patients with patent ductus arteriosus, we found no echocardiographic findings of coronary artery dilatation. This study demonstrates that cross-sectional echocardiography is useful in identifying the dilated coronary artery in coronary artery fistula and distinguishing this entity from patent ductus arteriosus.

CONGENITAL coronary artery fistula is relatively uncommon, but not rare, and generally occurs as an isolated anomaly. The lesion should be suspected whenever the patient is referred with atypical findings of patent ductus arteriosus. At present, angiography is used to diagnose coronary artery fistula.

Weyman and colleagues¹ first described a method of visualizing the left main coronary artery with cross-sectional echocardiography. Subsequently, we described the use of cross-sectional echocardiography to diagnose coronary artery aneurysms in patients with mucocutaneous lymph node syndrome.² The lesions appear as a circular echo-free space with clearly defined borders in sites corresponding to angiographically proved aneurysms.

The purpose of this study was to use cross-sectional echocardiography to visualize the dilated coronary arteries in patients with coronary artery fistulas. The majority of the involved coronary arteries in this condition are characteristically dilated.

Materials and Methods

Cross-sectional echocardiographic studies of the main coronary arteries were performed in 20 normal subjects who did not have invasive studies, 12 patients with angiographically proved patent ductus arteriosus and 14 patients with congenital coronary artery fistulas in whom the diagnosis was established by retrograde aortography or selective coronary arteriography. The normal subjects were children or young adults without coronary artery disease. All the patients with patent ductus arteriosus had a precordial continuous murmur that was best heard at the second or third left inter-

costal space. The patients were 12–46 years old. In six patients, the fistula was between the right coronary artery and the right atrium, in two between the right coronary artery and the right ventricle, in four between the left coronary artery and the pulmonary trunk and in two between the left coronary artery and the right atrium. The coronary artery that formed the fistula was typically dilated in 12 (all of the right coronary arteries and four of six left coronary arteries). There were five males and nine females, ages 7–60 years. All the patients had a precordial continuous murmur, which was loudest along the upper to middle sternal border in eight patients and at the lower sternal edge in six.

Cross-sectional echocardiography was performed using a Toshiba SSH-11A Echograph. We took a long-axis scan of the aorta. The transducer was then rotated 90° to a position parallel to the short axis of the aorta. The probe, with the plane of the sweep maintained perpendicular to the short axis of the aorta, was swept in a superior-inferior arc. During this sweep, a dense mass of echoes originating from the left inferior border of the aorta was identified. The transducer was then rotated parallel to the short axis or horizontal cross section of the body in an attempt to align the plane of the ultrasonic scan more closely to the course of the left main segment. In addition, the probe was rotated to a position close to the perpendicular section of the body rather than the short axis of the aorta to align the transducer sweep parallel to the long axis of the right main coronary artery.²

The luminal diameter of the main coronary arteries by cross-sectional echocardiography was assessed as the distance between the two parallel echoes just distal to the ostia. The diameter was taken from the anterior surface of the anterior wall to the anterior surface of the posterior wall. The two parallel echoes moved with each cardiac cycle, requiring frame-by-frame analysis of the videotape after the initial data were recorded. The measurement was made only when two parallel dominant linear echoes arising from the aorta were

From the Departments of Cardiology and Pediatric Cardiology, Kobe Municipal Central Hospital, Kobe, Japan.

Address for correspondence: Junichi Yoshikawa, M.D., Department of Cardiology, Kobe Municipal Central Hospital, Minatogawa-4-6, Chuo-ku, Kobe, Japan 650.

Received December 16, 1980; revision accepted June 10, 1981.
Circulation 65, No. 3, 1982.

clearly visualized and continuity between the lumina of two vessels was obviously present. The luminal diameter of the main coronary arteries on angiography was measured at the level just distal to the ostia using the lateral projection. The angiographic caliber of the main coronary arteries varied considerably with age in the patients who had patent ductus arteriosus, but was not greater than 7 mm. A coronary artery larger than 7 mm in diameter, therefore, was judged to be dilated, although this finding alone is not enough to make a diagnosis of coronary artery fistula.

Results

The left main coronary artery was adequately visualized in 15 of 20 normal subjects and eight of 12 patients with patent ductus arteriosus. The proximal right main coronary artery was detected in five of the above 32 subjects. All of the 28 visualized main coronary arteries appeared as two dominant parallel linear echoes, with a clear, but not wide, lumen. Its diameter was not larger than 6 mm in each subject. The echocardiographically visualized main coronary arteries of the two patients with coronary artery fistula, in whom no luminal dilatation of the vessels was observed by

angiography, appeared normal (fig. 1). In the 12 patients in whom the coronary artery fistula of the dilated main coronary artery was assessed angiographically, two parallel linear echoes of wide lumen arising from the aorta were observed in the region of the involved artery.

Figure 2 is a cross-sectional echocardiogram obtained from a patient with a fistula between the right coronary artery and the right ventricle. The two parallel linear echoes of markedly wide lumen originating from the anterior portion of the aorta is clearly visualized. This cross-sectional echocardiographic pattern corresponded well to the angiographically demonstrated dilated right coronary artery (fig. 3). Figure 4 is a cross-sectional echogram from a patient with a fistula between the right coronary artery and the right atrium. The moderately dilated right coronary artery is visualized. The angiographic and cross-sectional echocardiographic diameters of the proximal main coronary arteries correlated well in the 12 patients with a dilated main coronary artery (fig. 5).

Discussion

Previous reports^{1, 3, 4} using a real-time, cross-sectional echocardiographic scanner have demonstrated the feasibility of recording the left main coronary artery. The normal coronary artery appears as two

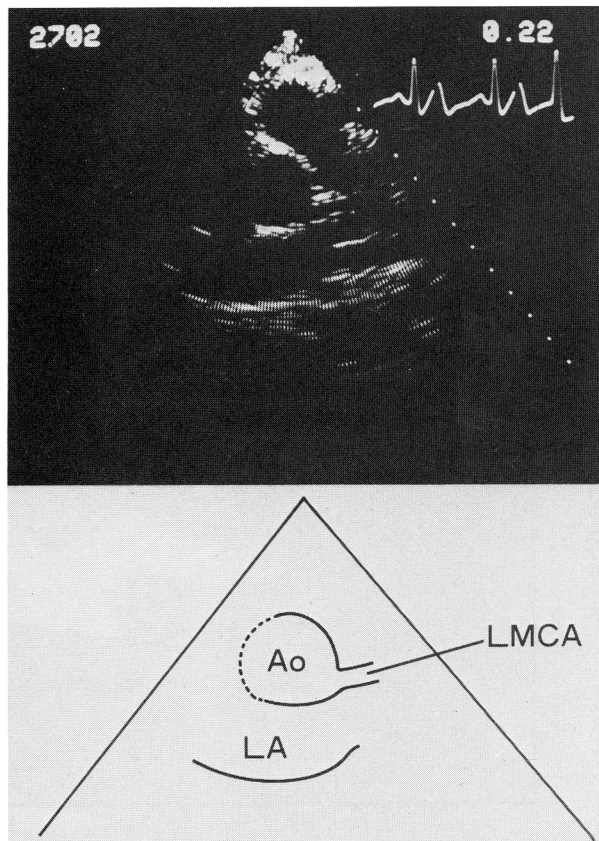


FIGURE 1. Cross-sectional echocardiogram of the normal left main coronary artery (LMCA) obtained from a patient with a fistula between the left coronary artery and the pulmonary trunk. The artery appears as two parallel dominant linear echoes that seem to arise from the inferolateral portion of the aorta (Ao) and to extend in a slightly anterior and leftward direction. LA = left atrium.

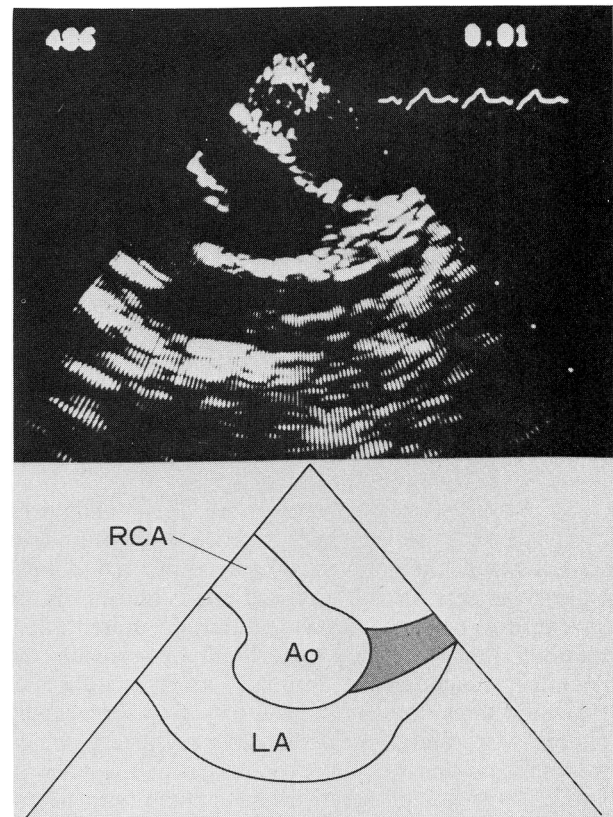


FIGURE 2. Cross-sectional echocardiogram from a patient with a fistula between the right coronary artery (RCA) and the right ventricle. The two parallel linear echoes of markedly wide lumen originating from the anterior portion of the aorta (Ao) are clearly shown. LA = left atrium.

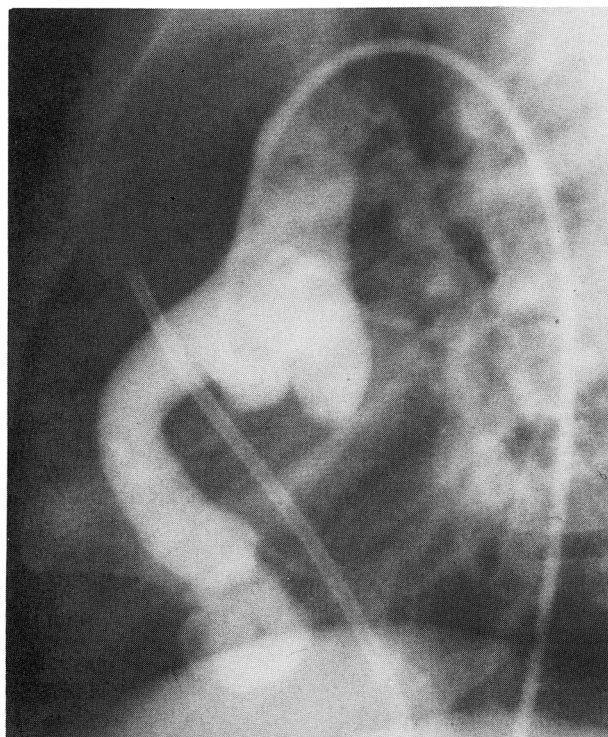


FIGURE 3. Angiogram corresponding to the cross-sectional echogram in figure 2. The right coronary artery is markedly dilated.

dominant parallel linear echoes, with a clear space representing the lumen of the vessel. Obstruction was defined using the criterion of luminal narrowing identified by a break in the continuous luminal space. The aneurysmal lesion appears as a large, circular, echo-free area with clearly definable boundaries. This study demonstrates that real-time, cross-sectional echocardiography is useful in visualizing the dilated right or left main coronary artery in patients with coronary artery fistula. The dilated main coronary artery appears as two parallel echoes of wide lumen arising from the aorta in the region of the involved artery. The distance between the two parallel echoes corresponded well to the angiographically estimated diameter of the main coronary artery.

The diagnosis of coronary artery fistula should be suspected in a patient with a precordial continuous murmur, which is often mistakenly attributed to a patent ductus arteriosus;⁵⁻⁸ the continuous murmur is the hallmark of coronary artery fistulas. At present, aortography and coronary arteriography provide the definitive diagnosis of coronary artery fistula and typically show the involved artery to be markedly dilated. The dilatation of the coronary artery, which was present in the majority of our patients with fistulas, was not observed in any patient with patent ductus arteriosus. Noninvasive visualization of the dilated coronary vessel is therefore of great value in distinguishing the two lesions. However, the dilatation of proximal coronary arteries could be caused by other conditions, including coronary artery aneurysms or anomalous origin of the coronary arteries. There-

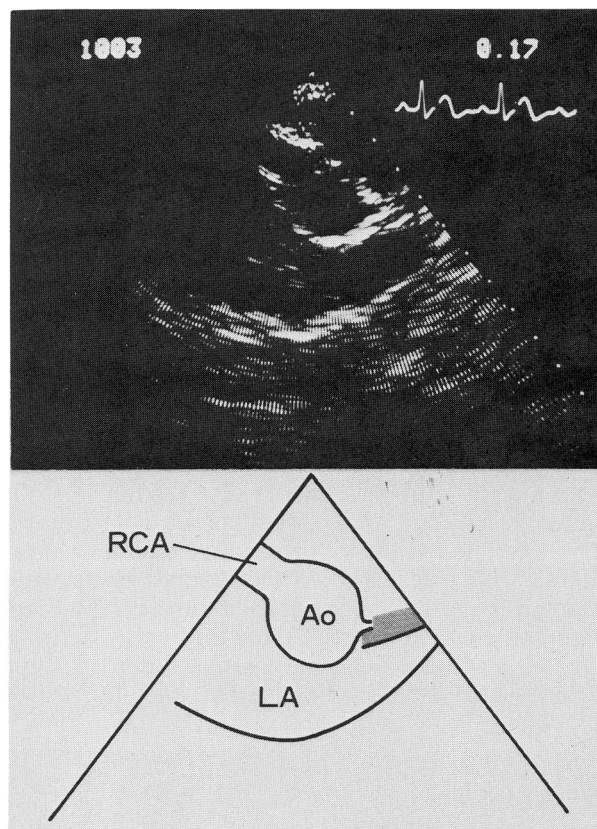


FIGURE 4. Cross-sectional echocardiogram from a patient with a fistula between the right coronary artery (RCA) and the right atrium. The RCA is moderately dilated. Ao = aorta; LA = left atrium.

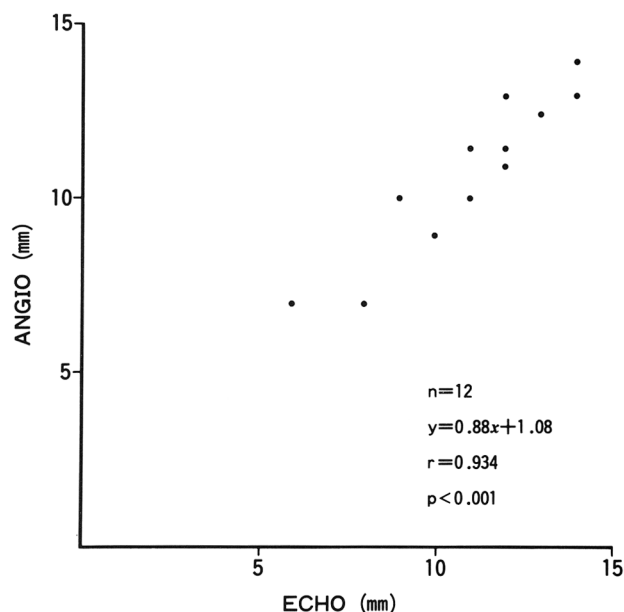


FIGURE 5. Relationship between the cross-sectional echocardiographic measurement (ECHO) and the diameter of the main coronary arteries determined by angiography in the 12 patients with a fistula of the dilated main coronary artery. The correlation is extremely good ($r = 0.934$, $p < 0.001$). ANGIO = angiographic measurement.

fore, cross-sectional echocardiographic visualization of dilated proximal coronary arteries alone does not indicate the presence of a coronary artery fistula. It is often difficult to distinguish a coronary artery fistula from a coronary artery aneurysm or anomalous origin of the coronary arteries.

There are several problems in visualizing the coronary arteries using cross-sectional echocardiography. First, satisfactory visualization of the left main coronary artery is not possible in many patients.⁴ The ultrasonic study is difficult if the patient is obese, has pulmonary emphysema or a large anteroposterior chest diameter. However, technically satisfactory studies of the left main coronary artery may be performed in young normal adults⁴ or patients with coronary artery aneurysms.² Adequate visualization of the coronary arteries appears to be facilitated when they become enlarged. We satisfactorily visualized the coronary artery in each of the 12 involved arteries.

Second, the technique can show only the proximal portions of the coronary arteries. It is not obvious whether the left anterior descending or circumflex coronary artery branches or the distal right coronary artery can be adequately visualized using this technique. The coronary artery in this condition, however, becomes dilated entirely from the most proximal portion to the entry site, if it occurs. Therefore, the technique could be useful in detecting the presence or absence of the dilated coronary artery and might prevent unnecessary angiography.

Finally, since the coronary artery moves in and out of the plane of the cross-sectional scan, analysis of

a number of still frames is required to visualize the involved coronary artery clearly. Again, frequent changes in transducer angulation are necessary in the more adequate visualization of the coronary arteries.

This study shows that cross-sectional echocardiography is a useful noninvasive technique for visualizing the dilated coronary arteries and can be used to distinguish coronary artery fistulas from patent ductus arteriosus.

References

1. Weyman A, Feigenbaum H, Dillon JC, Johnston KW, Eggleton RC: Noninvasive visualization of the left main coronary artery by cross-sectional echocardiography. *Circulation* **54**: 169, 1976
2. Yoshikawa J, Yanagihara K, Owaki T, Kato H, Takagi Y, Okumachi F, Fukaya T, Tomita Y, Baba K: Cross-sectional echocardiographic diagnosis of coronary artery aneurysms in patients with mucocutaneous lymph node syndrome. *Circulation* **59**: 133, 1979
3. Chen CC, Morganroth J, Ogawa S, Mardelli TJ: Detecting left main coronary artery disease by apical, cross-sectional echocardiography. *Circulation* **62**: 288, 1980
4. Chandraratna PAN, Aronow WS: Left main coronary arterial patency assessed with cross-sectional echocardiography. *Am J Cardiol* **46**: 91, 1980
5. Davis C Jr, Dillon RF, Fell EH, Gasul BM: Anomalous coronary artery simulating patent ductus arteriosus. *JAMA* **160**: 1047, 1956
6. Engle MA, Goldsmith EI, Holswade GR, Goldberg HP, Glenn F: Congenital coronary arteriovenous fistula. Diagnostic evaluation and surgical correction. *N Engl J Med* **264**: 856, 1961
7. Ernst CB, Klassen KP, Ryan JM: Vascular malformation overlying the pulmonary artery simulating a patent ductus arteriosus. *Circulation* **23**: 759, 1961
8. Nunn DB, Thrower WB, Boone JA, Lipton M: Coronary arteriovenous fistula simulating patent ductus arteriosus. *Am Surg* **28**: 476, 1962