

Quantitation of Regional Cardiac Function by Two-dimensional Echocardiography

I. Patterns of Contraction in the Normal Left Ventricle

ROBERTO V. HAENDCHEN, M.D., H.L. WYATT, PH.D., GERALD MAURER, M.D.,
WERNER ZWEHL, M.D., MORAYE BEAR, M.A., SAMUEL MEERBAUM, PH.D.,
AND ELIOT CORDAY, M.D.

SUMMARY Regional differences in wall motion and wall thickening were quantitated in the normal left ventricle using two-dimensional echocardiography (2-D echo). Using a computer-aided system, the left ventricle was subdivided in a standardized manner into 40 segments of five 2-D echo short-axis cross sections from the mitral valve level to the low left ventricle or apex. Measurements of sectional and segmental cavity areas, muscle areas and endocardial as well as epicardial perimeters, allowed assessment of contractile function using such indexes as endocardial systolic fractional area change (FAC), wall thickening (WTh), and circumferential fiber shortening (shortening). In 50 normal anesthetized, closed-chest dogs (including 10 studies in the conscious state) and in 32 normal humans, left ventricular contractile function increased significantly from base to apex. Thus, in anesthetized dogs, sectional FAC, WTh and shortening increased from left ventricular base to apex as follows: $39.4 \pm 5.1\%$ to $61.6 \pm 7.2\%$, $20.5 \pm 6.6\%$ to $46.7 \pm 11.5\%$ and $22.7 \pm 3.4\%$ to $35.4 \pm 5.9\%$, respectively. Similar trends were noted in conscious dogs. In man, sectional FAC, WTh and shortening also increased from the mitral valve to the low left ventricular level: $38.8 \pm 3.3\%$ to $60.7 \pm 4.5\%$, $23.9 \pm 5.6\%$ to $28.9 \pm 7.6\%$ and $21.4 \pm 5.0\%$ to $30.6 \pm 5.6\%$, respectively. Detailed segmental analysis in individual cross sections also revealed regional differences in contraction. Generally, contraction was most vigorous in posterior regions of the left ventricle. The septal regions exhibited lowest contraction at the base, but also the greatest increase from base to apex, both in the canine and human. Lateral regions did not show significant changes along the length of the left ventricle. Diastolic wall thickness also varied. We conclude that contraction in the normal left ventricle cannot be assumed to be uniform or symmetrical. These normal regional differences in function should be taken into account when evaluating altered physiologic states and in studying effects of therapeutic interventions.

FOR MANY YEARS cardiologists have assumed that the pattern of contraction in the normal left ventricle is concentric and uniform, classically defined as synergic motion.¹ Most of the earlier studies aimed at characterizing ventricular function were therefore based on models and assumed myocardial fiber structure consistent with uniform contraction.^{2,3} However, animal investigations have shown that the distribution of fiber angles is complex and changes during systolic contraction; endocardial and epicardial fibers tend to be oriented longitudinally and midwall fibers circumferentially.⁴ A study by Greenbaum et al.⁵ indicates that the human cardiac fiber architecture is even more complex than previously thought. Thus, models based on uniform wall motion may not adequately describe LV function in normal states, a prerequisite for studying altered physiologic conditions. Clinical studies using cineventriculography in man have indicated that myocardial performance in the normal left ventricle is

nonuniform,^{6,7} and noninvasive examination with M-mode echocardiography have demonstrated heterogeneity of myocardial wall dynamics.⁸ This nonuniformity was verified through detailed investigation in conscious and anesthetized dogs, using sonomicrometry to quantitate regional contractile function.⁹

The present study was undertaken to comprehensively map and assess regional patterns of contraction in both the canine and human normal left ventricle noninvasively. Two-dimensional echocardiography (2-D echo) appeared to be most satisfactory for comprehensive quantitative assessment of segmental function from base to apex and around the circumference of the left ventricle.

Methods

Experimental Study

Fifty healthy mongrel dogs (weight 22–35 kg) were anesthetized with morphine (1.2 mg/kg i.m.) followed by pentobarbital (25 mg/kg i.v.). Respiration was maintained with a Harvard respirator pump after endotracheal intubation. The dogs were selected from a larger number in our laboratory, based on a 2-D echo, short-axis, cross-sectional image quality that permitted complete visualization of both endo- and epicardial interfaces of the left ventricle. In 10 of the 50 dogs, echocardiograms were also obtained before the anesthetic agents were administered.

A mechanical 90° ultrasonic sector scanner (ATL, Mark III or 300) was used for the 2-D echo studies. The left ventricle was imaged with the dog lying in a

From the Division of Cardiology, Department of Medicine, Cedars-Sinai Medical Center, and the Department of Medicine, University of California, Los Angeles School of Medicine, Los Angeles, California.

Supported in part by NHLBI grants HL-17651-08 and HL-14644-09 from the NIH, and by the Ahmanson Foundation, the W.M. Keck Foundation, Mr. and Mrs. Nicolai Joffe, Mrs. Jules Stein, Mr. and Mrs. E.E. Fogelson, Mr. Beldon Katleman, Mr. and Mrs. Randolph Schott, Mr. and Mrs. Harry Roman, Mrs. Dorothy Forman, Mr. J.C. Dunas, and Ms. Joan and Mrs. Pearl Borenstein, Los Angeles, California.

Address for correspondence: Eliot Corday, M.D., Halper Research Building, Cedars-Sinai Medical Center, 8700 Beverly Boulevard, Los Angeles, California 90048.

Received December 31, 1982; revision accepted March 14, 1983.
Circulation 67, No. 6, 1983.

right lateral position and the transducer placed underneath the chest wall.¹⁰

Human Subjects

Thirty-two normal humans (mean age 34 years, 14 females) with superior 2-D echo parasternal short-axis views of the left ventricle were selected from hospital employees, as well as patients undergoing 2-D echo in our outpatient laboratory. Most of the latter patients were young females, in whom echocardiograms were performed to rule out mitral valve prolapse, and results found to be negative. All subjects were examined in a 30–60° left lateral position.

2-D Echo Views and Wall Motion Analysis

Several short-axis views from base to apex of the left ventricle were obtained using the parasternal window, in both dogs and humans (fig. 1). The mitral valve level (MV) was defined as a short-axis section in which both valvular leaflets could be well seen; the high papillary muscle (HP) or chordae level as a section where subvalvular structures could still be visualized, especially in systole; the midpapillary level (MP) as a section through the body of the papillary muscles, with no chordae tendineae seen during diastole or systole; the low papillary muscle level (LP) as a section in which papillary muscles appeared smaller and protruded less into the left ventricular cavity. These cross sections were obtained from the same intercostal space by changing transducer angulation. A low left ventricular level (LLV) was identified as a section between

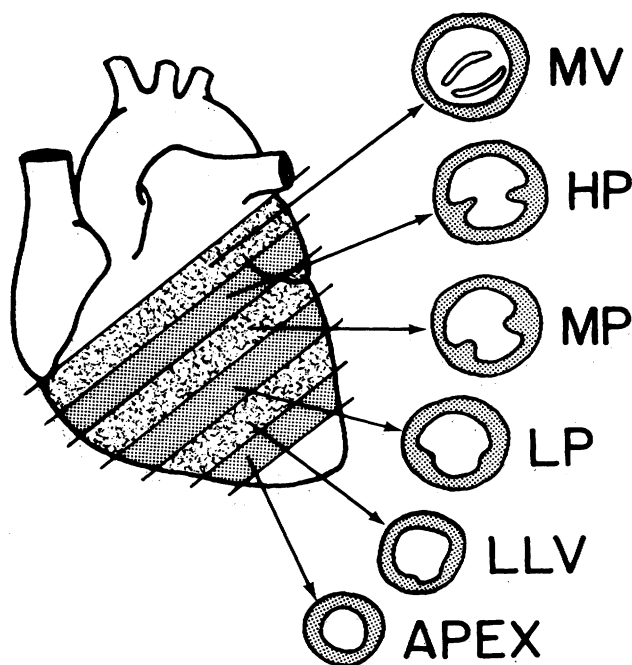


FIGURE 1. The two-dimensional echocardiographic short-axis cross-sectional views of the left ventricle used in this study. MV = mitral valve level; HP = high papillary muscle (or chordae tendineae) level; MP = midpapillary muscle level; LP = low papillary muscle level; LLV = low left ventricular level; Apex = apical short-axis level.

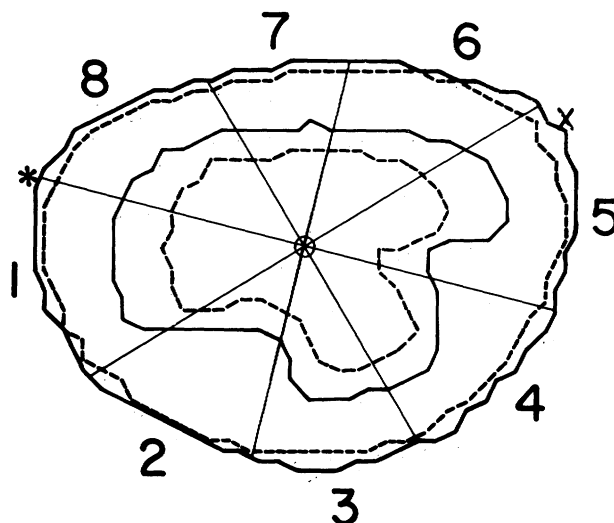


FIGURE 2. Computer-assisted outlines of epicardium and endocardium at end-diastole (solid lines) and end-systole (broken lines) from a left ventricular short-axis section at the high papillary muscle level in a normal dog. The reference system for segmental wall motion analysis is described in the text. O = endocardial diastolic area center; X = posterior junction. The asterisk represents the anterior junction of right ventricular free wall and septum.

the LP and the apex, with papillary muscles still seen. The apical short axis was defined as the section with the smallest luminal area, where no papillary muscles could be visualized. All six short-axis views were obtained in the 50 dogs. MV, HP and MP sections were obtained in all 32 humans. LP and LLV views were adequate in 27 and 14 cases, respectively. The apical short-axis view was satisfactory in a small number of humans, and therefore was not analyzed.

Images were recorded at 30 frames/sec on a video recorder (Panasonic NV8200). Wall motion analysis was initiated by outlining epi- and endocardial interfaces in end-diastolic and end-systolic stop frames using a video-disc system, which allows better appreciation of wall dynamics and thus improves interface delineation. End-diastolic frame was chosen as the largest and most circular short-axis section, and end-systolic as the smallest area, using the ECG as a guide. The largest end-diastolic areas generally coincided with the peak of the QRS or one frame thereafter (presumably in the isovolumic contraction phase), and end-systolic frames were usually near the end of the T wave. Images were manually traced and then digitized into a computer (PDP 11/34) for calculation of areas and perimeters. The leading-edge method was used to trace interfaces in all the images. Each short-axis was then subdivided into eight equal segments using an internal referencing system (fig. 2). To provide standardized subdivision of the sections, an indexing line was drawn from the diastolic endocardial geometric center to the anterior (in the dog) or posterior (in the human) junction of the right ventricular free wall and septum.

Left ventricular subsegments were pooled into re-

gions designated as posterior, anterior, septal or lateral. Since the septal wall usually encompassed three octants, it was further divided into anterior, middle and posterior aspects. Apical short-axis views were treated as single regions. Fixed referencing was used in anesthetized dogs because intrathoracic movement was minimal, except in apical sections, where a distinct shift toward the anterior wall was seen during systole. In humans, both fixed and floating axis systems were used for wall motion studies.

Correction for whole heart motion (translation) was performed in 10 humans by superimposing the endo- or epicardial area center. The results of segmental wall motion and wall thickening were then compared to results obtained using fixed axis. No attempt was made to correct for rotation of the left ventricle, primarily because there is at this time no universally accepted method to correct for this motion.

Indexes of Contractile Function

Three indexes of contractile function were derived from the short-axis sections: systolic fractional area change (FAC), wall thickening (WTh) and circumferential fiber shortening (shortening):

$$\text{FAC} = \frac{\text{EDA} - \text{ESA}}{\text{EDA}} \times 100,$$

where EDA = end-diastolic area and ESA = end-systolic area;

$$\text{WTh} = \frac{\text{WTes} - \text{WTed}}{\text{WTed}} \times 100,$$

where WTes = wall thickness at end-systole and WTed = wall thickness at end-diastole;

$$\text{Shortening} = \frac{\text{EDP} - \text{ESP}}{\text{EDP}} \times 100,$$

where EDP = end-diastolic perimeter and ESP = end-systolic perimeter.

Thus, FAC measures the extent of area change during systole in relation to the end-diastolic area, WTh the systolic change in wall thickness and shortening the extent of segmental perimeter shortening relative to its end-diastolic length.

FAC and shortening were calculated for both endocardium and epicardium. Because of the more circumferentially oriented myocardial fibers in the midwall, shortening was also calculated and expressed as the mean value between endo- and epicardial shortening. Wall thickness, perimeters and derived measurements were obtained from the short-axis sections excluding the papillary muscles; area measurements were calculated including as well as excluding papillary muscles. Wall thickness in each segment was derived by dividing the regional muscle area by the average segment perimeter. All measurements were obtained for both the overall sections (sectional function) as well as in each octant (segmental function), and expressed as percent, according to the formulas above. Absolute

values for area and perimeter change were also calculated. (EDA - ESA = absolute area change; EDP - ESP = absolute perimeter change.)

Reproducibility of 2-D Echo Measurements

Two-dimensional echocardiographic images were obtained by two or three echocardiographers, and sections were traced by two observers. The variability of cavity area measurements in the dog and wall thickness in humans was studied over a wide range of values and expressed as mean percent error (first observer - second observer/average of both observers).

Statistical Analysis

Experimental Study

Nonparametric statistical techniques were used to analyze the data. Because of the repeated-measures design, the Wilcoxon-pairs, signed-ranks test and Friedman's two-way analysis of variance (ANOVA) were the two main statistical tests.¹¹ Wilcoxon's test was used when two treatment conditions were analyzed (i.e., conscious vs anesthetized dogs). Friedman's test was used when more than two conditions were compared (i.e., segments 1, 3, 5 and 7). If the Friedman's test demonstrated a significant result ($p \leq 0.05$, two-tailed), the Newman-Keuls multiple comparison procedure with $\alpha = 0.05$ was conducted to identify the significant differences.

Human Study

Data measured in humans were analyzed by a one-way ANOVA with repeated measures or Hotelling's T test.¹² Significant ANOVA results ($p \leq 0.05$, two-tailed) were followed by Tukey's multiple comparison procedure, while significant Hotelling T results were followed by Scheffe-type simultaneous confidence intervals with α levels set at 0.05. The analysis was conducted in two phases. The first phase consisted of the sectional analysis. Because fewer patients had data for the LP and LLV sections, the analysis for sectional function was additionally conducted in two separate parts. First only the MV, HP and MP views were contrasted using the entire sample of 32 patients. As the second part, all five sections were contrasted, which reduced the number of patients in the analysis to 14. The second phase consisted of the analysis for segmental function (segment 1 vs 3 vs 5 vs 7).

The agreement between the fixed method and the epicardial or endocardial area center superimposition methods for segmental wall motion studies was assessed using the intraclass correlation. To further verify the comparability between the methods, a Wilcoxon paired-sample test was used, and the intraclass correlations for the fixed and endocardial superimposition methods were compared with the correlation for the fixed and epicardial superimposition methods for both FAC and WTh.

Results

Left Ventricular Sectional Function

The results of sectional FAC, shortening and WTh

in anesthetized dogs are shown in figure 3 and the results in normal humans are shown in figure 4. Endocardial contraction in both canine and human left ventricles increases significantly from base to apex, while epicardial FAC and shortening were much lower and relatively uniform along the length of the left ventricle. Figure 5 illustrates in 10 dogs the differences in sectional FAC between conscious and anesthetized states. The general trends were similar, but contraction was more vigorous during the conscious state. The mean heart rate was 79.0 ± 21.2 (\pm SD) in the conscious and 86.2 ± 10.3 in the unconscious state (NS).

The absolute changes in sectional area and perimeters in short-axis views in 10 conscious dogs and in 14 humans are tabulated in table 1. Although endocardial FAC was significantly smaller at basal levels, absolute area changes in humans did not vary significantly from the MV to LLV level, indicating that the regional contribution to stroke volume is relatively uniform along the left ventricle, but starts to decrease near the apex. The latter was best appreciated in the dogs, in which an apical short-axis view could be studied. For the absolute changes in perimeter, the basal cross-sections presented again with the lowest values, and the largest absolute changes were seen in the middle left ventricle (MP and LP sections).

Inclusion and Exclusion of Papillary Muscles in Wall Motion Studies

The effect of including or excluding papillary muscles in area measurements in the derivation of endocardial FAC in short-axis sections is shown in figure 6. FAC in sections containing papillary muscles (HP to LLV) is smaller when these structures are excluded for endocardial outline. However, the base-to-apex trends are similar whether papillary muscles are included or excluded.

Left Ventricular Segmental Function

The regional differences in contraction around the circumference at different levels of the LV are shown in figures 7–10. Segmental FAC is presented including papillary muscles in the dogs (fig. 7) and excluding them in the humans (fig. 8). Regional WTh is illustrated in figures 9 and 10, in both canine and humans, respectively. Segment-to-segment variations in mean

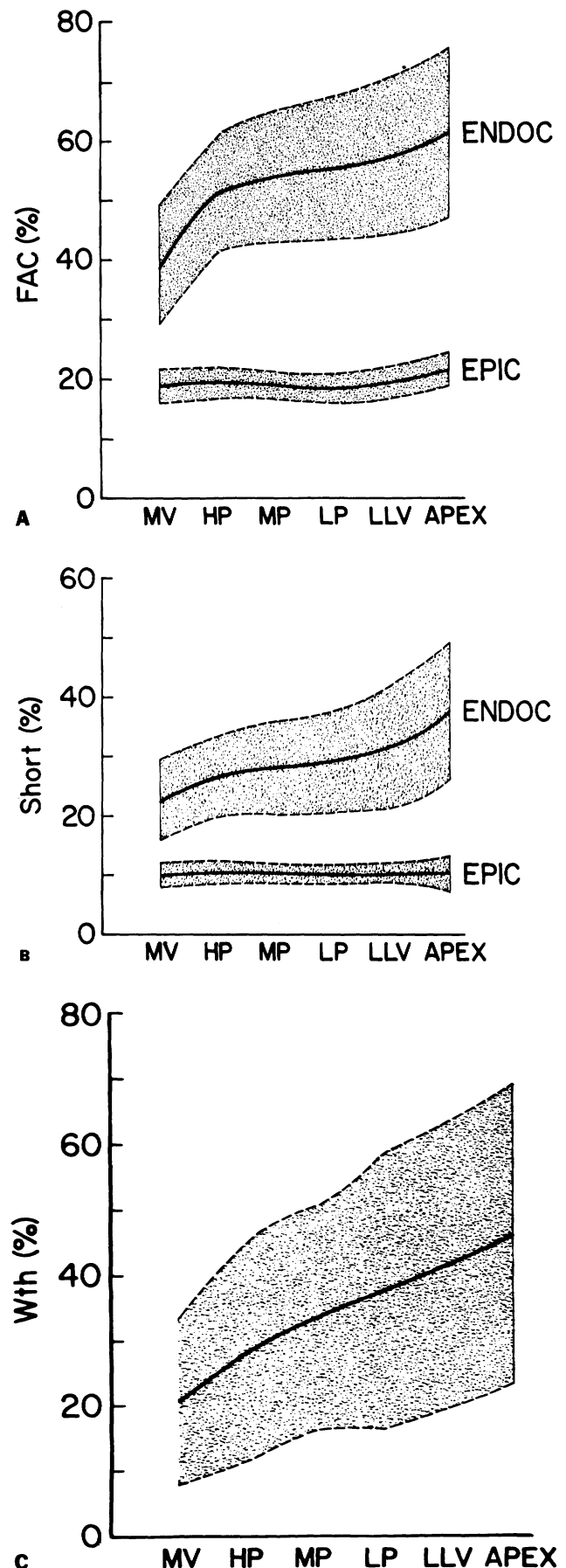


FIGURE 3. Base-to-apex variations of left ventricular sectional function in 50 anesthetized intact dogs. Results are expressed as mean (solid line) \pm 2 SD (stippled areas above and below the solid line). (A) Epicardial (EPIC) and endocardial (ENDOC) fractional area change (FAC). There was a statistically significant difference in ENDOC FAC between the various left ventricular short-axis levels, except for HP vs MP, MP vs LP, and LP vs LLV. (B) ENDOC and EPIC circumferential fiber shortening (Short). ENDOC SHORT was significantly different between all levels except for HP vs MP and MP vs LP. (C) Systolic wall thickening (WTh), again showing significantly increased contractile function in lower left ventricular sections. All levels were significantly different from each other, except for LP vs LLV. Abbreviations are as in figure 1.

values were generally greater for FAC than for WTh measurements, particularly in the dog, but standard deviations for WTh were always larger than those for FAC measurements.

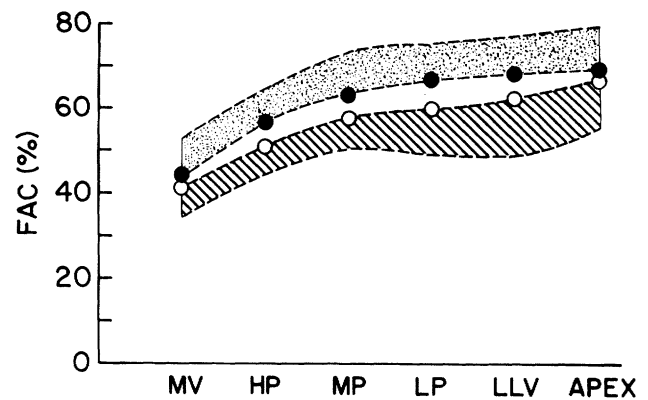
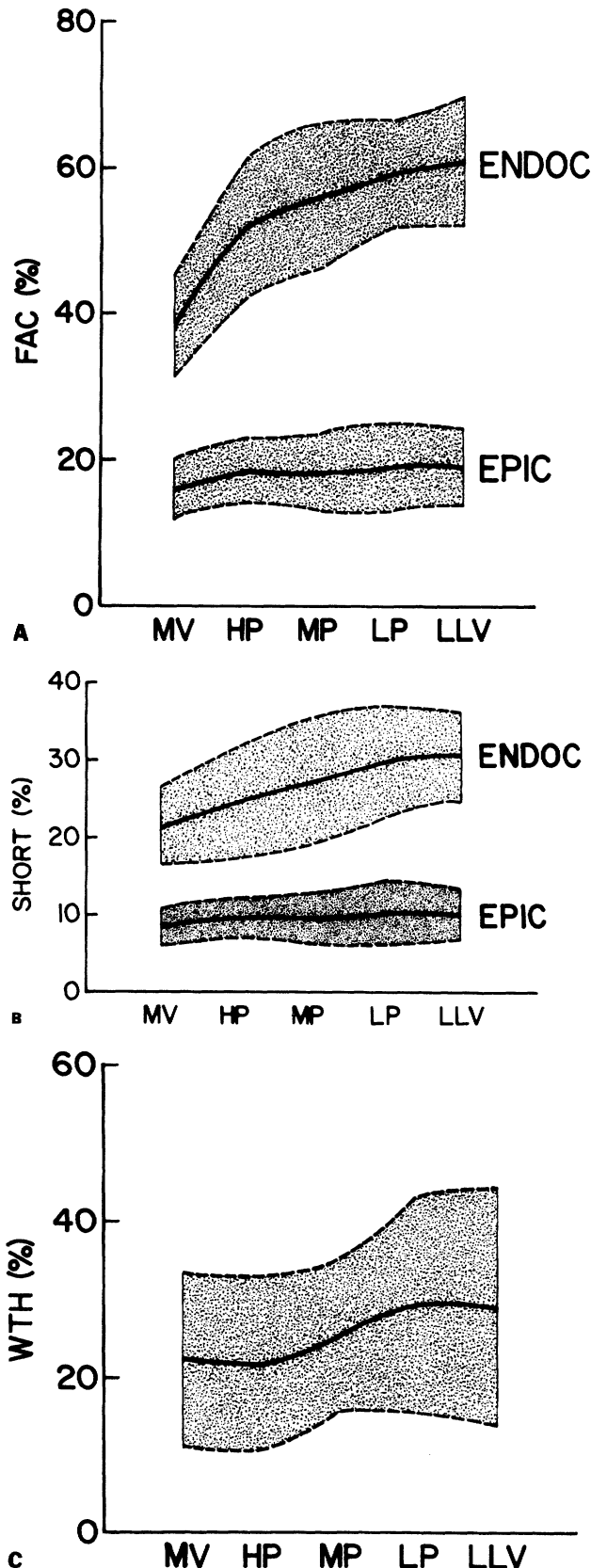


FIGURE 5. Differences in sectional ENDOC FAC from base to apex of the left ventricle between conscious and anesthetized state in 10 dogs. Results are expressed as mean (filled circles) plus 2 sd in conscious state and mean (open circles) minus 2 sd in anesthetized state. FAC was significantly higher in the conscious state at the HP, MP, LP and LLV levels. Abbreviations are as in figures 1 and 3.

In general, the trends in FAC, WTh and shortening were similar in most regions of the left ventricle. The most repeatable pattern of segmental contraction was noted in septal regions, which exhibited a consistent and stepwise increase in FAC and WTh from basal to the lower left ventricular levels. FAC and WTh in the humans increased from the MV to LLV level, by 35.1% and 41.9% in the anteroseptal segment, by 40.3% and 40.0% in the midseptum, and by 35.5% and 35.8% in the posterior septum. Septal regions exhibited the lowest contractile indexes at the base of the left ventricle (MV and HP levels), compared with other regions. Conversely, lateral regions presented a lesser degree of variations from level to level. An increase in function from base to apex was also seen in the posterior and anterior segments, although less than those in septal regions. Figure 11 summarizes results of segmental end-diastolic wall thickness and midwall shortening in 40 regions of the left ventricle in the 14 humans in whom five distinct short-axis sections were obtained.

Fixed vs Floating Axis for Segmental Wall Motion and Thickness Analysis

The intraclass correlation coefficient for the different methods are presented in table 2 for both FAC and WTh. The correlations were tested at the MV, MP and LP levels for segments 1, 3, 5 and 7 in 10 normal humans chosen at random. All coefficients were significantly different from zero at the $p < 0.05$ level,

FIGURE 4. Variations in sectional function from base to low level of the left ventricle in 14 normal humans. Results are presented as mean (solid line) \pm 2 sd. (A) EPIC and ENDOC FAC; statistical analysis (STAT) for ENDOC FAC indicated significant differences: MV < HP, MP, LP, LLV; HP < LP, LLV; MP < LLV. (B) EPIC and ENDOC SHORT; STAT for ENDOC SHORT: MV < MP, LP, LLV; HP < LP, LLV; MP < LP, LLV. (C) WTh; STAT: HP < LP, LLV; MV < LP. Abbreviations are as in figures 1 and 3.

TABLE 1. Relationship Between End-diastolic Area and Absolute Changes in Area, and Between End-diastolic Perimeter and Absolute Changes in Perimeter in Left Ventricular Short-axis Sections from Base to Apex

	MV	HP	MP	LP	LLV	APEX
Conscious dogs (n = 10)						
AAC/EDA (cm ²)	6.1/14.8	6.2/12.1	7.3/12.7	7.2/12.3	6.6/10.7	5.4/8.2
APC/EDP (cm)	3.3/14.0	3.7/14.2	4.5/14.7	4.3/14.1	4.5/13.0	4.2/10.8
Humans (n = 14)						
AAC/EDA (cm ²)	6.3/16.3	6.4/12.5	6.6/11.7	6.7/11.2	6.0/9.8	
APC/EDP (cm)	3.2/14.6	3.5/14.4	3.7/13.9	4.1/13.5	3.8/12.3	

Values are mean.

Abbreviations: n = no. of observations; AAC = absolute change in area; EDA = end-diastolic area; APC = absolute change in perimeter; EDP = end-diastolic perimeter; MV = mitral valve level; HP = high papillary muscle level; MP = midpapillary muscle level; LP = low papillary muscle level; LLV = low left ventricular level; APEX = apical short-axis level.

except the values for fixed vs endocardial superimposition methods for FAC at the MV level midseptal wall (segment 7) and LP level posterior wall (segment 1). The correlations for fixed vs epicardial superimposition methods were uniformly higher ($p < 0.03$) than those for the fixed vs endocardial superimposition for FAC measurements. There was no significant difference between these correlations for WTh.

Interobserver Variability of 2-D Echo Measurements

The interobserver variability of measurements for sectional and segmental areas as well as wall thickness is given in table 3. Variability for end-systolic areas was larger than for end-diastolic areas, but within acceptable limits. Interobserver variability for wall thickness, measured at different LV regions is also

indicated, showing good agreement between the observers (less than 8% error).

Discussion

Base-to-Apex Variations in Left Ventricular Contractile Function

Both human and canine 2-D echo studies revealed that contraction increases gradually from base to apex of the left ventricle. FAC derived by 2-D echo, which characterizes endocardial motion, was about 60% near the apex for both human and dog, vs about 40% at the base of the left ventricle. Although relative contraction appears to be greatest at the left ventricular apex, it contributes less toward stroke volume because the absolute systolic change in cross-sectional area is smallest near the apex (table 1).

Although endocardial FAC, shortening and WTh increase in the direction of the apex, epicardial FAC and shortening were relatively uniform along the entire left ventricle. Similar findings were reported by LeWinter et al.,⁹ who used sonomicrometry in anesthetized and conscious dogs. Kong et al.,⁶ Leighton et al.,¹³ and Liedke et al.,⁷ who used cineventriculography in humans, also found an increase in endocardial shortening from base to apex. End-diastolic wall thickness measurements, recently validated by Wyatt et al.,¹⁴ also varied along the left ventricle, more so in dogs than in humans (fig. 11B).

The explanation for the base-to-apex variation in left ventricular function is not clear, even though several hypotheses can be postulated. LeWinter et al.⁹ conjectured that the greater apical shortening may be associated with longer sarcomeres at the left ventricular apex, as previously reported by Laks et al.¹⁵ Using M-mode echo in normal children, Shapiro and co-workers⁸ found larger fractional shortening at the papillary muscles than at the MV level and attributed this to the typical myocardial fiber structure in man, recently reported by Greenbaum et al.⁵ and previously studied in dogs by Streeter and colleagues.⁴ Thus, at the left ventricular base, the thicker layer of circumferentially oriented fibers (especially in the septum) could be responsible for the smaller shortening and thickening. At the papillary muscle level, the larger extent of inward motion may be due to a decrease in the thickness of the midwall circumferential fibers and an increasing num-

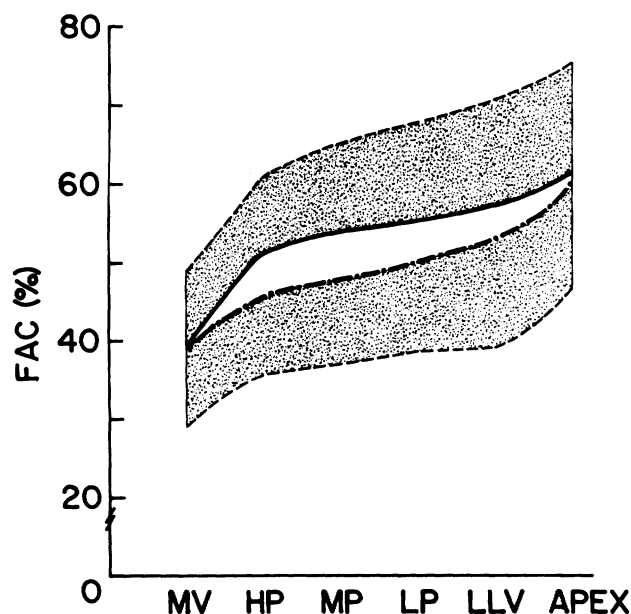


FIGURE 6. Differences in endocardial contraction (FAC) including or excluding the papillary muscles in left ventricular endocardial outlines, in short-axis views in 50 anesthetized dogs. Mean (solid line) FAC plus 2 SD including papillary muscles and mean (broken line) FAC minus 2 SD excluding papillary muscles are shown. Similar trends were observed in normal humans. See text for details. Abbreviations are as in figure 1.

ber of longitudinally oriented fibers, resulting in a more pronounced muscle thickening. As one approaches the apex, this middle layer becomes progressively thinner.⁵ Regional differences in contraction

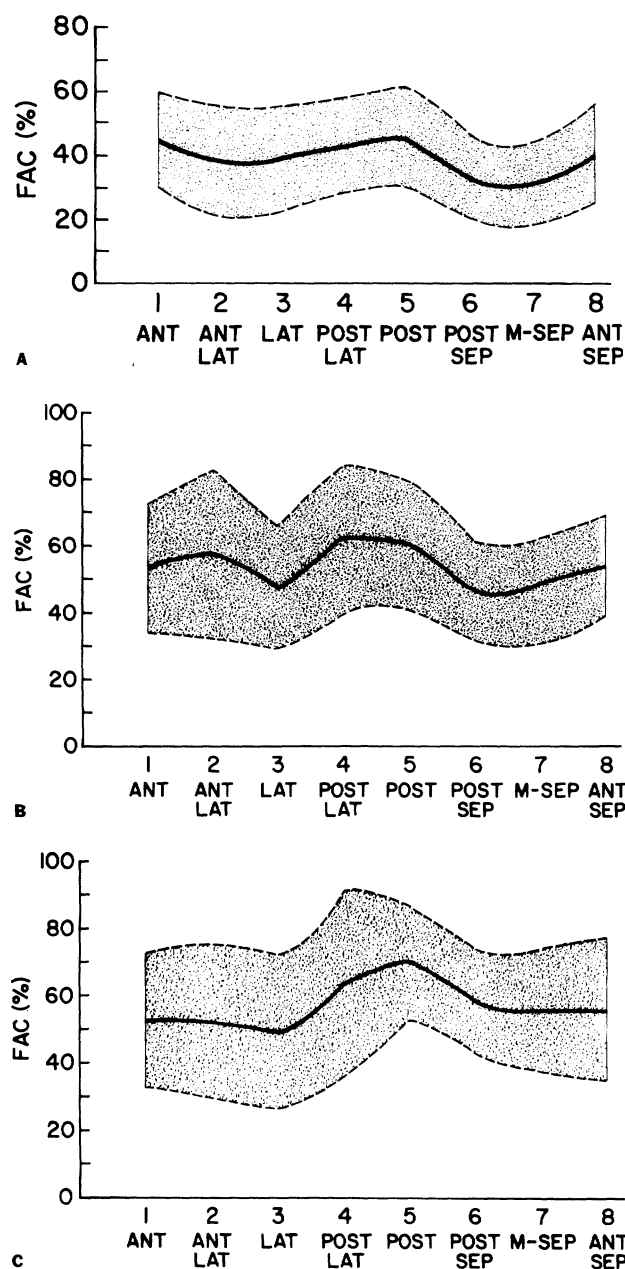


FIGURE 7. Regional differences in endocardial FAC around the circumference at three short-axis cross-sectional levels of the left ventricle in 50 anesthetized dogs. Mean values for each region (solid line) \pm 2 SD are shown. (A) At the MV level FAC was lowest in septal regions (STAT: segment 7 < 1, 3, 5; segment 3 < 1, 5). (B) At the MP level FAC was highest in posterior regions (STAT: segment 3 < 1, 5; segment 7 < 1, 5; segment 1 < 5). (C) At the LLV level FAC was again highest in posterior segments. (STAT: segment 3 < 5, 7; segment 1 < 5, segment 7 < 5). Note an increasing FAC in septal regions from MV to LLV levels. ANT = anterior; LAT = lateral; POST = posterior; SEPT = septal wall; M = mid; STAT = statistical analysis. Other abbreviations are as in figures 1 and 3.

could be related to temporal¹⁶ or spatial heterogeneity¹⁷ of myocardial blood flow, previously reported in the normal canine left ventricle. Marcus et al.¹⁷ showed that the apex and endocardium receive more flow than other portions of the left ventricle.

The presence of papillary muscles in some of the short-axis sections results in an apparent enhancement

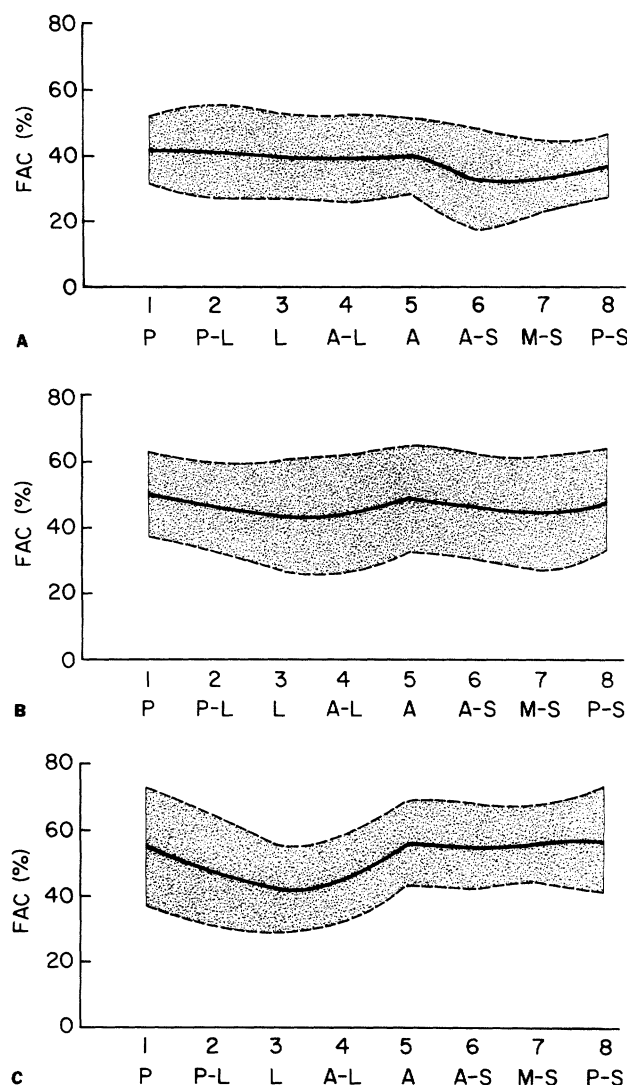


FIGURE 8. Regional differences in endocardial FAC in normal humans. (A) FAC at the MV level, also showing lower FAC in septal regions (STAT: segment 7 < 1, 3, 5; $n = 32$). (B) At the MP level showing higher FAC in posterior segments, compared to septal and lateral. (STAT: segment 7 < 1; segment 3 < 1, 5; $n = 32$). (C) At the LLV level the septal segments contract more vigorously compared to MV and MP levels. (STAT: segment 3 < 1, 5, 7; $n = 14$). P = posterior; L = lateral; A = anterior; S = septal wall; M = mid. n = number of observations. Other abbreviations are as in figures 1 and 3. Compared with studies in dogs (fig. 7), contraction patterns in the human exhibited similar trends. The smaller SD and lower segment-to-segment variations in the human may be due to exclusion of papillary muscles. Anterior and posterior segments in the human appear inverted in the echocardiograms. (In the dog, the echo transducer is underneath the chest wall.)

of FAC and thus in left ventricular ejection fraction (fig. 6). This is probably related to the observation that the papillary muscle during systole appears relatively larger than in diastole.

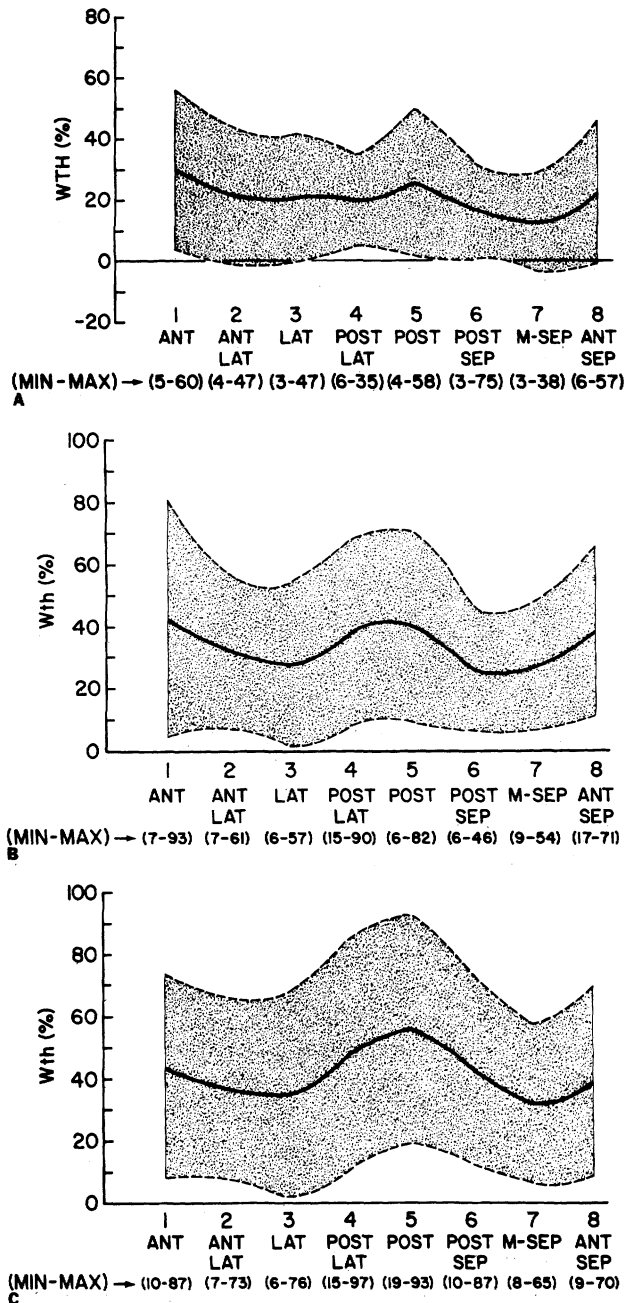


FIGURE 9. Regional variations in wall thickening (WTh) around the circumference in three distinct short-axis of the left ventricle in 50 anesthetized dogs. Mean values (solid line) \pm 2 sd are shown. The minimum (MIN) and maximum (MAX) WTh values encountered in each region are also indicated. (A) At the MV level, indicating decreasing WTh in septal regions. (STAT: segment 7 < 1, 3, 5; segment 3 < 1, 5.) (B) At the MP level, posterior segments show higher WTh. (STAT: segment 1 and 5 > 3, 7.) (C) At the LLV level the posterior regions exhibited the highest regional WTh. (STAT: segments 7 and 3 < 1, 5; segment 1 < 5.) Abbreviations are as in figures 1, 3 and 7.

Recognition of the base-to-apex variations in contractile function is important, not only for identification and quantitation of dysfunction at specific levels of the LV, but also because there is some evidence from recent experimental studies that the functional response to loading, heart rate, and therapeutic interventions is not uniform, and may also vary along the length of the left ventricle.¹⁸

Segmental Wall Motion Patterns

Segmental heterogeneity of contraction in the normal left ventricle has also been reported by several

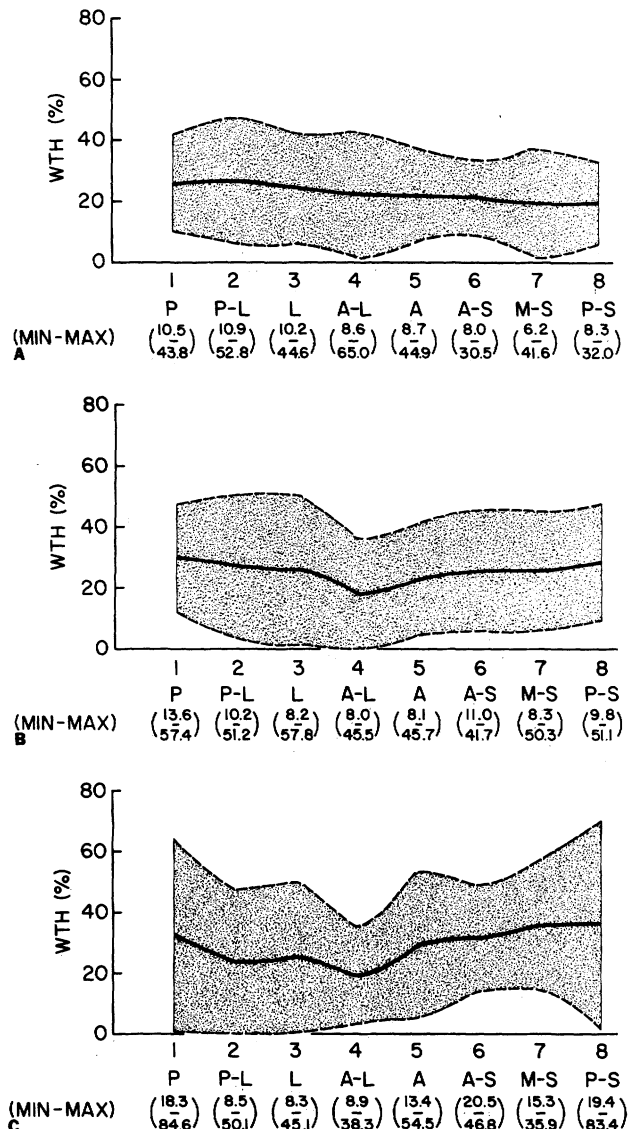


FIGURE 10. Regional variations in wall thickening (WTh) in normal humans. (A) Regional WTh at the MV level, with septal regions showing the smallest values. (STAT: segment 7 < 1, 3; n = 32). (B) At the MP level posterior segments exhibited higher WTh. (STAT: segment 1 > 5; n = 32). (C) At the LLV level WTh increases in septal regions and shows almost no change in lateral regions compared to MV and MP levels. (STAT: no significant differences between segments 1, 3, 5 and 7; n = 14). Abbreviations are as in figures 1, 3 and 8.

investigators using various techniques. Biplane cine-angiograms indicated a greater extent of shortening in the free wall than in septal regions.⁶ Sniderman et al.¹⁹ and Ingels et al.²⁰ found that contraction along the posterior wall was greater than in the anterior wall in normal subjects, particularly in the middle and apical surfaces of the left ventricle. Gelberg et al.²¹ studied 60° left anterior oblique ventriculograms and found a larger extent of radial shortening in the lower septum than in the middle and basal septum, whereas Klausner et al.²² reported lack of homogeneity of wall motion in normal patients both in systole and in diastole. Reports using 2-D echo in both normal canine and human left

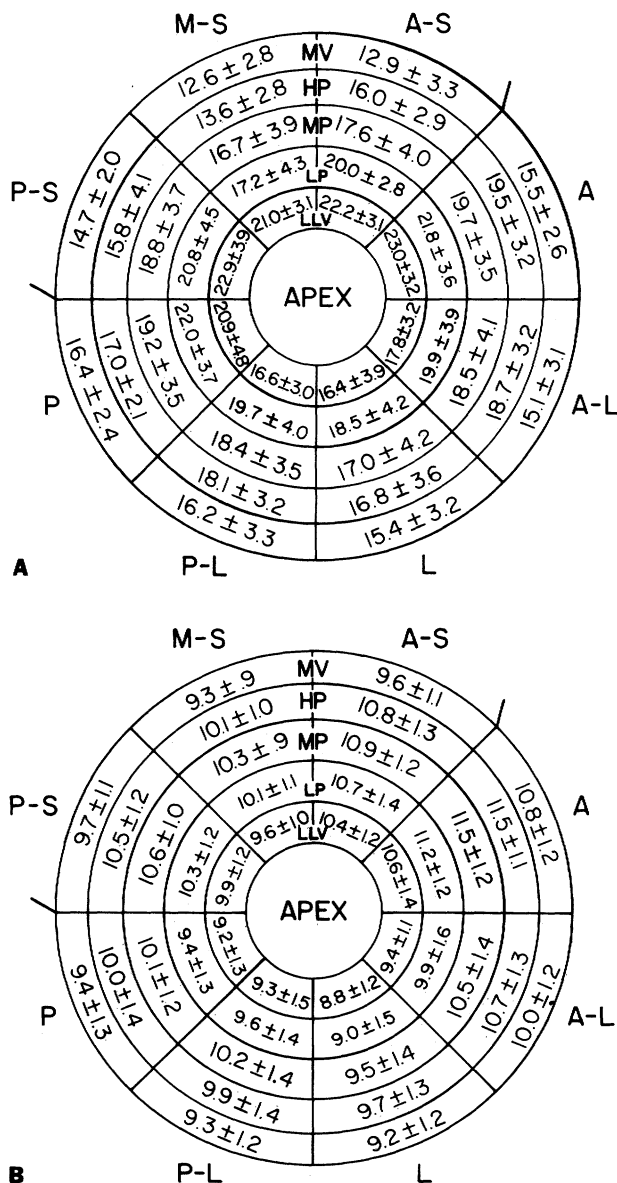


FIGURE 11. Mapping of regional patterns of (A) midwall circumferential fiber shortening and (B) end-diastolic wall thickness (mm) in 40 segments of the left ventricle in 14 normal humans. Each concentric ring represents one short-axis level of the LV. Abbreviations are as in preceding figures. Values are mean \pm SD.

TABLE 2. Correlation Coefficients Relating Fixed- vs Floating-axis Methods for Segmental Wall Motion and Thickness Analysis

	Fixed vs EP Sup		Fixed vs EN Sup	
	FAC	WTh	FAC	WTh
MV level				
Post wall (segment 1)	0.823	0.999	0.654	0.999
Lat wall (segment 3)	0.847	0.999	0.604	0.996
Ant wall (segment 5)	0.863	0.991	0.638	0.999
Midsep wall (segment 7)	0.514	0.999	0.297*	0.999
MP level				
Post wall (segment 1)	0.871	0.999	0.593	0.997
Lat wall (segment 3)	0.962	0.999	0.841	0.995
Ant wall (segment 5)	0.910	0.996	0.730	0.980
Midsep wall (segment 7)	0.908	0.999	0.544	0.999
LP level				
Post wall (segment 1)	0.861	0.999	0.310*	0.996
Lat wall (segment 3)	0.908	0.999	0.605	0.989
Ant wall (segment 5)	0.931	0.999	0.697	0.993
Midsep wall (segment 7)	0.961	0.999	0.699	0.998

*Not significantly different from zero.

Abbreviations: FAC = fractional area change; WTh = wall thickening; Post = posterior; Lat = lateral; Ant = anterior; Midsep = midseptal; EP Sup = epicardial area center superimposition method; EN Sup = endocardial area center superimposition method; MV = mitral valve; MP = midpapillary; LP = low papillary.

ventricle also suggested heterogeneous regional myocardial performance.²³⁻²⁶

We found regional variations in endocardial motion and wall thickening, and also intersegmental variation in end-diastolic wall thickness (fig. 11B), which in itself has important clinical implications. Significant regional differences were also noted in midwall shortening (fig. 11A). Vatner²⁷ has recently shown that endocardial shortening decreases with as little as a 10–20% reduction in blood flow, but severe reduction in flow was required to completely abolish active regional shortening in conscious dogs. WTh might be more sensitive to reductions in blood flow, as shown by Gallagher et al.,²⁸ who demonstrated that 75% reduction in WTh can occur when perfusion to only the inner half of the myocardium is reduced.

Identification of Segmental Left Ventricular Dysfunction

Most studies of regional wall motion in the human applied invasive methods, which do not lend themselves for practical sequential studies. Also, in contrast to the relatively easy assessment of akinesis-dyskinesis, considerable disagreement persists with respect to

TABLE 3. Variability of Short-axis Area Measurements and Wall Thickness Between Two Trained Observers

	End-diastole	End-systole
Sectional areas (n = 25)	4.0 \pm 2.7%	7.1 \pm 6.0%
Segmental areas (n = 104)	6.6 \pm 5.0%	12.5 \pm 10.4%
Wall thickness (n = 52)	7.0 \pm 4.1%	6.0 \pm 4.4%

Values are mean \pm SD.

the most appropriate approach for quantifying regional hypokinesis.^{13, 19, 29, 30} The use of 2-D echo presents advantages over other techniques, including bedside and serial evaluation of cardiac function. Besides, wall thickening can be studied in various left ventricular regions. Considering that segmental wall motion abnormalities may be seen in conditions other than ischemic heart disease, particularly in septal regions (such as during pacing or right ventricular overload), WTh derived by 2-D echo could be a better index of regional myocardial performance. Furthermore, in no instance was wall thinning observed in this study. Another advantage of WTh is that it is not significantly affected by intrathoracic heart motions (table 2). Its present disadvantage is that it can be derived only from parasternal views, because of inadequate visualization of epi- or endocardial targets in apical views, which are generally more readily obtainable in patients with ischemic heart disease.

Enhanced computer methods of data acquisition and display should facilitate analysis and interpretation of segmental left ventricular function. Thus, we reported promising real-time computer modes in 2-D echo and have incorporated automatic edge-detection programs for wall motion analysis.³¹

Methods for Segmental Wall Motion Analysis

In a recent 2-D echo study, Parisi et al.³² found that a fixed-axis system was the most sensitive method for recognition of segmental left ventricular dysfunction in patients with coronary artery disease. Ingels et al.,³³ using implanted myocardial markers in man, and Vas et al.,³⁴ using digital subtraction angiography, also found the fixed axis most appropriate. In one of our studies, a fixed-axis method was validated using histochemical delineation of myocardial ischemia based on tissue glycogen depletion, and showed good agreement with regional left ventricular dysfunction by 2-D echo.³⁵ Use of a floating axis system may be desirable to correct for rotation and translation of the heart, but is complicated by the necessity of finding two internal landmarks that can be precisely identified during diastole and systole.

The method we used in this study expressed FAC and WTh in terms of sector area measurements, rather than linear changes along radii. It has been reported in 2-D echo³⁶ and ventriculographic studies²¹ that area measurements are more sensitive for detection of segmental wall motion abnormalities. The measurements average motions and thickness within each of a limited number of sectors, which provide a simplified method for studying regional cardiac performance. An alternative for studying wall motion is to use apical views. However, the problem with these views is that the left ventricular apex may be inadequately visualized in the near field of the echo image, and it is often difficult to outline endocardium, particularly in still frames.

Further Clinical Implications

Knowledge of the significant regional differences in contraction in the normal left ventricle appears essen-

tial for correct evaluation of wall motion abnormalities in patients with coronary artery disease and of the effects of various interventions. Another implication is in left ventricular hypertrophy, in which the ratio of left ventricular radius to wall thickness has been reported to have a bearing on function and prognosis.³⁷ Compared to M-mode echo,³⁸ left ventricular hypertrophy in unusual locations can be best detected using

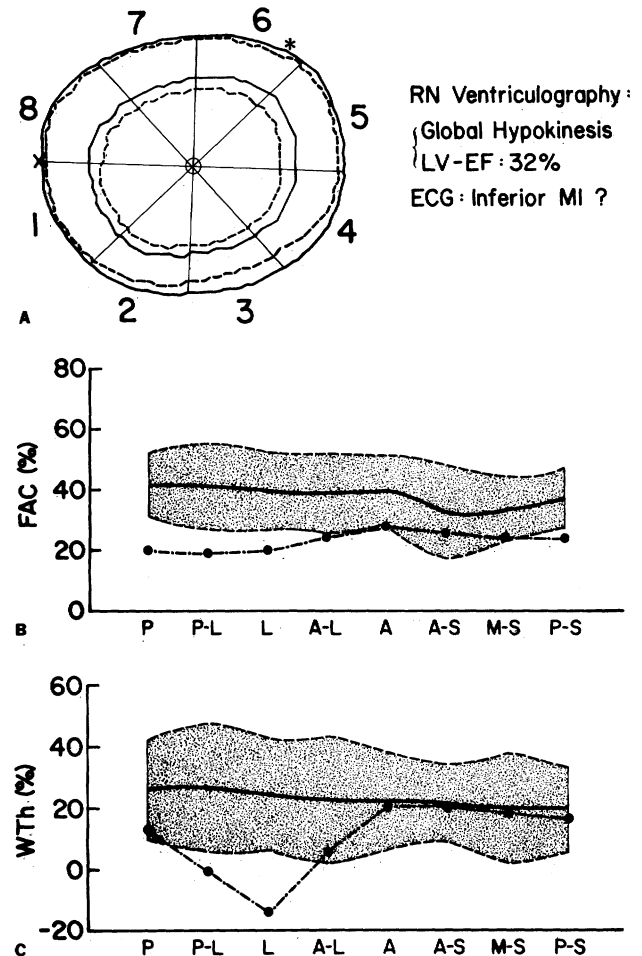


FIGURE 12. (A) Computer outlines of epicardial and endocardial surfaces at end-diastole (solid line) and end-systole (broken line) in a MV short-axis plane echocardiogram in a 49-year-old male with ischemic cardiomyopathy. This patient had clinical history of several myocardial infarctions (MI), and his ECG revealed pathologic Q-waves in leads III, aV_F and V₁. A technetium-99m radionuclide (RN) wall motion study showed global hypokinesis in several projections and a left ventricular ejection fraction (LV-EF) of 32%. (B) Compared with segmental FAC in normals, 2-D echo quantitative wall motion analysis in this patient (---) indicates hypokinetic motion only in posterior and lateral segments (segments 1–3 and 8, with borderline FAC in segments 4, 5 and 7). However, segmental WTh study (C) indicates thinning in posterolateral regions (segments 2 and 3), with preserved thickening in anterior and septal segments, suggesting the presence of scar tissue limited to the posterolateral myocardium. Similar abnormalities were observed at the HP and MP levels in this patient. Abbreviations are as in figures 1, 3 and 8.

2-D echo, but proper identification should be aided by knowing the normal limits of variations of wall thickness. Whenever follow-up or sequential studies are required, it is essential to obtain measurements in standardized locations, since variations in end-diastolic dimensions and wall thickness occur along the left ventricle.

Figure 12 shows an example of evaluation of segmental wall motion and thickening using our quantitative 2-D echo model in a patient with regional left ventricular dysfunction. Figure 12 clearly indicates that important additional information can be obtained compared to a qualitative radionuclide wall motion study.

Limitations in Evaluating Regional Left Ventricular Function with 2-D Echo

One limitation in applying the results of this study is the marginal image quality seen in a number of clinical 2-D echo studies. Thus, apical cross sections do not allow reliable identification of endocardium, which is required for measurement of wall thickness. Quantitative studies of parasternal long-axis views require measurements in standardized locations, and the distal portions of the LV, which are usually involved in ischemia, are not well seen in this view. In short-axis views, directionally opposite errors in wall thickness measurements during diastole and systole may significantly alter the derived index of wall thickening. Thus, a large standard deviation in WTh measurements (e.g., figs. 9 and 10) may present difficulties when trying to identify left ventricular segments exhibiting reduced wall thickening.

We conclude that the normal left ventricle exhibits a characteristic and significant enhancement of regional contraction from base to apex. Two-dimensional echocardiographic cross-sectional measurements are comprehensive and allow mapping of circumferential and longitudinal variations in segmental contraction. Knowledge of the normal regional differences may not be essential in assessing grossly abnormal contraction, but it could be critical for interpretation of hypokinesis, a frequently encountered wall motion abnormality in patients with coronary artery disease.

Acknowledgment

The authors gratefully acknowledge the work of Rosa Goldsmith in preparing the illustrations for this article. They also thank Myles Prevost for technical assistance, Mark Koury and Barbara Voigt for typing the manuscript, and Jeanne Bloom for editorial assistance.

References

- Herman MV, Heinle RA, Klein MD, Gorlin R: Localized disorders in myocardial contraction. Asynergy and its role in congestive heart failure. *N Engl J Med* 277: 222, 1967
- Braunwald E, Ross J Jr, Sonnenblick EH: Mechanisms of contraction of the normal and failing heart. *N Engl J Med* 277: 1012, 1967
- Gault JH, Ross J Jr, Braunwald E: Contractile state of the left ventricle in man. *Circ Res* 22: 451, 1968
- Streeter DD, Spotnitz HM, Patel DP, Ross J Jr, Sonnenblick EH: Fiber orientation in the canine left ventricle during diastole and systole. *Circ Res* 24: 339, 1969
- Greenbaum RA, Ho SY, Gibson DE, Becker AE, Anderson RH: Left ventricular fibre architecture in man. *Br Heart J* 45: 248, 1981
- Kong Y, Morris JJ, McIntosh HD: Assessment of regional myocardial performance from biplane coronary cineangiograms. *Am J Cardiol* 27: 529, 1971
- Liedke JA, Gault JH, Leman DR, Blumenthal MS: Geometry of left ventricular contraction in the systolic click syndrome. *Circulation* 47: 27, 1973
- Shapiro E, Marier DL, St. John Sutton ME, Gibson DE: Regional non-uniformity of wall dynamics in normal left ventricle. *Br Heart J* 45: 264, 1981
- LeWinter MM, Kent RS, Kroener JM, Carew TW, Covell JW: Regional differences in myocardial performance in the left ventricle of the dog. *Circ Res* 37: 191, 1975
- Wyatt HL, Heng MK, Meerbaum S, Hestenes JD, Cobo JM, Davidson RM, Corday E: Cross-sectional echocardiography. I. Analysis of mathematic models for quantifying mass of the left ventricle in dogs. *Circulation* 60: 1104, 1979
- Conver WJ: *Practical Nonparametric Statistics*, 2nd ed. New York, J Wiley and Sons, 1980
- Morrison D: *Multivariate Statistical Methods*, 2nd ed. New York, McGraw-Hill, 1976
- Leighton RF, Wilt SM, Lewis RP: Detection of hypokinesis by a quantitative analysis of left ventricular cineangiograms. *Circulation* 50: 121, 1974
- Wyatt HL, Haendchen RV, Meerbaum S, Corday E: Two-dimensional echocardiography: assessment of methodologies for quantitation. *Am J Cardiol*. In press
- Laks MM, Nisenson MJ, Swan HJC: Myocardial cell and sarcomere lengths in the dog heart. *Circ Res* 21: 671, 1967
- Falsetti HL, Carrol RJ, Marcus ML: Temporal heterogeneity of myocardial blood flow in anesthetized dogs. *Circulation* 52: 848, 1975
- Marcus ML, Kerber RE, Ehrhardt J, Abboud FM: Three dimensional geometry of acutely ischemic myocardium. *Circulation* 52: 254, 1975
- Gueret P, Meerbaum S, Corday E, Uchiyama T, Wyatt HL, Broffman J: Differential effects of nitroprusside on ischemic and non-ischemic myocardial segments demonstrated by computer assisted two-dimensional echocardiography. *Am J Cardiol* 48: 59, 1981
- Sniderman AD, Marpole D, Fallen EL: Regional contraction patterns in the normal and ischemic left ventricle in men. *Am J Cardiol* 31: 485, 1973
- Ingels NB, Daughters GB II, Stinson ED, Alderman EL: Is wall motion in the normal left ventricle uniform, symmetric and synergic? (abstr) *Circulation* 60 (suppl II): II-93, 1979
- Gelberg JH, Brundage BH, Glantz S, Parmley WW: Quantitative left ventricular wall motion analysis: a comparison of area, chord and radial methods. *Circulation* 59: 991, 1979
- Klausner SC, Blair TJ, Bulawa WF, Jeppson GM, Jensen RS, Clayton PD: Quantitative analysis of segmental wall motion throughout systole and diastole in the normal human left ventricle. *Circulation* 65: 580, 1982
- Haendchen RV, Wyatt HL, Meerbaum S, Povzhnikov M, Corday E: Characteristic variations in left ventricular contractile function mapped by two-dimensional echocardiography. (abstr) *Am J Cardiol* 49: 1020, 1982
- Nieminen M, Parisi AF, O'Boyle JE, Folland ED, Khuri S, Kloner RA: Serial evaluation of myocardial thickening and thinning in acute experimental infarction: identification and quantification using two-dimensional echocardiography. *Circulation* 66: 174, 1982
- Pandian N, Skorton D, Collins S, Burke E, Falsetti H, Kerber R: Heterogeneity of segmental left ventricular wall thickening and excursion in two-dimensional echocardiograms of normal humans. (abstr) *Am J Cardiol* 47: 452, 1981
- Franklin T, Wiske PS, Clendenon JL, Hogan RD, Avery KS, Burke KM, Sanghvi NT, Weyman AE: Variation in cross-sectional echocardiographic radial target motion relative to a calculated mean centroid of the left ventricle. (abstr) *Circulation* 62 (suppl III): III-132, 1980
- Vatner SF: Correlation between acute reductions in myocardial blood flow and function in conscious dogs. *Circ Res* 47: 201, 1980
- Gallagher KP, Kumada T, Koziol JA, McKown D, Kemper WS, Ross J Jr: Significance of regional wall thickening abnormalities relative to the transmural myocardial perfusion in anesthetized

- dogs. *Circulation* **62**: 1266, 1980
29. Richards A, Seabra-Gomes R, Thurston P: The assessment of regional abnormalities of the left ventricle by angiography. *Eur J Cardiol* **5**: 167, 1977
 30. Harris LD, Clayton PH, Marshal HW, Warner HR: A technique for the detection of asynergistic motion in the left ventricle. *Comp Biomed Res* **7**: 380, 1974
 31. Garcia E, Gueret P, Bennet M, Corday E, Zwehl W, Meerbaum S, Corday S, Swan HJC, Berman D: Real time computerization of two-dimensional echocardiography. *Am Heart J* **101**: 783, 1981
 32. Parisi AF, Moynihan PF, Folland ED, Feldman CL: Quantitative detection of regional left ventricular contraction abnormalities by two-dimensional echocardiography. II. Accuracy in coronary artery disease. *Circulation* **63**: 761, 1981
 33. Ingels NB, Daughters GT II, Stinson EB, Alderman EL: Evaluation of methods for quantitating left ventricular segmental wall motion in man using myocardial markers as a standard. *Circulation* **61**: 966, 1980
 34. Vas R, Diamond G, Forrester JS, Whiting JS, Pfaff MS, Levisman JA, Nakano FS, Swan HJC: Computer-enhanced digital angiography: correlation of clinical assessment of left ventricular ejection fraction and regional wall motion. *Am Heart J* **104**: 732, 1982
 35. Meerbaum S, Fishbein M, Rit J, Broffman J, Russel D, Haendchen R, Corday E: Two-dimensional echo measurement of regional cardiac function vs histochemical delineation of acutely ischemic myocardium. (abstr) *Clin Res* **29**: 22A, 1981
 36. Moynihan PF, Parisi AF, Feldman CL: Quantitative detection of regional left ventricular contraction abnormalities by two-dimensional echocardiography. I. Analysis of methods. *Circulation* **63**: 752, 1981
 37. Gaasch WH: Left ventricular radius to wall thickness ratio. *Am J Cardiol* **43**: 1189, 1979
 38. Maron BJ, Gottdiener JS, Bonow RD, Epstein SE: Hypertrophic cardiomyopathy with unusual locations of left ventricular hypertrophy undetectable by M-mode echocardiography. *Circulation* **63**: 409, 1981

In Vivo Assessment of Left Ventricular Wall and Chamber Dynamics During Transient Myocardial Ischemia Using Prospectively ECG-gated Computerized Transmission Tomography

ROBERT F. MATTREY, M.D., ROBERT A. SLUTSKY, M.D., STEPHEN A. LONG,
AND CHARLES B. HIGGINS, M.D.

SUMMARY Seven dogs were evaluated with prospective ECG-gated computerized transmission tomography (CTT) to analyze left ventricular (LV) wall thickness and cross-sectional chamber area after acute occlusion of the left anterior descending coronary artery (LAD). ECG-gated CTT scanning during i.v. administration of contrast material was performed over the mid-left ventricle at rest, after acute occlusion of the LAD and 30 minutes after release.

The extent of systolic wall thickening (EWTh) of the anterior (potentially ischemic) segment was $39.8 \pm 8.8\%$ (SEM) in the control state and $-26.0 \pm 4.7\%$ during LAD occlusion ($p < 0.01$). The nonischemic septum demonstrated a compensatory increase in EWTh, from $28.6 \pm 3.5\%$ to $46.4 \pm 6.1\%$ during LAD occlusion ($p < 0.05$). The end-diastolic LV luminal area (LVA) increased from $17.4 \pm 0.8 \text{ cm}^2$ in the control state to $21.0 \pm 1.1 \text{ cm}^2$ during LAD occlusion ($p < 0.01$). End-systolic LVA also increased, from 11.0 ± 0.9 to $15.2 \pm 1.1 \text{ cm}^2$ ($p < 0.01$). In addition, the percent change in LVA from end-diastole to end-systole declined from $37.4 \pm 3.8\%$ during control to $28.0 \pm 2.6\%$ during LAD occlusion ($p < 0.02$).

In conclusion, gated CTT demonstrates that the alterations in acute ischemia are characterized by changes in regional wall thickening dynamics, consisting of wall thinning during systole in the jeopardized segment and compensatory increase in the extent of systolic thickening in the normal segment, and changes in global LV function, consisting of an increase in the LVA and a decrease in the percent change of LVA during systole. Gated CTT may be useful for monitoring regional and global effects of ischemia when subjects can be studied in the supine position and with respiration suspended for 45 seconds.

EARLY DETECTION of myocardial ischemia and the quantitation of the extent of myocardial ischemic damage are important goals of noninvasive imaging techniques. Detection of myocardial ischemia by functional imaging methods requires the demonstration of

regional contraction abnormalities. The availability of prospective ECG-gated computerized transaxial tomography (CTT) not only provides good discrimination of the ischemic myocardium,^{1,2} but can also be used to evaluate segmental function by displaying wall thickening dynamics during the cardiac cycle. Previous reports^{3,4} using retrospective gating have indicated the potential of this technique for assessing left ventricular (LV) dimensions, including wall thickness changes. The ability to assess wall thickening dynamics is relevant in ischemic heart disease because they are a reliable and sensitive functional indicator of seg-

From the Department of Radiology, University of California, San Diego, San Diego, California.

Address for correspondence: Charles B. Higgins, M.D., Department of Radiology, University of California Medical Center, 225 Dickinson Street, San Diego, California 92103.

Received September 23, 1982; revision accepted February 17, 1983.

Circulation **67**, No. 6, 1983