

Validation of a computerized edge detection algorithm for quantitative two-dimensional echocardiography

WERNER ZWEHL, M.D., RONALD LEVY, M.D., ERNEST GARCIA, PH.D.,
ROBERTO V. HAENDCHEN, M.D., WILLIAM CHILDS, STEPHEN R. CORDAY, M.D.,
SAMUEL MEERBAUM, PH.D., AND ELIOT CORDAY, M.D.

ABSTRACT An edge detection algorithm used in conjunction with digitized two-dimensional echocardiograms was applied to validate computerized two-dimensional echocardiographic (2DE) quantitation of cross-sectional areas of canine left ventricular chambers. Images were enhanced by space-time smoothing and dynamic range expansion, after which automatic edge detection was performed by convolving a Laplacian operator with the enhanced image. In an in vitro study of 29 myocardial slabs, computer-derived 2DE measurements of short-axis sections of the left ventricle were compared with manually derived 2DE data and validated against direct measurements of intraluminal areas of myocardial slabs. Correlations of both manually and computer-derived 2D echocardiograms vs direct measurements were equally satisfactory ($r = .95$ for both). Computer-derived measurements of perimeters tended to underestimate actual perimeters of the endocardial outlines of left ventricular sections. In 13 closed-chest anesthetized dogs, manually and computer-derived left ventricular short-axis areas measured by 2DE techniques showed a good correlation at both end-diastole ($r = .91$) and end-systole ($r = .92$). Left ventricular volumes reconstructed from 2DE images were compared with angiographically determined volumes. The computer-enhanced 2DE method correlated against angiography, with $r = .93$ for end-diastolic and $r = .93$ for end-systolic volumes. Left ventricular volume correlations between manually and computer-derived 2D echocardiograms were satisfactory, with $r = .87$ for end-diastole and $r = .87$ for end systole. We conclude that computerized enhancement and edge detection of 2D echocardiograms obtained in dogs provided accurate analysis of actual left ventricular cross-sectional areas and left ventricular volumes.

Circulation 68, No. 5, 1127-1135, 1983.

IMPROVEMENTS in two-dimensional echocardiographic (2DE) imaging systems have made this non-invasive diagnostic technique more suitable for quantitative analysis of cardiac function. Currently, delineation of endocardial and epicardial interfaces in several cross-sectional images of the heart are being applied to assess systolic sectional or segmental area or perimeter changes and wall thickening as indexes of regional contractile function.^{1,2} Various reconstruction methods are also used to derive chamber volumes and ejection fractions.³⁻⁸ However, a major limitation of 2DE has been the lack of direct computerized ac-

quisition, processing, and automated analysis of images, which could obviate the currently time-consuming, tedious, and subjective manual methods of edge delineation.

Several groups have reported computer acquisition and processing of 2DE images, using 2DE video still frames,^{9,10} flying-spot scanners,¹¹ contour digitizers,¹² and video disc recorders.¹³ Recently, other investigators have also addressed 2DE real-time computerization.¹⁴ These methods were illustrated in selected examples and by comparison to linear measurements,¹⁵⁻¹⁷ yet no systematic validation of computerized 2DE techniques for measurement of cross-sectional areas or reconstructed volumes has been presented, even for superior 2DE images obtained in the experimental laboratory or in normal human subjects. We have previously described our development of a computer system that can acquire and process 2DE video signals in real time.¹⁸ The current study was designed to validate, through in vitro and in vivo studies of the canine heart,

From the Division of Cardiology, Department of Medicine, Cedars-Sinai Medical Center, and the UCLA School of Medicine, Los Angeles.

Supported in part by grants HL 17651-08 and HL 14644-09 from the National Heart, Lung and Blood Institute, National Institutes of Health, the W. M. Keck Foundation, the Ahmanson Foundation, and by the Mitchell Family Foundation.

Address for correspondence: Werner Zwehl, M.D., Halper Bldg., Room 325, Cedars-Sinai Medical Center, 8700 Beverly Blvd., Los Angeles, CA 90048.

Received March 23, 1983; revision accepted July 28, 1983.

the adequacy of a fully automated endocardial edge detection method for computerized quantitation of regional and global left ventricular function.

Methods

Computer methodology

Instrumentation and image acquisition. The computer system used in this study consisted of the following:

- (1) Nova-3 central processor unit
- (2) 128 K 16 bit word main-frame memory
- (3) 256 K 16 bit word remote or auxiliary memory
- (4) 80 megabyte multiplate storage module (magnetic disc)
- (5) Keyboard and video display with up to 512×512 pixel resolution, with 256 gray levels
- (6) Video interface

The video interface consisted of an analog-to-digital converter capable of digitizing in real time 100 pixels per video line and storing them into memory. The input video field consists of a 640 and 480 pixel matrix. A window encompassing the 2DE video image is digitized into 8 bit pixels in a chosen 64×64 frame format, which is continuously transferred to the disc at 30 frames/sec, as required for real-time acquisition.

The window location on the video screen was controlled by software and operator joystick. Combination of pixel inputs into memory was done by maximum pixel intensity within a unit area.

Processing. A 64×64 matrix windowed to encompass just the area of the left ventricle was used to convert an analog 2DE

video image (figure 1, *B*) to a digital format (figure 1, *C*). This was done to optimize the number of pixels per unit area in the region of the left ventricle, approximately corresponding to better than 1 pixel per millimeter. After acquisition, space-time smoothing was performed to reduce random noise and effect of dropouts (figures 1, *D*, and 2, *B*). We have developed an optimized algorithm that can smooth in both space and time 30, 64×64 byte images in 12 sec. Temporal smoothing is performed first by replacing the content of each pixel with a weighted average of itself and the pixels with the same cartesian coordinates in the frame immediately before and after. The weighting factor emphasizes the contents of the pixel under examination by a factor of 2:1. Spatial smoothing is then performed, replacing the content of each pixel by a weighted average of itself and of the eight surrounding pixels within the same frame. This uses a 4:2:1 weighing factor, which emphasizes the contents of the pixel by a factor of 2 and the diagonally aligned pixels by a factor of 1.

Automated edge detection. After space-time smoothing, the operator selects end-diastolic and end-systolic echocardiographic image frames for quantitative analysis. This selection is based on the largest and smallest cross-sectional lumina, respectively. Automated edge detection of the endocardium is achieved by applying a 3×3 Laplacian operator (second derivative). Convolving an image with a Laplacian operator^{19, 20} results in edge sharpening in two dimensions, without regard to edge direction. The operation results basically in a two-dimensional discrete second derivative of the original image (figure 2, *C*). Since the second derivative of a function is zero at a relative maximum, minimum, or point of inflection, the latter are identi-

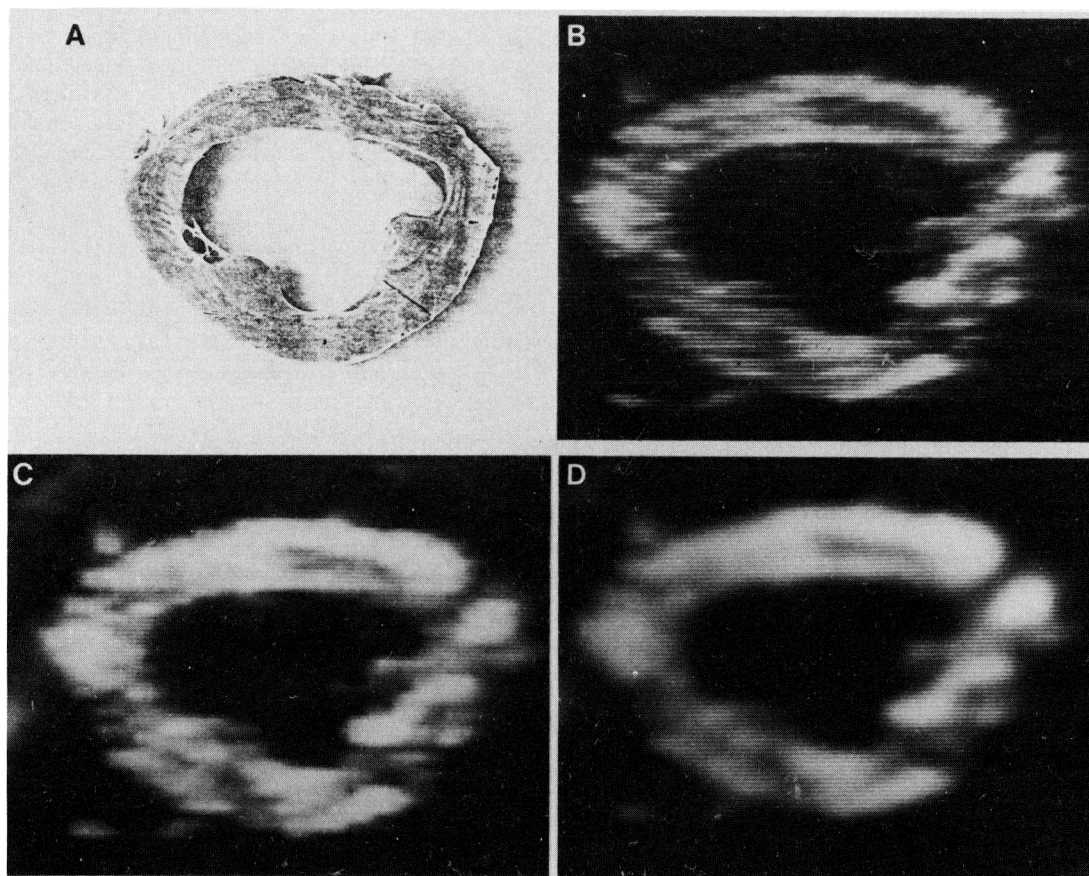


FIGURE 1, A to D. Comparison of left ventricular short-axis cross-section slice and 2DE image. A, Photocopy of typical canine slab; B, untreated 2DE video image; C, display of computer digitized image; D, display of space-smoothed computer image. (For measurement, all imaging systems were x and y calibrated.)

fied as the edges of an object. These points of inflection can be separated from the relative minimum by establishing a criterion where each pixel identified as an edge in the original image exceeds a predefined threshold amplitude. We have implemented a 3×3 Laplacian operator (8 in the center and -1 on the sides), in combination with thresholding, to create binary images of the left ventricle from space-time-smoothed, short-axis cross sections. In this binary image each pixel is "on" ($= 1$) if it is within the left ventricular cavity and "off" ($= 0$) if outside. Once the binary image is formed it becomes the input of a tracing program, which tracks the boundary corresponding to the inner wall of the ventricle (figures 1, *E* and *F*, and 2 *D*).

During the processing, the operator selects the largest (end-diastolic) or smallest (end-systolic) cross-sectional image (with fewest dropouts) before the computer program is started. The operator identifies an appropriate processed image threshold level as well as windows in the Laplacian image to produce a binary image (figure 2, *C*) that conforms to the operator's perception of the endocardial edge. The operator then assigns a point in the left ventricular cavity and starts execution. The computer system is also capable of continuous edge detection for multiple frames. The operator has the option of assigning the necessary variable for each individual frame (semiautomatic mode) or letting the algorithm use the parameters defined for the initial frame to process the rest of the cardiac cycle (automatic mode).

Once all edges have been extracted, the algorithm calculates cross-sectional areas and perimeters of the endocardium, and further calculations for segmental areas can be performed as well (figure 1, *F* and *H*). When in the semiautomatic mode, the operator has the option of manually modifying the tracked endocardium with the joystick.

The length of the left ventricular chamber is directly calculated by the computer from long-axis images in end-systolic and end-diastolic frames, from manual joystick assignment of the apex and the mitral aortic junction.

In vitro validation study. Eleven postmortem canine hearts were fixed in formalin for more than 24 hr and sectioned in short-axis planes (perpendicular to the long-axis) into 0.9 to 1.1 cm thick slices. Sections of the basal left ventricle were selected because they showed similar superior and inferior intraluminal areas. The right ventricular wall was separated from the septum.

To record actual ventricular sectional intraluminal areas, planimetry was performed on the actual slabs. The superior and inferior surface of each canine ventricle section was directly photocopied on a Royfax Bond copier (figure 1, *A*), along with a calibration scale in both x and y directions. These photocopied images served as reference standards of the endocardial outline of each slab.

2DE imaging was carried out on individual left ventricular sections suspended in a glass tank filled with water at room temperature (20°C). A specially designed stand was used to keep the 2DE transducer and the heart section aligned, so as to achieve stable, short-axis cross-sectional views (figure 1, *B*). The gain and reject setting of the 2DE equipment was optimized for each slab. Apparent "dropouts" in 2DE images were "filled in" by slightly moving the transducer along the section. To correct for measurement errors introduced by imaging in 20°C water, which leads to slowing of the speed of sound and overestimation of axial distances, a calibrated echo phantom with spaced nylon strings was placed in the 20°C water bath to provide the correct vertical and horizontal calibration factors subsequently applied to the in vitro measurements. Images were recorded on a Panasonic $\frac{3}{4}$ inch videotape recorder.

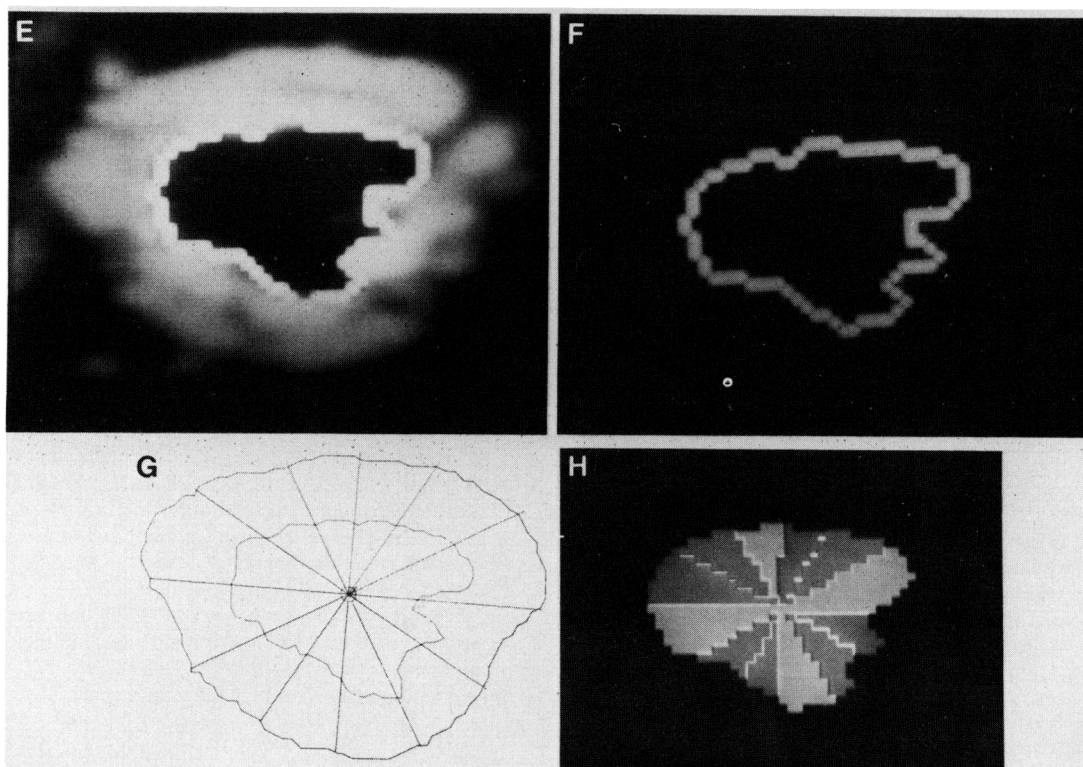


FIGURE 1, *E* to *H*. *E*, Computer-processed and space-smoothed 2DE image with automatic endocardial edge outline; *F*, endocardial edge; *G*, computer-assisted outline of manually drawn 2DE image (outer border represents epicardium, inner border represents endocardium), subdivided into 12 segments after locating endocardial center of area, and using midpapillary (3 o'clock reference point) as the intraluminal landmark; *H*, automatic computer subdivision of cross section into 12 segments with standardized referencing.

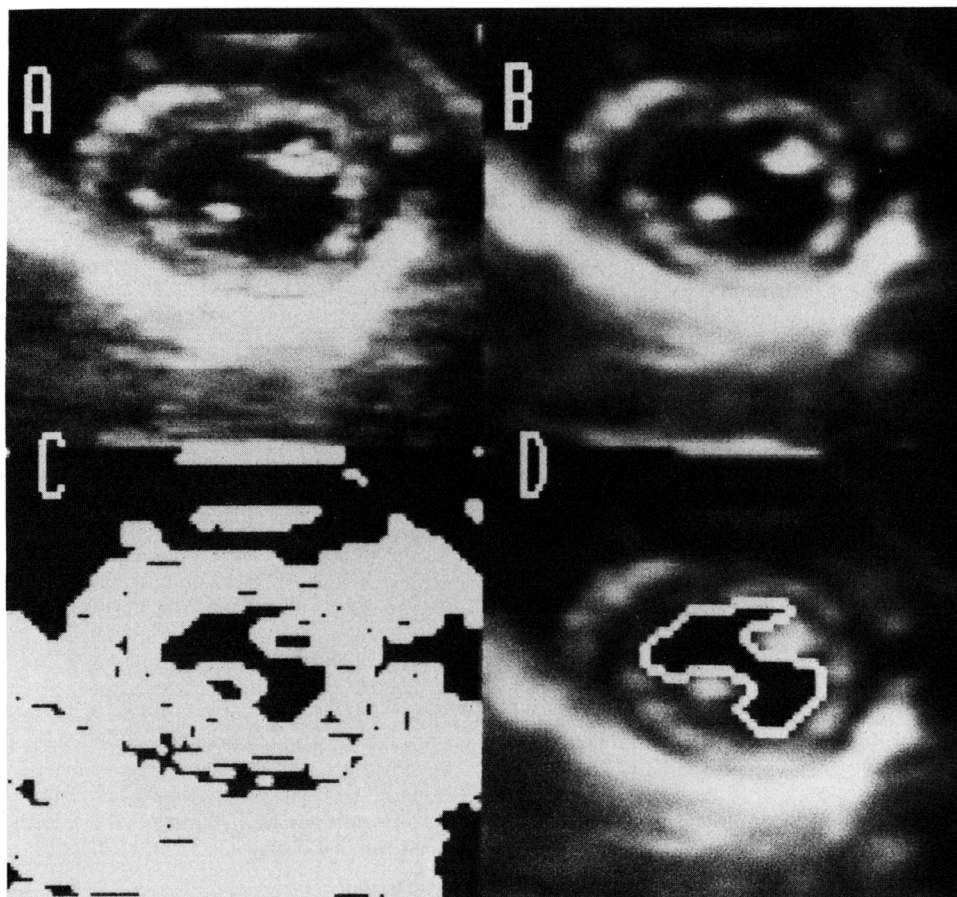


FIGURE 2. A, Video image of a 2DE left ventricular short-axis section recorded during an in vivo dog study. Space-time smoothed image before (B) and after (D) automatic endocardial edge definition. C, Binary Laplacian image, a step in the computer algorithm.

For manual measurements of left ventricular sectional and segmental intraluminal areas encompassed by the endocardial interface, the photocopied images of the sections and standardized subsections were planimetered and the intraluminal area of each section was calculated as the mean of the superior and inferior surface areas. Manual measurements from video displayed 2DE images were obtained as follows: The inner edge of the cross-sectional image (trailing-leading edge methodology) was traced from stop frames onto a clear plastic sheet. With slow motion and frame-by-frame review, endocardial dropouts were filled in. The tracing was then digitized into a computer system for calculation of total and segmental areas. The latter were obtained through subdivision into 12 segments, with the center of the area and a standardized indexing line connecting the center to a specific landmark (figure 1, G) (e.g., tip of papillary muscle).

In vivo validation study. Echocardiographic examination was performed in 13 closed-chest dogs. In nine of these animals, left ventricular cineventriculography was quantifiable. The dogs (weight 20 to 36 kg) were anesthetized with morphine (1.2 mg/kg im), followed by administration of sodium pentobarbital (30 mg/kg iv), and respiration was maintained with a Harvard respirator pump.

2DE data acquisition and analysis. A mechanical 2DE sector scanner (ATL Mark 5) was used. The experimental echographic imaging technique used has been previously developed and validated in our laboratory.¹³ The dog was placed on its right side, the transducer was directed from underneath against the dog's right side of the chest, and multiple left ventricular short-

and long-axis cross-sections were obtained. A representative left ventricular short-axis cross section (video image) is shown in figure 2, A.

With internal cardiac landmarks used as a guide, 2DE left ventricular short-axis sections were obtained at five levels (mitral valve, high, middle, and low papillary muscle, and subpapillary low left ventricular level). A long-axis cross section for measurement of left ventricular length (L) was obtained by rotating the transducer 90 degrees. Receiver gain setting was optimized for each study and then maintained throughout the experiment.

The 2DE images were recorded on video tapes and played back for echocardiographic analysis. After planimetry of short-axis cross-sectional areas (end-diastole being the largest luminal area and end-systole the smallest area) and long-axis sectional length, left ventricular volumes were calculated by a modified Simpson reconstruction method based on all five short-axis areas (A). In the latter reconstruction, the left ventricular volume was calculated by multiplying the planimetered section luminal area by the height of the slab ($h = L/5$), except in the apical region (A_5), for which the volume was calculated with an ellipsoid formula. The total ventricular volume (V) was then obtained by adding the volumes of individual sections.^{4, 5}

$$V = (A_1 + A_2 + A_3 + A_4)h + A_5h + \frac{\pi h^3}{6}$$

Left ventricular cineangiography. With the dog placed on its left side in a right anterior oblique position (67 degrees) as

suggested by Bentivoglio et al.,²¹ a 50% hypaque solution (1 ml/kg) was injected into the left ventricle with an electrocardiograph-synchronized system in early diastole. Ventriculograms were recorded at 30 frames/sec on 16 mm film, and end-diastolic (largest) and end-systolic (smallest) outlines of the left ventricle were subsequently traced.

Left ventricular volumes were calculated with standard formulas, assuming left ventricular geometry as an ellipsoid of revolution. Volumes were corrected by means of the Kennedy regression equation.²²

Methods for reproducibility analysis. To determine interobserver and intraobserver variability, measurements of manually outlined and computer-processed echocardiograms were analyzed twice by one observer and by two independent observers.

Statistical analysis. All data were analyzed by linear regression with the method of least squares to obtain estimates of the slopes and intercept parameters.

Results

In vitro. A representative photocopied image of a left ventricular slab is shown in figure 1, A, its equivalent 2DE image in figure 1, B, the computer-digitized (C) and processed image (D), with the computer-derived endocardial outline shown in figure 1, E. Comparisons of sectional left ventricular cavity areas in the 29 cardiac slices are shown in figure 3.

Measurement of sectional left ventricular cavity area indicated excellent correlation of both the manually outlined and computer-derived 2DE methods with the actual luminal area ($r = .95$ and $.96$). There was no significant underestimation by the manual 2DE technique (11.6 ± 3.7 cm², mean \pm SD) or by the computer-derived 2DE images (12.3 ± 3.9) compared with actual slab area (12.4 ± 3.6). Comparison of the manually vs computer-derived 2DE areas also showed a high degree of correlation ($r = .95$).

Results for perimeter measurements are shown in figure 4. Both manually and computer-derived 2DE data showed excellent correlation with direct measurements ($r = .94$). Computer measurements (13.1 ± 2.7 cm) generally tended to underestimate directly measured perimeters (14.7 ± 2.4) more than the manually determined 2DE data (14.5 ± 2.8).

Examples of subdivision of the manually drawn and digitized outline and the computer-derived subdivided cross-sectional image are shown in figure 1, G and H.

2DE segmental area measurements ranged from 0.38 cm² to 3.15 cm². Comparison between the two techniques (for $29 \times 12 = 348$ segmental areas)

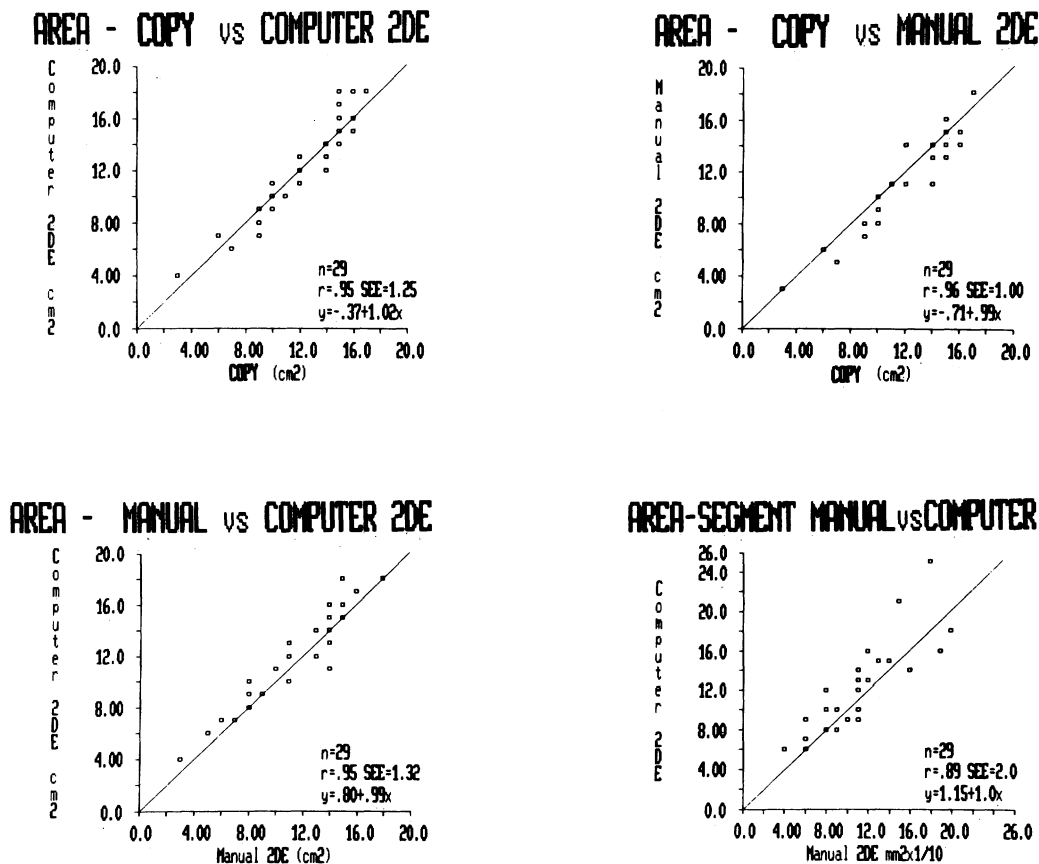


FIGURE 3. Comparison and validation of short-axis cross-sectional left ventricular lumen areas derived by 2DE methods. *Top left*, comparison of areas from slab photocopy (COPY) vs 2DE method with computer delineation. *Top right*, slab photocopy vs manually drawn 2DE image. *Bottom left*, manually drawn 2DE image vs computer delineation. Solid line is line of identity.

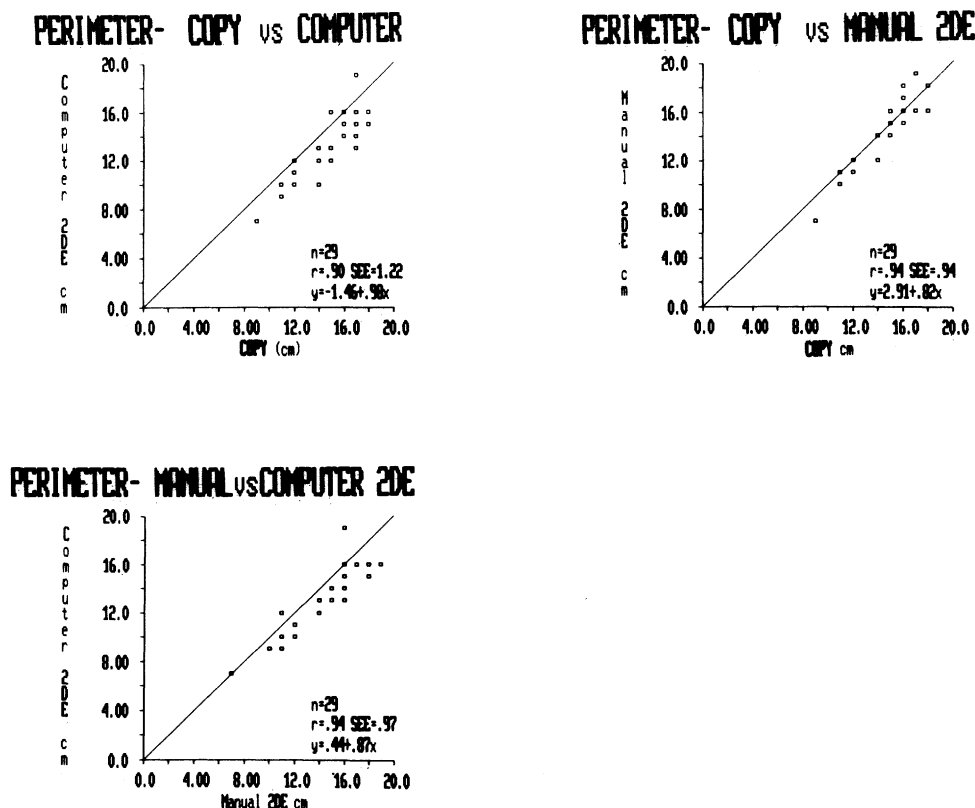


FIGURE 4. Comparison of slab-perimeter measurements. Graphic sequence as in figure 3. Note the underestimation when using computer method as compared with manually determined perimeter.

showed correlations ranging from $r = .79$ to $.95$.

Reproducibility. Computer analysis for total and segmental short-axis areas were studied for intraobserver and interobserver reproducibility of measurements. Total segmental areas showed excellent correlations ($r = .99$ and $.98$, respectively), and correlations for segmental areas segments ranged from $r = .83$ to $.96$.

In vivo. End-diastolic and end-systolic measurements of 60 short-axis cross-sectional intraluminal areas were compared. Manually derived vs computer determined cross-sectional areas (figure 5) indicated a correlation of $r = .91$ in end-diastole and $r = .92$ in end-systole. Simpson reconstructed end-diastolic volumes correlated with $r = .92$ and end-systolic volumes with $r = .91$ for the two 2DE methods.

Further validation of manually derived volumes with angiographically determined volumes showed a correlation factor of $r = .86$ in end-systole (manual 2DE, 38.3 ± 12.4 ml; angiography, 41.8 ± 16.8 ml) (SEE ± 8.5 ml) and a factor of $r = .88$ in end-diastole (manual 2DE, 84.2 ± 21.5 ml; angiography, 85.3 ± 29.3 ml) (SEE ± 14.1 ml) (figure 6). Comparison of computerized 2DE (end-systolic volume, 45.6 ± 13.7 ml; end-diastolic volume, 90.4 ± 29.1 ml) and angiographic left ventricular volumes demonstrated a correlation coefficient for end-systole of $r = .93$ (SEE ± 5.1 ml) and a coefficient for end-diastole of $r = .93$ (SEE ± 10.6 ml) (figure 6).

Reproducibility. Intraobserver reproducibility of computer-derived 2DE in vivo measurements of 48 diastol-

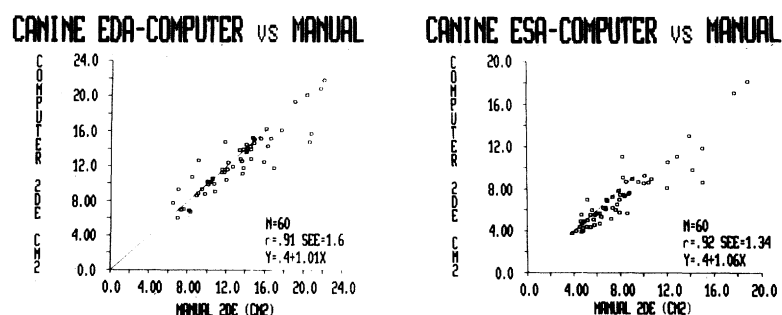


FIGURE 5. Comparison of in vivo dog left ventricular short-axis end-diastolic and end-systolic cross-sectional area measurements, derived manually and by computer edge detection.

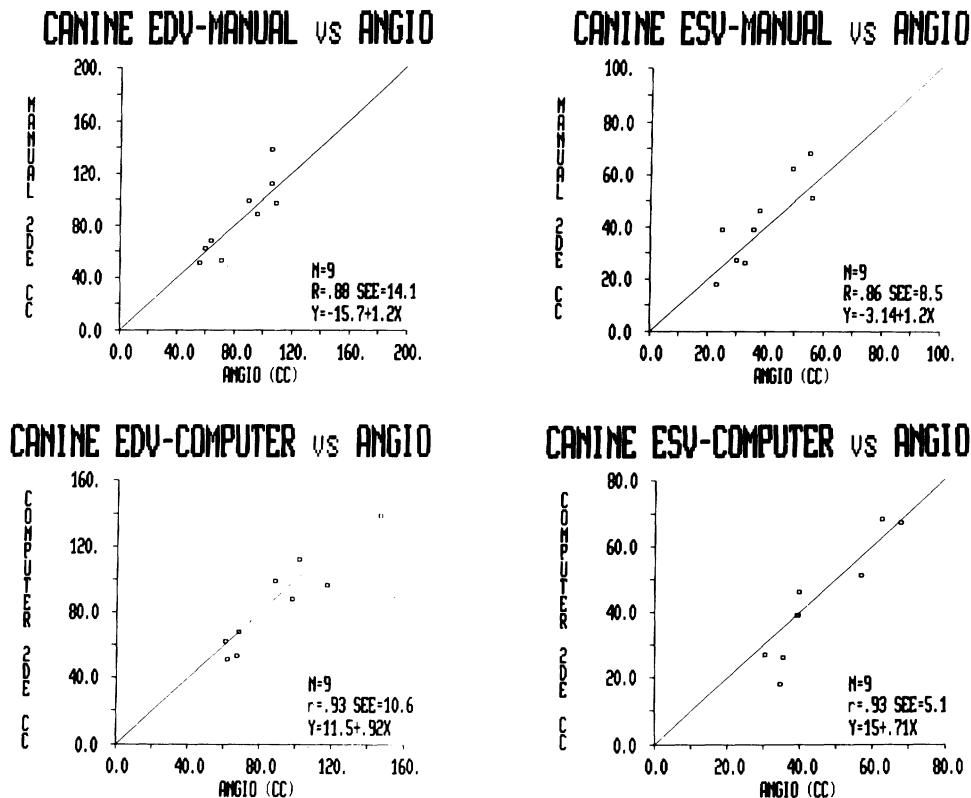


FIGURE 6. Comparison of 2DE-derived reconstructed left ventricular volumes and angiographically determined volumes. Both manually (*top row*) and computer-derived (*bottom row*) 2DE volumes compared favorably with angiographically determined volumes.

ic and 47 systolic section area measurements yielded correlation coefficients of $r = .93$ (SEE ± 1.5) and $r = .88$ (SEE ± 1.48), respectively. Interobserver reproducibility were equally satisfactory ($r = .91$ to $.95$). For reconstructed volume measurements intraobserver and interobserver reproducibility ranged from $r = .91$ to $.96$, with SEE from 6.5 to 14.0 ml (figure 7).

Discussion

Quantitative assessment of left ventricular function with manual 2DE methods has been validated in several studies. Thus validations from our laboratory^{4,5} and other institutions have proved 2D echocardiography to be an accurate and reproducible method for in vitro and in vivo measurement of left ventricular size and function in the dog. Although these methods have been applied in a large number of experimental studies, the limitations of currently used manual 2DE image-tracing techniques are generally recognized. Thus analysis in individual cardiac cycles of each frame is time consuming, outline of interfaces is observer dependent, and stop frame image degradation often requires considerable image replay to provide adequate endocardial and epicardial edge delineation in the 2DE cross sections.

The introduction of computer acquisition and analysis of 2DE images promises to provide some of the improvements needed for practical, prompt, and quantitative evaluation of cardiac function. Most of the published studies of enhanced 2DE image processing and analysis have used digitization of still frames, either from photographic or from video images.⁹⁻¹² Obviously, study of the dynamic changes throughout the cardiac cycle requires a more powerful real-time computer system, with high-speed analog-to-digital conversion and a large memory. The computerized 2DE system used in this study presented real-time analog-to-digital transfer (30 frames/sec) and adequate storage of 2DE images.

To fully utilize computer capabilities for objective quantitation of cardiac function, we have developed an algorithm that provides automated edge detection of endocardial interfaces in 2DE cross sections. As discussed, this algorithm is based on detection of echo intensity points of inflection, along with thresholding to an echo amplitude.

Comparison of in vitro measurements. Although comparison of 2DE-derived measurements with direct in vitro slab measurement should provide the most stringent evaluation, inherent 2DE resolution problems

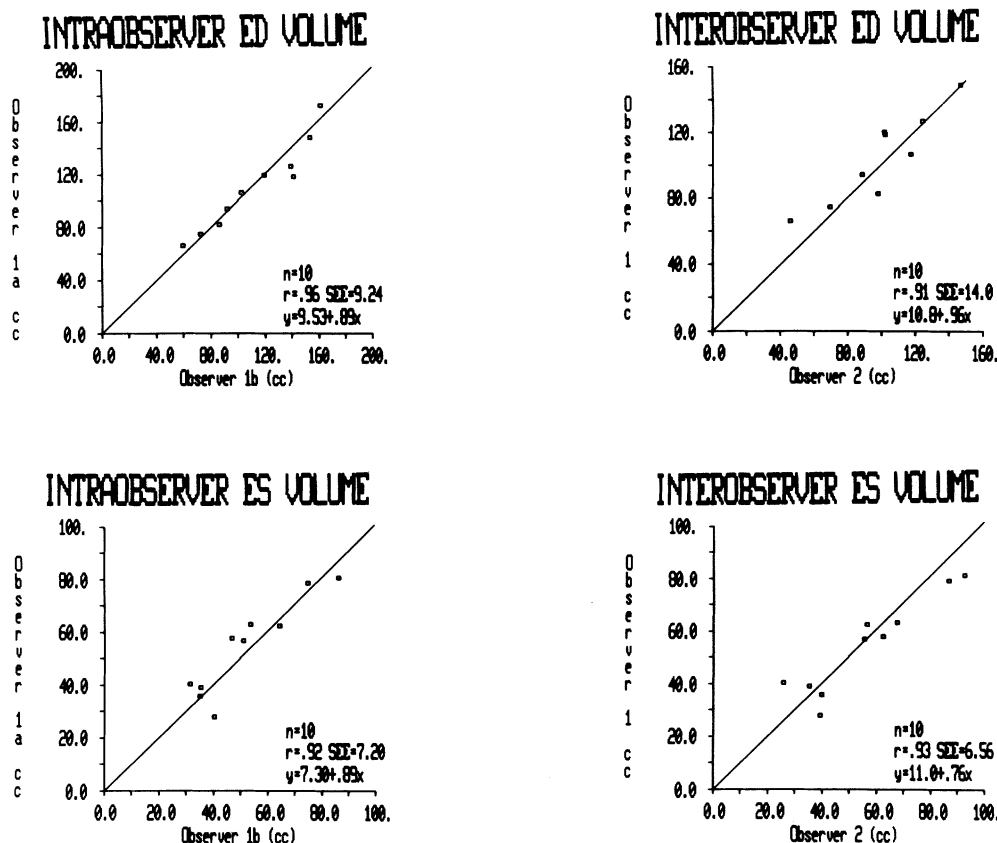


FIGURE 7. Interobserver and intraobserver reproducibility of computer processed volume measurements, showing close correlation of end-systolic and end-diastolic measurements.

need to be kept in mind. Thus a 10 mm thick myocardial slice represents a three-dimensional object with generally varying intraluminal areas as one progresses from its lower to its upper side. Current 2DE methods are associated with finite axial and lateral resolution, which varies along the axis of the transducer and determines limitations of quantitative measurements. When applied to imaging of myocardial borders, a complex summation of backscatter within the region sampled by the transducer may result in a smaller imaged intracavitary lumen as compared with the actual ventricular cavity, partially explaining differences reported between 2DE and direct *in vitro* measurements.²³

In the present *in vitro* study, care was taken to select the most cylindrical left ventricular slabs exhibiting similar areas and perimeters on both sides. The very close echocardiographic estimation of actual sectional measurements may also be caused by the use of a mechanical 2DE system, which in comparison with electronic phased array scanners tends to present a narrower beam width and improved image resolution.

Although detection of endocardial outlines was automated by the computer, any echo “dropout” was filled in manually by means of a joystick, which was also used to correct for obvious artifacts. There was an

excellent agreement between all three sectional area measurement techniques (direct, echo-manual, and echo-computerized). The computer-derived perimeter measurements tended to underestimate the actual and 2DE manually derived dimensions; this is believed to be due to the 64×64 pixel matrix, which tends to average minute indentations or protrusions at the endocardial interface, presenting an artifactually “smoothed” but underestimated perimeter.

To further test the accuracy of computer-derived analysis of 2DE images, each of the 29 sections was subdivided into 12 segments for comparison of hand-drawn and automated computer analysis.

Analysis of 348 segmental areas showed good agreement between manually and computer-derived 2DE data, with correlation coefficients ranging from .79 to .95 and small SEE (0.16 to 0.27 cm²). Differences in measurements of several segments were probably caused by the specific procedure for section subdivision, which depended on internal landmarks in the manually drawn and computer-outlined borders. Thus a slight rotation of the initially selected indexing point would introduce some differences in regional measurements.

In vivo measurements. As has been reported in pre-

vious studies, there is good agreement between angiographically determined left ventricular volume measurements and 2DE measurements with appropriate reconstruction models.³⁻⁸ Dynamic computer acquisition of complete cardiac cycles allowed selection of the smallest and largest short-axis sections for subsequent quantitation. As in the in vitro study, there was excellent agreement between automatically derived end-diastolic and end-systolic sectional areas and manually derived 2DE data. Left ventricular volume reconstruction with both manual and computerized 2DE methods correlated well with angiographically determined left ventricular volumes.

In both in vitro and in vivo validations in dogs, 2DE images of excellent quality were selected to provide the signal-to-noise ratio required for adequate automated computer analysis. Nevertheless, since the computer processing for automated edge detection entailed two observer-dependent steps, i.e., choosing a "threshold" level for the processed image and appropriate "windowing" of values in the Laplacian image, an intraobserver and interobserver study was performed to determine the variability of the 2DE computer processing. Good agreement was found between measurements by two independent observers.

Implications. For application of this computerized 2DE technique in the clinical setting in which 2DE images are of inferior quality, the following aspects need to be considered: (1) general improvement of the actual 2DE imaging equipment and (2) computer enhancement of 2DE images to overcome echo dropouts and to improve the signal-to-noise ratio.

We express our appreciation to Mr. Myles Prevost for his technical assistance with this study, Mrs. Jeanne Bloom for her editorial assistance in the preparation of the manuscript, and Ms. M. Bear and J. Prause for their statistical analysis.

References

1. Parisi AF, Moynihan PF, Feldman CL: Quantitative detection of regional left ventricular contraction abnormalities by two-dimensional echocardiography. II. Accuracy in coronary artery disease. *Circulation* **63**: 761, 1981
2. Haendchen RV, Wyatt HL, Maurer G, Zwehl W, Bear M, Meerbaum S, Corday E: Quantitation of regional cardiac function by two-dimensional echocardiography. I. Patterns of contraction in the normal ventricle. *Circulation* **67**: 1234, 1983
3. Eaton LW, Maughan WL, Shoukas AA, Weiss JL: Accurate volume determination in the isolated ejecting canine left ventricle by two-dimensional echocardiography. *Circulation* **60**: 320, 1979
4. Wyatt HL, Heng MK, Meerbaum S, Gueret P, Hestenes JD, Dula E, Corday E: Cross-sectional echocardiography. II. Analysis of mathematic models for quantifying volume of the formalin-fixed left ventricle. *Circulation* **61**: 1119, 1980
5. Gueret P, Meerbaum S, Wyatt HL, Uchiyama T, Lang TW, Corday E: Two-dimensional echocardiographic quantitation of left ventricular volumes and ejection fraction: importance of accounting for dyssynergy in short-axis reconstruction models. *Circulation* **62**: 1308, 1980
6. Schiller NB, Acquatella H, Ports TA, Drew D, Goerke J, Ringertz H, Silverman NH, Brundage B, Botvinick EH, Boswell R, Carlson E, Parmley WW: Left ventricular volume from paired biplane two-dimensional echocardiography. *Circulation* **60**: 547, 1979
7. Folland ED, Parisi AF, Moynihan PF, Jones RJ, Feldman CL, Tow DE: Assessment of left ventricular ejection fraction and volumes by real-time two-dimensional echocardiography: a comparison of cineangiographic and radionuclide technique. *Circulation* **60**: 760, 1979
8. Helak J, Reichek N: Quantitation of human left ventricular mass and volume by two-dimensional echocardiography: in vitro anatomic validation. *Circulation* **63**: 1398, 1981
9. Price RR, Erickson JJ, Jones TB, Fleisher AF, Partain CL, James AE Jr: A digital signal and image processing system for ultrasonography. In *Proceedings of the 25th Annual Meeting of the AIUM*. American Institute of Ultrasound in Medicine, Oklahoma City, Sept. 1980, p 202
10. Skorton DJ, McNary CA, Child JS, Shah PM: Computerized image processing in cross-sectional echocardiography. *Am J Cardiol* **45**: 403, 1980
11. Matsumoto M, Matsuo H, Kitabatake A, Inoue M, Hamanaka Y, Tamura S, Tanaka K, Hiroshi A: Three-dimensional echocardiograms and two-dimensional echocardiographic images at desired planes by a computerized system. *Ultrasound Med Biol* **3**: 163, 1977
12. Garrison JB, Weiss JL, Maughan WL, Tuck OM, Guier WN, Fortuin NJ: Quantifying regional wall motion and thickening in two-dimensional echocardiography with a computer-aided contouring system. In *Computers in cardiology*. Long Beach, 1977, IEEE Computer Society, pp 25-35
13. Skolnick ML: A new approach to ultrasound image recording using a video disc recorder. *Radiology* **133**: 530, 1979
14. Melton HE, Collins SM, Skorton DJ: Automatic real-time endocardial edge detection during two-dimensional echocardiographic examination. *Circulation* **66** (suppl II): II-337, 1982
15. Geiser EA, Zhang LD, Buss DD, Franklin BD, Fu KJ, Conetta DA, Conti CR: Automated border definition from 2D-echocardiograms. *Circulation* **66** (suppl II): II-337, 1982
16. Conetta DA, Geiser EA, Skorton DJ, Pandian N, Kerber RE: Accuracy and reliability of border identification techniques for quantitative 2D echo. *Circulation* **66** (suppl II): II-337, 1982
17. Skorton DJ, McNary CA, Child JS, Newton FC, Shah PM: Digital image processing of two-dimensional echocardiograms: identification of the endocardium. *Am J Cardiol* **48**: 479, 1981
18. Garcia E, Gueret P, Bennett M, Corday E, Zwehl W, Meerbaum S, Corday S, Swan HJC, Berman D: Real time computerization of two-dimensional echocardiography. *Am Heart J* **101**: 783, 1981
19. Rosenfeld A, Kak AC: *Digital picture processing*, ed 2. New York, 1982, Academic Press, Inc., pp 283-244, (vol 1), pp 89-91 (vol 2)
20. Hall EL: *Computer image processing and recognition*. New York, 1979, Academic Press, Inc., pp 394-409
21. Bentivoglio LG, Griffith LD, Cuesta AJ, Geczy M: Radiographic evaluation of formulas for left ventricular volume using canine casts. *J Appl Physiol* **33**: 365, 1972
22. Kennedy JW, Trenholme SE, Kasser IS: Left ventricular volume and mass from single-plane cineangiogram: a comparison of anteroposterior and right anterior oblique methods. *Am Heart J* **80**: 343, 1970
23. Helak JW, Plappert T, Muhammad A, Reichek N: Two-dimensional echocardiographic imaging of the left ventricle: comparison of mechanical and phased array systems in vitro. *Am J Cardiol* **48**: 728, 1981