

Endocardial mapping in humans in sinus rhythm with normal left ventricles: activation patterns and characteristics of electrograms

DENNIS M. CASSIDY, M.D., JOSEPH A. VASSALLO, M.D., FRANCIS E. MARCHLINSKI, M.D.,
ALFRED E. BUXTON, M.D., WILLIAM J. UNTEREKER, M.D., AND MARK E. JOSEPHSON, M.D.

ABSTRACT Endocardial catheter mapping was performed in 15 patients in sinus rhythm who had no evidence of structural heart disease and normal left ventricles. Mapping was performed with the use of 10 mm interelectrode distance from various left ventricular endocardial sites. In 10 patients a quantitative analysis of electrographic amplitude, duration, and amplitude/duration ratio was performed. The normal left ventricular bipolar electrograms had an amplitude of greater than 3 mV, a duration of less than 70 msec, and an amplitude/duration ratio of greater than 0.045. Local activation times were also assessed in the 15 patients. This analysis revealed two endocardial breakthrough sites, one on the midinferior septum and a second on the anterior wall near the insertion of the anterior papillary muscle. We therefore have defined normal quantitative characteristics of left ventricular bipolar electrograms and the normal left ventricular activation sequence in the intact normal human left ventricle.

Circulation 70, No. 1, 37-42, 1984.

NORMAL left ventricular endocardial activation and electrographic characteristics in man have not previously been described in vivo. It is imperative to establish normal guidelines if this technique is to be used to evaluate conduction defects, infarction, or arrhythmias. Our study was designed to characterize the electrograms and sequence of ventricular activation obtained during sinus rhythm by catheter endocardial mapping of the normal human left ventricle.

Methods

Patient population. Fifteen patients referred to the Hospital of the University of Pennsylvania for electrophysiologic evaluation underwent sinus rhythm endocardial mapping during the course of their examinations. There were eight male and seven female subjects with a mean age of 30 years (range 17 to 64).

In no patient was there evidence of structural heart disease. All had normal M mode and two-dimensional echocardiograms.

From the Clinical Electrophysiology Laboratory, Hospital of the University of Pennsylvania, Cardiovascular Section, Department of Medicine, University of Pennsylvania School of Medicine, Philadelphia.

Supported in part by grants from The American Heart Association, Southeastern Pennsylvania Chapter, Philadelphia; grant Nos. HL00361 and HL24278 from The National Heart, Lung and Blood Institute, Bethesda; and the Fannie E. Ripple Foundation, Morristown, NJ.

Address for correspondence: Mark E. Josephson, M.D., Cardiovascular Section, Room 658 Ravdin Building, Hospital of the University of Pennsylvania, 3400 Spruce St., Philadelphia, PA 19104.

Received Oct. 28, 1984; revision accepted Feb. 23, 1984.

Dr. Cassidy is supported by a Canadian Heart Foundation Research Fellowship, Ottawa.

Dr. Marchlinski and Dr. Buxton are supported by the University of Pennsylvania Department of Medicine Measey Foundation.

Dr. Josephson is the Robinette Foundation Associate Professor of Medicine (Cardiovascular Diseases).

Ten of the 15 patients had normal left ventricular radionuclide-gated blood pool scans and in 10 (including five who did not undergo radionuclide-gated blood pool scanning) of the 15 patients results of left heart catheterization and coronary angiographic examination were normal. All patients had normal PR and QRS intervals and normal electrical axes. In two patients intermittent long QT intervals were documented (one drug-related and the other idiopathic). Electrocardiograms of both patients were normal at the time of endocardial mapping. There was no evidence of a preexcitation syndrome in any patient, as determined clinically and by laboratory testing. Electrophysiologic studies were performed to determine the presence or absence of a variety of arrhythmias. Three patients had sustained ventricular tachycardia in the absence of structural heart disease.

Electrophysiologic study. Studies were performed in patients in the nonsedated, postabsorptive state after informed written consent had been obtained. Antiarrhythmic drug therapy was discontinued at least five half-lives before endocardial mapping. Drug levels were not obtained at the time of study. One quadripolar catheter (No. 6F USCI) was inserted percutaneously into the femoral artery of each patient and advanced to the left ventricle under fluoroscopic guidance. One to two quadripolar catheters were inserted percutaneously and were advanced to the right ventricular apex and right ventricular outflow tract. Catheters had a 5 mm interelectrode distance and the width of the electrode ring was 2 mm. Heparin, 5000 units as a bolus followed by 1000 units/hr, was administered after insertion of the arterial catheter in all patients.

The left ventricular mapping scheme used is shown in figure 1. The 12 sites represent segmental areas of the heart of approximately 5 to 10 cm². Ten to 22 electrograms were recorded in each patient. The catheter sites were verified by multiple-plane fluoroscopy. The catheter was repositioned to the same site to confirm reproducibility of recordings. Stability was ensured by recording from each site for a minimum of 5 to 30 sec. Electrograms were recorded with a 10 mm interelectrode distance. This was accomplished with the distal electrode paired to the third

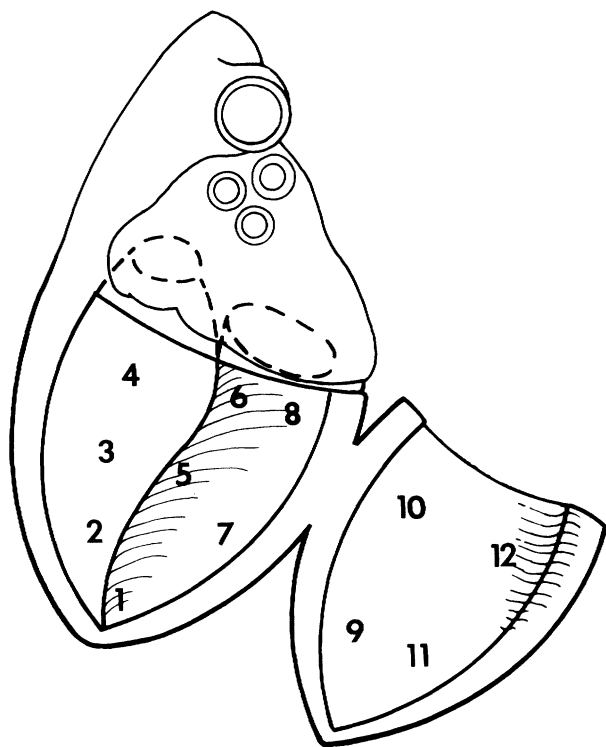


FIGURE 1. Schema of mapping sites in the left ventricle. Site 1 is the apex; sites 2, 3, 4 are on the septum. Sites 5 and 7 are on the inferior wall and sites 6 and 8 are on the posterior base. Sites 9 and 10 are on the lateral wall and sites 11 and 12 are on the anterior wall.

electrode ring. All electrograms were filtered at 30 to 500 Hz. The intracardiac electrograms were recorded at variable gain to achieve the best electrographic definition and were accompanied by a 1 mV calibration obtained from an isolated 1 mV input signal similarly filtered at a 30 to 500 Hz band pass. A 10 mm bipolar fixed-gain signal was recorded at 1 cm/mV amplification at each site. Intracardiac recordings were simultaneously displayed on a multichannel oscilloscope (Electronics for Medicine VR 16) and were stored on analog magnetic tape (Honeywell 5600) and recorded on a 16-channel Mingograf (Siemens-Elema) at a paper speed of 200 mm/sec.

Definitions. Electrographic amplitude (in mV) was defined as the maximum upward to maximum downward deflection measured by the 10 mm variable-gain bipolar electrogram. Electrographic duration (in msec) was defined as the time from the earliest electrical activity to the onset of the decay artifact produced by the amplified filtered signal measured in the 10 mm fixed-gain bipolar electrogram. The amplification and duration measurements were combined to give an amplitude/duration ratio to allow equal emphasis to be placed on each of these values. Local activation time at a site was defined as the time from the onset of the surface QRS to the time at which the largest rapid deflection crossed the baseline measured in the 10 mm variable-gain bipolar electrogram. Examples of the measurement technique in two typical recording sites are shown in figure 2.

Normal electrographic amplitude was defined as that amplitude (or greater) that characterized 95% of the electrograms and normal electrographic duration was defined as that duration (or less) that characterized 95% of the electrograms.

Electrograms were defined as basal (sites 4, 6, 8, 10, and 12) or nonbasal (sites 1, 2, 3, 5, 7, 9, and 11).

Data analysis. Electrographic amplitudes, durations, and activation times and onset of surface QRS complexes were as-

essed at each site by at least two independent observers. Four to eight complexes were assessed at each site. When more than one electrogram was obtained at a given site, the mean of all the electrograms at that site was used for analysis. Results are expressed as mean \pm SD. The Student's *t* test for unpaired data was used when comparing electrographic characteristics in regions of the left ventricle.

Results

General description. One hundred fifty-six electrograms (both variable and fixed gain) were obtained in 10 patients for quantitative analysis of characteristics of amplitude and duration. The use of mean values for multiple electrograms recorded from the same defined sites left 112 electrograms for analysis. Two hundred fifteen electrograms (variable gain only) were obtained in 15 patients for analysis of left ventricular endocardial activation time. When only one electrogram per site was used, 169 electrograms were analyzed for activation time. There was no significant difference in activation times or electrographic characteristics when the total number of electrograms or when the per site mean average of electrograms were analyzed. We have therefore reported our results using the per site mean average. Electrographic characteristics and activation times in the three patients with ventricular tachycardia were not significantly different from those of the other patients.

Descriptive characteristics. Electrograms from normal left ventricles had rapid deflections and distinct components. Low-amplitude slow activity of only a few

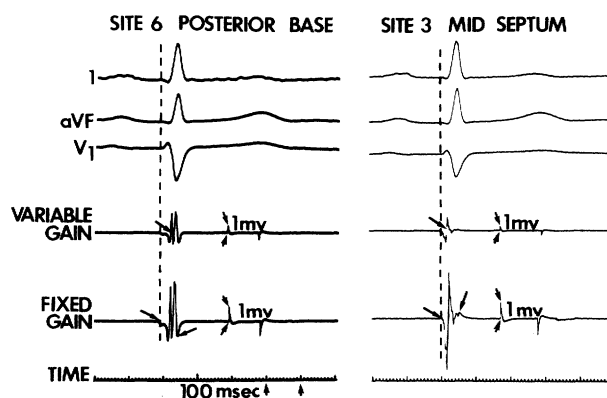


FIGURE 2. Left, A posterobasal site. Right, The midseptum. Surface electrocardiographic leads (I, aVF, V₁) are accompanied by two intracardiac recordings (variable gain, fixed gain). Each electrogram is accompanied by a 1 mV calibration signal. Arrows indicate 1 mV. The vertical dashed line denotes onset of surface QRS activity. The arrow on the variable-gain electrogram shows local activation time, while the arrows on the fixed-gain electrograms show onset and offset of local electrical activity. Note that the arrows marking the offset show the artifact produced by the decay of the amplified filtered signal. This is also seen on the 1 mV calibration signals. Time line is marked at bottom of figure.

TABLE 1
Summary of electrographic characteristics of normal left ventricles

	All sites	Basal sites	Nonbasal sites	p value
Amplitude (mV)				
Mean \pm SD	6.7 \pm 3.4	6.5 \pm 3.2	6.9 \pm 3.5	NS
95% \geq	3.0			
Range	1.5–21			
Duration (msec)				
Mean \pm SD	54 \pm 13	60 \pm 14	50 \pm 11	<.001
95% \leq	70			
Range	18–82			
Amplitude/duration ratio (mV/msec)				
Mean \pm SD	0.133 \pm 0.073	0.116 \pm 0.070	0.144 \pm 0.074	<.05
95% \geq	0.046			
Range	0.031–0.438			
No. of electrograms	112	45	67	

milliseconds (range 2 to 15) duration was recorded at the beginning of all electrograms. No split, fractionated, or late electrograms were observed.^{1–8}

Quantitative characteristics. Results of the quantitative analysis of normal electrographic characteristics are listed in table 1. Mean electrographic amplitude was 6.7 \pm 3.4 mV and 95% of the electrograms were of an amplitude of 3 mV or greater. Mean electrogram duration was 54 \pm 13 msec; 95% of the electrograms were of 70 msec or less duration. Mean electrogram/duration ratio was 0.133 \pm 0.073 mV/sec and the ratio for 95% of the electrograms was 0.045 mV/msec or greater. Quantitative descriptions of all electrograms recorded are listed in table 2.

Basal electrograms tended to be of lower amplitude (6.5 vs 6.9 mV; p = NS), of greater duration (60 vs 50 msec; p < .001), and to have a lower amplitude/duration ratio (0.166 vs 0.144 mV/msec; p < .05).

Left ventricular endocardial activation. Left ventricular endocardial activation began at 0 to 15 msec (mean 6) after the onset of the QRS. Left ventricular endocardial activation was completed at 29 to 52 msec (mean 43). The duration of left ventricular endocardial activation ranged from 28 to 50 msec (mean 36). This comprised 41% of the total surface QRS complex (mean QRS duration 87 msec, range 80 to 100). Analog and isochronic maps for a typical patient are illustrated in figures 3 and 4, respectively.

A definitive pattern of left ventricular endocardial activation was observed, although some patient-to-patient variability existed. The inferior border of the middle septum was the earliest area of left ventricular endocardial activation, while the superior-basal aspect of the free wall was a second endocardial breakthrough site. Moreover, the first and second earliest sites of endocardial breakthrough were nonadjacent 67% (10/

TABLE 2
Electrographic amplitude and duration characteristics in normal left ventricles

Patient No.	Left ventricular site ^A											
	1	2	3	4	5	6	7	8	9	10	11	12
1	6.7/45	4.8/50	5.4/62	3.1/69	6.5/62	3.7/72	7.0/60	7.0/70	4.2/52	3.2/70	6.0/50	6.2/56
2	8.5/60	9.0/55	7.3/56	—	7.8/55	7.5/50	11.2/50	7.5/52	3.2/60	8.5/60	4.5/52	8.5/48
3	21/48	5.6/48	4.5/57	3.3/62	9.3/53	4.4/62	7.0/46	2.0/48	4.8/56	3.0/63	—	—
4	4.8/47	4.7/48	6.0/40	—	5.1/40	4.8/48	9.7/40	9.3/46	5.4/18	11.5/62	5.2/40	8.2/40
5	3.3/48	10/40	2/25	6.3/42	6.2/26	8.0/22	3.3/26	9/43	7/30	10.6/46	3/58	6/28
6	6.8/46	8.5/50	5.3/52	—	7.8/52	5.2/70	3.9/33	7.1/59	—	3.4/76	4.8/53	6.2/68
7	11.2/58	5.4/65	4.4/60	3.8/69	2.9/55	7.2/79	6.4/65	11.5/80	17.5/62	7.8/56	4.5/70	3.6/58
8	2.7/37	8.5/40	1.6/51	3.4/56	5.2/47	3.0/49	4.5/46	4.5/59	5.0/64	2.8/58	4.7/21	1.5/46
9	9.2/55	6.7/57	14.5/60	5.0/75	15.1/53	6.0/82	7.8/45	7.0/78	8.5/60	14.5/75	8.8/50	—
10	13/50	6.6/50	4.4/54	6.4/70	—	11.4/75	9.3/46	5.0/70	10.0/60	15.5/70	6.5/49	8.5/67

Values are amplitude (mV)/duration (msec).

^ASites correspond to those in figure 1.

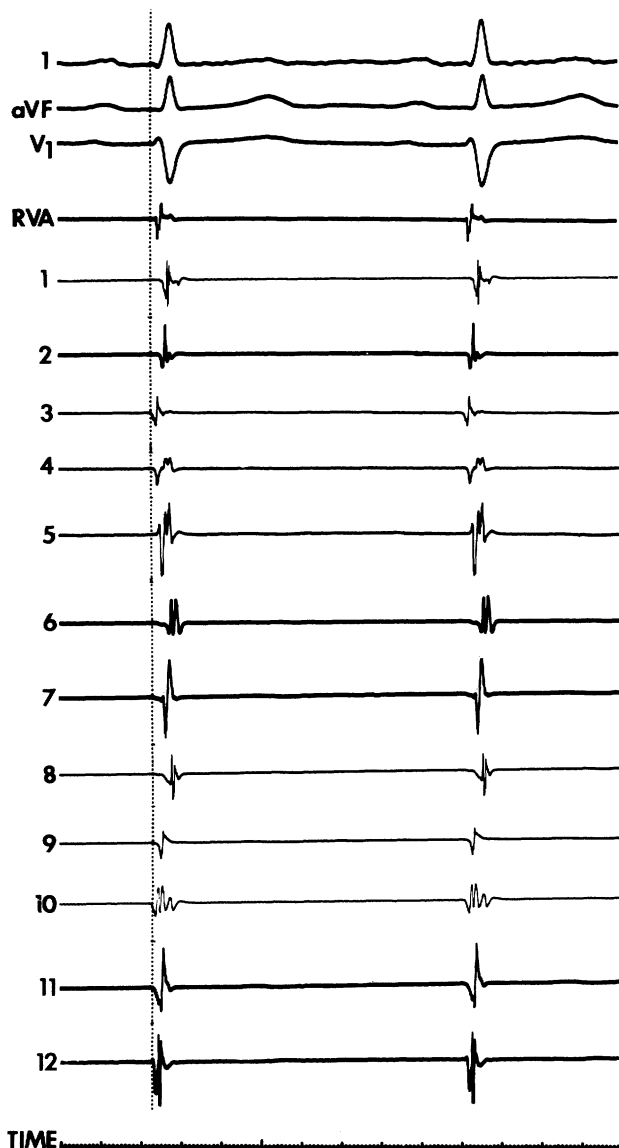


FIGURE 3. Analog map from a patient in sinus rhythm. The three surface QRS leads (I, aVF, V₁) are accompanied by the right ventricular apex (RVA) reference and 12 left ventricular (1 through 12) sites. Vertical line denotes onset of surface QRS activity (see text for discussion).

15) of the time. Activation then appeared to spread radially from these breakthrough sites so that the apex was activated relatively late while the base at the inferior posterior wall was consistently the last area to be activated. The isochronic map of left ventricular endocardial activation along with mean values per site for the entire group are shown in figure 5.

Discussion

Description of electrograms. This is the first attempt during cardiac catheterization to examine endocardial bipolar electrograms of intact normal left ventricles and to characterize these electrograms; previously only unipolar epicardial electrograms have been described

semiquantitatively in man.⁹ The normal left ventricular bipolar electrogram was characterized by an amplitude greater than 3 mV and a duration of less than 70 msec. No split, fractionated, or late electrograms were found, confirming preliminary data from our laboratory in which different catheters and nonstandardized methods were used.³ The present results are based on a 10 mm interelectrode distance and specified filter and gain settings. The importance of rigid adherence to the technical considerations of interelectrode distance, filter settings, and amplifier gain cannot be overemphasized. These factors are known to influence characteristics of recorded electrograms.^{10, 11}

Of interest is the difference noted in electrograms recorded at the base compared with those from the remainder of the heart. The lower amplitude and wider duration was most pronounced at the inferoposterior basal portion of the left ventricle. There are a number of possible explanations for this finding. Purkinje fibers are less dense at the base of the heart and hence more muscle-to-muscle electrical activation may take place, which could account for the longer electrogram duration.¹² Fiber orientation, which is different at the base, can influence electrographic amplitude and duration if the bipolar pair is recorded perpendicular to the

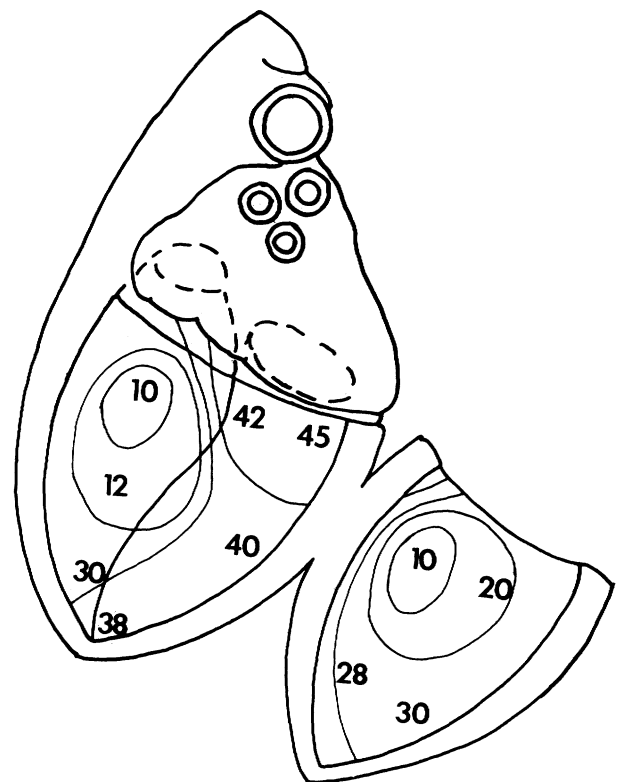


FIGURE 4. Accompanying sinus rhythm isochronic map from same patient as in figure 3. Numbers represent local left ventricular activation time. Lines represent 10 msec isochrones (see text for discussion).

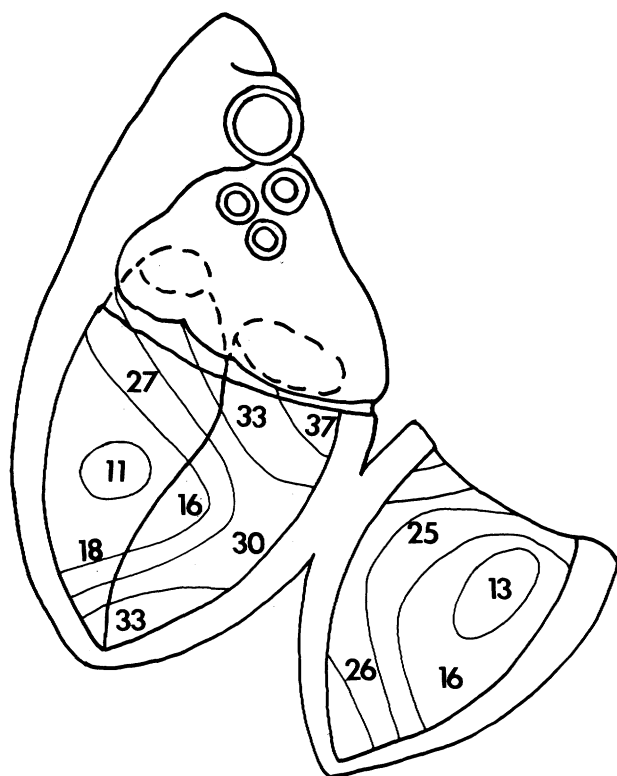


FIGURE 5. Sinus rhythm isochronic map for entire group. Numbers represent mean values for local activation times for the entire group. Lines represent 5 msec isochrones. Note two endocardial breakthrough sites.

main fiber orientation. A third possibility is related to the electrode contact, which due to technical considerations is different at the base than in the remainder of the left ventricle. The role of catheter and electrode position in causing the differences in electrograms recorded from the base may be resolved in a setting in which direct electrode recordings can be made. Thus, location in the left ventricle must also be considered when assessing electrographic characteristics.

We believe the formulation of an amplitude/duration ratio is useful. Ischemic injury can influence both amplitude and duration measurements, but the order and magnitude of change has not been reported.¹³ Consideration of either parameter in isolation may result in the inaccurate interpretation of a finding. The calculated amplitude/duration ratio may balance these equally important parameters and may prove useful in the analysis of abnormal electrograms.

Activation. The earliest descriptions of sinus rhythm activation have dealt with depolarization sequence in animal hearts¹⁴⁻¹⁷ and have been summarized in recent reviews.¹⁸⁻²⁰

The left ventricular endocardium is activated near the terminations of the left bundle branch slightly before the right ventricular endocardium. Activation of

the septum is mainly left to right but does proceed in both directions. The entire endocardium is activated rather rapidly via the Purkinje network. The more thinly walled right ventricle has an earlier epicardial breakthrough than the thicker left ventricular wall. The wave of depolarization soon encompasses the entire septal and apical myocardium, leaving the basal and posterior aspects of the heart to be the latest areas excited.

Except for a small number of studies of epicardial and intramural recordings in isolated postmortem hearts,^{9, 21-25} prior work in human hearts has been largely limited to the study of epicardial recordings. Our study is the first description of endocardial activation in the intact normal left ventricle.

We have described two separate sites of earliest endocardial activation — the middle inferior septum and the anterior wall in the area of the insertion of the anterior papillary muscle. Our data are similar to the findings of Durrer et al.²⁴ who, in addition, described a third breakthrough site at the inferior paraseptal region. This third breakthrough site would be adjacent to the earliest site that we noted on the middle septum. Our inability to distinguish a third breakthrough site may be explained by the limited number of sampling points available to us using endocardial catheter mapping.

Our data suggest that, after initial activation, electrical activity spreads radially and rapidly from these breakthrough points to converge at the apex and finally the inferoposterior base. The observation that the apex is activated “relatively late” (last 25% of left ventricular endocardial activation) has not been noted previously. An explanation for this is not apparent since prior work in canine preparations has shown that the Purkinje fiber network is extensive to the apex.¹⁷

Although we have measured total endocardial activation time in the normal left ventricle, it is not possible with the present techniques to derive conduction velocities. The establishment of a normal left ventricular endocardial activation time will allow the evaluation of the mechanism of conduction abnormalities on the surface electrocardiogram.

Limitations. The standard catheter used by most laboratories has a 10 mm interelectrode distance. This relatively wide interelectrode distance records more distant activity^{11, 14} than that recorded from very narrow bipolar electrodes; therefore, the interpretation of what constitutes local activity remains a difficult one. The occurrence of low-amplitude slow activity recorded with all electrograms may represent more distant activity; however, we believed, for the sake of reproducibility, that this should be included in the measure-

ment of duration of the local electrogram. A similar analysis of electrograms with the use of electrodes with smaller surface areas and narrower interelectrode distance is possible during surgery.

The absolute definition of electrographic amplitude obtained with a bipolar recording system must be interpreted with caution. The direction of the wavefront in relation to the recording bipole can have a definite effect on the recorded amplitude. A similar word of caution should be expressed concerning the choice of filter settings used. The narrower the band pass selected the lower the amplitude of the recorded signal obtained. The effect that filter settings have on electrographic duration has not been fully described. The quantitative characteristics presented in this report were determined at predefined amplifier and filter settings; deviation from these settings may produce results that are not comparable to those presented here.

The number of sites that can be sampled by catheter mapping is more limited than with direct visualization procedures. Conclusions concerning activation time must recognize this limitation. However, our results are similar to those of the more detailed studies *in vitro* by Durrer *et al.*²⁴ who used a larger number of electrograms.

Potential uses. The definition of characteristics of the normal left ventricular endocardial electrogram and of normal activation sequence can now be applied to the analysis of various clinical abnormalities. A greater understanding of conduction disturbances and abnormal activation sequences related to myocardial damage should be possible. Finally, sinus rhythm mapping has been suggested as a means to localize ventricular tachycardia.^{4-8, 26} The values presented here provide a framework for characterization of abnormal electrograms and, thus, a critical assessment in this application.

References

- Boineau JP, Cox JL: Slow ventricular activation in acute myocardial infarction. *Circulation* **68**: 702, 1973
- Josephson ME, Horowitz LN, Farshidi A: Continuous local electrical activity: A mechanism of recurrent ventricular tachycardia. *Circulation* **57**: 659, 1978
- Untereker WJ, Spielman SR, Laskey W, Greenspan AM, Hirshfeld JW, Goldberg S, Horowitz LN, Kastor JA, Josephson ME: The endocardial electrogram as a predictor of wall motion. *Circulation* **62** (suppl II): II-249, 1980
- Waldo AL, Arciniegas JG, Klein H: Surgical treatment of life-threatening ventricular arrhythmias: The role of intraoperative mapping and consideration of the presently available surgical techniques. *Prog Cardiovasc Dis* **23**: 247, 1981
- Josephson ME, Horowitz LN, Spielman SR, Waxman HL, Greenspan AM: Role of catheter mapping in the preoperative evaluation of ventricular tachycardia. *Am J Cardiol* **49**: 207, 1982
- Gallagher JJ, Kasell JH, Cox JL, Smith WM, Ideker RE, Smith WM: Techniques of intraoperative electrophysiologic mapping. *Am J Cardiol* **49**: 221, 1982
- Wiener I, Mindich B, Pitchon R: Determinants of ventricular tachycardia in patients with ventricular aneurysms: Results of intraoperative epicardial and endocardial mapping. *Circulation* **66**: 856, 1982
- Klein H, Karp RB, Kouchoukos NT, Zorn GL, James TN, Waldo AL: Intraoperative electrophysiologic mapping of the ventricles during sinus rhythm in patients with a previous myocardial infarction. *Circulation* **66**: 847, 1982
- Jouve A, Corriol J, Torresani J, Benyamine R, Velasque P, Peytavy R: Epicardial leads in man. *Am Heart J* **59**: 856, 1960
- Durrer D, van der Tweel LH, Blickman JR: Spread of activation in the left ventricular wall of the dog III. *Am Heart J* **48**: 13, 1954
- Waxman HL, Sung RJ: Significance of fragmented ventricular electrograms observed during intracardiac recording techniques in man. *Circulation* **62**: 1349, 1980
- Scher AM: The sequence of ventricular excitation. *Am J Cardiol* **14**: 287, 1964
- Kaiser GA, Waldo AL, Harris PD, Bowman FO, Hoffman BF, Malm JR: New method to delineate myocardial damage at surgery. *Circulation* **39** (suppl I): I-83, 1969
- Harris AS: The spread of excitation in turtle, dog, cat and monkey ventricles. *Am J Physiol* **134**: 319, 1941
- Sodi-Pallares D, Bisteni A, Medrano GA, Cisneros F: The activation of the free left ventricular wall in the dog's heart. *Am Heart J* **49**: 587, 1955
- Durrer D, van der Tweel LH, Berreklouw S, van der Wey LP: Spread of activation in the left ventricular wall of the dog IV. *Am Heart J* **50**: 860, 1955
- Spach MS, Huang S, Ayers CR: Electrical and anatomic study of the Purkinje system of the canine heart. *Am Heart J* **65**: 664, 1963
- Sodi-Pallares D, Calder RM: New bases of electrocardiology. St. Louis, 1956, The C. V. Mosby Company, p 358
- Scher AM: Excitation of the heart. *In* Hamilton WF, Dow P, editors: Handbook of physiology, section 2. *Circulation*, vol 1. Baltimore, 1962, The Williams & Wilkins Company, p 287
- Scher AM, Spach MS: Cardiac depolarization and repolarization and the electrocardiogram. *In* Berne RM, Sperelakis N, Geiger SR, editors: Handbook of physiology, section 2. The cardiovascular system, vol 1. Baltimore, 1979, The Williams & Wilkins Company, p 357
- Barker PS, MacLeod AG, Alexander J: The excitatory process observed in the exposed human heart. *Am Heart J* **5**: 720, 1930
- Durrer D, Buller J, Graff P, Lo GI, Meyler FL: Epicardial excitation pattern as observed in the isolated revived and perfused fetal human heart. *Circ Res* **9**: 29, 1961
- Roos JP, Van Dam RTh, Durrer D: Epicardial and intramural excitation of normal heart in six patients 50 years of age and older. *Br Heart J* **30**: 630, 1968
- Durrer D, Van Dam RTh, Frend GE, Janse MJ, Meijler FL, Arzbaeher RC: Total excitation of the isolated human heart. *Circulation* **41**: 899, 1970
- Wyndham CR, Meeran MK, Smith T, Saxena A, Engelman RM, Levitsky S, Rosen KM: Epicardial activation of the intact human heart without conduction defect. *Circulation* **59**: 161, 1979
- Kienzle MG, Falcone RA, Kempf FC, Miller JM, Harken AH, Josephson ME: Intraoperative endocardial mapping: Relation of fractionated electrogram in sinus rhythm to endocardial activation in ventricular tachycardia — surgical implications. *Am Coll Cardiol* **1**: 582, 1983