

## Intraoperative detection of myocardial ischemia in high-risk patients: electrocardiography versus two-dimensional transesophageal echocardiography

JOHN S. SMITH, M.D., MICHAEL K. CAHALAN, M.D., DAVID J. BENEFIEL, M.D.,  
BENJAMIN F. BYRD, M.D., FRANCIS W. LURZ, M.A., WILLIAM A. SHAPIRO, M.D.,  
MICHAEL F. ROIZEN, M.D., ALAIN BOUCHARD, M.D., AND NELSON B. SCHILLER, M.D.

**ABSTRACT** Because acute segmental wall motion abnormalities (SWMAs) of the left ventricle are highly sensitive and specific indicators of myocardial ischemia, this study compared the incidence and significance of ischemia, as detected by two-dimensional transesophageal echocardiography and surface electrocardiography, during anesthesia and surgery in patients at high risk of myocardial ischemia. During surgery, 24 of the 50 patients studied had new SWMAs, whereas only six had ST segment changes. All patients with ST segment changes also had new SWMAs: in three instances, SWMAs occurred before the ST segment change, and in three instances, they occurred simultaneously. All three patients who had intraoperative myocardial infarctions also had persistent intraoperative SWMAs, whereas only one patient had ST segment changes. Ten healthy patients requiring noncardiovascular surgery were monitored similarly; none of these had SWMAs, ST segment changes, or myocardial infarction. This study demonstrates the superiority of two-dimensional transesophageal echocardiography over electrocardiography for the intraoperative detection of myocardial ischemia. Furthermore, when new SWMAs persist to the conclusion of surgery, myocardial infarction is likely to have occurred.

*Circulation* 72, No. 5, 1015–1021, 1985.

DESPITE THE AVAILABILITY of aggressive intraoperative cardiac monitoring and therapy, myocardial ischemia and infarction remain common causes of perioperative morbidity and mortality.<sup>1, 2</sup> The standard surface electrocardiogram (ECG) may not reveal subendocardial ischemia.<sup>3</sup> Even severe transmural ischemia may go undetected if only a single electrocardiographic lead is monitored,<sup>4</sup> if excessive filtration is used, or if signal standardization is inappropriate. Furthermore, electrocardiographic monitoring for the detection of ischemia may be impossible if certain conduction disturbances or paced rhythms are present.<sup>5, 6</sup> Nevertheless, the ECG remains the monitor most commonly used to diagnose intraoperative myocardial ischemia.

In 1935 Tennant and Wiggers<sup>7</sup> demonstrated that acute coronary ligation results in paradoxical motion in the ischemic area. Subsequently, wall motion abnormalities have been shown to occur within seconds of the onset of regional ischemia,<sup>8–11</sup> simultaneously with regional lactate production,<sup>12</sup> but before (and even in the absence of) changes on the surface ECG.<sup>13</sup> Because two-dimensional echocardiography reliably detects segmental wall motion abnormalities (SWMAs),<sup>14</sup> this technique may be a more sensitive measure of intraoperative myocardial ischemia than electrocardiography. However, precordial echocardiographic methods are impractical during surgery. In contrast, two-dimensional transesophageal echocardiography can be used during surgery and has been shown to provide safe, reproducible images of the left ventricle.<sup>15, 16</sup>

To compare the incidence of myocardial ischemia, as detected by the occurrence of new SWMAs on echocardiograms, with the incidence as detected by ST segment changes on ECGs, we studied patients at high risk of myocardial ischemia during anesthesia and surgery. Furthermore, we tested whether these

From the Departments of Anesthesia and Medicine, Division of Cardiology, University of California, San Francisco.

Supported by NIH grants No. 1R23GM-28502-03 and NIA 1 PO 1 AG03104-02,3 and the Anesthesia Research Foundation.

Address for correspondence: Michael K. Cahalan, M.D., Department of Anesthesia, University of California, Third and Parnassus Avenues, Room S436, San Francisco, CA 94109.

Presented in part at the annual meetings of the Society of Cardiovascular Anesthesiologists and the American Society of Anesthesiologists in 1984.

changes accurately predicted perioperative myocardial infarction.

## Methods

With approval from our committee on human experimentation and informed consent, we prospectively studied 50 patients: 29 undergoing vascular surgery and 21 undergoing coronary artery bypass grafting (CABG). We documented preoperatively any history of angina or myocardial infarction and extent of coronary disease revealed on the angiogram (when available). On the morning of surgery, patients were given their usual medications and appropriate preanesthetic medications. In the operating room, a conventional electrocardiographic system (Marquette MAC-1; Marquette Electronics, Milwaukee, WI), standardized to 10 mm/mV, was attached to the patient. A baseline ECG consisting of leads I, II, III, aVR, aVL, aVF, and V<sub>5</sub> was recorded, and induction of anesthesia was begun. In the last 30 patients, we recorded the ECG every 3 min during induction of anesthesia and endotracheal intubation. Once the endotracheal tube was in place, we introduced into the esophagus a 9 mm (diameter) gastroscope that had a 3.5 MHz phased-array transducer (Diasonics, Inc.; Milpitas, CA) on its tip.

The transducer was connected to an ultrasonograph (Diasonics 3400R or CV-60) focused at 10 cm. We positioned the transducer behind the heart to obtain a short-axis, cross-sectional view of the left ventricle at the level of the papillary muscles (figure 1, A). After insertion of the transducer (routinely requiring 15 to 30 sec), we recorded echocardiographic images at predetermined intervals for 60 sec on ½ inch VHS videotape. At the same time, ECGs were recorded. For all patients, one baseline echocardiogram was recorded before skin incision, and a second one within 3 min after skin incision. In those undergoing vascular surgery, recordings were made 3 min before vascular cross-clamping, 3 min after cross-clamping, 30 min after cross-clamping (if the clamp was still in place), and after unclamping. In those undergoing CABG, recordings were made after sternal split, before institution of cardiopulmonary bypass, 5 min after cessation of bypass, 30 min after bypass (if the chest was still open), and after sternal closure. The concluding echocardiogram and ECG were recorded in all patients during skin closure.

The diagnosis of myocardial infarction was based on postoperative ECGs and creatine kinase (CK) isoenzyme levels, which were determined in all patients. Additionally, technetium pyrophosphate scans were obtained in 18 of 21 patients undergoing CABG.

**Data analysis.** After surgery, ECGs were analyzed with the use of conventional criteria for the diagnosis of ischemia: horizontal or downsloping ST segment depression of at least 1 mm, or ST segment elevation of more than 1 mm (compared with baseline) 80 msec after the J point. The echocardiograms of all intervals were transcribed into a standard format for analysis and were analyzed by modification of the method of Van Reet *et al.*<sup>17</sup> The cross-sectional image was divided into quadrants with the papillary muscles as guides. This floating-reference system keyed to the papillary muscles compensated for translational and rotational movements of the heart. Only the short-axis view at the level of the papillary muscles was analyzed because this view was maintained throughout the study in each patient. Based on our studies in patients without cardiovascular disease,<sup>18</sup> a segment was considered to contract normally if an imaginary radius to the center of the left ventricle shortened by more than 30% and the wall thickened considerably. Mild hypokinesia was considered to occur if shortening of the radius was less than 30% but more than 10% and the wall thickened. Severe hypokinesia was diagnosed if the wall thickened minimally and radial shortening was less than 10%. An akinetic segment was

defined as one in which the wall did not thicken during systole, and a dyskinetic segment as one in which the wall bulged and thinned during systole. This analysis system is qualitative and the estimates of endocardial motion and myocardial thickening are made visually. With the use of the first echocardiogram as a baseline recording, we subsequently judged a segment to be ischemic if it worsened by two or more classifications without the entire image doing likewise. A change was considered transient if it resolved before skin closure (figure 1), and persistent if it did not. Echocardiograms were considered unreadable if the short-axis view was unobtainable, if the orientation changed, or if image definition was insufficient to detect wall thickening. The echocardiograms were analyzed by two independent observers who were unaware of the patient's clinical course or the results of electrocardiographic analysis. All disagreements were arbitrated by a third observer, our senior echocardiographer (N.B.S.).

To describe and compare echocardiographic results with electrocardiographic findings, we used a modification of the method of Heger *et al.*<sup>19</sup>: the cross section was considered to consist of four regions, each of which could be subdivided for analysis if necessary (figure 2).

**Verification of probe position.** To ensure the ability to re-gain consistently the same cross section when the probe or the heart was moved, we performed the following procedure in 10 consecutive patients undergoing CABG. After recording during skin closure, we deliberately unlocked and advanced the probe 2 cm into the esophagus, and then attempted to locate the previous image and record it. Similarly, we pulled the probe back 2 cm toward the mouth and repeated the same procedure. These images were edited and retaped to disguise any association and were submitted for analysis. All images were graded by the same two observers, and the wall motion scores from the two relocated echocardiograms were compared with those from the echocardiograms taken at skin closure. Additionally, using a semiautomatic light-pen system (Diasonics), we compared cross-sectional areas at end-diastole and end-systole.

**Incidence of intraoperative SWMAs in non-high-risk patients.** To determine the incidence of intraoperative SWMAs in healthy adults, we studied 10 patients (28 to 54 yr of age) who had no evidence of cardiovascular disease and required noncardiovascular surgical procedures. In these patients two-dimensional transesophageal echocardiograms were recorded after induction of anesthesia, 1 to 3 min after skin incision, and 10 to 20 min after skin incision. These images were rerecorded onto the same tapes that contained the images from our high-risk patients, but were disguised to prevent observers from knowing their origins.

## Results

**High-risk patients.** Thirty-four of the 50 patients in this study had at least one prior myocardial infarction. In 28 of these 34 patients SWMAs were detected on the baseline echocardiogram. Of the 16 patients having no history of myocardial infarction, one patient had a baseline area of hypokinesia, and 15 had no SWMAs. Forty-three patients had a history of angina. Of the 21 patients studied with coronary angiography, 16 had triple-vessel disease and five double-vessel disease.

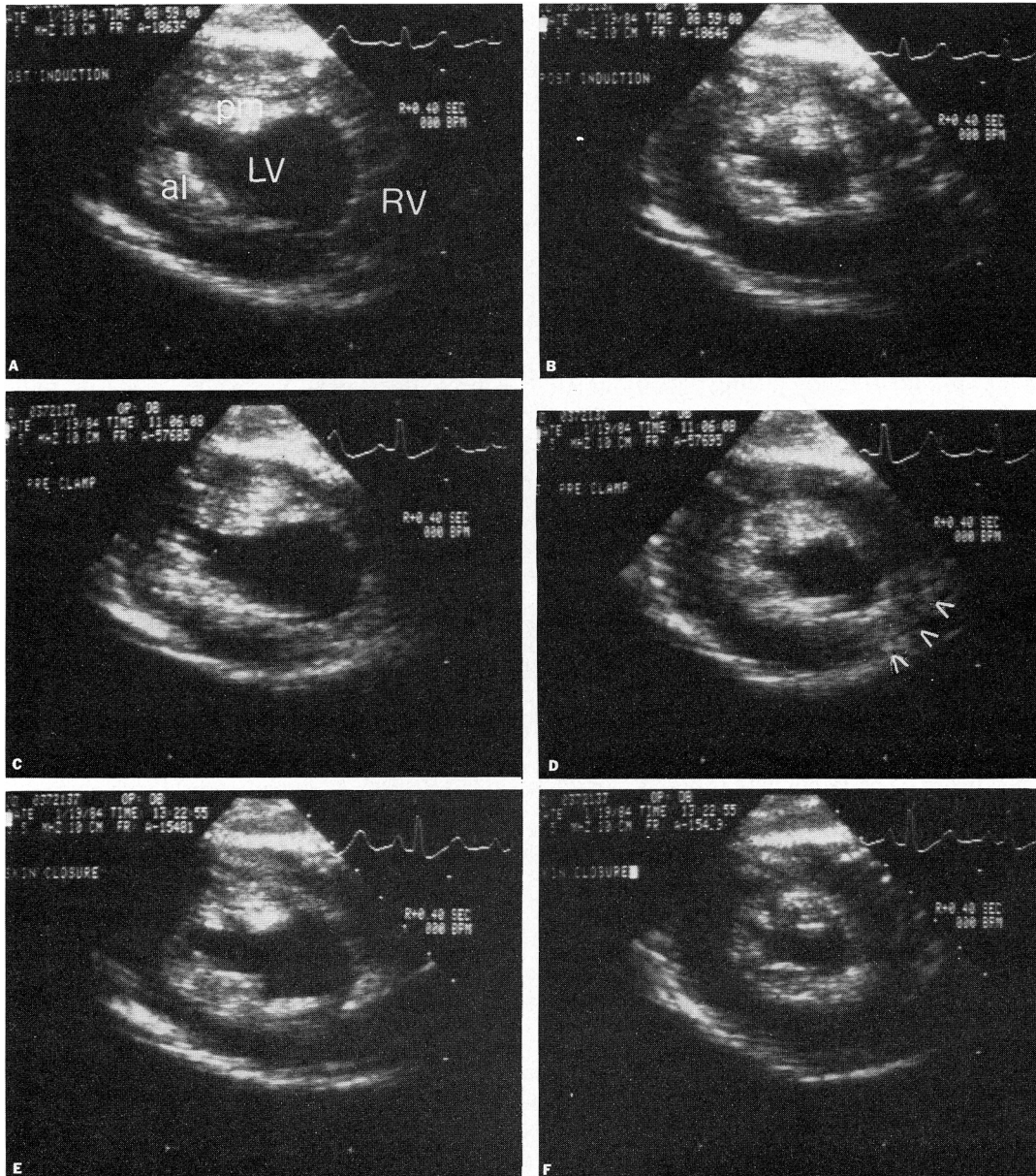
We obtained echocardiograms adequate for analysis of SWMAs in 339 of the 350 measurement intervals attempted. In only one patient were we unable to obtain the appropriate cross section at any time. Four

patients had a single interval for which the echocardiogram could not be analyzed. Each of these four instances occurred after cardiopulmonary bypass.

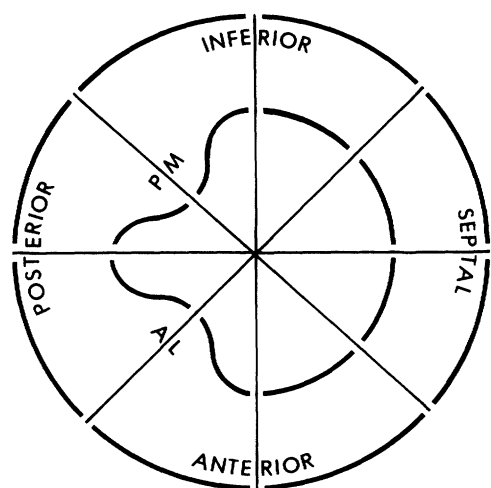
We were able to analyze the ST segment of the ECG for 342 of 400 intervals. Five patients had either left bundle branch block or a ventricularly paced rhythm throughout the surgical procedure. Eleven other patients had at least one interval in which the ST segment could not be analyzed because of a transient conduction disturbance or because heart rhythm was con-

trolled: for one patient (undergoing vascular surgery), this interval occurred after aortic cross-clamping, at which time rhythm was controlled by a demand pacemaker; for 10 patients, this interval occurred after cardiopulmonary bypass.

Five of the 30 patients studied with sequential ECGs during induction of anesthesia had ST segment changes diagnostic of ischemia at this time: the ST segments changed in all leads in two patients; in leads II, III, and aVF in two patients; and in only lead V<sub>5</sub> in



**FIGURE 1.** Recorded after induction of anesthesia, short-axis echocardiographic images at end-diastole (A) and end-systole (B) show the left ventricle at the level of the papillary muscles. The inferior wall is nearest to the intraesophageal transducer. The orientation of all other figures is identical. LV = left ventricular cavity; RV = right ventricular cavity; pm = posteromedial papillary muscle; al = anterolateral papillary muscle. Segmental wall motion is normal. Approximately 1 hr later, the end-diastolic image (C) has not changed, but the end-systolic image (D) reveals a segmental wall motion abnormality (arrows) of the anterior-septal myocardium that resolves before completion of the surgery (E and F).



**FIGURE 2.** Schematic cross-sectional view of the left ventricle at the level of the papillary muscles depicting the octants into which the ventricle is divided and the corresponding walls. PM = posteromedial papillary muscle; AL = anterolateral papillary muscle.

one patient. These changes reverted to normal by the first postinduction recording; thereafter, none of these patients had any episode of ischemia detected on the ECG or echocardiogram. Subsequently, six of 50 patients had ST segment changes during surgery. Three changes were transient, and three were still present at skin closure. The ST segments changed in lead  $V_5$  in one patient; in leads II, III, and aVF in two patients; in leads II, III, aVF, and aVL in two patients; and in lead aVF in one patient.

During the course of surgery, 24 patients had a total of 32 new SWMAs. The locations of the SWMAs were as follows: 10, septal wall; nine, inferior wall; nine, anterior wall; and four, posterior wall. Two patients had baseline hypokinetic segments that subsequently became dyskinetic. The remaining 22 had normal baseline wall motion in the segment that subsequently developed an abnormality. Of these 22, four had segmental dyskinesis; nine, segmental akinesis; and nine, severe segmental hypokinesis. New SWMAs were detected during all intervals without a preponderance of occurrence during any one interval. Changes were transient in 16 patients but persisted through skin closure in eight. Four of five patients with double-vessel disease had new SWMAs, and these changes were in regions of myocardium supplied by the diseased coronary arteries and never in the "risk free" myocardium. Two of these patients had disease in the circumflex and anterior descending arteries and they had both anterior and septal SWMAs. The remaining two patients had circumflex and right coronary disease and had inferior SWMAs.

The six patients who had ST segment changes diag-

nostic of ischemia during surgery also had new SWMAs (table 1). In three of these patients, the wall motion abnormality appeared at least one interval before the change on the ECG. Four patients had a new SWMA when the ST segment could not be analyzed. One of these patients had left bundle branch block throughout surgery, whereas the other three had conduction disturbances after bypass. No patient had an ST segment change during an interval in which the echocardiogram could not be analyzed.

Four patients had perioperative myocardial infarction, three of which appear to have occurred intraoperatively because isoenzyme levels peaked at 8 hr after surgery. One patient had persistent inferior and posterior wall motion abnormalities; ST segment elevation in leads II, III, and aVF; and ST segment depression in lead aVL. Two patients had persistent wall motion abnormalities but no intraoperative changes on the ECG. One of these patients died, and myocardial infarction was confirmed at autopsy; the other patient had an inferior wall infarction that corresponded with the intraoperative wall motion abnormality. Finally, the fourth patient had only a transient intraoperative wall motion abnormality and no change on the ECG; myocardial infarction occurred 48 hr after surgery, and CK isoenzyme levels peaked on the third postoperative day. As determined by chi-square analysis, the patients with persistent SWMAs had a significantly higher incidence of intraoperative infarction than did patients with transient SWMAs or those without SWMAs ( $p < .05$ ).

No complications related to the use of two-dimensional transesophageal echocardiography occurred in any of our patients.

**Verification of probe position.** Deliberate repositioning of the probe never caused a change in wall motion rating of greater than one classification or any significant change in the end-systolic or end-diastolic cross-sectional area (table 2).

**Intraoperative SWMAs in non-high-risk patients.** The 10 normal patients that we examined had normal baseline wall motion, no intraoperative wall motion changes, and no postoperative evidence of myocardial infarction, as assessed by routine clinical surveillance.

## Discussion

Studies in animals have demonstrated that wall motion abnormalities progress as coronary artery constriction and myocardial ischemia increase,<sup>9-13, 20, 21</sup> and that subendocardial ischemia alone can cause severe segmental wall dysfunction.<sup>10</sup> Echocardiography has been used to detect SWMAs due to ischemia and

**TABLE 1**  
**Patients with intraoperative evidence of ischemia**

Patient No.	Ischemic changes detected by:		Perioperative myocardial infarction
	Leads of the ECG	SWMA on echocardiograms	
6	V <sub>5</sub> <sup>A</sup>	Anterior <sup>A</sup>	No
9	II, III, aVF <sup>A</sup>	Inferior <sup>A</sup>	No
17	II, III, avF	Anterior/septal	No
26	II, III, aVF, aVL	Anterior/septal	No
34	II, III, aVF, aVL <sup>A</sup>	Inferior/posterior <sup>A</sup>	Yes
46	aVF	Inferior	No
3	None	Septal	No
4	None	Anterior	No
8	None	Septal	No
10	None	Posterior	No
12	None	Anterior <sup>A</sup>	Yes
14	None	Septal/inferior	No
16	None	Septal <sup>A</sup>	No
20	None	Inferior	No
22	None	Posterior	No
24	None	Anterior/posterior	No
29	None	Inferior <sup>A</sup>	No
31	None	Anterior/septal	Yes <sup>B</sup>
35	None	Inferior	No
37	None	Anterior/septal <sup>A</sup>	No
38	None	Anterior	No
40	None	Inferior <sup>A</sup>	Yes
43	None	Septal	No
48	None	Inferior/septal	No

<sup>A</sup>Changes were persistent.

<sup>B</sup>This patient had infarction 2 days postoperatively.

infarction in experimental preparations and in patients.<sup>14, 19, 22–26</sup> For example, echocardiographically detected wall motion changes during exercise testing were shown to be sensitive and specific indicators of the presence and location of coronary artery disease.<sup>27</sup> In another study, adequate two-dimensional precordial echocardiograms were obtained in 65 of 80 consecutive patients with acute chest pain.<sup>28</sup> SWMAs occurred in 31 of the 33 patients with acute myocardial infarction, 18 of whom had nondiagnostic changes on the ECG. Additionally, 27 of 32 who did not have myocardial infarction had normal wall motion. The extent of wall motion abnormalities in patients with acute myocardial infarctions correlated with the incidence of ventricular arrhythmias, congestive heart failure, and death.<sup>29</sup>

Like Horowitz, Limacher, and others, we used a qualitative analysis of regional wall motion to detect ischemia. Since our interpretations were read by two independent observers who were guided by established criteria and were unaware of the patients' clinical courses, the chance for observer bias was minimized.

In our control patients, the two observers did not detect abnormalities, whereas in the high-risk patients, when new SWMAs persisted, the chance of myocardial infarction was high. No patient in whom there were not new intraoperative SWMAs had an immediate postoperative infarction.

Although not all patients with persistent wall motion changes had myocardial infarction, this is not surprising, and may represent either ongoing ischemia or postischemic ventricular dysfunction.<sup>30</sup> Owing to biological differences in normal patients, not all hearts contract uniformly<sup>31</sup>; however, only a pathophysiologic change would cause an acute alteration in segmental wall motion. In patients with coronary artery disease, a likely factor is regional myocardial ischemia. In fact, in our patients with angiographically demonstrated regional disease, SWMAs occurred only in the areas of myocardium at risk. Unmasking of areas of scarring and incoordinate contraction secondary to abnormal conduction are also possible causes of regional wall motion abnormalities. However, 92% of patients with wall motion changes developed abnormalities in previously normal segments.

Although we cannot exclude the possibility that scarring was a factor, the results of analysis of wall thickening as well as inward radial motion throughout the cardiac cycle make scarring an unlikely cause. Additionally, we described new wall motion abnormalities in only 25% of the patients with conduction defects, one of whom had left bundle branch block throughout the entire surgical procedure. Previous investigators have documented a high incidence of septal motion abnormalities after cardiac surgery.<sup>32–34</sup> Opening the sternum and pericardium may alter the motion of the heart within the chest and introduce a factitious decrease in the motion of the septal endocardium if a fixed-reference system is used.<sup>35</sup> However, thickening of the septal wall will not occur if the wall is ischemic.<sup>36</sup> We used a floating-reference system in this

**TABLE 2**  
**Changes in cross-sectional area with repositioning of the probe**

	Cross-sectional area		
	Skin closure	+ 2 cm, then repositioned	– 2 cm, then repositioned
End-diastolic area (cm <sup>2</sup> )	19.8 ± 6.4	19.8 ± 6.3	20.0 ± 6.0
End-systolic area (cm <sup>2</sup> )	11.8 ± 6.3	11.8 ± 6.1	12.1 ± 6.1

As determined by repeated-measures analysis of variance, no significant difference was found in cross-sectional areas after deliberate repositioning of the transducer.

study and evaluated both endocardial motion and wall thickening. Only three of 21 patients developed a SWMA of the septum after sternotomy or pericardiotomy. Therefore, we believe that the wall motion abnormalities we detected were most likely due to myocardial ischemia.

In experimental preparations, electrophysiologic changes rapidly follow the imposition of myocardial ischemia. However, the transthoracic ECG is relatively insensitive to subendocardial ischemia<sup>3</sup> and does not reflect changes until minutes after changes in wall motion and lactate metabolism. Another major limitation of electrocardiography is the difficulty of detecting ischemia in the presence of conduction defects or ventricularly paced rhythms. The new occurrence of such a conduction system defect is relatively common after cardiopulmonary bypass and does not accurately predict perioperative myocardial ischemia.<sup>37, 38</sup> Although monitoring the anterior precordial leads may have provided additional electrocardiographic evidence of ischemia, this area of the chest is inaccessible during cardiac and upper abdominal vascular procedures.

During anesthesia and surgery, we found four presumed episodes of ischemia by analysis of wall motion for every one episode detected by our electrocardiographic system. Three of the four patients with perioperative infarction had no electrocardiographic evidence of intraoperative ischemia, whereas all had SWMAs. Thus, our multilead electrocardiographic system failed to detect 75% of the intraoperative episodes of myocardial ischemia and was no better at predicting perioperative infarction. Moreover, the custom of relying on any single ECG lead would further diminish diagnostic efficacy.

Using one single cross section, we detected baseline wall motion abnormalities in 76% of patients with old myocardial infarctions. Although all major coronary vessels supply areas of myocardium at this level, it is conceivable that we may have missed wall motion abnormalities elsewhere. By not moving the probe, we simplified the process of monitoring, minimized the chances of introducing false positives secondary to changes in orientation of the transducer, and diminished the remote possibility of esophageal trauma. Despite this, we did not miss a single episode of intraoperative ischemia detected by electrocardiography.

During induction of anesthesia, we found a 16% incidence of ischemia detected by electrocardiography. This is a period of high risk during which transesophageal echocardiographic monitoring is not feasible. Additionally, ischemia occurring at this time may have caused wall motion abnormalities that we

took for baseline defects, thus diminishing the number of new wall motion changes detected.

In summary, we were able to detect intraoperative wall motion changes (presumed to be secondary to myocardial ischemia) by echocardiogram not only four times more frequently than we were able to detect ST segment changes on the ECG, but also when the ECG could not be analyzed because of conduction disturbances or paced rhythms. Patients experiencing persistent wall motion abnormalities were more likely to have myocardial infarction than those having only transient changes. No patient without a new wall motion abnormality had myocardial infarction. Two-dimensional transesophageal echocardiography seems superior to the ECG for the detection of intraoperative myocardial ischemia and should allow earlier identification of patients at higher risk of postoperative cardiovascular complications. Additionally, the ability to detect ischemia earlier may improve treatment of ischemic events and thereby reduce morbidity and mortality.

We thank Dasonics, Inc., and Marquette Electronics for supplying equipment; Pauline Snider and E.I. Eger II, M.D. for editorial advice; and Celeste Mangold for manuscript preparation.

## References

1. Marx GF, Mateo CV, Orkin LR: Computer analysis of postanesthetic deaths. *Anesthesiology* **39**: 54, 1973
2. Lunn JN, Mushin WW: Mortality associated with anaesthesia. London, Nuffield Provincial Hospitals Trust, 1982
3. Barnard RJ, Buckberg GD, Duncan HW: Limitations of the standard transthoracic electrocardiogram in detecting subendocardial ischemia. *Am Heart J* **99**: 476, 1980
4. Chaitman BR, Bourassa MG, Wagniat P, Corbara F, Ferguson RJ: Improved efficacy of treadmill exercise testing multiple lead ECG system and basic hemodynamic response. *Circulation* **57**: 71, 1978
5. Whinnery JE, Froelicher VF Jr, Stewart AJ, Longo MR, Triebwasser JH, Lancaster MC: The electrocardiographic response to maximal treadmill exercise of asymptomatic men with left bundle branch block. *Am Heart J* **94**: 316, 1977
6. Orzan F, Garcia E, Mathur VS, Hall RJ: Is the treadmill exercise test useful for evaluating coronary artery disease in patients with complete left bundle branch block? *Am J Cardiol* **42**: 36, 1978
7. Tennant R, Wiggers CJ: The effect of coronary occlusion on myocardial contraction. *Am J Physiol* **112**: 351, 1935
8. Vatner SF: Correlation between acute reductions in myocardial blood flow and function in conscious dogs. *Circ Res* **47**: 201, 1980
9. Forrester JS, Wyatt HL, Protasio L, Tyberg JV, Diamond GA, Swan HJC: Functional significance of regional ischemic contraction abnormalities. *Circulation* **54**: 64, 1976
10. Gallagher KP, Kumada T, Koziol JA, McKown MD, Kemper WS, Ross J Jr: Significance of regional wall thickening abnormalities relative to transmural myocardial perfusion in anesthetized dogs. *Circulation* **62**: 1266, 1980
11. Kerber RE, Marcus ML, Ehrhardt J, Wilson R, Abboud FM: Correlation between echocardiographically demonstrated segmental dyskinesia and regional myocardial perfusion. *Circulation* **52**: 1097, 1975
12. Waters DD, Luz PD, Wyatt HL, Swan HJC, Forrester JS: Early changes in regional and global left ventricular function induced by graded reductions in regional coronary perfusion. *Am J Cardiol* **39**: 537, 1977



13. Battler A, Froelicher VF, Gallagher KP, Kemper WS, Ross J Jr: Dissociation between regional myocardial dysfunction and ECG changes during ischemia in the conscious dog. *Circulation* **62**: 735, 1980
14. Pandian NG, Kerber RE: Two-dimensional echocardiography in experimental coronary stenosis. I. Sensitivity and specificity in detecting transient myocardial dyskinesia: comparison with sonomicrometers. *Circulation* **66**: 597, 1982
15. Schlüter M, Langenstein BA, Polster J, Kremer P, Souquet J, Engel S, Hanrath P: Transesophageal cross-sectional echocardiography with a phased array transducer system. Technique and initial clinical results. *Br Heart J* **48**: 67, 1982
16. Schlüter M, Hinrichs A, Thier W, Kremer P, Schröder S, Cahalan MK, Hanrath P: Transesophageal two-dimensional echocardiography: comparison of ultrasonic and anatomic sections. *Am J Cardiol* **53**: 1173, 1984
17. Van Reet RE, Quinones MA, Poliner LR, Nelson JG, Waggoner AD, Kanon D, Lubetkin SJ, Pratt CM, Winters WL Jr: Comparison of two-dimensional echocardiography with gated radionuclide ventriculography in the evaluation of global and regional left ventricular function in acute myocardial infarction. *J Am Coll Cardiol* **3**: 243, 1984
18. Cahalan MK, Kremer PF, Beaupre PW, Lurz FW, Roizen MF, Cronnelly R, Robinson S, Hamilton WK, Eger EI, Schiller NB: Consistency and reproducibility of transesophageal two-dimensional echocardiography. *Anesth Analg* **63**: 194, 1984
19. Heger JJ, Weyman AE, Wann LS, Dillon JC, Feigenbaum H: Cross-sectional echocardiography in acute myocardial infarction: detection and localization of regional left ventricular asynergy. *Circulation* **60**: 531, 1979
20. Gallagher KP, Osakada G, Hess OM, Koziol JA, Kemper WS, Ross J Jr: Subepicardial segmental function during coronary stenosis and role of myocardial fiber orientation. *Circ Res* **50**: 352, 1982
21. St. John Sutton MG, Ritman EL: Effects of progressive reduction in coronary blood flow on regional and global left ventricular contraction and relaxation during normal and increased afterload: a roentgen videometric study. *Cardiovasc Res* **16**: 535, 1982
22. Kisslo JA, Robertson D, Gilbert BW, Von Ramm O, Behar VS: A comparison of real-time, two-dimensional echocardiography and cineangiography in detecting left ventricular asynergy. *Circulation* **55**: 134, 1977
23. Weiss JL, Bulkley BH, Hutchins GM, Mason SJ: Two-dimensional echocardiographic recognition of myocardial injury in man: comparison with postmortem studies. *Circulation* **63**: 401, 1981
24. Lieberman AN, Weiss JL, Jugdutt BI, Becker LC, Bulkley BH, Garrison JG, Hutchins GM, Kallman CA, Weisfeldt ML: Two-dimensional echocardiography and infarct size: relationship of regional wall motion and thickening to the extent of myocardial infarction in the dog. *Circulation* **63**: 739, 1981
25. Wann LS, Faris JV, Childress RH, Dillon JC, Weyman AE, Feigenbaum H: Exercise cross-sectional echocardiography in ischemic heart disease. *Circulation* **60**: 1300, 1979
26. Gibson RS, Bishop HL, Stamm RB, Crampton RS, Beller GA, Martin RP: Value of early two dimensional echocardiography in patients with acute myocardial infarction. *Am J Cardiol* **49**: 1110, 1982
27. Limacher MC, Quinones MA, Poliner LR, Nelson JG, Winters WL, Waggoner AD: Detection of coronary artery disease with exercise two-dimensional echocardiography. Description of a clinically applicable method and comparison with radionuclide ventriculography. *Circulation* **67**: 1211, 1983
28. Horowitz RS, Morganroth J, Parotto C, Chen CC, Soffer J, Paulletto FJ: Immediate diagnosis of acute myocardial infarction by two-dimensional echocardiography. *Circulation* **65**: 323, 1982
29. Horowitz RS, Morganroth J: Immediate detection of early high-risk patients with acute myocardial infarction using two-dimensional echocardiographic evaluation of left ventricular regional wall motion abnormalities. *Am Heart J* **103**: 814, 1982
30. Braunwald E, Kloner RA: The stunned myocardium: prolonged, postischemic ventricular dysfunction. *Circulation* **66**: 1146, 1982
31. Pandian NG, Skorton DJ, Collins SM, Falsetti HL, Burke ER, Kerber RE: Heterogeneity of left ventricular segmental wall thickening and excursion in 2-dimensional echocardiograms of normal human subjects. *Am J Cardiol* **51**: 1667, 1983
32. Burggraf GW, Craige E: Echocardiographic studies of left ventricular wall motion and dimensions after valvular heart surgery. *Am J Cardiol* **35**: 473, 1975
33. Righetti A, Crawford MH, O'Rourke RA, Schelbert H, Daily PO, Ross J Jr: Interventricular septal motion and left ventricular function after coronary bypass surgery. *Am J Cardiol* **39**: 372, 1977
34. Vignola PA, Boucher CA, Curfman GD, Walker HJ, Shea WH, Dinsmore RE, Pohost GM: Abnormal interventricular septal motion following cardiac surgery: Clinical, surgical, echocardiographic and radionuclide correlates. *Am Heart J* **97**: 27, 1979
35. Kerber RE, Litchfield R: Postoperative abnormalities of interventricular septal motion: Two-dimensional and M-mode echocardiographic correlations. *Am Heart J* **104**: 263, 1982
36. Kerber RE, Marcus ML, Wilson R, Ehrhardt J, Abboud FM: Effects of acute coronary occlusion on the motion and perfusion of the normal and ischemic interventricular septum. An experimental echocardiographic study. *Circulation* **54**: 928, 1976
37. Zeldis SM, Morganroth J, Horowitz LN, Michelson EL, Josephson ME, Lozner EC, MacVaugh H, Kastor JA: Fascicular conduction disturbances after coronary bypass surgery. *Am J Cardiol* **41**: 860, 1978
38. O'Connell JB, Wallis D, Johnson SA, Pifarre R, Gunnar RM: Transient bundle branch block following use of hypothermic cardioplegia in coronary artery bypass surgery: high incidence without perioperative myocardial infarction. *Am Heart J* **103**: 85, 1982