

Incomplete lysis of thrombus in the moderate underlying atherosclerotic lesion during intracoronary infusion of streptokinase for acute myocardial infarction: quantitative angiographic observations

B. GREG BROWN, M.D., PH.D., CHRISTIAN A. GALLERY, B.A., RODNEY S. BADGER, M.D., J. WARD KENNEDY, M.D., DETLEF MATHEY, M.D., EDWARD L. BOLSON, M.S., AND HAROLD T. DODGE, M.D.

ABSTRACT Thrombolytic recanalization of the obstructed coronary lumen was studied in 32 patients receiving intracoronary streptokinase for 60 to 90 min during acute myocardial infarction. The process was viewed at high arteriographic magnification and was quantified with computer-assisted measurements from repeated single-plane views. The variability of the method for this application was 0.15 to 0.18 mm on minimum diameter estimates. Structural details were seen that are not commonly appreciated at conventional magnification. The recanalized lumen appears to form along an interface between the thrombus and the vessel wall, progressively enlarging its minimum arteriographic diameter to 0.65 ± 0.24 mm (± 1 SD) at the end of the short-term infusion of streptokinase reflecting a final percent stenosis of $77 \pm 10\%$. In nine infarct lesions found patent 5 \pm 3 weeks later, the recanalized lumen further improved an average of 0.34 mm in minimum diameter ($p < .005$) and 13% stenosis ($p < .01$). A thin film of contrast medium surrounding the obstructing thrombus faintly defined the boundaries of the original atherosclerotic lumen in all but two cases. The "original stenosis" measured 1.25 ± 0.32 mm in minimum diameter and $56 \pm 14\%$ stenosis when first visualized; it was unchanged throughout the course of infusion of streptokinase. In five patients catheterized 10 \pm 12 weeks before their infarction, the original stenosis averaged 1.15 ± 0.22 mm in the preinfarct angiogram, as compared with 1.17 ± 0.23 mm in its faintly defined form during thrombolytic therapy ($p = \text{NS}$). In 10 cases, this original lesion was less than a 50% stenosis, and in 21 cases less than 60%. These measurements permit an objective evaluation of the thrombolytic process; they demonstrate that mild-to-moderate atherosclerotic coronary lesions are subject to acute thrombotic occlusion and that intracoronary streptokinase administered over 60 to 90 min only partially lyses the obstructing thrombus. *Circulation* 73, No. 4, 653-661, 1986.

THE SYSTEMIC INFUSION of a thrombolytic agent is a potentially beneficial treatment option in the setting of acute myocardial infarction.¹⁻⁷ Current evidence suggests that the great majority of arteries supplying the zone of infarction are occluded by thrombus appearing to originate at the site of an atherosclerotic plaque.^{8,9} In many cases, plaque ulceration may be the initiating thrombogenic event.¹⁰ A number of factors

may influence the effectiveness of thrombolytic therapy. Among these are the agent and dose used,¹¹⁻¹⁷ the time of its delivery,¹⁸⁻²² location of the occlusion and presence of collaterals,¹⁷ the route and duration of drug administration,²⁰⁻²⁴ and the rate and extent of initial recanalization.^{25,26} Objective techniques that can be used to assess the role of each of these factors include the follow-up of well-defined clinical end points, contrast and radionuclide ventriculography, and contrast arteriography. Although the ultimate goals of therapy are expressed in terms of myocardial viability and the clinical state, the immediate objective is to produce a rapid and hemodynamically effective recanalization of the occluded artery. Information pertinent to that objective can be found in the coronary arteriogram. Un-

From the Cardiology Division, University of Washington, Seattle.
Supported in part by USPHS grants HL 13517 and HL 19451, by a Washington State Heart Association grant-in-aid, by a grant from the R. J. Reynolds Foundation, and by Established Investigator Award 79-116 from the American Heart Association (Dr. Brown).

Address for correspondence: B. Greg Brown, M.D., Ph.D., Cardiology Division RG-22, University of Washington, Seattle, WA 98195.

Received May 6, 1985; revision accepted Dec. 27, 1985.

fortunately, there is considerable observer variability in the conventional estimation of severity of coronary stenosis,^{27, 28} and we believe that the recanalized arterial lumen has structural features²⁹ that make accurate visual interpretation even more difficult in this setting. Therefore, we have developed an objective arteriographic approach to the analysis of the thrombolytic process and have evaluated its variability. Measurements are described from 32 patients with initially successful recanalization with intracoronary streptokinase.

Methods

Patients. Arteriograms from 16 participants in the Western Washington trial of intracoronary streptokinase in myocardial infarction⁶ and from 16 patients undergoing similar thrombolytic therapy in Hamburg, West Germany,⁴ were collected for evaluation from series of 23 and 20 consecutive cases, respectively. These were selected with the requirements that intracoronary streptokinase was used and that reperfusion occurred during its infusion. Mean age of the patients was 56 years (range 28 to 82). Mean time to administration of intracoronary streptokinase was 3.9 hr (range 2.0 to 11.5) after the onset of chest pain. Mean intracoronary dose was $203,000 \pm 74,000$ (SD) IU of streptokinase. Occlusion of the left anterior descending coronary artery occurred in 19 (59%) of these patients, of the right coronary artery in 10 (31%), and of the left circumflex coronary artery in three (10%).

Three patients groups were defined. Five patients (group 1) had undergone coronary angiography shortly before the acute myocardial infarction. The mean interval between the "preinfarct" angiogram and the streptokinase angiogram was 10 ± 12 weeks. Group 1 provided a unique opportunity to examine the stenosis before its thrombotic occlusion and to evaluate the amount of thrombolytic recanalization relative to the "original" stenosis. In 16 patients (group 2), angiograms of the occluded artery were repeated in a preselected view after intracoronary administration of 0.2 mg of nitroglycerin, and then every 15 min during the subsequent intracoronary infusion of streptokinase, which continued in all patients for 1 hr and in five for longer, up to 90 min. Group 2 permitted observations on the temporal sequence of events in thrombolysis. Thirteen patients (group 3), principally those treated in Hamburg, were electively recatheterized at an average of 5 ± 3 weeks after the initial infusion of streptokinase. In none of these was an intervening procedure such as bypass grafting or percutaneous angioplasty performed. In all cases, warfarin anticoagulation was initiated and continued until the late angiogram (protime data are not available). Group 3 permitted a perspective on the early fate of an initially recanalized stenosis. Two patients in group 2 also provided data for group 3. Patients in groups 1, 2, and 3 received $220,000 \pm 66,000$, $202,000 \pm 84,000$, and $198,000 \pm 71,000$ IU of intracoronary streptokinase, respectively.

Quantitative angiography. We quantified the process of thrombolytic recanalization from repeated injections in a single arteriographic view.³⁰ Practical considerations prevented the traditional use of paired perpendicular views. Specifically, repeated *paired* views at five points during the course of thrombolysis would have added up to 100 ml of additional contrast medium to the procedure; this extra contrast burden is potentially hazardous in a patient with acute myocardial infarction. Consequently, the "best" view of the occluded artery was selected by the angiographer from among the initial two-to-four standard

projections, and injections were repeated in this single view at subsequent points. In measuring these arteriograms, traditional corrections for pincushion distortion and for out-of-plane magnification were made with three-dimensional information obtained from the initial paired views; thus the dimensional accuracy of these measurements is as previously described.³⁰⁻³³ Single-plane lesion analysis, as performed in these studies, makes the assumption that the measured lumen is round in cross-section. We believe that this is a suitably accurate approximation in the usual atherosclerotic lesion,³⁴⁻³⁶ based on measurements of lumen dimensions in physiologically distended diseased arterial segments. However, the assumption of lumen "roundness" in the partially thrombosed recanalizing lumen is as yet untested. Lumen cross-section in that unique setting might well be irregular, perhaps even crescent-shaped. Thus, even if the perpendicular views were obtained, we believe it would be *inappropriate* to estimate lumen *cross-sectional area*, as we have done with the usual coronary lesion. For this reason, the lumen measurements in this report are expressed simply in terms of the observed lumen diameters. "Normal" artery diameter was measured proximal and, when seen, distal to the thrombosed segment, as were minimum lumen diameter and percent diameter reduction in the stenosis. Stenosis pressure loss at a hypothetical normal flow of 1 ml/sec³⁷ was estimated³¹ assuming a round lumen with the diameter being that measured from the single view.

From our initial experiences in observing these thrombosed segments at high magnification, it became obvious that conventional measures of severity of stenosis do not always apply directly to the recanalizing lumen. Figures 1 to 4 illustrate the unique nature of this problem in the definition of lumen geometry. Initially, the lumen is totally or subtotally occluded with thrombus. As perfusion is reestablished, blood (and contrast medium) flows through a *recanalized lumen*, which appears to course along a path at the interface between the intimal surface and the newly formed thrombus. The injected contrast medium can also be seen to surround the thrombotic mass in such a way as to faintly opacify its contours, thus appearing to define the boundaries of the *original lumen*. This distinction between the densely opacified and the faintly opacified lumens was clear in all but two cases. The problem is to determine the *effective lumen*, whose actual size must fall between that of the small densely opacified channel through which blood appears to flow most rapidly, and that of the larger, faintly opacified channel defined by the staining of the thrombus. As one solution to this dilemma we measured *each* of these two lumens, and observed the time course of change in each during the thrombolytic process.

Angiograms of obstructed segments were projected* at about 5.5-fold magnification in the selected view, and the borders of the original lumen and of the recanalized lumen were traced, as illustrated in figure 1, *b*. For each study time point, these two traced versions of the obstructed segment were manually digitized into a DEC-VAX computer. A segment of the catheter tip, of known diameter, was digitized as a scaling reference. The computer software corrects for pincushion distortion and for out-of-plane and optical magnification to provide a true-scale representation of the occluded segment as illustrated in figure 1, *c*, from which are computed the above estimates. The accuracy and precision of this technique for measurement of ordinary coronary lesions have been described³⁰⁻³³ and the hemodynamic estimates experimentally validated.³⁸ Error and variability are within $\pm 3\%$ (± 1 SD) and ± 0.1 mm on repeated estimates of percent stenosis and minimum lumen diameter.

Variability of method for study of thrombolysis. Because

*Vanguard Instrument Co., Melville, NY, Model M35c/S2 stand.

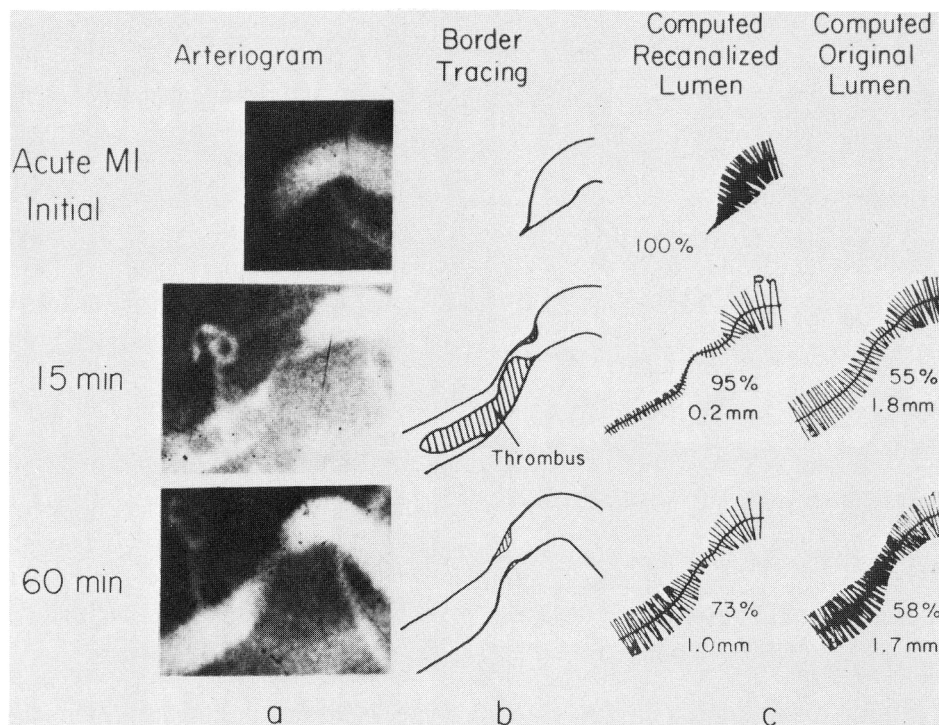


FIGURE 1. Development of the recanalized lumen during intracoronary infusion of streptokinase. *a*, Sequential angiographic images. *b*, Sequential tracings of recanalized lumen and original lumen, as densely and faintly opacified by contrast. *c*, Computer representation of the tracings. In this case a large tail of thrombus extending downstream from its point of adherence in the stenosis is largely lysed after 60 min of intracoronary streptokinase.

the quantitative angiographic analysis of the recanalized lesion is somewhat more complex and subjective than that of ordinary atherosclerotic coronary lesions, it was necessary to evaluate the variability of the method for this application. Serial measurements were made during the successful recanalization of 11 lesions and were repeated, in blind fashion, from the same cine-films at least 11 months later. A total of 61 injections of these lesions were measured; the measurements were repeated without reference to the initial analysis. From each injection, two frames were selected by an experienced angiographer. These were traced and digitized once each by the angiographer and by a single technical assistant. Each dimensional estimate for a given lesion and time point was thus an average of the four individual measurements. The initial and final measurements were compared in terms of the average of their differences (evidence for a change in technique over the 11 month interval) and the standard deviation of their differences (an estimate of measurement variability).

The statistical analysis used paired *t* tests for evaluation of group trends and pooled *t* tests for comparison of two groups. A difference was called significant if the probability of its chance occurrence was less than .05.

Results

Morphologic features. Figures 1 to 4 provide typical examples of the thrombolytic process and illustrate the measurement method. When viewed at high magnification, structural details are visible that are not easily appreciated at the magnifications used commonly for angiographic viewing. In 30 of 32 cases, one or more distinct lobulated masses of thrombus were seen in the

vessel lumen after flow had been reestablished. In 29 of these cases, the proximal part of the thrombus appeared to adhere to a site of atherosclerotic arterial narrowing (see figure 3 for the apparent exception). In 16 (55%) of these 29 cases, this thrombus extended

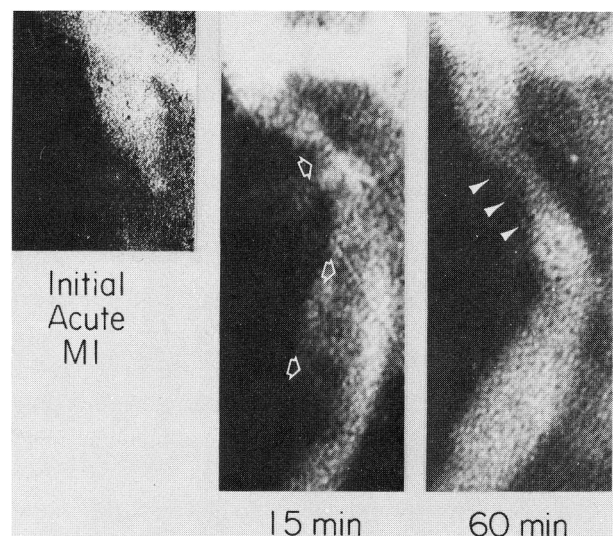


FIGURE 2. Example of the developing recanalized lumen and the rapidly disappearing large tail of thrombus extending distally from its apparent site of attachment in the original stenosis. Residual "thrombus" at 60 min is indicated by the arrows.

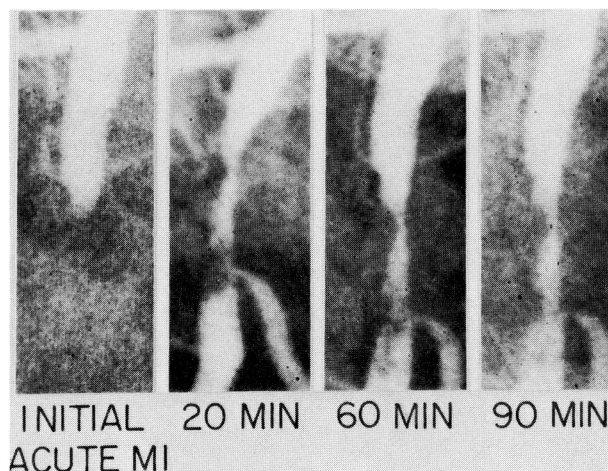


FIGURE 3. Time-course of thrombolysis over 90 min infusion. Initially, this right coronary artery appears occluded at a site of severe organic stenosis. At 20 min, the thrombus appears to have migrated downstream and to have reattached at or near the ostium of an acute marginal branch, where it appears to cause the greatest focal obstruction. During the course of treatment, the thrombus mass diminishes but the severe proximal stenosis persists.

downstream, well into the apparently normal lumen distal to the stenosis. In these 16 cases, the initial diameter of this “tail” of thrombus, measured by caliper from the tracings, averaged 71% of the distal lumen it nearly filled. In 10 of the 16 cases in which this large mass of thrombus was observed, it completely or nearly completely (>75%) disappeared during the infusion of streptokinase. The average residual diameter of this “tail” was 24% of its initially observed diameter. Definite distal embolization from this thrombotic mass was observed during contrast injection in four of the 16 cases. Furthermore, nine of these 16 distal thrombi were observed to abruptly become much smaller between two consecutive angiograms, a characteristic finding in the four cases with documented embolization. Thus thrombus fragmentation and distal embolization may occur more frequently than is commonly appreciated. Embolized thrombus appears to be lysed quickly; in no case in this study did it cause transient clinical deterioration or persistent distal obstruction. By comparison, the relatively small plug of apparent thrombus occupying the narrowest portion of the original stenosis lumen was more resistant to lysis. Despite streptokinase infusions of 1 to 2 hr, this plug persisted at 50% or more of its original diameter in 15 of 29 cases and on the average was reduced to only $49 \pm 20\%$ (SD) of its original diameter.

Measurement variability. Table 1 gives the results of the variability analysis. Normal and minimum diameter in the original and the recanalizing lumen were measured from 61 different injections of 11 infarct

lesions. The same measurements were repeated 11 months later, using the same cinefilms, but without reference to the original analysis. The average of differences between the two measurements was small and not significantly different from zero. The standard deviation of differences in the minimum diameter measurement in the *recanalizing* lumen was 0.18 mm, almost twice that of repeat measurements of ordinary atherosclerotic lesions. This increased variability is due to frame-to-frame differences in appearance of the recanalized lumen, as well as difficulty in identifying distinct borders. Variability in measurement of minimum diameter in the original stenosis was 0.15 mm, surprisingly low in view of the faintness of contrast defining this lumen. Variability for measurement of normal vessel caliber was 0.27 mm, somewhat greater than usual because the segment distal to the occlusion was frequently poorly visualized during the early stages of recanalization.

Diameter of the recanalized lumen. For each of the three patient groups, figure 5 shows the time course of the four angiographically measured diameters: proximal “normal,” distal “normal,” minimum diameter of

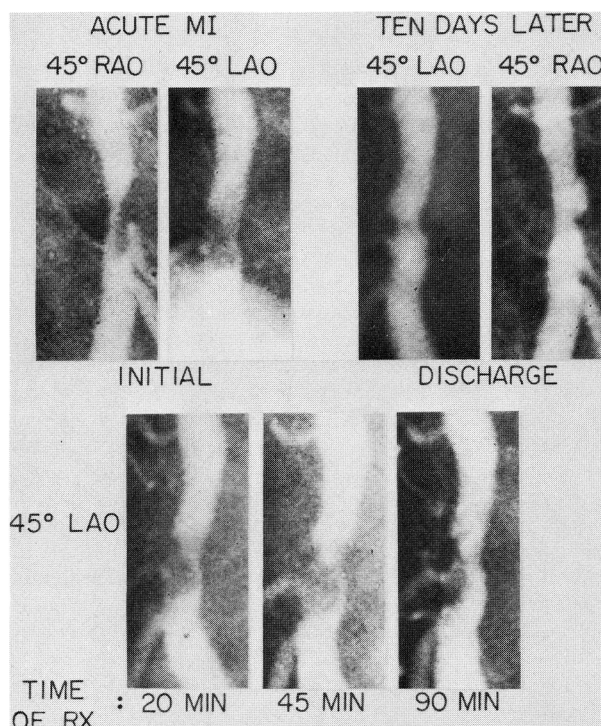


FIGURE 4. Example of successful lysis of a thrombus adherent to a site eventually seen to be a large plaque ulcer in an arteriogram obtained 10 days after the acute myocardial infarction. This right coronary artery was initially subtotally occluded in the clinical setting of acute inferior infarction. During the 90 min infusion, the recanalized lumen underwent substantial enlargement and the patient's pain disappeared. Further thrombolysis occurs between 90 min and 10 days (compare the 45° LAO views at these two time points).

TABLE 1

Comparison of initial (I) arterial measurements with repeat (R) measurements done 11 months later (61 angiographic views of 11 recanalizing lesions)

	Recanalized lumen minimum diameter (mm)	Original stenosis minimum diameter (mm)	Normal lumen diameter (mm)	% Diameter reduction, recanalized lumen
n	41	41	97	41
Mean of all measures	0.41	1.21	3.09	89
Mean of differences (I - R)	+0.04 (NS)	-0.05 (NS)	-0.02 (NS)	-2 (NS)
Standard deviation of differences (I - R)	0.18	0.15	0.27	6

NS = not significantly different from zero.

the recanalized lumen, and minimum diameter of the original stenosis lumen. The recanalized lumen averaged 0.24 mm in the six vessels initially found to be subtotally occluded before nitroglycerin or streptokinase. Three of 11 totally occluded vessels opened with intracoronary infusion of nitroglycerin to severe stenoses averaging 0.28 mm minimum diameter. Twenty-one of the 26 that were initially occluded were open at 15 or 30 min; all vessels eventually opened during the infusion of streptokinase. As seen in figure 5, average recanalized lumen diameter increased with time in a linear fashion, due in part to recruitment of newly opened vessels and to continued thrombolysis in those already opened. At the end of the streptokinase infusion, minimum diameter in the recanalized lumen averaged 0.65 ± 0.24 mm (± 1 SD) in the 32 patients. It reached 80% or more of the minimum diameter of the "original" stenosis in only five cases, in-

cluding the two in which intraluminal thrombus was not seen. There was no significant difference in the time course of the change in diameter among the three groups.

Figure 5 also shows the time course of change in percent stenosis in the recanalized lumen. Initially, this averaged $90 \pm 3\%$ in the six subtotally occluded vessels and was otherwise 100%. At the final injection of the short-term study, percent stenosis averaged $77 \pm 10\%$. In nine patients with open vessels at repeat angiography an average of 5 ± 3 weeks later, the recanalized lumen improved an average of 0.34 mm (0.66 to 1.00; $p < .005$) and 13% (74% to 61%; $p < .01$) in its severity.

Diameter of original stenosis lumen. Figures 1 through 5 show that the larger lumen defined by a faint contrast stain surrounding the thrombus was a stable anatomic feature of the reperfused vessel, averaging $1.25 \pm$

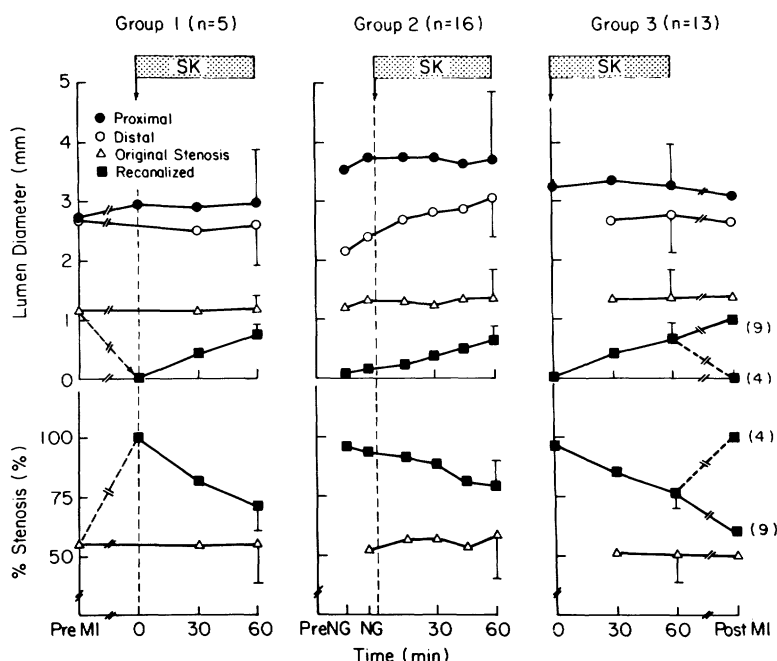


FIGURE 5. Top, Changes in diameter of proximal, distal, "original" stenosis and recanalized coronary lumens during intracoronary infusion of streptokinase (SK). Group 1 comprises five patients in whom preinfarct angiograms, obtained an average of 10 weeks before the thrombolytic angiograms, showed that the faintly defined lumen seen during recanalization is the original stenosis before occlusion. Group 2 consists of 16 patients in whom injections every 15 min document the average time course of opening at the point of greatest narrowing in the recanalized lumen. Group 3 includes 13 patients in whom angiograms were obtained an average of 5 weeks after the acute thrombolytic study. Bottom, Changes in percent stenosis of the original and recanalized lumen in each group. The original diseased lumen is constant, averaging 55% stenosis; the recanalized lumen improves from an average initial stenosis of 97% to 77% at 60 min. In nine lesions still open at the late angiogram, the recanalized lumen demonstrated further improvement, although residual thrombus was usually seen. MI = myocardial infarction; NG = nitroglycerin.

0.32 mm in minimum diameter and $56 \pm 14\%$ stenosis when seen initially, and 1.28 ± 0.38 mm and $55 \pm 16\%$ stenosis at the end of the infusion of streptokinase. There were no significant differences among the three patient groups in the extent of narrowing in the original stenosis lumen. In five patients for whom comparable angiographic views had been obtained before the infarct angiogram, the measured preinfarct lumen averaged 1.15 ± 0.22 mm, compared with 1.17 ± 0.23 mm as the "original" stenosis lumen faintly defined in the infarct angiogram ($p = \text{NS}$). These observations strongly support the hypothesis that the lumen boundaries defined by faint contrast staining during recanalization approximate those of the diseased lumen before it became occluded by thrombus. The original stenosis was frequently mild-to-moderate in severity. Among the 32 lesions, the percent diameter reduction of the original stenosis was between 20% and 30% in one (3%); it was between 30% and 40% in five (16%), between 40% and 50% in four (13%), between 50% and 60% in 11 (34%), between 60% and 70% in six (19%), and greater than 70% in five (15%).

Figure 6 integrates these morphologic features and measurements of the recanalization process into a con-

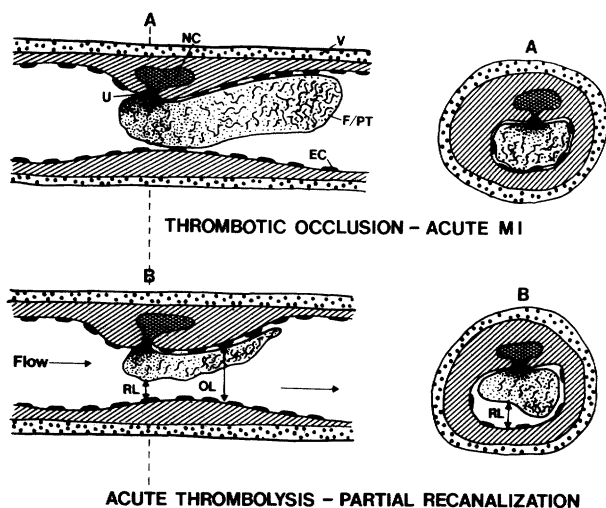


FIGURE 6. An interpretation of the morphologic features and measurements of the recanalization process. Typically, fresh thrombus is totally obstructive (A). During recanalization (B), thrombus morphology and the geometry of the underlying artery are revealed radiographically by faint staining due to contrast penetration into the gap between thrombus and endothelium (EC). Typically, the underlying stenosis is moderate; the fibrin/platelet thrombus (F/PT) may adhere to a site of obvious ulceration (U) arising from the necrotic center (NC) of the plaque. A large downstream "tail" of thrombus is nearly completely lysed (or embolized). But, in the stenosis, the acutely recanalized lumen (RL) is only about 50% of the diameter of the original lumen (OL) after 60 min intracoronary of streptokinase. Thus a large part of the original stenosis remains blocked by persistent thrombus.

ceptual interpretation of the usual geometry and events of thrombolysis.

Diameter of normal vessel segments. The occluded vessels were large, averaging 3.26 ± 0.96 mm lumen diameter proximal to the obstruction. Proximal diameter increased an average of 6% ($p = \text{NS}$) after the intracoronary infusion of nitroglycerin and remained constant thereafter. Lumen diameter distal to the stenosis increased during the recanalization process, averaging 2.63 ± 0.59 mm at the time of first visualization and 2.81 ± 0.68 mm ($p < .05$) at the final visualization after an average of 63 ± 10 min of the streptokinase infusion. Distal lumen dilation peaked much later than proximal dilation, suggesting that it was more likely a response to rising distal arterial pressure than to nitroglycerin.

Time course of change in stenosis resistance. For purposes of this analysis, totally occluded vessels were assigned a resistance value of 1000 mm Hg/ml/sec, inconsistent with even minor distal perfusion. Figure 7 shows the average time course of change in estimated stenosis pressure loss with "normal" flow for those vessels found open initially, for those opening "early" (15 or 30 min), and those opening "late" (45 or 60 min). The roughly parallel course of declining resistance followed by these three groups suggests that once reperfusion is initiated, regardless of the time of opening, the process of recanalization is similar.

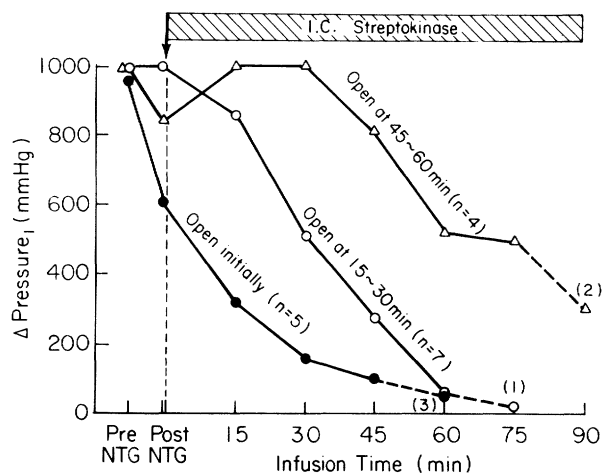


FIGURE 7. Time course of change in flow resistance (pressure loss at "normal" flow of 1 ml/sec) in recanalized lumen during infusion of streptokinase in 16 patients of group 2. Resistance was arbitrarily called 1000 mm Hg/ml/sec in totally occluded vessels. Five arteries were barely open initially; seven opened at 15 or 30 min (early); four opened at 45 or 60 min (late). Effective recanalization to a minimum lumen diameter of 0.5 mm or more correlated with a resistance of 100 mm Hg/ml/sec or less. Once the artery was open, the time course of hemodynamic improvement in these three subgroups appeared comparable. NTG = nitroglycerin.

Discussion

During successful coronary thrombolysis, as visualized with highly magnified arteriographic images, an initially small channel forms along the least resistant pathway through the occluding thrombus and enlarges with continued lysis. Outside the boundaries of this developing channel, a larger faintly opacified lumen is usually seen. The latter appears to result from the penetration of contrast medium into the narrow gap between thrombus and the coronary endothelial surface, thus defining the lumen of the original stenosis as it appeared before its acute occlusion. At its narrowest point, this original lumen averaged 1.28 ± 0.38 mm (SD) in diameter, a $55 \pm 15\%$ diameter stenosis. The original stenosis was less than 50% in 10 of 32 (31%) acutely thrombosed coronary segments, and in 21 (66%) it was less than 60%. Thus, by clinical standards, the majority of these coronary segments that became acutely occluded were mildly or moderately narrowed by atherosclerosis. This finding conflicts with the widely held view that thrombosis occurs primarily in a severe stenosis. But it is consistent with the observation that many myocardial infarctions occur in previously asymptomatic individuals and often after the recent demonstration of excellent exercise capacity.

The finding of a mild-to-moderate stenosis as the pathology frequently underlying acute coronary occlusion implies that the severity of atherosclerotic narrowing is not the primary determinant of the likelihood of acute occlusion. Additional factors may include morphologic features of the lesion such as vasomobility, the size and composition of the necrotic center of the atheroma, the thickness of the atheroma's fibrous cap or its vulnerability to ulceration, the amount of local inflammatory reaction, the capacity for local prostacyclin production, or the vigor of mechanical flexing. In a few instances (see figure 4) the angiographic image reveals plaque ulceration as the basis for acute thrombosis. However, in our experience, *obvious* plaque ulceration is present in less than 20% of cases after thrombolytic therapy. By comparison, ulceration is found at pathologic examination in more than 90% of fatal episodes of myocardial infarction.^{10, 39} Failure to consistently observe this at angiography may be due to the small size of the usual ulcer or to the fact that most ulcers remain filled with thrombus—a situation visible histologically but not angiographically.

"Successful" short-term thrombolytic therapy results in a recanalized lumen that averages 0.65 ± 0.24 mm in diameter at the point of greatest narrowing. This

is approximately half of the 1.28 ± 0.38 mm minimum diameter of the original stenosis. This failure to fully recanalize to the dimensions of the original stenosis has at least four possible explanations: First, the thrombolytic infusion may not have been continued long enough. Feldman et al.²⁴ have shown an improvement in stenosis severity with continued streptokinase infusion to as long as 180 min. Our resistance data suggest that active recanalization continues for at least 60 min after the time of first visualization (see figure 7). And in those nine cases found open at later restudy, there was significant further improvement beyond the last short-term measurement (see figure 5, group 3). Although it is clear that continued thrombolysis occurs, neither our data nor those of other investigators directly address the question of the appropriate duration of intracoronary infusion. Second, the thrombus occluding the original stenosis lumen may have heterogeneous composition, so that part of it is susceptible to lysis by streptokinase and part is resistant. For example, an initiating *platelet-rich* thrombus adherent to a site of intimal injury may release prothrombin activators, which results in completed obstruction by a *fibrin-rich* thrombus, the latter being possibly more sensitive to lysis by activated plasminogen. The relatively rapid lysis of the large downstream "tail" of thrombus could be due to such heterogeneity, or alternatively, to embolization or to a larger exposed surface area. Third, certain cofactors in the thrombolytic reaction (such as plasminogen) could become depleted during the initial period of infusion, thus diminishing the potential for continued lysis. Fourth, the material remaining in the original stenosis lumen may *not* be thrombus. It may be an extrusion of necrotic plaque debris into the lumen, or an intimal flap, or a portion of plaque forced into the stenosis lumen by internal plaque hemorrhage. We believe that the angiographic appearance in most cases and continued "late" recanalization argue against this possibility. But these arteriographic inferences must be supported by histopathologic data before this question can be resolved.

McMahon et al.³¹ have shown that the "critical" proximal coronary stenosis lumen in patients with medically refractory unstable angina averages 0.88 ± 0.14 mm minimum diameter and $72 \pm 5\%$ stenosis. By comparison, we found an average recanalized lumen diameter of 0.65 ± 0.24 mm and a $77 \pm 10\%$ stenosis at the time the intracoronary infusion was stopped. Even though the cross-sectional morphology of the atherosclerotic lumen and that of the recanalized lumen may differ, these measurements are certainly not encouraging. Badger et al.²⁶ report that a measured

minimum recanalized diameter of 0.4 mm or less correlates well with delayed antegrade flow and washout of contrast in the infarct vessel and that an acutely recanalized lumen diameter of 0.5 mm or less predicts frequent reocclusion. By this criterion, 10 of our 32 patients with recanalization had suboptimal thrombolysis. Harrison *et al.*,²⁵ without making the distinction between the "original" and "recanalized" lumen, observed that lumen *area* of less than 0.4 mm² (0.7 mm mean diameter) after infusion of streptokinase predicted eventual reocclusion. Finally, Sheehan *et al.*^{22, 40} have determined that improvement of myocardial contractile function does not occur if residual stenosis lumen diameter measured by the above method is less than 0.4 mm.

Acute recanalization either failed to occur or was *inadequate* by the criteria above in 22 of 44 (50%) of our patients who received intracoronary streptokinase, in 15 of 32 (47%) patients studied by Sheehan *et al.*,⁴⁰ and in at least 43 of 77 (56%) studied by Harrison *et al.*²⁵ The pessimistic interpretation of these data is that intracoronary streptokinase appears to be relatively ineffective in almost half of patients with acute transmural myocardial infarction. Such patients would require percutaneous angioplasty⁴¹ or bypass surgery⁴² to achieve satisfactory acute reperfusion. We favor a more optimistic interpretation; newer generations of thrombolytic agents, designed for rapid administration and for clot selectivity and given in optimal dose and duration, may well achieve the target of *total thrombolysis*. If this were to occur, the minimum diameter of the recanalized lumen would be restored to that of the original lumen, which averages 1.3 mm or a 56% stenosis.

In conclusion, these measurement methods provide an objective and apparently clinically useful means for characterizing the thrombolytic recanalization of an occluded artery. As such, this approach is presently being applied in the ongoing NIH-sponsored Thrombolysis in Myocardial Infarction trial.

We thank Dr. Timothy DeRouen for statistical advice, Joanna Haug for technical assistance, and Sue Schaefer for preparation of the manuscript.

References

1. Rentrop P, Blanke H, Karsch KR, Kaiser H, Köstering H, Leitz K: Selective intracoronary thrombolysis in acute myocardial infarction and unstable angina pectoris. *Circulation* **63**: 307, 1981
2. Ganz W, Buchbinder N, Marcus H, Mondkar A, Maddahi J, Charuzi Y, O'Conner L, Shell W, Fishbein MC, Kass R, Miyamoto A, Swan HJC: Intracoronary thrombolysis in evolving myocardial infarction. *Am Heart J* **101**: 4, 1981
3. Reduto LA, Freund GC, Gaeta JM, Smalling RW, Lewis B, Gould KL: Coronary artery reperfusion in acute myocardial infarction: beneficial effects of intracoronary streptokinase on left ventricular salvage and performance. *Am Heart J* **102**: 1168, 1981
4. Mathey DG, Rodewald G, Rentrop P, Leitz K, Merx W, Messmer BJ, Rutsch W, Bücherl ES: Intracoronary streptokinase thrombolytic recanalization and subsequent surgical bypass of remaining atherosclerotic stenosis in acute myocardial infarction: complementary combined approach effecting reduced infarct size, preventing reinfarction, and improving left ventricular function. *Am Heart J* **102**: 1194, 1981
5. Sheehan FH, Mathey DG, Schofer J, Krebber HJ, Dodge HT: Effect of interventions in salvaging left ventricular function in acute myocardial infarction: a study of intracoronary streptokinase. *Am J Cardiol* **52**: 431, 1983
6. Kennedy JW, Ritchie JL, Davis KB, Fritz JK: Western Washington randomized trial of intracoronary streptokinase in acute myocardial infarction. *N Engl J Med* **309**: 1447, 1983
7. Rentrop KP, Feit F, Blanke H, Stecy P, Schneider R, Rey M, Horowitz S, Goldman M, Karsch K, Meilman H, Cohen M, Siegel S, Sanger J, Slater J, Gorlin R, Fox A, Fagerstrom R, Calhoun WF: Effects of intracoronary streptokinase and intracoronary nitroglycerin infusion on coronary angiographic patterns and mortality in patients with acute myocardial infarction. *N Engl J Med* **311**: 1457, 1984
8. DeWood MA, Spores J, Notske R, Mouser LT, Burroughs R, Golden MS, Lang HT: Prevalence of total coronary occlusion during the early hours of transmural myocardial infarction. *N Engl J Med* **303**: 897, 1980
9. Davies MJ, Woolf N, Robertson WB: Pathology of acute myocardial infarction with particular reference to occlusive coronary thrombi. *Br Heart J* **38**: 659, 1976
10. Oliva PB: Pathophysiology of acute myocardial infarction. *Ann Intern Med* **94**: 236, 1981
11. Collen D, Verstraete M: Systemic thrombolytic therapy of acute myocardial infarction. *Circulation* **68**: 462, 1983
12. Tiefenbrunn AJ, Robison AK, Kurnik PB, Ludbrook PA, Sobel BE: Clinical pharmacology in patients with evolving myocardial infarction of tissue-type plasminogen activator produced by recombinant DNA technology. *Circulation* **71**: 100, 1985
13. Gold HK, Fallon JT, Yasuda T, Leinbach RC, Khaw BA, Newell JB, Guerrero JL, Vislosky FM, Hoyng CF, Grossbard E, Collen D: Coronary thrombolysis with recombinant human tissue-type plasminogen activator. *Circulation* **70**: 700, 1984
14. Van de Werf F, Ludbrook PA, Bergmann SR, Tiefenbrunn AF, Fox KAA, deGeest H, Verstraete M, Collen D, Sobel BE: Coronary thrombolysis with tissue-type plasminogen activator in patients with evolving myocardial infarction. *N Engl J Med* **310**: 609, 1984
15. Collen D, Topol EJ, Tiefenbrunn AJ, Gold HK, Weisfeldt ML, Sobel BE, Leinbach RC, Brinker JA, Ludbrook PA, Yasuda I, Bulkley BH, Robison AK, Hutter AM, Bell WR, Spadaro JJ Jr, Khaw BA, Grossbard EB: Coronary thrombolysis with recombinant human tissue type plasminogen activator: a prospective, randomized, placebo-controlled trial. *Circulation* **70**: 1012, 1984
16. Tennant SN, Dixon J, Venable TC, Page HL Jr, Roach A, Kaiser AB, Fredericksen R, Tacogue L, Kaplan P, Babu NS, Anderson EE, Wooten E, Jennings HS III, Breinig J, Campbell WB: Intracoronary thrombolysis in patients with acute myocardial infarction: comparison of the efficacy of urokinase with streptokinase. *Circulation* **69**: 756, 1984
17. Tendra MP, Campbell WB, Tennant SN, Ray WA: Factors influencing probability of reperfusion with intracoronary ostial infusion of thrombolytic agent in patients with acute myocardial infarction. *Circulation* **71**: 124, 1985
18. Mathey DG, Kuck KH, Tilsner V, Krebber HJ, Bleifeld W: Non-surgical coronary artery recanalization in acute transmural myocardial infarction. *Circulation* **63**: 489, 1981
19. Reimer KA, Lowe JE, Rasmussen MM, Jennings RB: The wave-front phenomenon of ischemic cell death. I. Myocardial infarct size vs duration of coronary occlusion in dogs. *Circulation* **56**: 786, 1977
20. Taylor GJ, Mikell FL, Moses HW, Dove JT, Batchelder JE, Thull A, Hansen S, Wellons HA Jr, Schneider JA: Intravenous versus intracoronary streptokinase therapy for acute myocardial infarction in community hospitals. *Am J Cardiol* **54**: 256, 1984
21. Anderson JL, Marshall HW, Askins JC, Lutz JR, Sorensen SG,

- Menlove RL, Yanowitz FG, Hagan AD: A randomized trial of intravenous and intracoronary streptokinase in patients with acute myocardial infarction. *Circulation* **70**: 606, 1984
22. Sheehan FH, Mathey DG, Schofer J, Dodge HT, Bolson EL: Factors that determine recovery of left ventricular function after thrombolysis in patients with acute myocardial infarction. *Circulation* **71**: 1121, 1985
23. Rogers WJ, Mantle JA, Hood WP, Baxley WA, Whitlow PL, Reeves RC, Soto B: Prospective randomized trial of intravenous and intracoronary streptokinase in acute myocardial infarction. *Circulation* **68**: 1051, 1983
24. Feldman RL, Crick WF, Conti CR, Pepine CJ: Quantitative coronary angiography during intracoronary streptokinase in acute myocardial infarction: how long to continue thrombolytic therapy? *Cathet Cardiovasc Diagn* **9**: 9, 1983
25. Harrison DG, Ferguson DW, Collins SM, Skorton DJ, Erickson EE, Kioschos JM, Marcus ML, White CW: Rethrombosis after reperfusion with streptokinase: importance of geometry of residual lesions. *Circulation* **69**: 991, 1984
26. Badger RS, Brown BG, Kennedy JW, Gallery CA, Mathey D, Bolson EL, Dodge HT: The diameter of the streptokinase-recanalized coronary lumen predicts reperfusion quality and reocclusion risk. *J Am Coll Cardiol* **5**: 421, 1985 (abst)
27. Detre KM, Wright E, Murphy M, Takaro T: Observer agreement in evaluating coronary angiograms. *Circulation* **52**: 979, 1975
28. DeRouen TA, Murray JA, Owen W: Variability in the analysis of coronary arteriograms. *Circulation* **55**: 324, 1977
29. Terrosu P, Ibba GV, Contini GM, Franceschino V: Angiographic features of the coronary arteries during intracoronary thrombolysis. *Br Heart J* **52**: 154, 1984
30. Brown BG, Bolson EL, Frimer M, Dodge HT: Quantitative coronary arteriography: Estimation of dimensions, hemodynamic resistance, and atheroma mass of coronary artery lesions using the arteriogram and digital computation. *Circulation* **55**: 329, 1977
31. McMahon MM, Brown BG, Cukingnan R, Rolett EL, Bolson E, Frimer M, Dodge HT: Quantitative coronary angiography: measurement of the "critical" stenosis in patients with unstable angina and single-vessel disease without collaterals. *Circulation* **60**: 106, 1979
32. Scoblionko DP, Brown BG, Mitten S, Caldwell JH, Kennedy JW, Bolson EL, Dodge HT: A new digital electronic caliper for measurement of coronary arterial stenosis: comparison with visual estimates and computer-assisted measurements. *Am J Cardiol* **53**: 689, 1984
33. Koh D, Mitten S, Stewart D, Bolson E, Dodge HT: Comparison between computerized quantitative coronary arteriography and clinical interpretation. *Circulation* **60**(suppl II): II-160, 1979 (abst)
34. Brown BG, Peterson RB: Computer-assisted measurements of coronary artery stenosis (reply to Letter to Editor). *Circulation* **60**: 1196, 1979
35. Liu LB, Richardson T, Holt JH, Taylor CB: Luminal eccentricity and deformity in atherosclerotic coronary arteries. *Paroi Arterielle* **3**: 167, 1976
36. Freudenberg H, Lichtlen PR: The normal wall segment in coronary stenosis — a postmortem study. *Z Kardiol* **70**: 863, 1981
37. Ganz W, Tamura K, Marcus HS, Donoso R, Yoshida S, Swan HJC: Measurement of coronary sinus blood flow by continuous thermodilution in man. *Circulation* **44**: 181, 1971
38. Gould KL, Kelley KO, Bolson EL: Experimental validation of quantitative coronary arteriography for determining pressure-flow characteristics of coronary stenosis. *Circulation* **66**: 930, 1982
39. Ridolfi RL, Hutchins GM: The relationship between coronary artery lesions and myocardial infarcts: ulceration of atherosclerotic plaque precipitating coronary thrombosis. *Am Heart J* **93**: 468, 1977
40. Sheehan FH, Brown BG, Mathey DG, Dodge HT: Effect of severe residual stenosis on recovery of function after streptokinase. *J Am Coll Cardiol* **3**: 526, 1984
41. Hartzler GO, Rutherford BD, McConahay DR, Johnson WL, Jr, McCallister BD, Gura GM, Jr, Conn RC, Crockett JE: Percutaneous transluminal coronary angioplasty with and without thrombolytic therapy for treatment of acute myocardial infarction. *Am Heart J* **106**: 965, 1983
42. DeWood MA, Spores J, Berg R Jr, Kendall RW, Grunwald RP, Selinger SL, Hensley GR, Suterland KI, Shields JP: Acute myocardial infarction: a decade of experience with surgical reperfusion in 701 patients. *Circulation* **68**(suppl II): II-8, 1983