

Regional and global left ventricular function in infants with anomalous origin of the left coronary artery from the pulmonary trunk: preoperative and postoperative assessment

AZARIA J. J. T. REIN, M.D., STEVEN D. COLAN, M.D., IRA A. PARNES, M.D.,
AND STEPHEN P. SANDERS, M.D.

ABSTRACT Anomalous origin of the left coronary artery from the pulmonary trunk (ALCA) remains a diagnostic as well as a therapeutic problem. The purposes of this study were: (1) to analyze left ventricular mechanics, including regional wall motion, in infants with ALCA, (2) to determine if the pattern of wall motion in infants with ALCA distinguishes these patients from those with congestive cardiomyopathy of other causes, and (3) to evaluate the potential for recovery of left ventricular function after successful restoration of a dual coronary artery system. Left ventricular mechanics were studied before and serially after surgery in six infants (2 to 13 months old) with ALCA. Fifteen age-matched normal subjects and seven age-matched patients with idiopathic congestive cardiomyopathy were also studied for comparison. Preoperatively, the end-diastolic volume in infants with ALCA was about four times larger than normal and did not differ from that in infants with CM; the myocardial volume was also about three times larger than normal, similar to that in the patients with CM. The myocardial volume/end-diastolic volume ratio was extremely low in patients with ALCA and in those with CM. The infants with ALCA did not exhibit specific segmental wall motion abnormalities but rather had global hypokinesis indistinguishable from that in the patients with CM. After successful repair, end-diastolic volume index rapidly decreased, reaching near normal values by 7 to 22 months after surgery, while myocardial volume index decreased at a slower rate, leading to an early phase of "overshoot hypertrophy," but reaching normal values by 7 to 22 months after surgery. The global and regional indexes of left ventricular function improved dramatically by 7 to 22 months after surgery, with the ejection fraction reaching the normal range and nine of the 13 left ventricular segments in short- and long-axis views exhibiting a normal shortening fraction. In conclusion (1) the regional wall motion pattern in infants with ALCA is not diagnostically useful for distinguishing ALCA from other causes of idiopathic congestive cardiomyopathy, (2) as in cardiomyopathy, preoperative left ventricular dysfunction in ALCA is severe and associated with inadequate left ventricular hypertrophy, (3) there is potential for nearly complete recovery of global and regional left ventricular function after successful repair of ALCA in early infancy.

Circulation 75, No. 1, 115-123, 1987.

ANOMALOUS ORIGIN of the left coronary artery from the pulmonary trunk (ALCA), although an uncommon lesion, remains a diagnostic and therapeutic problem. The diagnosis is difficult to confirm echocardiographically because of the unreliability of visualizing the origin of the coronary arteries.¹⁻³ It has been proposed that left ventricular regional wall motion ab-

normalities, as described in some adults with coronary artery disease, are also characteristic of ALCA.⁴⁻⁷ This finding has been reported to be useful in distinguishing ALCA from other causes of congestive cardiomyopathy.

If untreated, ALCA carries a grave prognosis.^{8,9} Nevertheless, the type of repair that achieves the best results in patients with ALCA has not been established. Simple ligation of the proximal main left coronary artery has been used with variable success.^{5, 10-13} More recently, methods to establish a dual coronary system by reimplantation or construction of an intra-

From the Department of Cardiology, The Children's Hospital, Boston.

Address for correspondence: Stephen P. Sanders, M.D., Department of Cardiology, The Children's Hospital, 300 Longwood Ave., Boston, MA 02115.

Received May 13, 1986; revision accepted Sept. 18, 1986.

pulmonary artery baffle have been introduced.^{5, 12-17} Nonetheless, the capacity of the left ventricle for recovery after successful surgical repair of this lesion remains uncertain.

This investigation was undertaken to address three major issues. (1) Are there regional wall motion abnormalities in infants with ALCA before repair that are similar to those observed in some adults with coronary artery disease? (2) Is the pattern of regional wall motion diagnostically useful in distinguishing infants with ALCA from those with congestive cardiomyopathy of other causes? (3) What is the potential for recovery of ventricular function after restoration of a dual coronary artery system?

Patients and methods

Between 1981 and 1985, 11 consecutive patients with ALCA underwent repair with use of an intrapulmonary artery baffle at The Children's Hospital, Boston. Seven patients were less than 18 months of age while the other four were teenagers. Of the seven infants, six underwent two-dimensional echocardiographic examinations 1 to 7 days before surgery and serially after repair (table 1). These six infants (2 to 13 months old) are the subjects of this report. Follow-up echocardiographic examinations were performed 8 to 15 days (three patients), 2 to 4 months (four patients), and 7 to 22 months (six patients) after surgery. One of the infants had a baffle occlusion proven by routine postoperative catheterization 3 years after surgery. Although he is asymptomatic and his systolic left ventricular function increased significantly (ejection fraction increased from 11% to 31%), he was excluded from this study since our purpose was to evaluate the recovery of left ventricular performance after successful repair. Fifteen normal infants matched with the patients with ALCA for the age at the time of each patient evaluation (range 1.4 to 24 months, mean 8.5) and seven similarly age-matched infants (range 2 to 30 months, mean 15) with idiopathic cardiomyopathy were studied for comparison.

Two-dimensional echocardiography. Subxiphoid short- and long-axis views of the left ventricle were obtained with a Dasonics Cardiovue 100 or a ATL Mark 600 with a 5.0 MHz transducer and were recorded on ½ inch videocassette tape. The left ventricular endocardial and epicardial borders for an entire cardiac cycle were digitized with a Franklin Quantic 1200 Review Center. The trabeculations and papillary muscles were

included in the cavity volume. Only the end-diastolic and end-systolic frames were hand digitized. The borders of the remaining frames were computer derived with an automatic edge-detection algorithm and subsequent frame-by-frame review and correction.¹⁸

Volume calculations. The intracavitary left ventricular end-diastolic volume was automatically calculated by a 5/6 area-length algorithm with the use of the cross-sectional area of the cavity at the level of the mitral valve and the long-axis length of the left ventricle from the mid aortic anulus to the apex (volume = 5/6 × area × length). The end-diastolic "epicardial" volume was calculated in an analogous manner with the use of the epicardial border of the free wall and the right ventricular endocardium of the interventricular septum. The myocardial volume was then calculated as the epicardial volume minus the intracavitary volume. Since myocardial mass is the product of myocardial volume and a constant (1.05 g/cm³), the terms mass and myocardial volume will be used interchangeably. The end-systolic cavity volume was calculated with the same formula used for end-diastolic volume and the stroke volume was computed as stroke volume = end-diastolic volume - end-systolic volume. The ejection fraction = stroke volume/end-diastolic volume. The end-diastolic, myocardial, and stroke volumes were then adjusted for the body surface area. The ratio between myocardial volume and the intracavitary end-diastolic volume was calculated as the myocardial volume/end-diastolic volume ratio.

Wall stress analysis. Left ventricular wall stress throughout ejection was calculated in one subject by previously described methods.¹⁹ The carotid pulse and the left ventricular echocardiogram, including the endocardial and epicardial borders of the left ventricular posterior wall, were digitized. The carotid pulse tracing was corrected for time delay by aligning the dicrotic notch with the first high-frequency component of the second heart sound. From the digitized data, instantaneous pressure (P), dimension (D), and wall thickness (WT) were derived by averaging five cardiac cycles. Left ventricular wall stress (WS) was calculated by the formula of Grossman *et al.*²⁰

$$WS = \frac{(p)(D) 1.35}{4(WT) [1 + (WT/D)]}$$

Regional wall motion analysis. The center of mass of the left ventricular cavity was calculated for each frame of the cardiac cycle. Sixty-four radii of equal arc were drawn outward from the center of mass for each frame to the point of intersection with the endocardial border (figure 1). Then, with the use of end-diastolic and end-systolic frames, the fractional shortening of each individual radius was calculated by dividing the differ-

TABLE 1
Preoperative and late postoperative volumes and ejection fraction

Patient	Sex	Before surgery						Late after surgery					
		Age (months)	BSA (m ²)	EDV _i (ml/m ²)	MV _i (ml/m ²)	MVR	EF (%)	Age (months)	BSA (m ²)	EDV _i (ml/m ²)	MV _i (ml/m ²)	MVR	EF (%)
W.J.	F	4	0.27	337	237	0.70	9	12	0.34	71	65	0.92	54
R.N.	F	8.5	0.39	174	172	0.98	38	30	0.54	109	107	.98	59
A.D.	M	2.5	0.25	348	204	0.59	23	13	0.42	76	95	1.25	72
A.K.	F	6	0.33	330	218	0.66	13	20	0.53	77	77	1.00	51
C.A.	F	2	0.27	152	96	0.63	28	9	0.40	80	71	0.89	62
T.E. ^A	M	13	0.38	484	334	0.67	11	36	0.75	204	165	0.81	31

BSA = body surface area; EDV_i = indexed end-diastolic volume; MV_i = indexed myocardial volume; MVR = myocardial volume/intracavitary volume ratio; EF = ejection fraction.

^APatient with baffle occluded; data not included in statistical analysis.

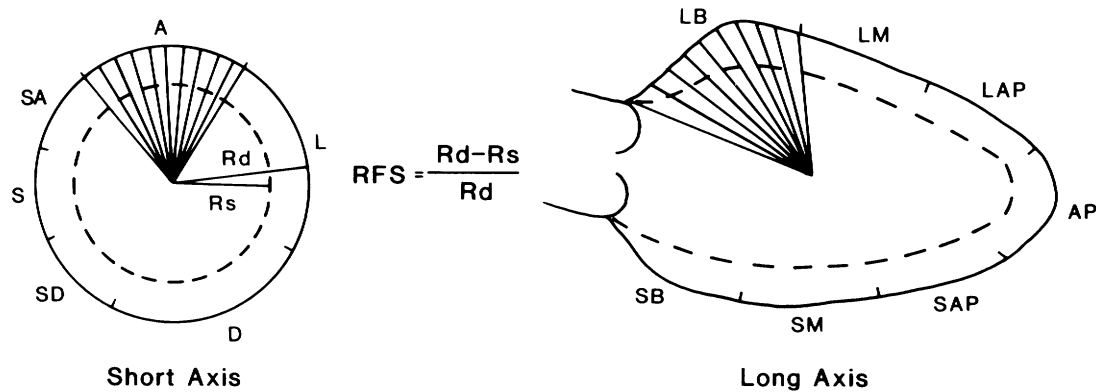


FIGURE 1. Regional wall motion analysis. Division of the endocardial contour into segments. In the short axis: A = anterior segment; L = lateral; D = diaphragmatic; SD = diaphragmatic septum; S = midseptum; SA = anterior-septum. In the long axis: LB = lateral-basal; LM = midlateral; LAP = apical-lateral; AP = apex; SAP = apical septum; SM = midseptum; SB = basal septum; RFS = radial shortening fraction; Rd = end-diastolic radius; Rs = end-systolic radius.

ence between the end-diastolic and end-systolic radii by the end-diastolic radius. The endocardial border was then divided into six segments in short axis and seven in segments in long axis based on anatomic landmarks. The shortening fraction was calculated for each segment by averaging the individual shortening fractions of the radii contained within each segment.

Rotational and translational motion of the heart was corrected by superimposition of the individual centers of mass and alignment of intracardiac anatomic reference points. In the short axis, the reference points for correction were the anterior and posterior insertions of the interventricular septum and for long-axis views, the reference points were the two edges of the aortic anulus and the left ventricular apex.

Statistical analysis. Preoperative and postoperative data from patients with ALCA were compared by use of the *t* test for paired data. The same test was used to compare the patients with ALCA before and after surgery with their respective age-matched counterparts in the normal and cardiomyopathic groups.

The variation in regional wall motion was evaluated within and between groups by unbalanced two-way analysis of variance. A *p* value < .05 was considered indicative of a statistically significant difference.

Results

Volumes. Before surgery, the mean indexed end-diastolic volume for the patients with ALCA was more than four times larger ($268 \pm 97 \text{ ml/m}^2$; $p < .001$) than that observed in the normal infants ($63 \pm 17 \text{ ml/m}^2$; figure 2), but not significantly different from that observed in the patients with cardiomyopathy ($281 \pm 146 \text{ ml/m}^2$). Although the end-diastolic volume did not change significantly by 8 to 15 days after surgery, by 2 to 4 months after surgery the indexed end-diastolic volume was less than half the preoperative value ($119 \pm 53 \text{ ml/m}^2$; $p < .02$) and at the late postoperative study (7 to 22 months after surgery), the end-diastolic volume was almost normal ($83 \pm 15 \text{ ml/m}^2$). At the late postoperative study, one patient (R. N.) had significant mitral regurgitation and an indexed end-diastolic volume significantly greater than the remainder

of the ALCA group (table 1). When this patient was excluded, the mean end-diastolic volume of the remaining patients with ALCA at the late postoperative study ($76 \pm 4 \text{ ml/m}^2$) was not significantly different from that of the normal group ($63 \pm 17 \text{ ml/m}^2$).

The preoperative indexed myocardial volume in patients with ALCA ($185 \pm 55 \text{ ml/m}^2$) was about three times larger than normal ($64 \pm 16 \text{ ml/m}^2$; $p < .001$), but not significantly different from that observed in patients with cardiomyopathy ($179 \pm 125 \text{ ml/m}^2$; figure 3, A). The indexed myocardial volume also decreased after surgery, but at a slower rate than that observed for the end-diastolic volume. By 7 to 22 months after surgery, the indexed myocardial volume was less than half the preoperative value ($83 \pm 17 \text{ ml/m}^2$; $p < .001$). The absolute (nonindexed) myocardial volume did not decrease significantly ($p = .11$) after surgery (preoperative = $56 \pm 18 \text{ ml}$; postoperative = $38 \pm 14 \text{ ml}$), although there was a trend toward reduction in myocardial volume (figure 3, B).

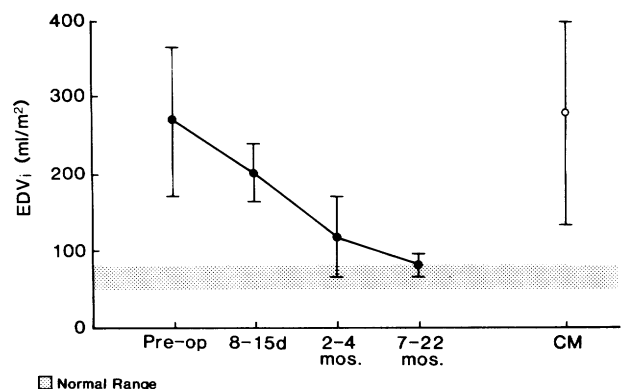


FIGURE 2. Indexed end-diastolic volume (EDV_i) before and after repair. d = days after surgery; mos = months after surgery; CM = idiopathic congestive cardiomyopathy.

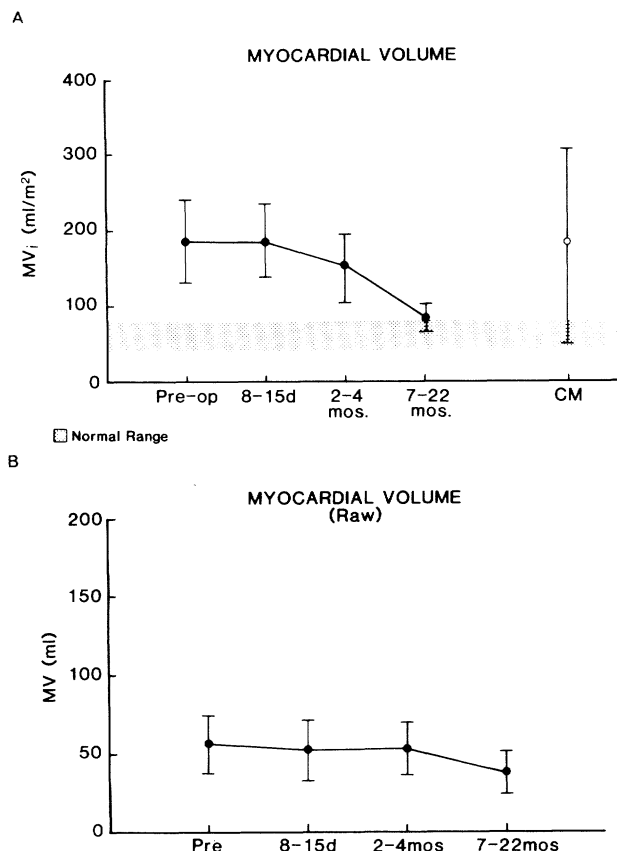


FIGURE 3. A, Indexed myocardial volume (MV_i) before and after repair. B, Raw (nonindexed) myocardial volume (MV) before and after repair. Other abbreviations as in figure 2.

Before surgery the myocardial mass/intracavitary volume ratio for the patients with ALCA (0.71 ± 0.16) was significantly lower than normal (1.01 ± 0.10 ; $p < .001$), but not significantly different from that observed in the patients with congestive cardiomyopathy (0.63 ± 0.11 ; figure 4). By 2 to 4 months after surgery, the mass/volume ratio (1.35 ± 0.44) was significantly higher than normal ($p < .05$), reflecting the more rapid reduction in end-diastolic volume compared with myocardial volume. At the late postoperative study (7 to 22 months), the mass/volume ratio in patients with ALCA (1.01 ± 0.14) was not significantly different from normal.

The ejection fraction (figure 5) before surgery ($22.2 \pm 11.6\%$) was significantly lower than normal ($66.1 \pm 5.2\%$; $p < .001$) and was not significantly different from that observed in patients with congestive cardiomyopathy ($23 \pm 13\%$). The ejection fraction doubled by 2 to 4 months after surgery ($49.7 \pm 16.6\%$; $p < .05$) and by 7 to 22 months after repair there was no significant difference between the patients with ALCA ($59.9 \pm 8.1\%$) and the normal subjects.

Regional wall motion. All left ventricular segments in both the short and long axis exhibited a significantly

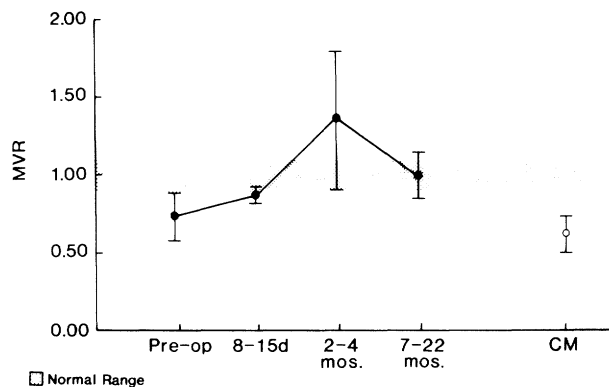


FIGURE 4. Myocardial volume/intracavitary volume ratio (MVR). Abbreviations as in figure 2.

lower segmental shortening fraction in preoperative patients with ALCA than in the normal subjects ($p < .005$ for all segments; figure 6). There was uniform reduction in shortening fraction for all segments, with no significant segment-to-segment variation in either long- or short-axis views.

The pattern of regional wall motion in the short and long axis in patients with ALCA before surgery was not statistically different from that observed in the patients with congestive cardiomyopathy (figure 6). Only the midseptal segment in the long axis exhibited a higher mean shortening fraction in patients with ALCA ($11 \pm 4\%$) than that observed in those with congestive cardiomyopathy ($1 \pm 4\%$; $p < .01$).

By 7 to 22 months after surgery for ALCA, shortening fraction increased in all the segments. In the short axis (figures 7, A, and 8), the segmental shortening fraction was not significantly different from normal for the diaphragmatic, diaphragmatic septal, and anterior septal segments. The three remaining segments exhibited a slightly lower segmental shortening fraction than normal ($p < .05$). In the long axis (figure 7, B), the

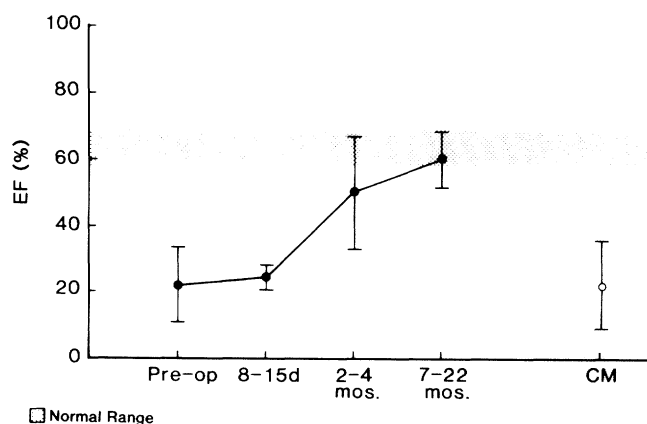


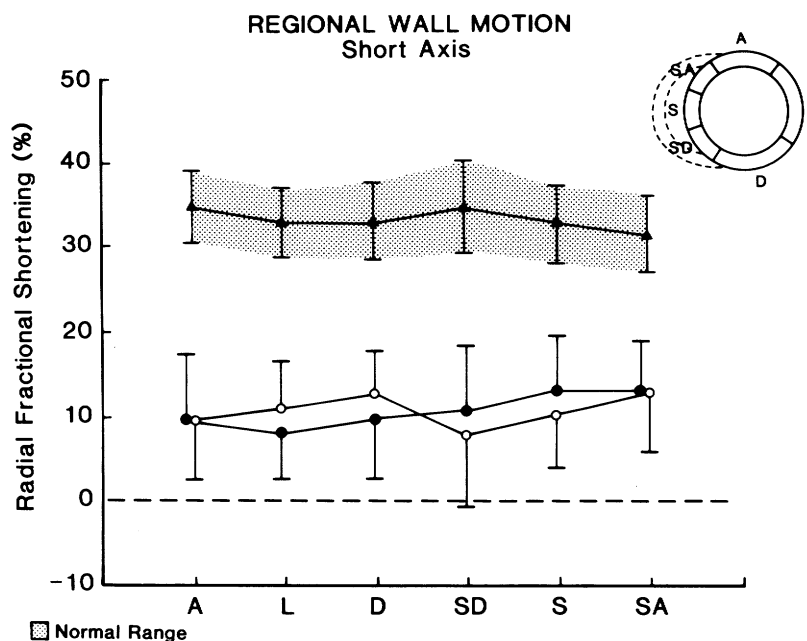
FIGURE 5. Ejection fraction (EF) before and after repair. Abbreviations as in figure 2.

shortening fraction for the lateral basal segment alone remained significantly below normal.

Wall stress. Left ventricular wall stress in one patient (C. A.) was markedly elevated throughout the period of ejection in the preoperative study compared with that in the postoperative state (figure 9) (peak systolic wall stress = 188 g/cm² preoperatively, 43 g/cm² post-

operatively; end-systolic wall stress 120 g/cm² preoperatively, 14 g/cm² postoperatively). The normal value in our laboratory for peak systolic stress in infants is 88 ± 17 g/cm² and that for end-systolic stress 29 ± 6 g/cm². Therefore, the preoperative wall stress was elevated and the postoperative wall stress was reduced with respect to normal values.

A



B

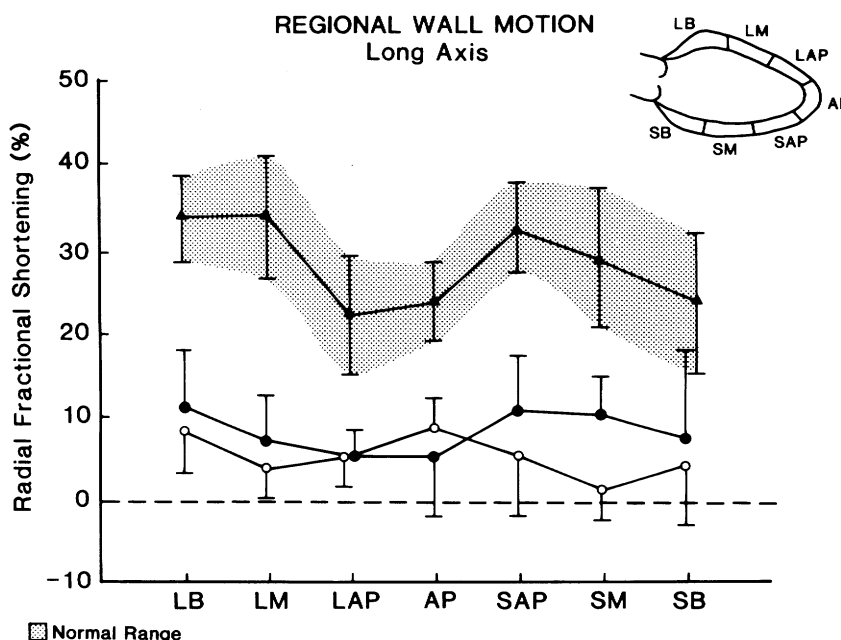


FIGURE 6. Regional wall motion analysis expressed as mean segmental shortening fraction ± 1 SD. A, Short axis; B, long axis. Triangles = normal subjects; closed circles = patients with ALCA before surgery; open circles = patients with cardiomyopathy. Segment labels as in figure 1.

Discussion

The hypothesis that specific regional wall motion abnormalities could be found in patients with ALCA and that this would provide another tool for diagnosing this disease was not verified. The pattern of global hypokinesis seen in patients with ALCA was similar to that observed in those with idiopathic cardiomyopathy. Furthermore, the disproportionate increase in cavity volume compared with left ventricular myocar-

dial volume was also analogous to that observed in idiopathic cardiomyopathy.

Global left ventricular dysfunction. The reason for hypokinesis of the left ventricular segments perfused by the right coronary artery remains unclear. Global hypokinesis rather than localized disturbances in left ventricular endocardial motion was also observed by Medina *et al.*²¹ in adults with coronary artery disease in the presence of left ventricular dilatation. They suggested

A

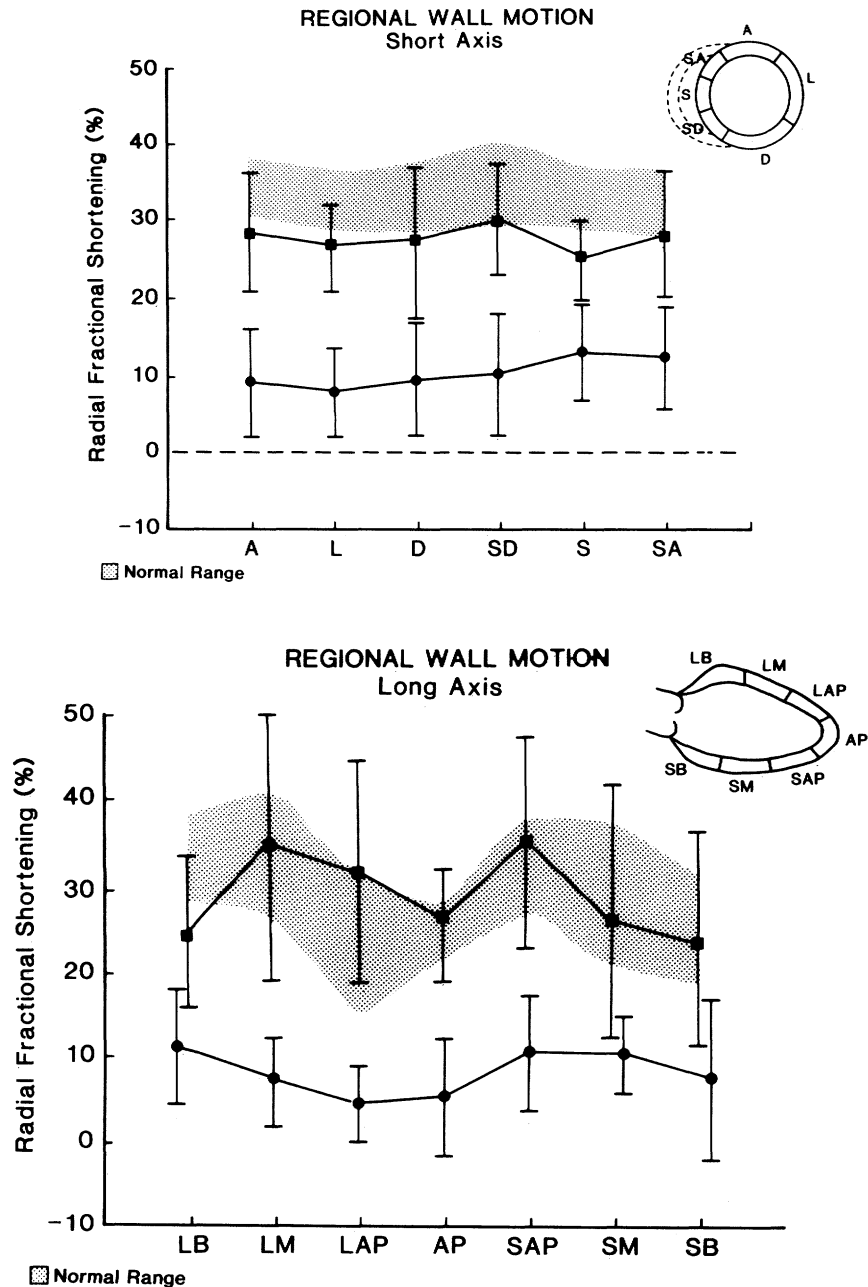


FIGURE 7. Regional wall motion analysis, as displayed in previous figures, comparing patients with ALCA before and after repair. A, Short axis; B, long axis. Closed circles = preoperative; closed squares = postoperative.

REGIONAL WALL MOTION Short Axis

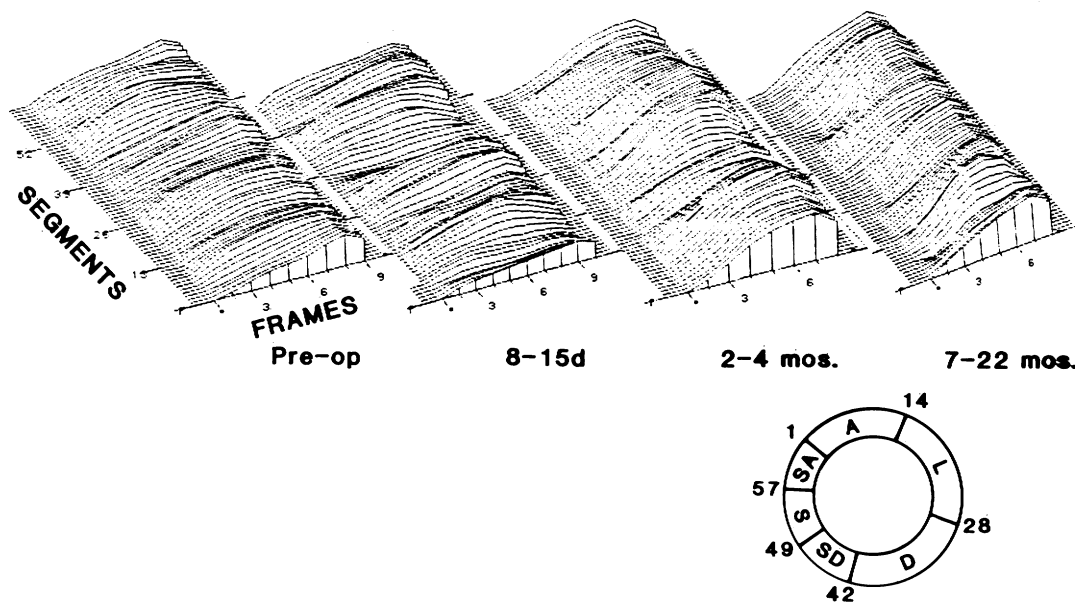


FIGURE 8. Frame-by-frame radial shortening fraction in systole in one patient (C. A.) with ALCA before and after repair. y axis = amplitude of shortening fraction. The shortening fraction is homogeneously depressed before surgery and gradually improves toward normal by 7 to 22 months after surgery.

this phenomenon resulted from the presence of multiple locations of infarction or extensive myocardial fibrosis. The dramatic recovery of regional and global left ventricular function observed in our five patients argues against such an explanation for global left ventricular dysfunction in infants with ALCA. The extreme left ventricular dilatation with a proportionately lesser increase in myocardial mass contributes to a very elevated left ventricular wall stress and consequently to an increase in oxygen requirement. Furthermore, due to collateral connections between the right and left coronary system, a steal phenomenon from the right to the left coronary artery system may be pres-

ent.^{5, 9, 10, 12} Thus, a severe imbalance of myocardial oxygen supply and demand appears to result in chronic and severe ischemia of the entire left ventricular myocardium. This hypothesis is further supported by the observation that restoration of a dual coronary system, and presumably adequate oxygen supply to the jeopardized left ventricular myocardium, was associated with dramatic and rapid improvement of global left ventricular systolic function and reduction of left ventricular volume.

The major determinants of myocardial oxygen consumption per gram of tissue are wall stress, heart rate, and contractility, with the latter making only a small contribution.²² As illustrated in this study, preoperatively both systolic wall stress and heart rate are markedly elevated. Thus, in addition to impaired oxygen supply, the myocardium is faced with an elevated demand. Further, wall stress is one of the major determinants of myocardial shortening characteristics.²³ Thus, the preoperative systolic dysfunction represents the combined effects of elevated afterload (wall stress) and reduced contractility. Postoperative recovery of systolic function reflects the reversal of both these abnormalities.

The rapid reduction in end-diastolic volume was not matched by a parallel decrease in myocardial mass. Although there was a trend toward reduction in absolute myocardial mass, this was not statistically signifi-

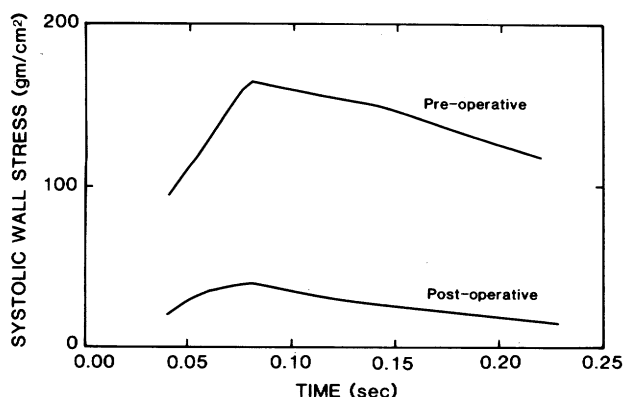


FIGURE 9. Left ventricular wall stress throughout systole in one patient (C. A.) before and after repair.

cant. The normalization of the mass index seen at the late postoperative examination was predominantly a function of somatic growth. In other words, the infants “grew into” their myocardial mass. An “overshoot hypertrophy” was therefore noted at 2 to 4 months after surgery due to rapid reduction in left ventricular volume with no change in myocardial mass, which is analogous to the findings described in patients recovering from myocarditis.²⁴

Prior studies. Regional disturbance in left ventricular endocardial motion has been described in infants with ALCA,⁴⁻⁶ although these observations may have been a result of the method used for analyzing wall motion. Driscoll *et al.*²⁵ described hypokinesis of the left ventricular posterior wall and septum based on M mode echocardiography. Since then, it has been well demonstrated that M mode echocardiography is not suitable for analysis of regional wall motion since only a small portion of the left ventricle is examined.

Extreme left ventricular dilatation along with severe global depression of left ventricular performance has been previously observed in infants with ALCA. Graham and Jarmakani²⁶ studied one infant whose preoperative end-diastolic volume was 558% of normal, with an ejection fraction of 10%. The mean end-diastolic volume in our study population was 425% of normal and the mean ejection fraction was 22%. Myocardial mass had not previously been studied in patients with ALCA so we were unable to compare our findings with those of others.

Left ventricular volume studies performed after simple ligation of the left coronary artery have shown a significant decrease in this variable in comparison with preoperative values, but not a return of normal volume. Wagner *et al.*²⁷ found that the left ventricular volume was still 329% of normal 21 months after left coronary artery ligation in one patient and that the ejection fraction was still depressed (19%). The patient studied by Graham and Jarmakani²⁶ was reexamined 5 years after left coronary artery ligation. The left ventricular end-diastolic volume was still 170% of normal, with a mildly depressed ejection fraction of 52%. Our single patient (T. E.) with baffle obstruction is comparable to those who have undergone ligation of the left main coronary artery. In this patient the end-diastolic volume decreased from 768% of normal to 324% of normal, while the ejection fraction increased from 11% to 31%.

In contrast, Tyrell and Bharadwaj²⁸ found that the ejection fraction increased from 39% before surgery to 62% 2 weeks after surgery in a patient with ALCA in whom a dual coronary system was restored. Levitsky

*et al.*¹⁶ also studied one infant before and 7 months after direct implantation of the left coronary artery into the aorta. The ejection fraction increased from 30% to 48%, with a fall in left ventricular end-diastolic pressure from 10 to 7 mm Hg. Our study of five infants further corroborates the dramatic improvement in left ventricular performance and normalization of left ventricular volume achieved after establishment of a dual coronary artery system.

The high survival (100%) after surgery of our patients has not been the experience at other institutions. Arciniegas *et al.*¹² reported two deaths among 17 infants (12%) who underwent different types of surgery for ALCA. They recommended establishment of a two coronary arterial system as the procedure of choice. Driscoll *et al.*²⁵ disagreed with this recommendation and postulated that this high survival rate of 88% after surgery was probably a result of the method of patient selection, by which the sickest infants had not been operated upon. The mortality rate reported by Driscoll *et al.* reached 75% when the infants underwent repair in their first year of life. Consequently, they strongly recommended delay of surgery until infants were up to 18 months of age, in spite of the 66% mortality rate observed in medically treated infants. We did not experience any operative or late mortality in this series. The difference in survival between our series and others may be related to the different surgical techniques used.

Methodologic issues. The 5/6 area-length algorithm used for volume calculation may not be accurate for estimation of volume in an extremely dilated left ventricle. However, even if the left ventricle assumed a spherical configuration, the error in volume estimation by this algorithm would be about 30%.

The methods for analysis of regional wall motion have been widely discussed in the literature.²⁹⁻³⁶ A floating center of mass method, as used in our study, has the advantage of correcting the rotational and translational motion of the heart. The disadvantage, however, is that this method may attenuate the amplitude of localized dysynergy. Preliminary studies performed in our laboratory in normal infants showed that analysis of left ventricular regional wall motion by a fixed-reference method was less reproducible, with more variation between and among segments, as compared with the floating center of mass model. This was not only due to the motion of the heart but also to instability of the video image when examined frame by frame.

The amplitude of left ventricular endocardial motion was expressed as radial shortening fraction rather than

area change. Although it has been much debated in the literature, there seems to be no advantage to the use of one method over the other. Both yield equal sensitivity and specificity in the detection of regional wall motion abnormalities by a floating-reference system.³⁰

In conclusion, infants with ALCA generally do not exhibit specific segmental abnormalities, but rather exhibit global left ventricular hypokinesis indistinguishable from that in patients with idiopathic congestive cardiomyopathy. As in cardiomyopathy, preoperative left ventricular dysfunction in ALCA is associated with inadequate hypertrophy, as reflected by an abnormally low mass/volume ratio. After successful intrapulmonary artery baffle repair, there is a rapid reduction in left ventricular volume and dramatic recovery of systolic function.

References

- Fisher EA, Sepehri B, Lendrum B, Luken J, Levitski S: Two dimensional echocardiographic visualization of the left coronary artery in anomalous origin of the left coronary artery from the pulmonary artery. Pre- and postoperative studies. *Circulation* **63**: 698, 1981
- Caldwell RL, Weyman AE, Girod DA, Hurwitz RA, Feigenbaum H: Cross sectional echocardiographic differentiation of anomalous left coronary artery from primary cardiomyopathy. *Circulation* **58**(suppl II): II-202, 1978 (abst)
- Martin GR, Cooper MJ, Silverman NH, Soifer SJ: Contrast echocardiography in the diagnosis of anomalous left coronary artery arising from the pulmonary artery. *Pediatr Cardiol* **6**: 203, 1986
- Shapiro J, Boxer R, Krongard E: Echocardiography in infants with anomalous origin of the left coronary artery. *Pediatr Cardiol* **1**: 23, 1979
- Neufeld HN, Schneeweiss A: Anomalous origin of the coronary arteries from the pulmonary artery. In *Coronary artery disease in infants and children*. Philadelphia, 1983, Lea & Febiger, p 1
- Terai M, Nagai Y, Toba T: Cross-sectional echocardiographic findings of anomalous origin of left coronary artery from pulmonary artery. *Br Heart J* **50**: 104, 1983
- Wasserman LA, Eshaghpour E, Takahashi O, Iskandrian A, Kotler MN: The noninvasive assessment of anomalous origin of the left coronary artery from the pulmonary artery. *Cathet Cardiovasc Diagn* **5**: 85, 1979
- Wesselhoeft H, Fawcett JS, Johnson AL: Anomalous origin of the left coronary artery from the pulmonary trunk: its clinical spectrum, pathology and pathophysiology, based on a review of 140 cases with seven further cases. *Circulation* **38**: 403, 1968
- Perry LW, Scott LP: Anomalous left coronary artery from pulmonary artery. Report of 11 cases: review of indications for and results of surgery. *Circulation* **41**: 1043, 1970
- Nadas AS, Gamboa R, Hugenoltz PG: Anomalous left coronary artery originating from the pulmonary artery: report of two surgically treated cases with a proposal of hemodynamic and therapeutic classification. *Circulation* **29**: 167, 1964
- Likar I, Criley JM, Lewis KB: Anomalous left coronary artery arising from the pulmonary artery in an adult: a review of the therapeutic problem. *Circulation* **33**: 727, 1966
- Arciniegas E, Farooki ZQ, Hakimi M, Green EW: Management of anomalous left coronary artery from the pulmonary artery. *Circulation* **62**(suppl I): I-180, 1980
- Askenazi J, Nadas AS: Anomalous left coronary artery originating from the pulmonary artery: report on 15 cases. *Circulation* **51**: 976, 1975
- Hamilton DJ, Ghosh PK, Donnely RJ: An operation for anomalous origin of left coronary artery. *Br Heart J* **41**: 121, 1979
- Takeuchi S, Imamura H, Katsumoto K, Hayashi I, Kathogi T, Yozu R, Ohkura M, Inoue T: New surgical method for repair of anomalous left coronary artery from pulmonary artery. *J Thorac Cardiovasc Surg* **78**: 7, 1979
- Levitski S, Van der Horst R, Hastreiter A, Fisher E: Anomalous left coronary artery in the infant, recovery of ventricular function following early direct aortic implantation. *J Thorac Cardiovasc Surg* **79**: 598, 1980
- Midgley FM, Watson DC, Scott LP, Kuehl KS, Perry LW, Galio FM Jr, Ruckman RN, Shapiro SR: Repair of anomalous origin of the left coronary artery in the infant and small child. *J Am Coll Cardiol* **4**: 1231, 1984
- Conetta DA, Geiser EA, Oliver LH, Miller AB, Conti CR: Reproducibility of left ventricular area and volume measurements using a computer endocardial edge-detection algorithm in normal subjects. *Am J Cardiol* **56**: 947, 1985
- Colan SD, Borow KM, Neumann A: Left ventricular end-systolic stress-rate-corrected velocity of circumferential shortening relation: a load independent index of myocardial contractility. *J Am Coll Cardiol* **4**: 715, 1984
- Grossman W, Jones D, McLaurin LP: Wall stress and patterns of hypertrophy in the human left ventricle. *J Clin Invest* **56**: 56, 1975
- Medina R, Panidis IP, Morganroth J, Kotler MN, Mintz GS: The value of echocardiographic wall motion abnormalities in detecting coronary artery disease in patients with or without a dilated left ventricle. *Am Heart J* **109**: 799, 1985
- Weber KT, Janicki JS: Myocardial oxygen consumption—the role of wall force and shortening. *Am J Physiol* **233**: H421, 1977
- Colan SD, Borow KM, Gamble WJ, Sanders SP: Effects of enhanced afterload (methoxamine) and contractile state (dobutamine) on the left ventricular late-systolic wall stress-dimension relation in humans. *Am J Cardiol* **52**: 1304, 1983
- Chung KJ, Fulton DR, Rabinovitch M: Transient myocardial hypertrophy among survivors with acute myocarditis. *Circulation* **70**(suppl II): II-131, 1984 (abst)
- Driscoll DJ, McHill MR, Mullins CE, Cooley DA, McNamara DG: Management of symptomatic infants with anomalous origin of the left coronary artery from the pulmonary artery. *Am J Cardiol* **47**: 642, 1981
- Graham PT Jr, Jarmakani JM: Evaluation of ventricular function in infants and children. *Pediatr Clin N Am* **18**: 1109, 1971
- Wagner HR, Nadas AS, Hugenoltz PG: Anomalous left coronary artery originating from the pulmonary artery. Detailed follow-up report of successful ligation of the aberrant vessel in two infants. *Pediatrics* **40**: 320, 1967
- Tyrell MJ, Bharadwaj B: Anomalous origin of the left coronary: the effects of aortocoronary bypass on left ventricular function. *Can Med Assoc J* **107**: 118, 1972
- Rein AJT, Saposnikov D, Lewis N, Halon DA, Gotsman MS, Lewis BS: Regional left ventricular ejection fraction from real-time echocardiography. *Int J Cardiol* **2**: 61, 1982
- Fujii J, Sawada H, Aizawa T, Kato K, Onoe M, Kuno Y: Computer analysis of cross sectional echocardiograms for quantitative evaluation of left ventricular asynergy in myocardial infarction. *Br Heart J* **51**: 139, 1984
- Schnittger I, Fitzgerald PJ, Gordon EP, Alderman EL, Popp RL: Computerized quantitative analysis of left ventricular motion by two-dimensional echocardiography. *Circulation* **70**: 242, 1984
- Parisi AF, Moynihan PF, Folland ED, Feldman CL: Quantitative detection of regional left ventricular contraction abnormalities by two-dimensional echocardiography. II. Accuracy in coronary artery disease. *Circulation* **63**: 761, 1981
- Moynihan PF, Parisi AF, Feldman CL: Quantitative detection of regional left ventricular contraction abnormalities by two-dimensional echocardiography. I. Analysis of methods. *Circulation* **63**: 752, 1981
- Erbel R, Schweizer P, Meyer J, Krebs W, Yalkinoglu O, Effert S: Sensitivity of cross sectional echocardiography in detection of impaired global and regional left ventricular function: prospective study. *Int J Cardiol* **7**: 375, 1985
- Clayton PD, Jeppson GM, Klausner SC: Should a fixed external reference system be used to analyze left ventricular wall motion? *Circulation* **65**: 1518, 1982
- Lorente P, Azancot I, Masquet C, Babalis D, Duriez M, Slama R: Relationships between single-vessel coronary artery obstructions and wall motion dysfunction analyzed by four computer-based methods. *Int J Cardiol* **7**: 361, 1985