

## **Duplex scanning for diagnosis of aortoiliac and femoropopliteal disease: a prospective study**

TED R. KOHLER, M.D., DALE R. NANCE, M.D., MILES M. CRAMER, B.S., R.V.T.,  
NORMA VANDENBURGHE, R.N., R.V.T., AND D. E. STRANDNESS, JR., M.D.

**ABSTRACT** We compared ultrasonic duplex scanning and angiography for the localization and classification of arterial stenoses and occlusions in 32 patients. The criteria for the detection of a greater than 50% diameter reducing stenosis was an increase in peak systolic velocity of greater than 100%, loss of reverse flow, and spectral broadening. Duplex studies and angiograms were evaluated in a blinded fashion. The agreement between duplex scanning and angiography for the 383 arterial segments studied was not significantly different than the previously reported agreement between two different radiologists reading the same angiograms (kappa of 0.55 vs 0.63). For detecting stenoses that were greater than 50% diameter reducing by angiography, duplex scanning had a sensitivity of 82%, a specificity of 92%, a positive predictive value of 80%, and a negative predictive value of 93%. These results are as good as previously reported comparisons between two different radiologists' readings of the same angiograms.

*Circulation* 76, No. 5, 1074-1080, 1987.

ANGIOGRAPHY is currently required to plan treatment for symptomatic aortoiliac and femoropopliteal arterial occlusive disease because current noninvasive tests are not sufficiently accurate or anatomically specific. Recent clinical experience has suggested that duplex ultrasound techniques similar to those used for the evaluation of carotid artery disease can be used for these peripheral arteries as well.<sup>1, 2</sup> The agreement between duplex scanning and angiography was as good as the agreement between two different radiologists evaluating the same angiograms. This report describes our clinical experience with duplex scanning and suggests how it can be integrated into clinical practice.

### **Methods**

Between July 1, 1984, and February 28, 1987, we performed 155 duplex examinations for symptomatic aortoiliac and femoropopliteal artery disease. Data from 32 patients who underwent angiography within 3 months of this noninvasive examination form the basis of this report.

Studies were performed with a Mark 600 or Ultramark 8 duplex scanner (Advanced Technology Laboratories, Inc., Bothell, WA). The dynamic range was set at 50 dB. The duplex scanner combines a B mode ultrasound imager with a pulsed Doppler flow detector to determine flow velocities at specific

locations along visualized arteries. The path of the Doppler beam is indicated by a white line on the B mode image, and the region from which velocity data are obtained (the sample volume) is indicated by a cross mark on that line (figure 1). Because this system permits measurement of the angle of incidence of the Doppler beam with the vessel axis, velocity can be calculated by the Doppler equation.

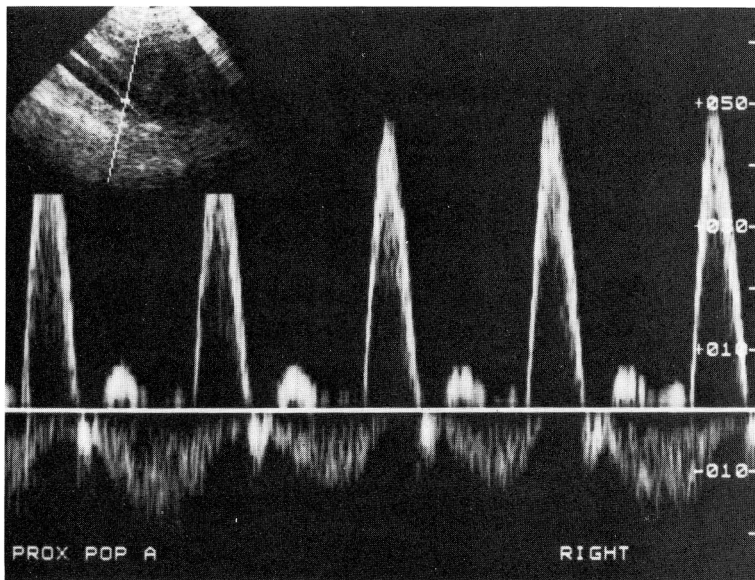
All examinations were performed by one of two technologists (M. C. or N. V.). Our technique has been previously described.<sup>1, 2</sup> Patients are asked to fast for 12 hr before the examination to decrease interference by abdominal gas. This has allowed us to obtain velocity signals from aortoiliac segments in approximately 90% of patients. Study of the recumbent patient starts at the proximal abdominal aorta, with a 3 MHz transducer for average-sized adults and a 5 MHz transducer for asthenic individuals. The transducer is placed just above the umbilicus to image the aorta and is then moved distally to the inguinal ligament, following the course of the iliac arteries. Examination of the more superficial distal arteries is performed with higher-resolution, 5 or 7.5 MHz, transducers. The popliteal artery is examined with the patient prone and the knee slightly flexed. When time permits we attempt to study all segments in each patient. Occasionally limited examinations directed at specific arterial sites are performed. A single extremity can be studied in less than an hour, whereas a complete study may take 2 hr or more.

We prospectively applied classification criteria previously described by Jager et al.<sup>1, 2</sup> Each arterial segment is graded into five categories of stenosis: normal, 1% to 19% diameter reduction, 20% to 49% diameter reduction, 50% to 99% diameter reduction, and total occlusion. Typical waveforms for each category are shown in figure 2. Normal arteries have a triphasic signal and minimal spectral broadening. The spectral band is narrow with a clear area below the systolic peak (systolic window). A diameter reduction of 1% to 19% causes only spectral broadening and loss of the systolic window. Waveform contour

From the Departments of Surgery and Radiology, University of Washington School of Medicine, Seattle.

Address for correspondence: Ted R. Kohler, M.D., Department of Surgery, Harborview Medical Center ZA-16, 325 9th Ave., Seattle, WA 98104.

Received May 18, 1987; revision accepted August 6, 1987.



**FIGURE 1.** Typical output from a duplex examination. The B mode image is shown in the upper left.

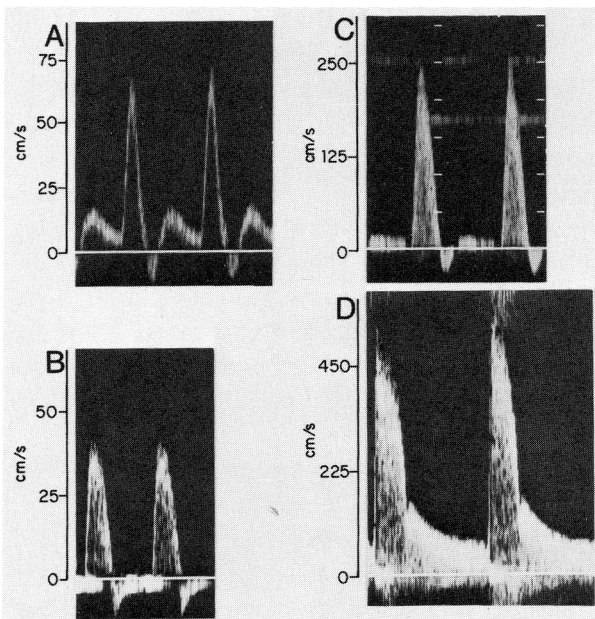
and peak systolic velocity remain normal. In moderate stenoses (20% to 49% diameter reduction), the peak systolic velocity increases 30% to 100% with respect to the normal segment immediately proximal to the stenosis, and spectral broadening is marked. Stenoses of 50% to 99% diameter reduction are considered hemodynamically significant. Reverse velocity is absent in these stenoses, the systolic peak is increased by 100% or more, and spectral broadening is usually prominent. Occluded arteries have no detectable flow, and velocity is markedly decreased in the segments proximal to the occlusion.

Standard uniplanar peripheral angiograms were obtained by the Seldinger technique. Oblique views of iliac and proximal femoral arteries were obtained at the discretion of the angiographer. Duplex scan and angiographic results were evaluated independently and disease classification was reported for the following locations: the distal aorta, common and external iliac

arteries, common and deep femoral arteries, the mid, middle, and distal superficial femoral artery, and the popliteal artery. Lesions that had significant pressure gradients measured at angiography ( $\geq 15$  mm Hg at rest) were assumed to have greater than 50% diameter reducing stenoses and were classified as such for comparison with duplex scanning even if the radiologist graded them as less than 50% diameter reducing based on the image. Results were tabulated and analyzed by two-way contingency tables and the kappa statistic, which evaluates congruence for this type of categorical data. Kappa takes into account agreement that occurs by chance alone and ranges from 0 (random agreement) to 1 (perfect agreement).<sup>3</sup> Sensitivity, specificity, and positive and negative predictive values were also calculated for the ability of duplex scanning to correctly identify lesions that either had a measured pressure gradient of greater than 15 mm Hg or were greater than 50% diameter reducing by angiography.

## Results

Complete examinations were performed in 20 patients. Examinations (generally both angiograms and duplex scans) were directed to only one extremity in four cases, to only femoropopliteal segments in three cases, and to only aortoiliac segments in five cases. One segment (an iliac artery) could not be investigated by duplex scanning because of overlying bowel gas. Common femoral arteries could not be studied by angiography because of overlying metal orthopedic prostheses in one patient. A total of 393 arterial segments were studied by both methods. The two-way contingency table for classification of disease by duplex scanning and angiography is given in table 1. The kappa value was 0.55. Exact agreement occurred in 273 (69%), and agreement within one category occurred in 343 (87%). For correctly identifying lesions that had a significant measured pressure gradient or were greater than 50% diameter reducing, duplex scanning had a sensitivity of 82%, a specificity of 92%, a positive predictive value



**FIGURE 2.** Typical waveforms for the four categories of stenosis: A, normal; B, 1% to 19% diameter reduction; C, 20% to 49% diameter reduction; D, 50% to 99% diameter reduction.

**TABLE 1****Two-way contingency table for results of duplex scanning vs angiography**

	Duplex classification				
	0	1–19%	20–49%	50–99%	100%
Angiogram classification					
0	161	16	9	6	1
1–19%	16	12	4	3	0
20–49%	20	10	14	12	0
50–99%	6	3	9	32	1
100%	2	0	0	2	54
	n = 393		kappa = 0.55		

of 80%, and a negative predictive value of 93%. Five of the significant stenoses missed by duplex scanning were less than total occlusions, where flow rates were inadequate to produce significant velocity increases. Table 2 lists sensitivities, specificities, and kappa values for the various arterial segments. Kappa values were low for the aorta and the common and deep femoral arteries. For the aorta and common femoral artery, this reflected the small number of diseased segments found and the tendency for duplex scanning to classify angiographically normal arteries as minimally diseased (1% to 15% diameter reduction). Kappa values for the deep femoral segments were low because of significant errors in agreement, including one normal artery classified as occluded and one occluded artery classified as normal. Results were particularly good for iliac and superficial femoral segments.

Eight patients had pressure gradients measured in 11 segments at the time of angiography. Significant gradients ( $> 15$  mm Hg) were measured in seven segments. These were classified as greater than 50% diameter reducing in six cases by duplex scanning and in five

cases by angiography (one lesion was classified as  $< 50\%$  diameter reducing by both techniques). Four lesions had less than 15 mm Hg gradients. Both techniques classified two of these as less than 50% diameter reducing and one as greater than 50% diameter reducing, and the remaining segment was classified as less than 50% diameter reducing by angiography and greater than 50% diameter reducing by duplex scanning. Ten bypass grafts (aortoiliac and femoropopliteal) were also studied in this group of patients. Duplex scanning correctly identified seven normal grafts and two graft stenoses. One graft stenosis was not detected by duplex scanning.

## Discussion

Angiography has long been the definitive test for symptomatic aortoiliac and lower extremity arterial disease. However, this approach provides anatomic rather than functional data and has many limitations. Interpretation is subject to wide interobserver variability.<sup>4, 5</sup> Because atherosclerotic lesions are often eccentric, the angiographic appearance may be misleading, especially if only unipolar views are obtained. The best way to determine the hemodynamic significance of arterial lesions is to measure the pressure gradient at angiography, but this is not always practical or anatomically possible. Finally, the invasive nature and relatively high cost of angiography make it unsuitable for screening purposes or routine follow-up. Before the introduction of duplex scanning, efforts were made to predict the status of the aortoiliac segment from continuous-wave Doppler signals taken at the common femoral artery. Because the velocity at the sites of involvement could not be assessed by this approach, various forms of waveform analysis, such as the pulsatility index<sup>6</sup> and the Laplace transform<sup>7</sup> were used. An inherent problem with these techniques is that, like all indirect tests, they rely on detecting changes downstream from diseased segments, and waveforms can normalize within a few vessel diameters.<sup>8</sup> In addition, these tests cannot distinguish near-total from total occlusion, cannot detect minimal disease, and do not reliably quantify disease in multiple segments.<sup>9–15</sup>

Duplex scanning overcomes many of these difficulties by combining a B mode ultrasound image with a pulsed Doppler flow detector and spectrum analyzer. This allows acquisition of Doppler information directly from areas of stenosis and measurement of the Doppler angle. Flow velocity is increased at sites of stenosis, and turbulence develops. Duplex scanning can detect both of these hemodynamic changes. Over the last

**TABLE 2****Duplex scanning vs angiography**

Arterial segment	n	Kappa	Sensitivity <sup>A</sup>	Specificity <sup>A</sup>	PPV <sup>A</sup>	NPV <sup>A</sup>
Aorta <sup>B</sup>	25	0.36	1.00	1.00	1.00	1.00
Iliac	110	0.58	0.89	0.90	0.75	0.96
Common femoral	50	0.42	0.67	0.98	0.80	0.96
Superficial femoral	123	0.61	0.84	0.93	0.90	0.88
Profunda	48	0.34	0.67	0.81	0.53	0.88
Popliteal	37	0.40	0.75	0.97	0.86	0.93
All segments	393	0.55	0.82	0.92	0.80	0.93
Grafts	10	0.57	0.67	1.00	1.00	0.87

PPV = positive predictive value; NPV = negative predictive value.

<sup>A</sup>For predicting hemodynamically significant stenoses.<sup>B</sup>No aortic segments had  $> 50\%$  stenosis in the study group.

decade an accurate classification scheme using this technique for diagnosis of disease in the internal carotid artery was developed.<sup>16-22</sup> Jager et al.<sup>1, 2</sup> used similar principles to develop a classification strategy for lower-extremity arterial disease. Their validation trial used 338 arterial segments of 30 patients (54 extremities) studied both by ultrasound and angiography. All angiograms were independently reviewed by two radiologists. The kappa value for duplex scanning vs angiography was 0.69, and that for one radiologist's interpretation of the angiograms vs the other's was 0.63. Results were not affected by multisegment disease. For categorizing stenoses as greater than or less than 50% diameter reduction, duplex scanning had a sensitivity of 77%, a specificity of 98%, a positive predictive value of 94%, and a negative predictive value of 92%. This was similar to comparison of the two radiologists' interpretations of the same angiograms (sensitivity 87%, specificity 94%, positive predictive value 88%, and negative predictive value 93%).

Our results applying these duplex scanning techniques prospectively to patients considered likely candidates for angioplasty or surgery were similar to those of Jager et al.<sup>1, 2</sup> Although overall agreement between duplex scanning and angiography was slightly less (kappa value 0.55 vs 0.69), specificity was comparable (92% vs 98%) and sensitivity was slightly higher (82% vs 77%). Unlike other noninvasive tests, duplex scanning reliably detected aortoiliac lesions. The sensitivity of duplex scanning for detecting hemodynamically significant stenoses was decreased in low-flow segments distal to total occlusions. Recognition of this difficulty should allow us to improve accuracy.

From a clinical standpoint, duplex scanning can localize and classify peripheral arterial stenoses nearly as well as angiography. A normal duplex study virtually excludes significant occlusive disease (negative predictive value of 93%) and abnormal studies can direct further examination. When the duplex study localizes the suspected area of disease, it can be helpful to the angiographer, who may be able to tailor the angiographic technique to fit the needs of the patient. Stenoses that are amenable to percutaneous transluminal angioplasty can be identified in patients who are not ideal candidates for operation and therefore would not otherwise undergo angiography. In addition, duplex scanning provides a baseline for assessing the early and long-term results of percutaneous transluminal angioplasty. Whereas other noninvasive methods are not sufficiently sensitive for this purpose,<sup>23, 24</sup> duplex scanning is ideal because it can detect restenosis of segments dilated by angioplasty or bypass graft

stenosis before pressure drops occur. Velocity information is easily obtained from bypass grafts with this technique. Flow velocities less than 40 cm/sec in femoropopliteal or femorotibial bypass grafts are associated with a high rate of graft failure.<sup>25</sup> Duplex scanning has also been useful for demonstrating ongoing thrombolysis in patients undergoing thrombolytic therapy. Several examples will demonstrate its use in patient management.

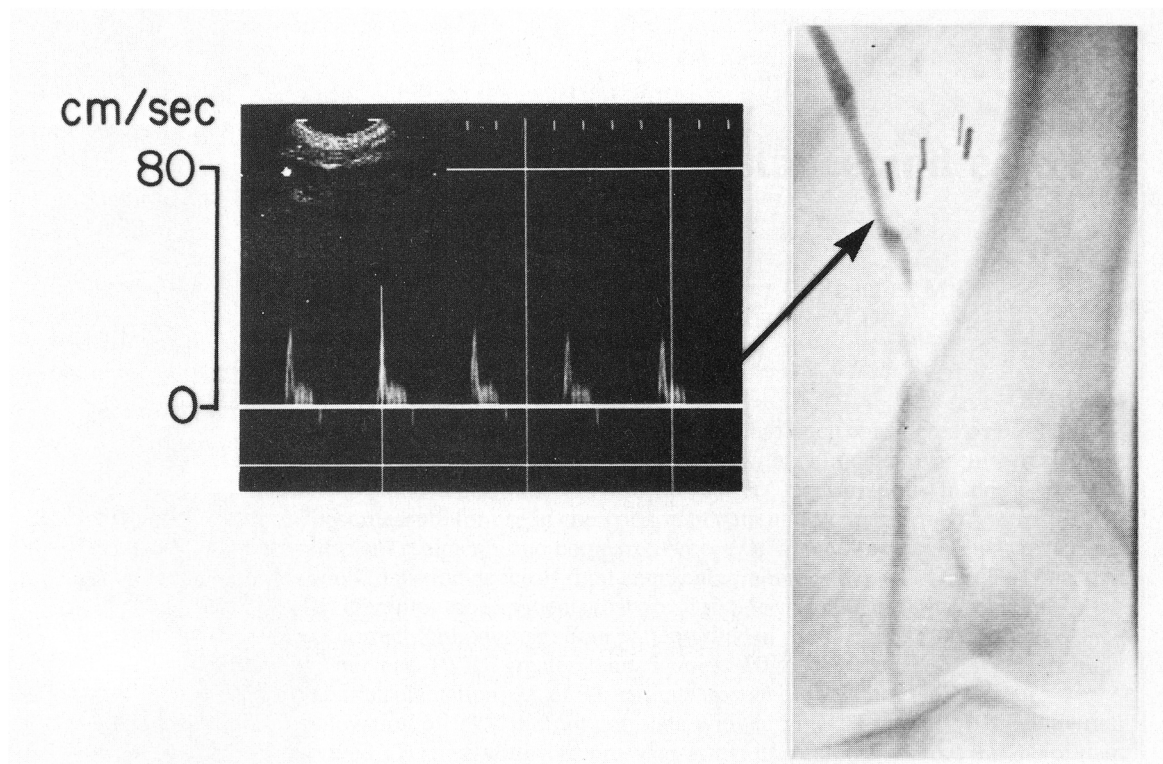
*Patient 1.* A 66-year old woman developed recurrent symptoms 6 months after undergoing a below-knee, in situ, femoral-popliteal bypass graft. The ankle-arm index had dropped to its preoperative value, and the popliteal pulse was absent on physical examination. The bypass graft appeared to be occluded. Because limb viability was not threatened, bypass to an infra-popliteal vessel was not indicated. However, duplex scanning revealed that the graft was still patent, although with minimal flow because of a tight stenosis at the distal anastomosis (figure 3). Angiography confirmed this finding, and repair was possible with patch angioplasty.

*Patient 2.* A 65-year old woman was seen in the clinic for left leg claudication. Femoral pulses were slightly diminished on the affected side. Duplex scanning revealed a significant proximal common iliac stenosis (figure 4). At angiography the stenosis was not visualized, but pressure measurements confirmed a significant pressure drop. Angioplasty successfully eliminated the stenosis and the patient's symptoms.

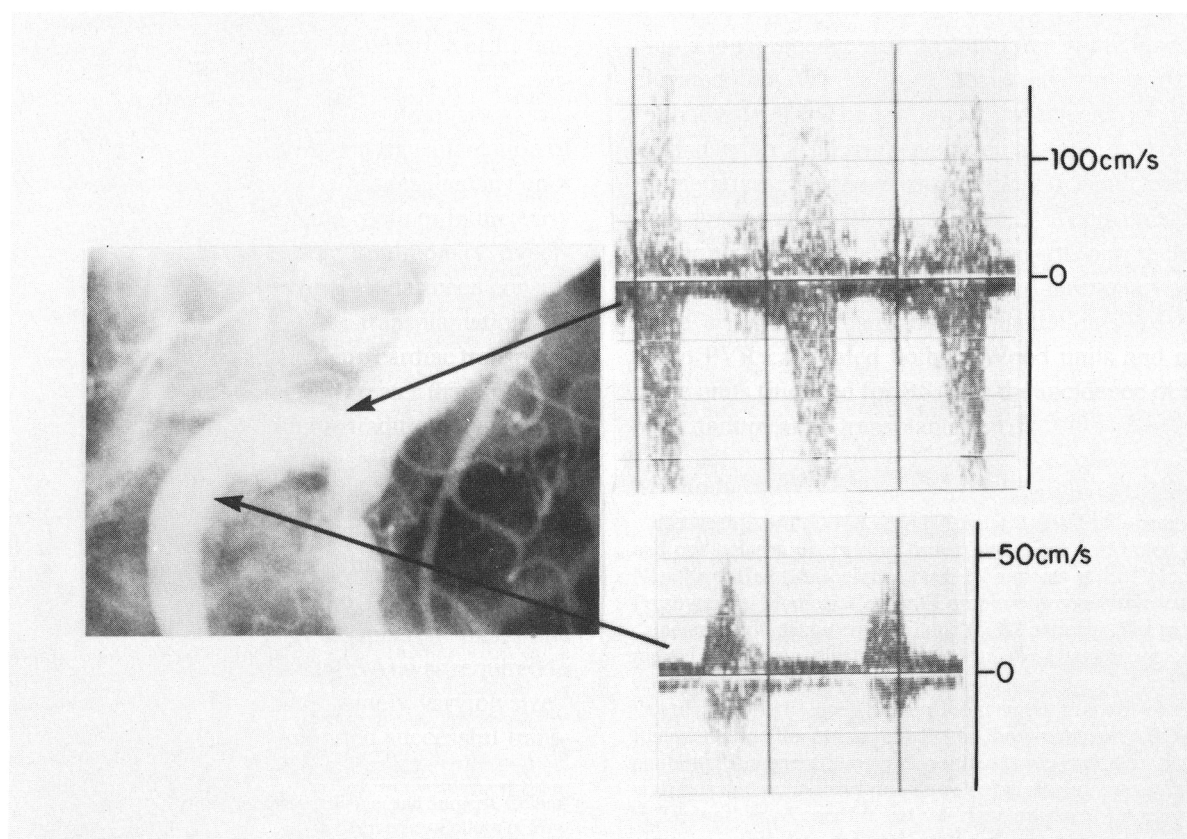
*Patient 3.* A 55-year old man underwent a successful percutaneous angioplasty of an iliac lesion. After 12 months symptoms of claudication returned. Follow-up duplex scanning revealed return of increased systolic velocity in the area of his angioplasty (figure 5). Return of the stenosis was confirmed and corrected by repeat angioplasty.

*Patient 4.* A 55-year old man complained of mild claudication 18 months after an aortobifemoral bypass graft. Symptoms alone were not severe enough to warrant surgery. Physical examination revealed excellent femoral pulses. Distal pulses and ankle blood pressures were diminished on the symptomatic side. Duplex scanning revealed a tight stenosis at the anastomosis to the common femoral artery on the affected side (figure 6). After angiography confirmed this finding, the lesion was repaired surgically to prevent thrombosis of the graft limb. In this case, duplex scanning correctly identified an operable stenosis. Had a mid-superficial femoral artery occlusion been identified by duplex scanning as the cause of his decreased ankle pressure, no further intervention would have been undertaken.

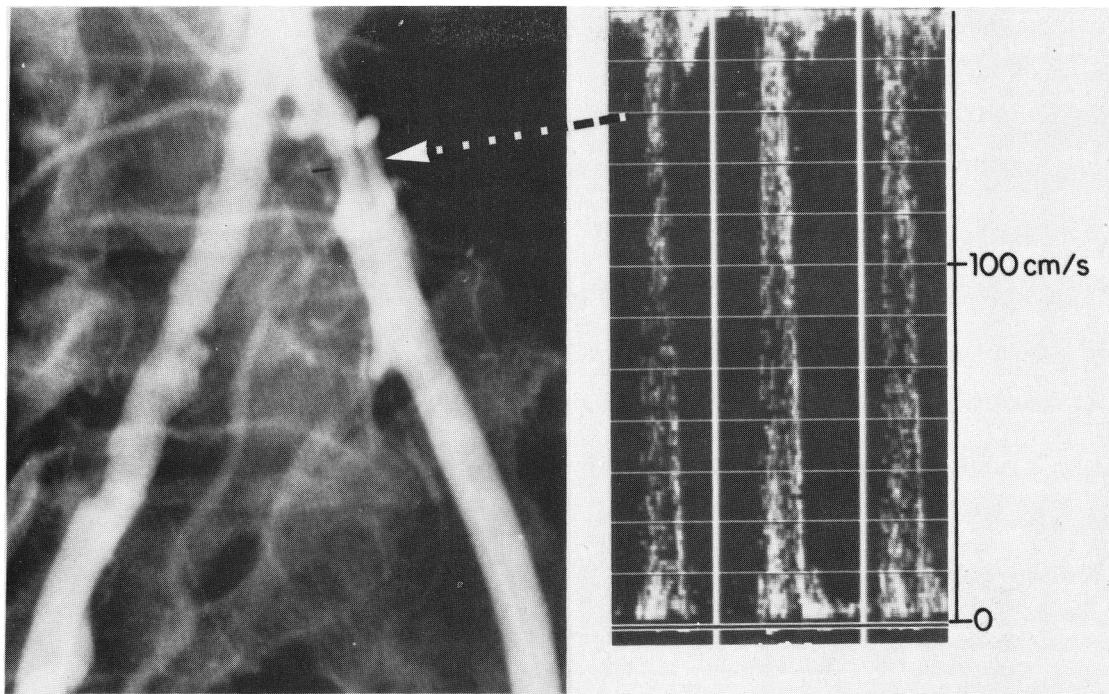




**FIGURE 3.** Duplex scan and subsequent angiogram from patient 1, demonstrating minimal flow in the bypass graft due to a tight stenosis near the distal anastomosis.



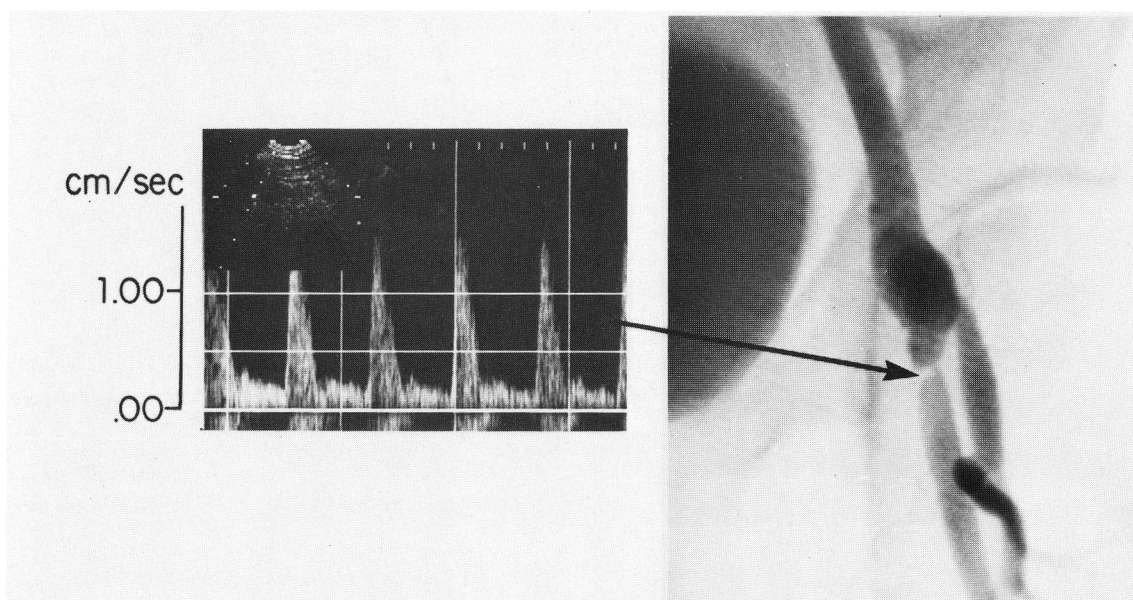
**FIGURE 4.** Duplex scan and subsequent angiogram from the iliac stenosis described in patient 2. Pressure measurements confirmed a significant stenosis that is not well seen on the angiogram. Velocity is increased at the site of stenosis and decreased beyond it.



**FIGURE 5.** Duplex scan and subsequent angiogram from patient 3, demonstrating restenosis after percutaneous transluminal angioplasty.

In conclusion, results of duplex scanning for diagnosis of peripheral arterial stenosis produce agreement with angiography that is as good as the agreement between two different radiologists interpreting the same angiograms. The ability of duplex scanning to distinguish high-grade stenosis from occlusion, to detect hemodynamically insignificant disease, and to localize

disease accurately is unique among noninvasive tests and represents the first practical means of documenting arterial disease progression. Patients can be selected for possible percutaneous transluminal angioplasty before angiography, and results of various interventions as well as natural disease progression can be precisely followed. Early detection and anatomic localization of



**FIGURE 6.** Duplex scan and subsequent angiogram from patient 4 demonstrating a tight stenosis at the left common femoral anastomosis.

disease progression or the development of stenoses after revascularization allows more timely and specific management of these problems.

## References

- Jager KA, Ricketts HJ, Strandness DE Jr: Duplex scanning for the evaluation of lower limb arterial disease. In Bernstein EF, editor: Noninvasive diagnostic techniques in vascular disease. St. Louis, 1985, The C. V. Mosby Co., p 619
- Jager KA, Phillips DJ, Martin RL, Hanson C, Roederer GO, Langlois YE, Ricketts HJ, Strandness DE Jr: Noninvasive mapping of lower limb arterial lesions. *Ultrasound Med Biol* **11**: 515, 1985
- Cohen J: A coefficient of agreement for nominal scales. *Educational and Psychological Measurement* **20**: 37, 1960
- Slot HB, Strijbosch L, Greep JM: Interobserver variability in single plane aortography. *Surgery* **90**: 497, 1981
- Thiele BL, Strandness DE Jr: Accuracy of angiographic quantification of peripheral atherosclerosis. *Prog Cardiovasc Dis* **26**: 223, 1983
- Johnston KW, Kassam M, Cobbold RSC: Relationship between Doppler pulsatility index and direct femoral pressure measurements in the diagnosis of aortoiliac occlusive disease. *Ultrasound Med Biol* **10**: 1, 1984
- Skidmore R, Woodcock JP: Physiological interpretation of Doppler-shift waveforms. II. Validation of the Laplace transform method for characterization of the common femoral blood-velocity/time waveform. *Ultrasound Med Biol* **6**: 219, 1980
- Thiele BK, Hutchinson KJ, Greene FM, Forster FK, Strandness DE Jr: Pulsed Doppler waveform patterns produced by smooth stenosis in the dog thoracic aorta. In Taylor DEM, Stevens AL, editors: Blood flow theory and practice. New York, 1983, Academic Press, Inc., pp 85
- Knox RA, Strandness DE Jr: Ultrasound technique for evaluation of lower extremity arterial occlusion. *Semin Ultrasound* **2**: 264, 1981
- Thiele BL, Bandyk DT, Zierler RE, Strandness DE Jr: A systematic approach to the assessment of aortoiliac disease. *Arch Surg* **118**: 477, 1983
- Barrie WE, Evans DH, Bell PRF: The relationship between ultrasonic pulsatility index and proximal arterial stenosis. *Br J Surg* **66**: 366, 1979
- Reddy DJ, Vincent GS, McPharlin M, Ernst CB: Limitations of the femoral artery pulsatility index with aortoiliac artery stenosis: an experimental study. *J Vasc Surgery* **4**: 327, 1986
- Baird RN, Bird DR, Clifford PC, Lusby RJ, Skidmore R, Woodcock JP: Upstream stenosis—its diagnosis by Doppler signals from the femoral artery. *Arch Surg* **115**: 1316, 1980
- Evans DH, Barrie WE, Asher MJ, Bell PR: The relationship between ultrasonic pulsatility index and proximal arterial stenosis in a canine model. *Circ Res* **46**: 470, 1980
- Ward AS, Martin TP: Some aspects of ultrasound in the diagnosis and assessment of aortoiliac disease. *Am J Surg* **140**: 260, 1980
- Blackshear SM, Phillips DJ, Thiele BL, Hirsh JH, Chikos PM, Marinelli MR, Ward KJ, Strandness DE Jr: Detection of carotid occlusive disease by ultrasonic imaging and pulsed Doppler spectrum analysis. *Surgery* **86**: 698, 1979
- Bodily KC, Zierler RE, Greene FM, Blackshear WM, Phillips DJ, Beach KW, Strandness DE Jr: Spectral analysis of Doppler velocity patterns in normals and patients with carotid artery stenosis. *Clin Physiol* **1**: 365, 1981
- Fell G, Phillips DJ, Chikos PM, Harley JD, Thiele BL, Strandness DE Jr: Ultrasonic scanning for disease of the carotid artery. *Circulation* **64**: 1191, 1981
- Langlois Y, Roederer GO, Chan A, Strandness DE Jr: The use of common carotid waveform analysis in the diagnosis of carotid occlusive disease. *Angiology* **34**: 679, 1983
- Langlois Y, Roederer GO, Chan A, Phillips DJ, Beach KW, Martin D, Chikos PM, Strandness DE: Evaluating carotid artery disease: the concordance between pulsed Doppler/spectrum analysis and angiography. *Ultrasound Med Biol* **9**: 51, 1983
- Phillips DJ, Greene FM, Langlois Y, Roederer GO, Strandness DE Jr: Flow velocity patterns in the carotid bifurcations of young, presumed normal subjects. *Ultrasound Med Biol* **9**: 39, 1983
- Roederer GO, Langlois YE, Chan AW, Primozich J, Lawrence RJ, Chikos PM, Strandness DE Jr: Ultrasonic duplex scanning of extracranial carotid arteries: improved accuracy using new features from the common carotid artery. *J Cardiovascular Ultrasonogr* **1**: 373, 1982
- Samson RH, Sprayregen S, Veith FJ, Gupta SK, Ascer E, Scher LA: Inadequacy of the noninvasive hemodynamic evaluation of percutaneous transluminal angioplasty. *Am J Surg* **147**: 212, 1984
- Gunn IG, Cowie TN, Forrest H, Guin RO, Sheldon C, Vallance R: Haemodynamic assessment following iliac artery dilatation. *Br J Surg* **68**: 858, 1981
- Bandyk DF, Cato RF, Towne JB: A low flow velocity predicts failure of femoropopliteal and femorotibial bypass grafts. *Surgery* **98**: 799, 1985