

Angiographic Features in the Infarct-Related Artery After Intracoronary Urokinase Followed by Prolonged Anticoagulation

Role of Ruptured Atheromatous Plaque and Adherent Thrombus in Acute Myocardial Infarction In Vivo

Susumu Nakagawa, MD, Yuhji Hanada, MD,
Yasushi Koiwaya, MD, and Kenjiro Tanaka, MD

To unravel sequential morphological features in infarct-related coronary arteries (IRCA), we performed coronary angiography (CAG) before, during, and immediately after intracoronary urokinase infusion in 43 consecutive patients. After 1 month of rigorous anticoagulation by intravenous heparin and subsequent oral warfarin or after the same period of treatment by antiplatelet agents, we repeated CAG in all patients except for one, who died 6 days after thrombolytic therapy. Thirty-two IRCAs were totally occluded, and 11 were severely occluded at baseline. With recanalization and/or reduction in luminal narrowing at the site of the occlusion by progressive removal of the overlying thrombus and plaque content, we recognized the development of extraluminal contrast pooling in an ellipsoid shape (type A), single or paired linear radiolucency(ies) with or without outpouching (type B), and definite outpouching (type C). The development of type A, B, and C lesions occurred in 4, 6, and 0 IRCAs immediately after thrombolytic therapy and in 0, 18, and 3 IRCAs 1 month later, respectively. Throughout the study, at least one of type A–C lesions developed in 23 of 43 (53.5%) IRCAs. Lesion development proceeded from total or severe occlusion to type A, then to type B or C, both accompanied by progressive reduction in luminal narrowing and frequent enlargement of outpouching. A postmortem study in one patient whose CAG immediately after thrombolytic therapy was interpreted as a type B lesion demonstrated a ruptured plaque with paired ridges. Serial observations in vivo indicate that many IRCAs are associated with a complex underlying spatial structure, probably composed of some part of ruptured atheromatous plaque with or without adherent thrombus. Recognition and identification of such complex structures beneath the accumulated thrombus are of great importance in both CAG interpretation and elucidation of the pathophysiological sequence of acute myocardial infarction in vivo and may enable prevention or more effective therapy of acute coronary events. (*Circulation* 1988;78:1335–1344)

In 1982, Levin and Fallon¹ compared the post-mortem coronary angiographic appearance with pathological characteristics and suggested that coronary angiography (CAG) could indicate the presence of complicated lesions associated with plaque rupture, plaque hemorrhage, superimposed partially occluding thrombus, or recanalized thrombus. Levin and Gardiner² later expanded the CAG findings suggestive of the presence of such compli-

cated lesions to include irregular borders, poorly defined or hazy borders, an outpouching within the narrowed segment that appeared to be ruptured plaque, intraluminal radiolucency(ies), and sharp leading or trailing edges that were either perpendicular to the coronary arterial wall or overhanging. Ambrose et al³ reviewed CAGs from patients with acute or recent myocardial infarction (AMI) or unstable angina and concluded that endoluminal narrow-necked or irregularly bordered negative images resulting in coronary narrowing (an eccentric stenosis with a narrow neck or irregular borders, which they termed “type II eccentric lesions”) were the most common morphological features in clinical settings and assumed that the lesions were likely representative of either ruptured atheroma-

From the First Department of Internal Medicine, Miyazaki Medical College, 5200 Kihara, Kiyotake, Miyazaki, 889-16, Japan.

Address for correspondence: Yasushi Koiwaya, MD, First Department of Internal Medicine, Miyazaki Medical College, 5200 Kihara, Kiyotake, Miyazaki, 889-16, Japan.

Received May 18, 1988; revision accepted August 9, 1988.

tous plaque or a partially occlusive or lysed thrombus or both. However, it appears that there are missing links between the CAG features described by both groups, and it is obvious that the role of such CAG features in the development of acute coronary events has not yet been described precisely.

In our own experience, with recanalization and/or reduction in luminal narrowing of the infarct-related coronary artery (IRCA) after thrombolytic therapy, not only endoluminal and intraluminal negative image(s) but also intraluminal linear radiolucency(ies) and outpouchings frequently developed. This development was highly specific to sites totally or severely occluded at baseline.

To observe the sequence of morphological changes in IRCAs during and after thrombolytic therapy and to unravel the clinical significance of accompanying features, we undertook serial CAG studies before, during, and immediately after therapy in 43 consecutive patients with AMI. The initial studies were followed after 1 month of prolonged rigorous anticoagulation, and CAG was performed again. With progressive removal of accumulated thrombus resulting in recanalization and/or reduction in luminal narrowing, we could observe sequential morphological changes in IRCAs in 35 patients. These observations may not only address the significance of some CAG features more clearly but also shed light on dynamic processes in the development of AMI in vivo.

Patients and Methods

Patients

Among 57 consecutive patients with AMI, 45 met the following criteria for intracoronary thrombolytic therapy: 1) AMI was evidenced by typical chest pain and electrocardiographic (ECG) changes (more than 2 mm ST segment elevation in more than two ECG leads) resistant to sublingual nitroglycerin and an increase in MB-creatinine phosphokinase; 2) age was less than 75 years old with an active daily life; 3) valvular disease was not associated; 4) neither percutaneous transluminal coronary angioplasty nor coronary bypass surgery had been performed; 5) there were no thrombolytic agent contraindications such as significant anemia, recent history of bleeding, recent surgery, recent cerebrovascular accidents, or renal insufficiency; 6) thrombolytic therapy was not refused; and 7) thrombolytic therapy could be started within 6 hours after onset of AMI.

After obtaining informed consent, diagnostic catheterization study was performed in 45 patients. Two patients were excluded from thrombolytic therapy because of less than 75% luminal occlusion in a large coronary branch in baseline or achievement of less than 50% luminal occlusion after 300 μ g i.c. nitroglycerin. Thus, 43 patients received thrombolytic therapy and follow-up CAG study 1 month later except for one patient, who expired 6 days

after thrombolytic therapy. Postmortem examination was performed on this patient.

Identification of Infarct-Related Coronary Artery

An IRCA was defined at the time of catheterization study as a major branch visually determined to be more than 90% occluded and whose perfusing area was compatible with the distribution of ST segment elevation on a 12-lead electrocardiogram and the asynergic area on two-dimensional echocardiography.

Intracoronary Infusion of Urokinase

Urokinase (240,000 IU) was continuously infused during four 10-minute periods at 10-minute intervals (total dose, 960,000 IU) into the ostium of the right or left coronary artery, depending on the location of the IRCA. When antegrade contrast flow was poor, an additional 240,000–480,000 IU urokinase was infused. No mechanical recanalization procedures such as guidewire penetration or percutaneous coronary angioplasty was used in any patient.

Coronary Angiography

All patients underwent emergency CAG at a film speed of 50 frames/sec with Judkins technique. Before the CAG study, 5,000–10,000 IU heparin was administered intravenously. To obtain the baseline lesion, contrast medium was injected into the vessel distant from the infarcted area. Subsequently, the IRCA was opacified in two or three diagnostic views, and an appropriate projection was selected to visualize the diseased portion in profile with minimum foreshortening and minimum overlapping of other vessels. The left anterior oblique and caudocranial projection was frequently used for the left anterior descending coronary artery. A single, and occasionally secondary, projection was used for subsequent visualization during and after urokinase therapy; CAGs were repeated every 10 minutes (i.e., after each administration of urokinase).

One month later (range, 25–52 days; mean \pm SD, 34.5 \pm 5.6 days), the 42 patients who survived the AMI underwent CAG study again. The morphology of the IRCA was interpreted by three independent observers who had no knowledge of either the patients' profiles or ECG changes. Special attention was focused not only on intraluminal morphology including luminal diameter and intraluminal radiolucency but also on the luminal outline to reconstruct the spatial structure of the IRCA. Based on interpretations where all observers agreed, morphology was classified as (Figure 1): 1) total occlusion. Coronary occlusion with no distal opacification by antegrade contrast flow; or 2) occlusion with or without type A–C lesions. Variable degree of luminal narrowing, occasionally caused by variable form of negative image(s) (radiolucencies) protruding into coronary lumen (endoluminal negative image[s]), in IRCA. The narrowing included those with or with-

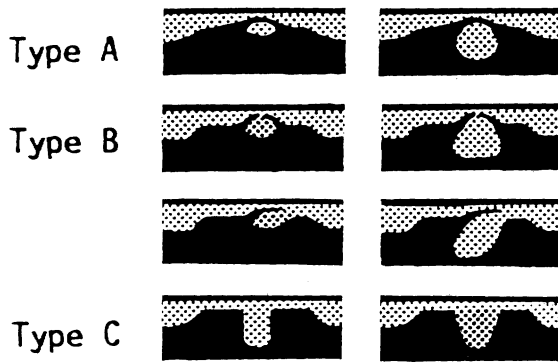


FIGURE 1. Schematic illustration of morphology developing after thrombolytic therapy in infarct-related coronary arteries. The lesions include an extraluminal contrast pooling (type A), single or paired thin linear radiolucency(ies) with or without outpouching (type B), and definite outpouching (type C).

out concentricity or symmetrization of the narrowing, haziness, or irregularity of luminal outline or definite outpouching. Four subgroups of occlusion were categorized: occlusion without type A–C lesions (luminal narrowing without type A–C lesions—type A–C lesions are defined below); occlusion with type A lesion (luminal narrowing with extraluminal ellipsoid-shaped contrast pooling adjacent to the diseased portion—the pooling was demarcated from the coronary lumen by a thin radiolucent line); occlusion with type B lesion (luminal narrowing with single or paired short, thin, linear radiolucency[ies]—the radiolucency[ies] was frequently associated with a variable degree of outpouching); occlusion with type C lesion (luminal narrowing with definite outpouching but without radiolucency).

Anticoagulation and Other Medication

After thrombolytic therapy, all patients in whom recanalization of the IRCA was established received a continuous infusion of heparin 400–800 IU/hr. Clotting time, determined every 6 hours, was kept at more than 30 minutes. Warfarinization was begun 3 days after therapy, and heparin was discontinued 5–7 days after the thrombotest level reached a therapeutic range of 15–25%. Warfarin was continued until repeated catheterization study was performed. When bleeding complication developed, anticoagulation was discontinued and ticlopidine or aspirin was administered after bleeding stopped. The patients in whom the IRCA was not recanalized despite urokinase infusion received ticlopidine or aspirin. In addition to the anticoagulant or antiplatelet agents, all patients received 120 mg diltiazem and 80 mg sustained isosorbide dinitrate.

Results

The present study included 43 IRCAs from 43 patients, comprising 38 men and five women with a mean age of 56.0 ± 7.3 years (range, 39–72 years).

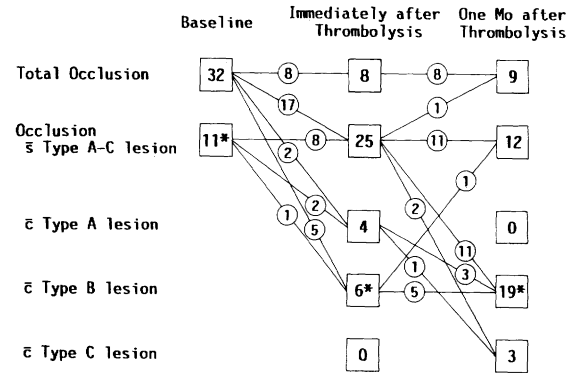


FIGURE 2. Diagram of patency and morphology in the infarct-related coronary arteries (IRCAs) in baseline and immediately and 1 month after thrombolytic therapy followed by prolonged rigorous anticoagulation. In totally or severely occluded IRCAs, variable morphology (occlusion with or without type A–C lesions) developed after thrombolytic therapy (indicated by the connecting lines). Numbers with asterisks include an IRCA from a patient who died 6 days after acute myocardial infarction.

Time between the development of AMI and thrombolytic therapy was 90–350 (242 ± 48) minutes.

Anticoagulation, Complications, and Clinical Course

Anticoagulation was discontinued in two patients because of hemorrhagic complication; in one from the site of catheter insertion and in another from the gastrointestinal tract (the former was administered ticlopidine and the latter aspirin). No other complications developed during the study, including in patients on antiplatelet agents.

Clinical course was uneventful in all patients except one, who died of progressive right ventricular failure 6 days after thrombolysis.

Patency of Infarct-Related Coronary Arteries Before and After Thrombolytic Therapy

In the baseline state, 32 IRCAs were totally occluded; eight out of the 32 were not reperfused despite intracoronary urokinase and remained totally occluded 1 month later (Figure 2). After urokinase infusion, 24 IRCAs were recanalized, three being accompanied by poor antegrade flow. One month later, 23 were patent with an increase in luminal diameter. The remaining IRCA, which had poor antegrade contrast flow immediately after thrombolytic therapy and in which anticoagulation was discontinued because of hemorrhagic complication, was totally occluded 1 month later.

Eleven IRCAs had more than 90% occlusion in baseline, including five with poor antegrade contrast flow. The severity of the narrowing was reduced in all IRCAs with disappearance of poor antegrade contrast flow immediately after urokinase infusion. The severity of the narrowing was further reduced 1 month later. In one IRCA, patency was confirmed by postmortem study.

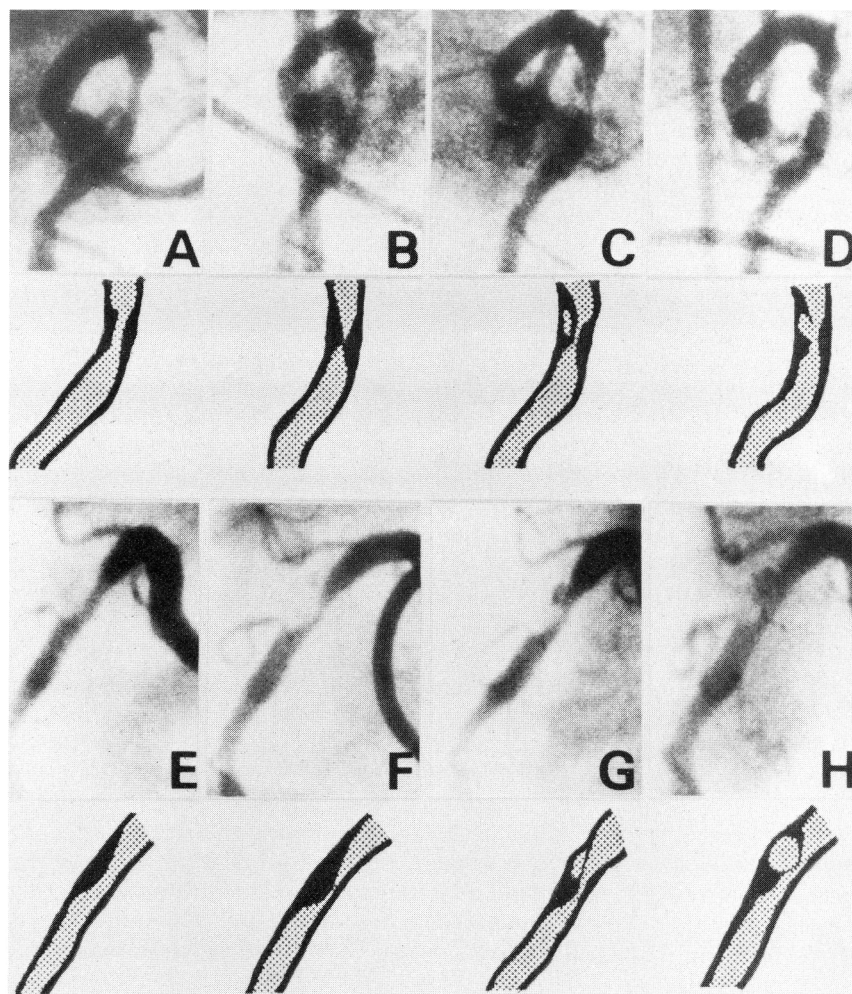


FIGURE 3. Right coronary angiograms and schematic illustrations from a 62-year-old man 62 days before (A and E) and 4 hours after inferior myocardial infarction (B and F) and immediately (C and G) and 1 month after thrombolytic therapy (D and H). A–D were through right anterior oblique projection and E–H were through left anterior oblique projection. Before thrombolytic therapy, an eccentric lesion with marginal haziness produced severe occlusion in the proximal portion of the right coronary artery (B and F), which had been mildly stenotic 62 days before (A and E). After therapy, the luminal narrowing was lessened along with appearance of extraluminal elliptical contrast pooling adjacent to the diseased portion; a linear radiolucency was visualized between the narrowed site and the pooling (C and G). One month later, the narrowing was further reduced, the pooling became larger and rounder with irregular outline, and linear radiolucency was interrupted, producing an outpouching (D and H).

Morphology of Infarct-Related Coronary Arteries Before, During, and After Thrombolytic Therapy

In the totally occluded 32 IRCAs before thrombolytic therapy, the distal end of the contrast was scalloped in 23 IRCAs and irregular in nine. After intracoronary urokinase, the recanalization achieved in 24 IRCAs was frequently preceded by lengthening of the patent tract and penetration of contrast medium into the distal portion, but recanalization was independent of the form of the distal end.

With recanalization and/or reduction in luminal narrowing and smoothing of the contours, type A–C lesions, which had not been observed before urokinase, developed at the point that was totally or severely occluded in baseline (Figures 2–4, 6, and 7). Type A lesion developed in four IRCAs, type B in six, and type C in 0 immediately after urokinase therapy. The demonstration of type A–C lesions was usually on only a few frames in one cardiac cycle in a selected projection, probably when the structures were shown in profile. Especially, most of the thin linear radiolucency(ies) were visualized on only two to four frames.

A postmortem study of the IRCA in the deceased patient, whose lesion had been interpreted as type

B lesion immediately after thrombolytic therapy, revealed a recently ruptured atheromatous plaque with paired ridges containing a small amount of thrombus.

One month after the therapy and after rigorous anticoagulation, type A lesion was demonstrated in 0 IRCAs, type B in 19 (postmortem study confirmed the presence of one IRCA), and type C in three (Figures 2–7). In many type B and C lesions, the sum of the depth in the outpouching and residual luminal diameter was larger than the diameter proximal and/or distal to the diseased portion (Figures 3–5).

In one totally occluded IRCA in baseline state, type B lesion with outpouching developed immediately after thrombolytic therapy, but both linear radiolucency and outpouching disappeared 1 month later along with no reduction in luminal narrowing, whereas anticoagulation was discontinued because of bleeding complication. Thus, type A–C lesions were demonstrated in a total of 23 of 43 (53.5%) IRCAs.

In the severely occlusive 11 IRCAs in baseline, the presence of endoluminal negative images with a narrow neck or irregular outline (type II eccentric lesion by Ambrose et al³) were observed in three

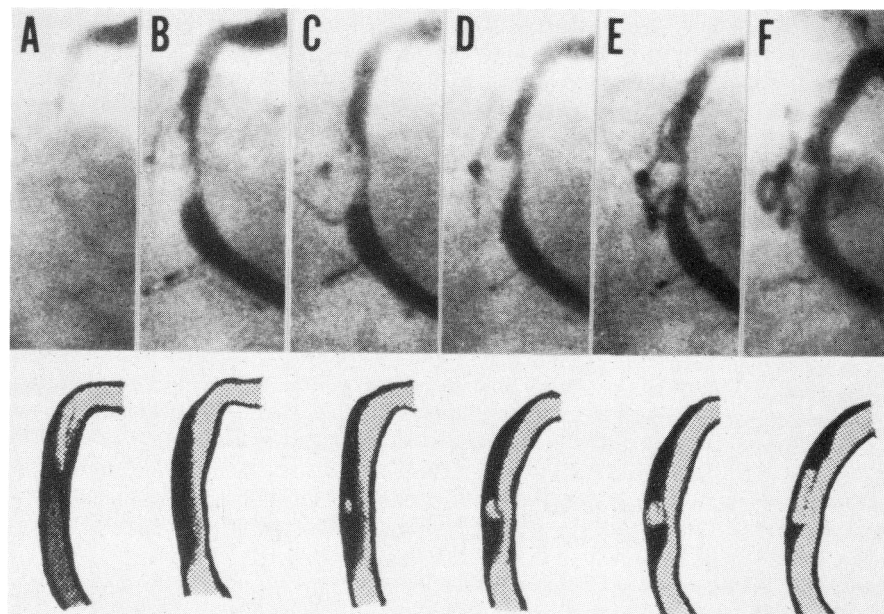


FIGURE 4. Right coronary angiograms and schematic illustrations from a 69-year-old man 3 hours after inferior myocardial infarction (A) and during (B–D), immediately after (E), and 1 month after thrombolytic therapy (F). Before urokinase infusion, the right coronary artery was subtotally occluded in the proximal portion with markedly faint antegrade flow. The narrowing was reduced along with repeated infusion of urokinase. The sequence of reduction in residual narrowing and morphology was as follows: development of haziness or irregularity on the luminal outline (B), appearance of extraluminal contrast pooling with disappearance of the irregularity on the luminal outline (C), enlargement of the extraluminal contrast pooling with communication with coronary lumen and further reduction in luminal narrowing (D), and then further enlargement of outpouching (E). One month later, the outpouching increased in width and was multilobulated (F). A linear radiolucency was shown between the outpouching and coronary lumen in D–F.

IRCA. With recanalization and/or reduction in luminal narrowing, such endoluminal negative images newly developed in only six IRCA. All the negative images disappeared 1 month later.

Sequential Change in the Morphology of Infarct-Related Coronary Arteries

Sequential observations of IRCA revealed the following sequence of morphological change (Figures 2–7): 1) in baseline, all IRCA were totally or severely occluded, whereas type A–C lesions were never observed; 2) the lesion appeared to develop from type A into types B and C along with a reduction in narrowing after thrombolytic therapy; and 3) the outpouching frequently enlarged.

A typical sequence in the morphological change is shown in Figure 3. Two months before AMI, insignificant segmental narrowing was shown in the proximal right coronary artery. The lesion was severely occluded with marginal haziness immediately after development of AMI. After urokinase infusion, extraluminal contrast pooling developed adjacent to the narrowed portion (type A lesion), becoming larger after therapy. One month later, type B lesion was revealed with a further decrease in narrow-

ing. In one IRCA, the outpouching became extremely wide and was multilobulated 1 month later (Figure 4).

Discussion

We observed a dynamic process in the morphology of IRCA after intracoronary urokinase infusion followed by prolonged rigorous anticoagulation. Primary occlusion in the present series was probably mainly attributable to adherent thrombus because many IRCA were associated with sequential morphological change such as total occlusion with a scalloped or irregular distal end, persistent staining with contrast medium, lengthening of the patent tract, and progressive patency of the IRCA frequently showing endoluminal negative images.⁴

Extraluminal Pooling, Single or Paired Linear Radiolucency(ies), and Outpouching (Type A–C Lesions)

Along with progressive removal of intracoronary thrombus, a distinctive morphology developed. The morphology was classified into four categories, including progressively mild narrowing of the occluded site with or without type A–C lesions. Because the present study provided only indirect

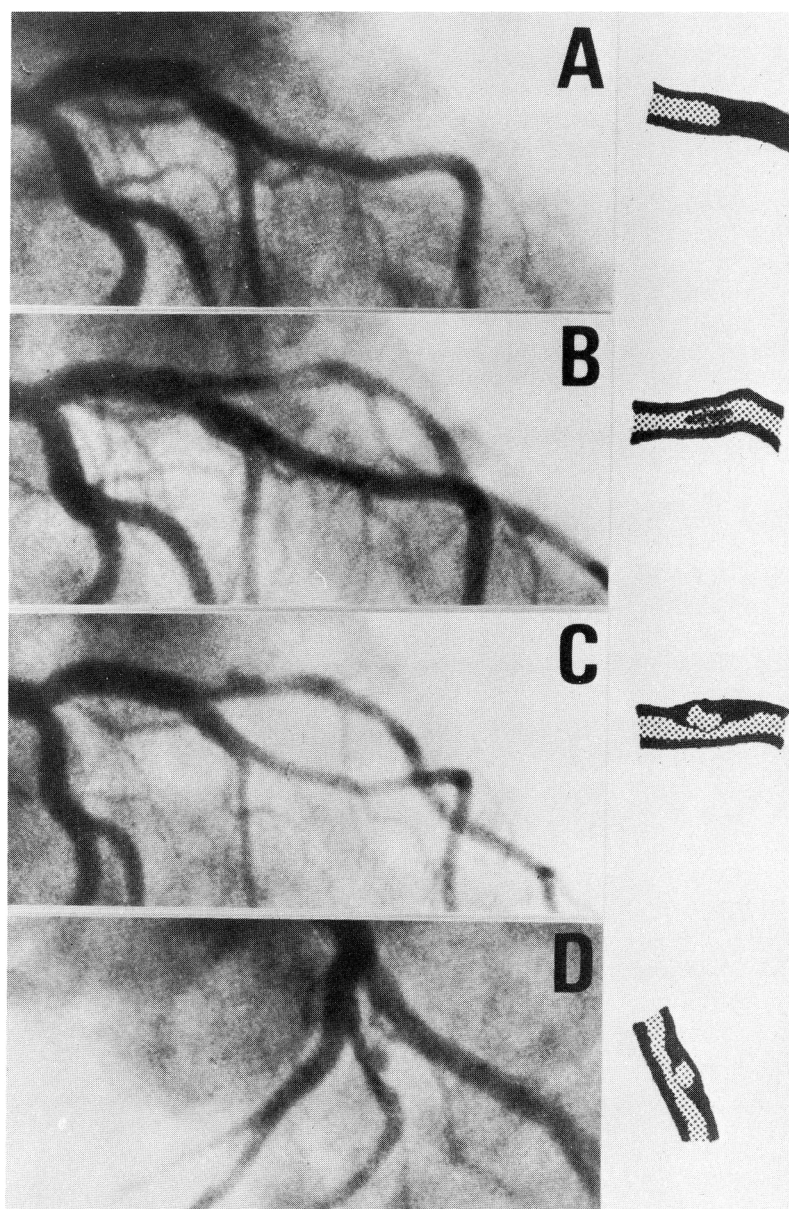


FIGURE 5. Left coronary angiograms and schematic illustrations from a 50-year-old man with acute anterior myocardial infarction. A–C were through right anterior oblique projection, and D was through left anterior oblique and caudocranial projection. The totally occluded first diagonal branch (A) was recanalized after thrombolysis, leaving a round intraluminal filling defect probably resulting from a mural thrombus (B). One month later, intraluminal elliptical contrast pooling developed in the diseased portion (C). The outline of the pooling was irregular. The presence of paired radiolucent lines with outpouching was demonstrated through left anterior oblique and caudocranial projection (D).

evidence regarding spatial structure in the IRCA except for one IRCA with histological confirmation, we cannot state exactly what was represented by type A–C lesions. Some of them could have indicated organization or incomplete lysing of a previously occluding thrombus. However, it can be argued that type A–C lesions probably indicated some part of ruptured atheromatous plaque with or without adhering thrombus. This conclusion is based on the following observations: 1) the lesions developed at the same point that had been totally or severely occluded in baseline state during and after thrombolytic therapy and prolonged anticoagulation; 2) all extraluminal contrast pooling (type A lesion) developed into outpouching with or without intraluminal radiolucency(ies) (type B and C lesions), becoming larger with time; 3) many outpouchings in type B and C lesions were exter-

nally more prominent than the proximal and distal lumen that did not appear narrowed (Figures 3–5); 4) no mechanical manipulation was used during and after the procedure; 5) the postmortem study in one patient revealed the presence of ruptured atheromatous plaque with ridges, whereas the IRCA had been interpreted as type B lesion on CAG; and 6) the morphology of type A–C lesions is compatible with that found in previous postmortem studies of patients who died of MI.^{1,5–10}

Original structural details in IRCAs with possible local outpouching, prominent irregularities, or other features could not be determined in the present study. Recent studies have included some such features in “complicated lesions”^{1,11,12} and have stated that such lesions are occasionally associated with ruptured atheromatous plaque. However, it is difficult to interpret such morphology correctly, and

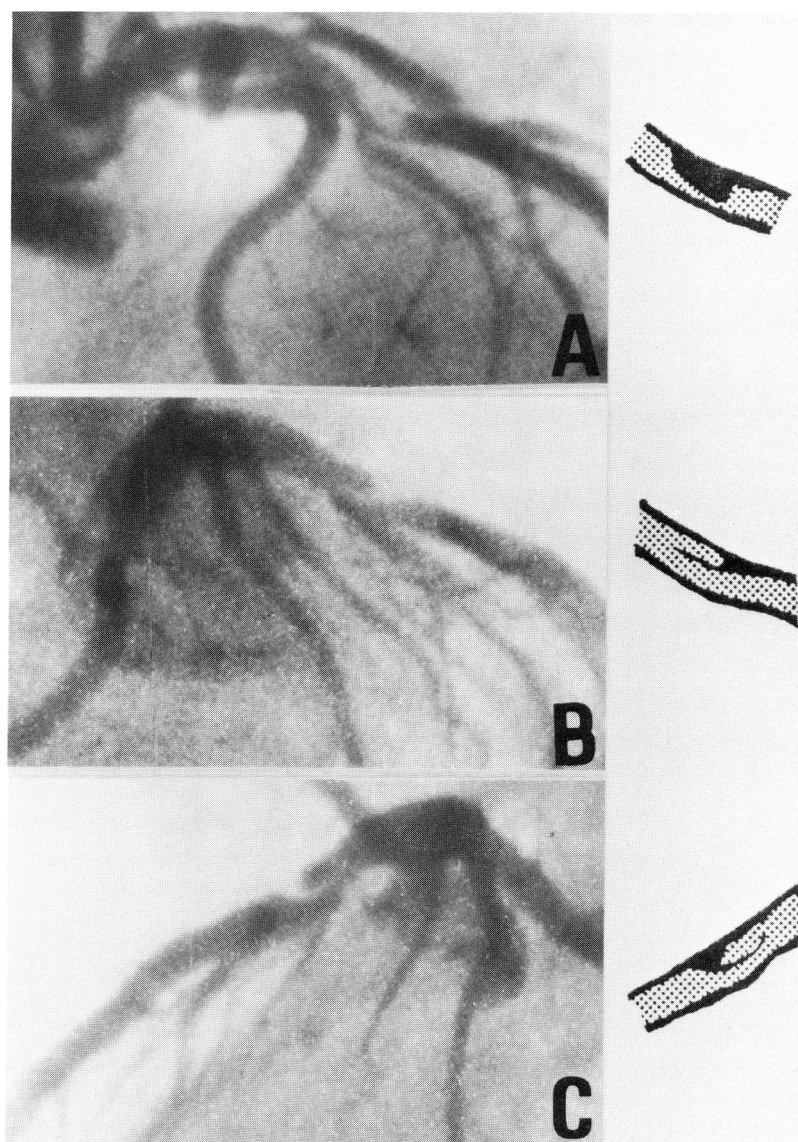


FIGURE 6. Left coronary angiograms and schematic illustrations from a 67-year-old man with acute anteroseptal myocardial infarction immediately (A) and 42 days after thrombolytic therapy (B and C). A and B were through right anterior oblique projection, and C was through left anterior oblique projection. In baseline, an endoluminal negative image with an overhanging edge inducing poor antegrade flow to distal portion (an eccentric subtotal occlusion with poor antegrade contrast flow) was demonstrated on the left anterior descending coronary artery. The grade of luminal narrowing was not reduced despite 960,000 IU intracoronary urokinase, but poor antegrade contrast flow disappeared (A). After 42 days, the luminal narrowing was lessened with appearance of linear radiolucency along the luminal outline observed immediately after thrombolytic therapy (B and C).

it appears that such features are less specific for the presence of ruptured plaque.

Neither the presence and development of endoluminal narrow-necked negative images nor irregular border before and after thrombolytic therapy was as frequent in the present series as in the study by Ambrose et al.³ This may have resulted from differences in the inclusion criteria for the study and in patient groups. They analyzed the CAGs within 12 hours after occurrence of AMI.

Prevalence of Ruptured Atheromatous Plaque in Infarct-Related Coronary Arteries

Serial CAG studies demonstrated type A–C lesions in a total of 23 of 43, IRCAs with the prevalence of ruptured atheromatous plaque estimated to be 53.5%. However, this is probably underestimated because some IRCAs without A–C lesions might have been associated with ruptured atheromatous plaque. Some type A–C lesions large enough to be demonstrated

on the CAGs might have been interpreted incorrectly because of a suboptimal projection angle. A very small or thin anatomic structure may have been beyond the resolving power of the CAG equipment. Incomplete removal of adherent thrombus and/or plaque contents or reaccumulation of thrombus may have masked underlying structural details. In one patient, a single linear radiolucency associated with an outpouching demonstrated immediately after thrombolysis was not seen 1 month later, probably due to thrombus accumulation (Figure 2). Some IRCAs not recanalized, or with possible local outpouching or irregular outline after thrombolytic therapy, could have been associated with underlying ruptured atheromatous plaque.^{1,2} Thus, the prevalence of ruptured atheromatous plaque should be at least as high as the figure reported herein.

Possible causes of the frequent demonstration of type A–C lesions in the present study may have included administration of urokinase as the thrombo-

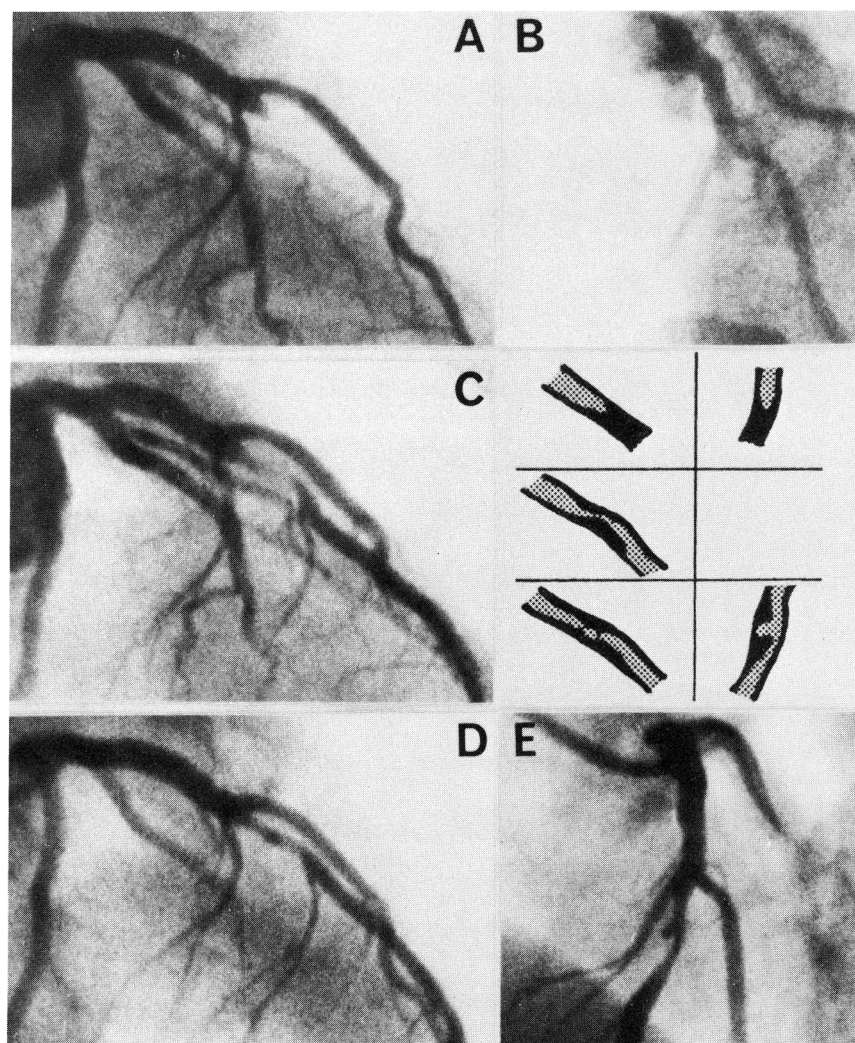


FIGURE 7. Left coronary angiograms and schematic illustrations from a 50-year-old man 4 hours after anteroapical myocardial infarction (A and B) and immediately (C) and 1 month after thrombolytic therapy (D and E). A, C, and D were through right anterior oblique projection, and B and E were through left anterior oblique and caudocranial projection. The totally occluded left anterior descending coronary artery (A and B) was recanalized after thrombolysis, leaving a significant residual narrowing with marginal haziness probably resulting from a mural thrombus (C). One month later, the residual narrowing was lessened, accompanied by elliptical contrast pooling in the diseased portion (D). A definite outpouching was observed in left anterior oblique and caudocranial projection (E).

lytic agent; repeated performance of CAGs, sometimes with two or more multiple projections; administration of calcium-antagonist and nitrates; and prolonged rigorous anticoagulation after thrombolytic therapy. Calcium-antagonist and nitrates might have prevented coronary artery constriction or spasm,¹³⁻¹⁶ resulting in a lowered stasis of coronary blood flow, which prevented further thrombus accumulation. Prolonged anticoagulation may have resulted in substantial lysis of adherent thrombus.^{17,18}

Role of Ruptured Atheromatous Plaque and Adherent Thrombus in Acute Myocardial Infarction

Although the precise pathophysiological sequence of AMI is not yet understood, histological studies have suggested that the primary mechanism of AMI is the rupture of atheromatous plaque followed by thrombus accumulation.⁵⁻¹⁰ But these studies are greatly limited by selection bias and postmortem events, and the results may apply only to those who died. Obviously, histological studies fail to reveal the dynamic nature of ruptured plaque and throm-

bus accumulation. Our observations in unselected consecutive patients in vivo demonstrate dynamic events, make up for certain limitations of histological examinations, and indicate that ruptured atheromatous plaque and adherent thrombus play just as important a role in patients who survive as in those who die.

Initiating mechanisms for the rupture of atheromatous plaque are not provided by the present study but may include 1) hemorrhage into the atheromatous plaque or an increase in lipid content that may culminate in rupture,⁵⁻¹⁰ 2) compression and distortion of the content of the plaque by mechanical, rheologic, hemodynamic, and vasomotor stress that may cause rupture,¹⁹ or 3) coronary artery constriction or spasm that may induce rupture.

Limitations in the Present Study

A major limitation in the present study is the fact that it is not conclusive what type A-C lesions really represent except in one IRCA with histological confirmation. We were also unable to accurately substantiate the prevalence of ruptured atheromatous plaque,

although our study revealed that ruptured atheromatous plaque was found in more than half of the patients. A definitive conclusion regarding prevalence would require the observation of a larger number of patients; however, the real prevalence may be higher than what could be obtained from any study because the angiographical approach has a limited resolution. The morphology that developed after thrombolytic therapy was analyzed mainly on the presence of thin linear radiolucency and the depth of outpouching. Radiolucency may frequently have been missed, and the depth of the outpouching may have sometimes been underestimated. Angiographically demonstrated outpouching may not have been the whole size or real shape of the ruptured plaque but only some part because some of the thrombus and plaque contents may have been left after thrombolytic therapy (Figure 4). Older thrombi, if present, undergo organization indistinguishable from ruptured plaque, even by means of histological examination.⁵⁻¹⁰ Thus, the morphology and numbers shown in Figure 2 may not accurately reflect the real morphology or actual number of cases.

Implications

The present study provides considerable information regarding the pathophysiology of acute coronary events and CAG interpretation in clinical practice. We were able to show that some plaque contents were not solid in vivo because the plaque contents disappeared or permitted contrast medium to penetrate. We revealed some sequence in the development of AMI in vivo: the provision of the in vivo sequence may emphasize possible effectiveness of thrombolytic therapy to salvage jeopardized myocardium. We also demonstrated that prolonged rigorous anticoagulation after thrombolytic therapy may have been responsible for further reduction in residual narrowing. A recent study²⁰ suggested that survival in some patients who underwent thrombolytic therapy may be improved by applying revascularization procedures. Prolonged rigorous anticoagulation after thrombolytic therapy may permit one to avoid applying revascularization procedures.

The results of our study may enable more precise interpretation of CAGs. It may be possible that some so-called "aneurysms on an atherosclerotic basis"²¹ and coronary arterial dissection could represent ruptured atheromatous plaque with or without adherent thrombus. Some coronary aneurysms and dissections complicated with coronary angioplasty²²⁻²⁴ could also be induced by the rupture of an atheromatous plaque. Rapid progression and so-called "regression" in coronary lesions could result from an accumulation or substantial lysis of adherent thrombus.

Type A-C lesions may be predictive features of future development of coronary events. Among the CAG findings suggestive of the presence of complicated coronary lesions,^{1,11,12} only luminal irregularity, at present, is proven to be predictive of MI.²⁵

Additional observations may make it possible to predict future coronary events more accurately.

On applying emergency coronary angioplasty, especially to an IRCA immediately after thrombolytic therapy, the guide wire may easily go into the plaque cavity. Ischinger et al²⁴ showed that coronary angioplasty for complicated lesions entails increased risk. With the recognition that narrowed portions in an IRCA are frequently associated with atheromatous plaque and adherent thrombus, careful guide wire manipulation may diminish the incidence of mechanically induced complications.

Acknowledgments

We are grateful to Drs. Toshifumi Taguchi, Takeshi Matsuo, Ippei Ikushima, Toshihide Unoki, Haruhito Kumagae, Yoshitatsu Nagatomo, Akihiko Matsuyama, Makoto Takenaga, Tadashi Ishikawa, Takuroh Imamura, Yasuhide Sohta, Nobuaki Ohtsuka, and Hiroyuki Kondoh and the personnel of the catheterization laboratory for performing thrombolytic therapy. They gave unstinting aid in this particularly difficult study at all hours of the day and night. We are also particularly grateful to the coronary care unit staff for their diligent patient care; to Drs. Akinobu Sumiyoshi and Tadashi Kohno for histological examination and invaluable suggestions; to Ms. Shizuko Nagatomo for secretarial assistance; and to Dr. Robert Adams for reading this manuscript.

References

1. Levin DC, Fallon JT: Significance of the angiographic morphology of localized coronary arterial stenosis: Histopathologic correlations. *Circulation* 1982;66:316-320
2. Levin DC, Gardiner GA Jr: Complex and simple coronary artery stenoses: A new way to interpret coronary angiograms based on morphologic features of lesions. *Radiology* 1987;164:675-680
3. Ambrose JA, Winters SL, Arora RR, Haft JJ, Goldstein J, Rentrop KP, Gorlin R, Fuster V: Coronary angiographic morphology in myocardial infarction: A link between the pathogenesis of unstable angina and myocardial infarction. *J Am Coll Cardiol* 1985;6:1223-1238
4. Terrosu P, Ibba VG, Contini GM, Franceschino V: Angiographic features of the coronary arteries during intracoronary thrombolysis. *Br Heart J* 1984;52:154-163
5. Roberts WC, Buja LM: The frequency and significance of coronary arterial thrombi and other observations in fatal acute myocardial infarction; a study of 107 necropsy patients. *Am J Med* 1972;52:425-443
6. Horie T, Sekiguchi M, Hirosawa K: Coronary thrombosis in pathogenesis of acute myocardial infarction: Histological study of coronary arteries in 108 autopsied cases using serial section. *Br Heart J* 1978;40:153-161
7. Silver MD, Baroldi G, Mariani F: The relationship between acute occlusive coronary thrombi and myocardial infarction studied in 100 consecutive patients. *Circulation* 1980; 61:219-227
8. Falk E: Plaque rupture with severe pre-existing stenosis precipitating coronary thrombosis: Characteristics of coronary atherosclerotic plaques underlying fatal occlusive thrombi. *Br Heart J* 1983;50:127-134
9. Falk E: Unstable angina with fatal outcome: Dynamic coronary thrombus leading to infarction and/or sudden death. *Circulation* 1985;71:699-708

10. Davies MJ, Thomas AC: Plaque fissuring—the cause of acute myocardial infarction, sudden ischaemic death, and crescendo angina. *Br Heart J* 1985;53:363–373
11. Wilson RF, Holida MD, White CW: Quantitative angiographic morphology of coronary stenosis leading to myocardial infarction or unstable angina. *Circulation* 1986;73:286–296
12. Brown BG, Gallery CA, Badger RS, Kennedy JW, Mathey D, Bolson EL, Dodge HT: Incomplete lysis of thrombus in the moderate underlying atherosclerotic lesion during intracoronary infusion of streptokinase for acute myocardial infarction: Quantitative angiographic observations. *Circulation* 1986;76:653–661
13. Koiwaya Y, Torii S, Takeshita A, Nakagaki O, Nakamura M: Postinfarction angina caused by coronary arterial spasm. *Circulation* 1982;65:275–280
14. Nakamura M, Koiwaya Y: Effect of diltiazem on recurrent spontaneous angina following acute myocardial infarction. *Circ Res* 1983;52(suppl 1):I-158–I-161
15. Koiwaya Y, Ishikawa T, Nakagawa S, Ochiai H, Tanaka K: Coronary artery spasm immediately after successful percutaneous transluminal coronary recanalization. *Arch Intern Med* 1985;145:943–945
16. Hackett D, Davies G, Chierchia S, Maseri A: Intermittent coronary occlusion in acute myocardial infarction; value of combined thrombolytic and vasodilator therapy. *N Engl J Med* 1987;317:1055–1059
17. Douglas JS Jr, Lutz JF, Clements SD, Robinson PH, Roubin GS, Lembo NJ, King SB III: Therapy of large intracoronary thrombi in candidates for percutaneous transluminal coronary angioplasty (abstract). *J Am Coll Cardiol* 1988;11(suppl A):238A
18. Gotoh K, Minamino T, Katoh O, Hamano Y, Fukui S, Hori M, Kusuoka H, Mishima M, Inoue M, Kamada T: The role of intracoronary thrombus in unstable angina: Angiographic assessment and thrombolytic therapy during ongoing anginal attacks. *Circulation* 1988;77:526–534
19. Feldman RL: Coronary thrombosis, coronary spasm and coronary atherosclerosis and speculation on the link between unstable and acute myocardial infarction. *Am J Cardiol* 1987;59:1187–1190
20. Kennedy JW, Martin GV, Davis KB, Maynard C, Stadius M, Sheehan FH, Ritchie JL: The Western Washington intravenous streptokinase in acute myocardial infarction randomized trial. *Circulation* 1988;77:345–352
21. Vlodaver Z, Amplatz K, Burchell HB, Edwards JE: Pathology of coronary artery disease, in *Coronary Heart Disease: Clinical, Angiographic, and Pathological Profiles*. New York, Springer-Verlag Co, 1976, pp 231–282
22. Hill JA, Margolis JR, Feldman R, Conti CR, Pepine C: Coronary arterial aneurysm formation after balloon angioplasty. *Am J Cardiol* 1983;52:261–264
23. Weston MW, Bowerman RE: Coronary artery aneurysm formation following PTCA. *Cath Cardiovasc Diag* 1987;13:181–185
24. Ischinger T, Gruentzig AR, Meier B, Galan K: Coronary dissection and total coronary occlusion associated with percutaneous transluminal angioplasty: Significance of initial angiographic morphology of coronary stenosis. *Circulation* 1986;74:1371–1378
25. Ellis SG, Cain K, Fisher L, Bourassa MG, Alderman EL: LAD lesion morphology as a predictor of anterior infarction in CASS (abstract). *J Am Coll Cardiol* 1986;7(suppl A):216A

KEY WORDS • thrombolytic therapy • acute coronary events • coronary atherosclerosis • percutaneous transluminal coronary recanalization