

Evidence of Endothelial Dysfunction in Angiographically Normal Coronary Arteries of Patients With Coronary Artery Disease

Steven W. Werns, MD, Joseph A. Walton, MD, Henry H. Hsia, MD,
Elizabeth G. Nabel, MD, Mark L. Sanz, MD, and Bertram Pitt, MD

Acetylcholine causes endothelium-dependent dilation of normal arteries in most animal species. The effect of acetylcholine on normal human coronary arteries is controversial. Pathologic studies and epicardial echocardiography have shown that diffuse atherosclerosis is often present despite angiographic evidence of discrete coronary artery disease (CAD). Therefore, we postulated that acetylcholine would cause vasoconstriction of coronary arteries that are angiographically normal in patients with CAD. Coronary artery diameter, measured by automated quantification of digitized cineangiograms, was determined before and after the intracoronary infusion of 0.2 mM acetylcholine at 0.8–1.6 ml/min. The diameter of stenotic or irregular segments of six atherosclerotic coronary arteries decreased from 1.80 ± 0.42 mm before acetylcholine to 1.26 ± 0.46 mm after acetylcholine ($p=0.0025$). Acetylcholine had a significantly different effect on the diameter of two groups of coronary arteries that are angiographically normal. Acetylcholine caused a 0.16 ± 0.09 -mm increase in the diameter of 14 normal coronary arteries in patients without CAD, whereas it caused a 0.26 ± 0.12 -mm decrease in the diameter of 14 normal coronary arteries in patients with CAD ($p<0.01$). Thus, the normal response to intracoronary acetylcholine is vasodilation, suggesting that endothelium-derived relaxing factor is released from normal human coronary endothelium. The vasoconstrictive effect of acetylcholine in the angiographically normal coronary arteries of patients with CAD suggests the presence of a diffuse abnormality of endothelial function. (*Circulation* 1989;79:287–291)

There is growing evidence that acetylcholine and a number of other substances induce vasodilation by stimulating the release of an endothelium-derived relaxing factor (EDRF) from endothelial cells, whereas nitroglycerin and other endothelium-independent vasodilators induce vasodilation through the direct stimulation of vascular smooth muscle.^{1,2,3} Thus, acetylcholine or aggregating platelets cause relaxation of arteries with an intact endothelium but cause contraction of arteries denuded of endothelium.^{1,2,3} An impairment of endothelium-dependent vasodilation has been observed in rabbits⁴ and monkeys^{5,6} that were fed an atherogenic diet. Dietary treatment of experimental atherosclerosis in monkeys produced morphologic regression of

atherosclerosis and restored endothelium-dependent relaxation to normal.⁶

Conflicting data exist, however, regarding the existence of endothelium-mediated vasodilation in human coronary arteries. Several in vitro studies conclude that acetylcholine and carbachol, both muscarinic agonists, constrict human coronary arteries,^{7–10} whereas other studies suggest that acetylcholine dilates normal human coronary arteries.¹¹ Similarly, a discrepancy exists regarding the effect of acetylcholine on human coronary arteries in vivo. After the intracoronary infusion of acetylcholine, Horio et al¹² observed at least a 25% decrease in the diameter of normal or almost normal coronary arteries in 27 of 70 arteries, whereas Ludmer et al¹³ reported an 11% increase in the diameter of normal coronary arteries.

Pathologic studies¹⁴ and studies with epicardial echocardiography¹⁵ have shown that diffuse atherosclerosis is often present in all three major coronary arteries in patients whose coronary angiograms show atherosclerosis in only one or two coronary arteries. Thus, the coronary arteries that appear angiograph-

From the Department of Internal Medicine, Division of Cardiology, University of Michigan Medical School, Ann Arbor, Michigan.

Address for correspondence: Steven W. Werns, MD, Cardiology Division, University Hospital, B1-F245, Box 0022, 1500 East Medical Center Drive, Ann Arbor, MI 48109.

Received May 10, 1988; revision accepted October 11, 1988.

ically normal in patients with one- or two-vessel coronary artery disease (CAD) often have inapparent early atherosclerosis and may respond abnormally to an endothelium-dependent vasodilator. Therefore, this study was performed to determine whether or not an endothelium-dependent vasodilator, acetylcholine, causes constriction of angiographically normal coronary arteries in patients with CAD.

Methods

Definitions

An angiographically normal coronary artery was defined as a vessel with neither a discrete stenosis nor intimal irregularities. An abnormal coronary artery was defined as a vessel with either minimal intimal irregularities or a discrete stenosis. Patients with one or more abnormal vessels were classified as patients with CAD.

Patients

The study protocol was approved by the University of Michigan Human Subject Review Committee, Ann Arbor, Michigan, and informed consent was obtained from each patient. Patients with a history of coronary artery spasm or ergonovine-induced coronary artery spasm were excluded.

The study population consisted of 24 patients referred for cardiac catheterization. There were eight patients without CAD. The group consisted of two women and six men ranging in age from 25 to 56 years. The indications for coronary angiography were atypical chest pain in all eight. Four had exercise tolerance tests that were normal, one had an exercise thallium test that showed redistribution suggestive of inferoseptal ischemia, and three did not have exercise tests. There were 16 patients with CAD. The group consisted of 10 men and six women ranging in age from 36 to 77 years. The indications for coronary angiography were chest pain in 14 patients, a recent myocardial infarction in one patient, and ventricular arrhythmias in one patient.

Protocol

After completion of the diagnostic cardiac catheterization, a 5F bipolar pacing catheter was positioned in the right ventricular apex and set in the demand mode at approximately 10 beats/min less than the baseline rate. Single-plane coronary cineangiograms were obtained at baseline and after drug injection at 30 frames/sec with standard Judkins catheters. Ionic contrast material was injected at a rate of 5 ml/sec to a total of 8 ml with a Medrad power injector (Cordis, Miami, Florida).

After the baseline coronary angiogram, a 0.2 mM solution of acetylcholine was infused at 0.8–1.6 ml/min for approximately 3 minutes into the coronary ostium through the Judkins catheter. After obtaining the angiogram after acetylcholine injection, a 250 μ g bolus of nitroglycerin was injected into the coronary ostium, and a repeat coronary angiogram was obtained.

Quantitative Coronary Angiography

Coronary artery diameter was measured with a previously described coronary quantification program that has been validated in studies of intracoronary plastic cylinders in dogs¹⁶ and coronary stenoses in humans.¹⁷ Analysis of intraobserver variability for the measurement of stenosis diameter in the canine coronary artery showed high reproducibility ($r=0.92$, SEE=0.23 mm).¹⁶ Similarly, analysis of interobserver variability for stenosis diameter in the human coronary artery showed high reproducibility ($r=0.97$, SEE=0.19 mm).¹⁷

Briefly, the end-diastolic frames of the cineangiograms were projected on a Vanguard viewer that is optically coupled to a video camera. The video signal was digitized onto an ADAC Laboratories (Milpitas, California) digital angiographic computer. The operator chooses a circular region of the digitized angiogram for analysis by positioning a light-pen cursor over the artery and then by adjusting the size of the circular region to encompass the desired segment of the artery to be analyzed. The software uses the catheter as a scaling device to determine absolute diameter.

The arteries were analyzed by a technician who was unaware of the identity of the patient and of the study's hypothesis and design. The proximal, or occasionally middle, portions of the coronary arteries were analyzed with bends and branch points serving as landmarks to reproducibly measure the same segment after each infusion. Coronary arteries that were inadequately opacified and segments that were overlapped by other structures were not analyzed.

Statistical Analysis

A paired t test was used for within-group comparisons of baseline and postinfusion absolute coronary artery diameter, heart rate, and blood pressure. An unpaired t test was used for intergroup comparisons of the drug-induced changes in absolute coronary artery diameter and relative coronary artery diameter (expressed as a percentage of pre-drug diameter). All data are expressed as mean \pm SEM. Differences are considered significant for a p value less than 0.05.

Results

Responses of Coronary Arteries

Stenotic or irregular segments of six abnormal coronary arteries were analyzed: four left anterior descending arteries, one left circumflex, and one right coronary artery. The mean diameter was 1.80 ± 0.42 mm before acetylcholine and 1.26 ± 0.46 mm after acetylcholine ($p=0.0025$) (Figure 1) infusion. The mean relative diameter after acetylcholine and nitroglycerin injection, expressed as a fraction of baseline, was 0.62 and 1.12, respectively. Smooth segments of eight abnormal coronary arteries were analyzed. The mean diameter was 3.13 ± 0.25 mm before acetylcholine, 2.98 ± 0.28 mm after acetylcho-

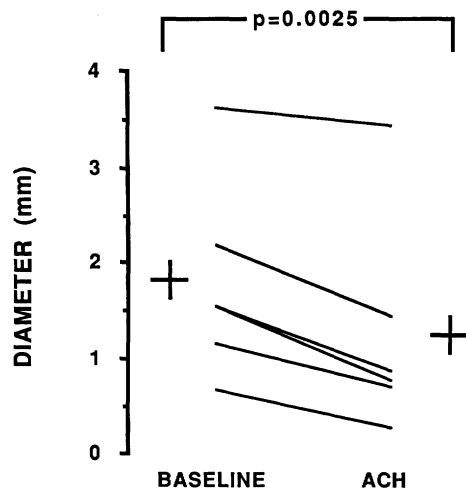


FIGURE 1. Graph of absolute diameter of six stenotic or irregular coronary arteries. Mean diameter was 1.80 ± 0.42 mm before acetylcholine and 1.26 ± 0.46 mm after acetylcholine ($p=0.0025$).

line ($p=0.094$), and 3.61 ± 0.38 mm after nitroglycerin ($p=0.064$) injection.

Twenty-eight angiographically normal coronary arteries were studied, 14 from the eight patients without CAD, and 14 from 12 patients with one- or two-vessel CAD. The vessels in the group without CAD consisted of eight left anterior descending arteries, five left circumflex arteries, and one right coronary artery. The vessels in the group with CAD were seven left anterior descending arteries and seven left circumflex arteries. The mean baseline coronary artery diameter was 2.93 ± 0.15 mm for the patients without CAD and 2.98 ± 0.25 mm for the patients with CAD ($p=0.87$). Acetylcholine had a significantly different effect on the diameter of the two groups of angiographically normal coronary arteries (Figure 2). Acetylcholine caused a 0.16-mm increase in coronary artery diameter in the patients without CAD, whereas it caused a 0.26-mm decrease in diameter in the patients with CAD ($p<0.01$). Relative diameter, expressed as fraction of baseline, was 1.06 after acetylcholine and 1.21 after nitroglycerin injection in the patients without CAD. The relative diameter of the angiographically normal coronary arteries in the patients with CAD was 0.91 after acetylcholine ($p=0.006$ vs. no CAD) and 1.09 after nitroglycerin ($p=0.06$ vs. no CAD) injection.

Hemodynamic Measurements

Only two right coronary arteries were studied because acetylcholine impairs atrioventricular nodal conduction. Thus, there were no significant changes in the heart rate or mean arterial pressure during the infusion of acetylcholine. Among the patients without CAD, the heart rate was 70 ± 4 beats/min before acetylcholine and 68 ± 4 beats/min after acetylcholine infusion ($p=0.16$). The mean arterial pressure was 92 ± 6 mm Hg before acetylcholine and 89 ± 5 after

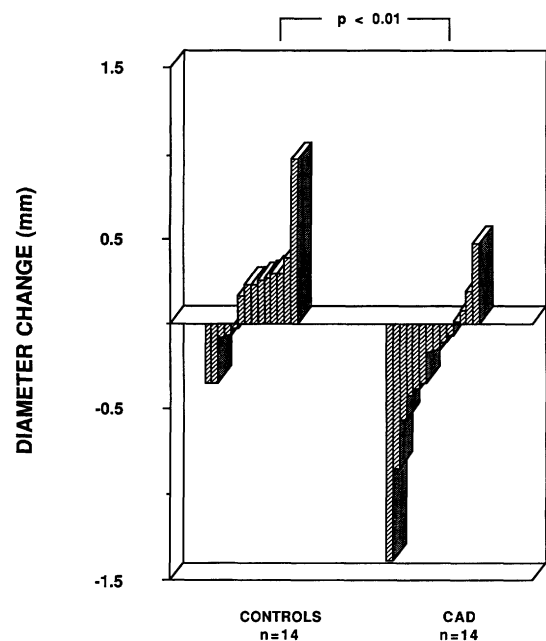


FIGURE 2. Bar graph of change in the diameter of 28 angiographically normal coronary arteries, 14 from eight patients without coronary artery disease (CONTROLS) and 14 from 12 patients with coronary artery disease (CAD). Mean change in coronary artery diameter after intracoronary acetylcholine was 0.16 ± 0.09 mm for the patients without coronary artery disease and -0.26 ± 0.12 mm for the patients with coronary artery disease ($p<0.01$).

acetylcholine infusion ($p=0.44$). Among the patients with CAD, the heart rate and mean arterial pressure were 70 ± 3 beats/min and 93 ± 3 mm Hg before acetylcholine, and 72 ± 2 beats/min ($p=0.24$) and 96 ± 3 mm Hg ($p=0.27$) after acetylcholine infusion. The mean heart rate and arterial pressure of each group were not significantly different before or after acetylcholine infusion.

Discussion

The results of this study suggest that acetylcholine, an endothelium-dependent vasodilator, dilates the coronary arteries of patients without evidence of atherosclerotic CAD, whereas angiographically normal coronary arteries in patients with angiographic evidence of CAD constrict in response to acetylcholine. Two recent studies demonstrated that acetylcholine dilates normal human coronary arteries¹¹ and internal mammary arteries¹⁸ in vitro. Regarding previous studies, several possible explanations exist for their conclusions that acetylcholine does not induce endothelium-dependent vasodilation in human coronary arteries.^{7-10,12} One explanation is the erroneous classification of coronary arteries as normal, which is due to the failure of coronary angiography to detect atherosclerosis that is diffuse rather than discrete.^{14,15} The results of previous studies may also be explained by the definitions of "normal" and "vasodilation" that

were applied. Ginsberg et al,⁷ for example, classified the coronary arteries of four hearts as "normal" despite histologic evidence of atherosclerosis similar in severity to that of transplanted hearts removed because of CAD. The study by Horio et al,¹² which reported that intracoronary acetylcholine caused vasoconstriction in 27 of 70 arteries, did not differentiate patients who had stenoses less than 25% from those without detectable coronary artery stenosis. One recent study of intracoronary acetylcholine defined vasodilation as an increase in diameter that was 25% or greater of baseline diameter,¹⁹ a difference that exceeds the mean increases in diameter observed in the normal patients in the present study after injecting acetylcholine or nitroglycerin.

The EDRF-stimulating effect of acetylcholine is counteracted by a direct contractile action on the smooth muscle.¹ Therefore, the observed response to acetylcholine may depend also on the peak concentration of acetylcholine. After infusion into the left coronary artery at 1 ml/min for 2 minutes, a 0.1-mM solution of acetylcholine caused coronary dilation, whereas a 1.0-mM solution caused constriction in six patients without CAD.²⁰ The present study used a 0.2-mM solution of acetylcholine infused at 0.8–1.6 ml/min, which is similar to that used by Ludmer et al.¹³ Thus, the vasoconstriction observed by Horio et al¹² may be due to their use of bolus injections that may have achieved a high concentration of acetylcholine, a conclusion that is consistent with the pronounced bradycardia induced by bolus injection^{12,19} but not constant infusions.¹³

An additional explanation for acetylcholine-induced vasoconstriction in vessels without angiographically detected CAD is unsuspected variant angina. Several studies have demonstrated that intracoronary acetylcholine provokes coronary artery spasm in patients with either normal or abnormal coronary arteries and variant angina.^{19,21,22} The present study excluded patients with a clinical history that suggested coronary artery spasm or ergonovine-induced coronary artery spasm.

Previously, coronary vasoconstriction due to muscarinic stimulation by methacholine was attributed to a reflex activation of the sympathetic nervous system secondary to system hypotension.²³ Although an intracoronary bolus injection of acetylcholine caused bradycardia and hypotension in previous investigations,^{12,21} the infusion of acetylcholine into the left coronary artery had no significant effect on the patients' heart rate or blood pressure in this study or in that reported by Ludmer et al.¹³ The latter study also demonstrated that coronary vasoconstriction during subselective infusion of acetylcholine into the left anterior descending coronary artery was not accompanied by diameter changes of the left circumflex coronary artery, indicating a direct effect of acetylcholine on the arterial wall.¹³

Expressed as a fraction of the baseline diameter, the mean diameter after acetylcholine was 0.91 for the angiographically normal coronary arteries in

patients with CAD, 0.94 for the smooth segments of abnormal arteries, and 0.62 for the stenotic or irregular segments of abnormal coronary arteries. Thus, angiographically abnormal segments demonstrated greater vasoconstriction. Brown et al²⁴ have proposed that vasoactive stimuli cause greater constriction of stenotic compared with nonstenotic segments because the geometric dimensions of certain stenoses may amplify the effect of circumferential smooth muscle shortening on the lumen. According to their hypothesis, 10% outer circumferential shortening of the compliant portion of an eccentric 49% stenosis would increase the percent diameter reduction to 76%, whereas 10% circumferential shortening of the entire circumference of a nonstenotic segment would result in only a 17% diameter reduction.²⁴ Other possible explanations for the greater vasoconstriction of stenotic segments are a more pronounced impairment of EDRF release, an increased sensitivity of the smooth muscle to acetylcholine's direct vasoconstrictive effect that opposes the endothelium-dependent vasodilation, and the release of endothelium-derived contracting factors.² Atherosclerotic human coronary arteries have displayed reduced relaxation by substance P, another endothelium-dependent vasodilator, rather than contraction.^{9,10} Thus, the vasoconstriction induced by acetylcholine may signify that the amount of EDRF released is inadequate to counteract acetylcholine's direct effect on the muscarinic receptors of the vascular smooth muscle.

Although it is uncertain whether or not the release of EDRF plays an important role in the regulation of coronary artery tone in humans, experimental studies indicate that an impaired ability to release EDRF may facilitate platelet aggregation and coronary vasoconstriction. Aggregating human platelets have relaxed intact canine coronary artery rings primarily because of the release of adenine nucleotides, whereas rings without endothelium have contracted.²⁵ The EDRF released by rabbit aortic endothelium has inhibited the aggregation of human platelets.²⁶ Thus, coronary arteries may be prone to vasospasm at sites of atherosclerotic endothelium because of a diminished inhibition of platelet aggregation and a failure to relax in response to endothelium-dependent vasodilators that are released by platelets.

Although coronary angiography often indicates that atherosclerosis is segmental and may be limited to only one or two vessels, histologic and echocardiographic examination of coronary arteries have shown that CAD is usually diffuse, with few segments that are free of atherosclerosis.^{14,15} Thus, an abnormal response to vasoactive stimuli may precede the angiographic recognition of CAD. The induction of vasoconstriction by an endothelium-dependent vasodilator such as acetylcholine may provide a useful tool in detecting early endothelial dysfunction and early atherosclerosis. The coronary arteries of cardiac transplant patients, for

example, have constricted in response to acetylcholine despite the absence of angiographic evidence of CAD.²⁷ Although considerable effort is being applied to halt the progression or induce regression of angiographically visible coronary atherosclerosis, it can be postulated that a more effective strategy may be to prevent the development of extensive cell damage and calcification in arteries with early atherosclerosis. The presence of acetylcholine-induced vasoconstriction of angiographically normal coronary arteries, as demonstrated in the present study, provides an important tool to test this hypothesis.

Acknowledgments

We thank Ray Worden and Darrell Debowey for their technical assistance and Vanessa Sims for secretarial assistance.

References

1. Furchgott RF: Role of endothelium in responses of vascular smooth muscle. *Circ Res* 1983;53:558–573
2. Vanhoutte PM: The endothelium—Modulator of vascular smooth-muscle tone. *N Engl J Med* 1988;319:512–513
3. Bassenge E, Busse R: Endothelial modulation of coronary tone. *Prog Cardiovasc Dis* 1988;30:349–380
4. Verbeuren TJ, Jordaens FH, Zonnekeyn LL, Van Hove CE, Coene MC, Herman AG: Effect of hypercholesterolemia on vascular reactivity in the rabbit. *Circ Res* 1986;58:552–564
5. Freiman PC, Mitchell GG, Heistad DD, Armstrong ML, Harrison DG: Atherosclerosis impairs endothelium-dependent vascular relaxation to acetylcholine and thrombin in primates. *Circ Res* 1986;58:783–789
6. Harrison DG, Armstrong ML, Freiman PC, Heistad DD: Restoration of endothelium-dependent relaxation by dietary treatment of atherosclerosis. *J Clin Invest* 1987;80:1808–1811
7. Ginsburg R, Bristow MR, Davis K, Dibiase A, Billingham ME: Quantitative pharmacologic responses of normal and atherosclerotic isolated human epicardial coronary arteries. *Circulation* 1984;69:430–440
8. Kalsner S: Coronary artery reactivity in human vessels: Some questions and some answers. *Fed Proc* 1985;44:321–325
9. Forstermann U, Mugge A, Frolich JC: Endothelium-dependent relaxation of human epicardial coronary arteries: Frequent lack of effect of acetylcholine. *Eur J Pharmacol* 1986;128:277–281
10. Forstermann U, Mugge A, Alheid U, Haverich A, Frolich JC: Selective attenuation of endothelium-mediated vasodilation in atherosclerotic human coronary arteries. *Circ Res* 1988;62:185–190
11. Bossaller C, Habib GB, Yamamoto H, Williams C, Wells S, Henry PD: Impaired muscarinic endothelium-dependent relaxation and cyclic guanosine 5'-monophosphate formation in atherosclerotic human coronary artery and rabbit aorta. *J Clin Invest* 1987;79:170–174
12. Horio Y, Yasue H, Rokutanda M, Nakamura N, Ogawa H, Takaoka K, Matsuyama K, Kimura T: Effects of intracoronary injection of acetylcholine on coronary arterial diameter. *Am J Cardiol* 1986;57:984–989
13. Ludmer PL, Selwyn AP, Shook TL, Wayne RR, Mudge GH, Alexander RW, Ganz P: Paradoxical vasoconstriction induced by acetylcholine in atherosclerotic coronary arteries. *N Engl J Med* 1986;315:1046–1051
14. Arnett EN, Isner JM, Redwood DR, Kent KM, Baker WP, Ackerman H, Roberts WC: Coronary artery narrowing in coronary heart disease: Comparison of cineangiographic and necropsy findings. *Ann Intern Med* 1979;91:350–356
15. McPherson DD, Hiratzka LF, Lamberth WC, Brandt B, Hunt M, Kieso RA, Marcus ML, Kerber R: Delineation of the extent of coronary atherosclerosis by high-frequency epicardial echocardiography. *N Engl J Med* 1987;316:304–309
16. Mancini GBJ, Simon SB, McGillem MJ, LeFree MT, Freidman HZ, Vogel RA: Automated quantitative coronary arteriography: Morphologic and physiologic validation in vivo of a rapid digital angiographic method. *Circulation* 1987;75:452–460
17. Sanz ML, Mancini GBJ, LeFree MT, Mickelson JK, Starling MR, Vogel RA, Topol EJ: Variability of quantitative digital subtraction coronary angiography before and after percutaneous transluminal coronary angioplasty. *Am J Cardiol* 1987;60:55–60
18. Luscher TF, Diederich D, Siebenmann R, Lehmann K, Stulz P, von Segesser L, Yang Z, Turina M, Gradel E, Weber E, Buhler FR: Difference between endothelium-dependent relaxation in arterial and in venous coronary bypass grafts. *N Engl J Med* 1988;319:462–467
19. Miwa K, Goto M, Lee JD, Matsuyama F, Shimizu H, Kato T, Hara A, Nakamura T: Supersensitivity of coronary arteries in variant angina to spasm induced by intracoronary acetylcholine. *Am J Cardiol* 1988;61:77–82
20. Newman CM, Hackett DR, Fryer M, El-Tamimi HM, Davies GJ, Maseri A: Dual effects of acetylcholine on angiographically normal human coronary arteries in vivo (abstract). *Circulation* 1987;76(suppl IV):IV-238
21. Yasue H, Horio Y, Nakamura N, Fujii H, Imoto N, Sonoda R, Kugiyama K, Obata K, Morikami Y, Kimura T: Induction of coronary artery spasm by acetylcholine in patients with variant angina: Possible role of the parasympathetic nervous system in the pathogenesis of coronary artery spasm. *Circulation* 1986;74:955–963
22. Okumura K, Yasue H, Horio Y, Takaoka K, Matsuyama K, Kugiyama K, Fujii H, Morikami Y: Multivessel coronary spasm in patients with variant angina: A study with intracoronary injection of acetylcholine. *Circulation* 1988;77:535–542
23. Stang JM, Kolibash AJ, Schorling JB, Bush CA: Methacholine provocation of Prinzmetal's variant angina pectoris: A revised perspective. *Clin Cardiol* 1982;5:393–402
24. Brown BG, Bolson EL, Dodge HT: Dynamic mechanisms in human coronary stenosis. *Circulation* 1984;70:917–922
25. Houston DS, Shepherd JT, Vanhoutte PM: Aggregating human platelets cause direct contraction and endothelium-dependent relaxation of isolated canine coronary arteries. *J Clin Invest* 1986;78:539–544
26. Furlong B, Henderson AH, Lewis MJ, Smith JA: Endothelium-derived relaxing factor inhibits in vitro platelet aggregation. *Br J Pharmacol* 1987;90:687–692
27. Fish RD, Nabel EG, Selwyn AP, Ludmer PL, Mudge GH, Kirshenbaum JM, Schoen FJ, Alexander RW, Ganz P: Responses of coronary arteries of cardiac transplant patients to acetylcholine. *J Clin Invest* 1988;81:21–31

KEY WORDS • acetylcholine • endothelium-derived relaxing factor • vasodilation • vasoconstriction • coronary artery disease