

Evolving Concepts in the Management of Congenital Junctional Ectopic Tachycardia

A Multicenter Study

Elizabeth Villain, MD, Victoria L. Vetter, MD, Jose Marin Garcia, MD, John Herre, MD,
Alberta Cifarelli, MD, and Arthur Garson Jr., MD

We reviewed the records of 26 infants with congenital junctional ectopic tachycardia (JET) from seven institutions to examine the evolution in the management of this tachycardia that is difficult to treat. JET was defined electrocardiographically as an incessant tachycardia with normal QRS morphology and atrioventricular (AV) dissociation. The ventricular rate ranged from 140 to 370 beats/min (mean, 230 beats/min); 16 of 26 patients had cardiac failure. Treatment success was defined as a stable decrease in the rate of JET, below 150 beats/min; partial success was a significant decrease of JET rate with alleviation of symptoms. All patients received digoxin with no significant effect. Propranolol was given to 16 patients, with two successes and one partial success. Combinations of other conventional agents were used in 11 patients with two successes; 14 patients were treated with amiodarone, which resulted in eight successes and three partial successes; three patients died suddenly on medical treatment (amiodarone, one patient; propranolol, one patient; or amiodarone plus propranolol, one patient); sudden AV block was a possible cause and consequently, two later patients had pacemaker implantation as well as medical treatment. His catheter ablation was successfully performed twice but contributed to death in a newborn; three surgical His ablations were performed for intractable JET with two successes and one death. The overall mortality was 35%. Among survivors, treatment has been stopped without any complications in five patients ranging in age from 10 months to 8 years (mean, 3.5 years). It seems that amiodarone alone is the best drug for treatment of congenital JET; necessity for permanent pacing remains unsettled. His ablation should be reserved only for intractable JET. (*Circulation* 1990;81:1544–1549)

Junctional ectopic tachycardia (JET) is thought to be "congenital" when it is first noted in a patient younger than 6 months of age. Mortality of infants with JET has been high.^{1–12} In the last few years, concepts have evolved in the management of JET; after failure of different conventional agents, more aggressive strategies involving destruction of the His bundle have been attempted as well as medical treatment with amiodarone.

Because no single center has a large number of patients, we performed a multicenter study reviewing the records of 26 patients to compare the efficacy of

different treatments and, therefore, to suggest the best current management for this resistant and life-threatening tachycardia.

Methods

This report is a cooperative study, dealing with 26 infants who were admitted to various institutions for congenital JET in 1970–1987. Patients were mainly referred to Houston (patients 1 through 11) and Paris (patients 18 through 26); the numbers and referral centers of the patients are listed in Table 1.

See p 1713

Ten of the 26 patients have been the subjects of previous individual reports.^{2,3,7,12}

After history and physical examination, each patient had a standard 15-lead electrocardiogram (ECG) and chest radiograph, and 16 were evaluated with M-mode and two-dimensional echocardiogram.

In all patients, the diagnosis of JET was made by ECG, and JET was defined as a tachycardia with a

From The Lillie Frank Abercrombie Section of Cardiology, Department of Pediatrics, Baylor College of Medicine, and Texas Children's Hospital, Houston, Texas.

Supported in part by grants HL-24916, HL-07190 and RR-00188 from the National Institutes of Health, Bethesda, Maryland, and a grant from the J.S. Abercrombie Foundation.

Address for reprints: Arthur Garson Jr., MD, Pediatric Cardiology, Texas Children's Hospital, 6621 Fannin, Houston, TX 77030.

Received April 11, 1989; revision accepted January 17, 1990.

TABLE 1. Patients With Junctional Ectopic Tachycardia

Patient	Center	Reference	Drug treatment			His ablation	Follow-up
			Unsuccessful	Successful			
				Complete	Partial		
1	H	7	C, D, Ph	P			Lost
2	H	7	D	P			Death, sudden
3	H		D	Ph			Lost
4	H		D	P			Sinus
5	H		D, P			Surg	Death, surgery
6	H	12	D, P		A		Death, sudden
7	H	7	D, P	C			Lost
8	H		D, P, Ph, Q			Surg	PM
9	H	12	D, P		A	Cath	PM
10	H	12	D		P	Cath	PM
11	H		D			Cath/Surg	Death, surgery
12	Ch		A, D, Pr				Death, PM
13	Ch		D, Pr	A			PM/Meds
14	M		A, D, P, Pr, Q				Death, JET
15	N		D, P, Ph, Pr				Sinus
16	S		D, F, P, Q				Death, Bx
17	R		A, D, F, P			Surg	PM
18	Pa		D		A		Meds
19	Pa		D	A			Meds
20	Pa		A				Death, JET
21	Pa		D	A			Sinus
22	Pa	3	D, P	A			Sinus
23	Pa	3	D	A			Sinus
24	Pa	3	D	A			Sinus
25	Pa		D		A		Meds
26	Pa	2, 3	Aj, D, Ds, P, V				Death, JET

H, Texas Children's Hospital, Houston; C, chlorpromazine; D, digoxin; Ph, phenytoin; P, propranolol; Lost, lost to follow-up; Sinus, alive, sinus rhythm; Death, surgery, death related to surgery; A, amiodarone; Q, quinidine; PM, pacemaker; Cath, catheter ablation; Cath/Surg, ablation of both catheterization and surgery; Ch, Children's Hospital of Philadelphia; Pr, procainamide; Death, PM, death during pacemaker implantation; PM/Meds, pacemaker and medication; M, Medical College of Virginia; Death, JET, death from congestive heart failure because of JET; N, Medical College of New Jersey; S, University of California, San Francisco; F, flecainide; Death, Bx, death associated with myocardial biopsy; R, Ospedale Bambino Gesù, Rome; Pa, Hospital Necker-Enfants Malades, Paris; Aj, ajmaline; Ds, disopyramide; V, verapamil.

normal QRS morphology and atrioventricular dissociation (AVD).

Eight patients underwent an electrophysiological study, including recordings of basic rhythm, rapid pacing, and programmed stimulation of the right atrium and ventricle. The diagnosis of JET was established by intracardiac recordings, showing a His bundle electrogram preceding each ventricular depolarization with a normal H-V interval identical to the interval recorded during atrial pacing. As a further criterion, JET did not convert with rapid pacing or cardioversion.⁷

All patients were treated medically. His ablation, either by catheter or cryosurgery, was attempted in six patients; these methods have been previously reported.¹²

The results of treatment were assessed by repeated ECGs and 24-hour ambulatory recordings (Holter). Treatment success was defined as a stable decrease in the ventricular rate to less than 150 beats/min;

partial success was defined as a decrease in the rate of JET to a rate greater than 150 beats/min but which resulted in alleviation of symptoms. Antiarrhythmic drug toxicity was monitored by plasma concentration, evidence for electrocardiographic toxicity, and symptoms of toxicity. In patients receiving amiodarone, plasma concentrations of any additional agents (e.g., digoxin) were monitored closely.

Results

Clinical Data

The initial age at diagnosis varied from birth to 6 months; 18 of 26 patients presented at or before 4 weeks of age. At the time of presentation, the average duration of tachycardia had been 1 day to 50 weeks (mean, 4 weeks); three infants had a history of intrauterine tachycardia (one with hydrops fetalis) although the type of tachycardia could not be ascertained from the fetal echocardiogram.

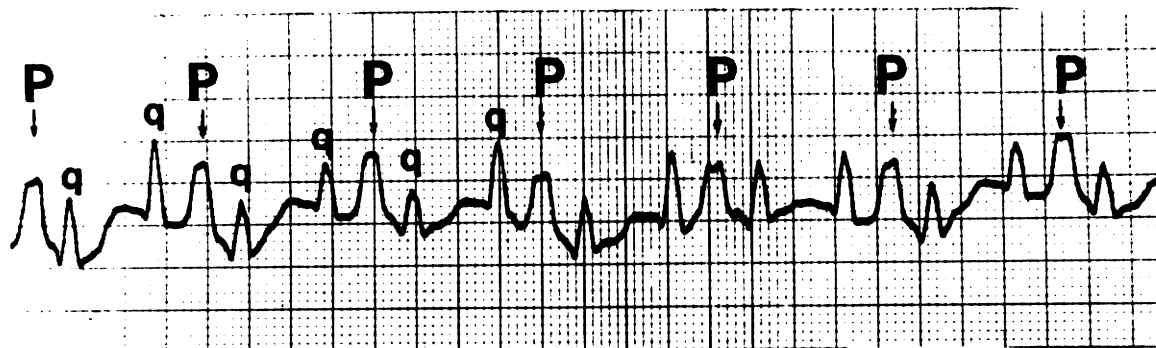


FIGURE 1. Recording showing congenital JET with atrioventricular dissociation. Paper speed is 50 mm/sec. P waves are marked by "P" (rate, 150/min) and QRS complexes are marked by "q" (rate, 280/min).

A family history of JET was positive in 50% of the children. Ten children were siblings; four were pairs of nonidentical twins; two infants were cousins, and the father of patient 21 (father not included in this study) was discovered to have accelerated junctional rhythm.

At the time of referral, 16 of 26 patients were symptomatic, presenting with varying degrees of congestive heart failure. All 16 had an abnormal echocardiogram with reduced shortening fraction. One of the youngest patients was referred as an emergency for cardiovascular collapse at 18 hours of age. The ventricular rate in those patients with congestive heart failure was significantly higher than in those patients without congestive heart failure (248 ± 26 vs. 220 ± 18 , $p < 0.05$). Age was not related to congestive heart failure. Five of eight echocardiograms performed in asymptomatic children showed abnormal results with dilation and decreased shortening fraction of the left ventricle in the range of 20–26% (mean, 23%).

Surface Electrocardiography

Continuous monitoring and repeated ECGs showed a permanent tachycardia with normal QRS morphology in all patients. At admission, the ventricular rate was in the range of 140–370 beats/min (mean, 230 beats/min); 24 patients had a regular tachycardia of more than 200 beats/min, with slight variations during the 24 hours and from day to day. Two children had more unusual ECGs showing irregularity in the RR intervals because of sinus capture beats.

Distinct P waves could be seen in the tracings of all patients, and AVD was apparent in 25 patients with independent atrial and ventricular rates (Figure 1). Three patients also demonstrated intermittent retrograde conduction to the atria.

Intracardiac Recordings

Seven children underwent electrophysiological study, three children for the diagnosis, three before a transcatheter ablation, and one before a cardiac biopsy.

The study confirmed the diagnosis in all patients. Atrial depolarizations were unrelated to the His and

ventricular depolarizations in six patients, and one had retrograde atrial activation with 1:1 ventriculoatrial conduction. No patient had atrioventricular block during atrial pacing.

Treatment

Digoxin. Digoxin was usually selected as the initial drug for treatment of the tachycardia (Table 1); it was also given to the mother of a hydropic fetus during the last month of gestation without effect on the fetal tachycardia. In the other patients, digoxin aided in controlling the symptoms of cardiac failure but, when used alone, did not affect the ventricular rate in any patient. Furthermore, digoxin had a deleterious effect in two patients. A 4-week-old child in severe cardiac failure developed ventricular fibrillation and required cardioversion after an appropriate loading dose of digoxin. A 10-day-old infant developed atrial tachycardia at a rate of 400 beats/min and then atrial flutter during progressive digoxin loading; this atrial tachycardia did not influence the ventricular rate (which was because of JET). The atrial flutter resolved after discontinuation of digoxin.

Propranolol. Propranolol (2–20 mg/kg/day and with digoxin) was the next regimen in 13 patients. The combination was ineffective in nine patients and resulted in slowing the ventricular rate in the other four patients. Of these four patients with a controlled ventricular rate, one subsequently died suddenly at 3 weeks of age. He had been taking 3 mg/kg/day.

Amiodarone. Intravenous amiodarone was given to one newborn admitted for cardiovascular collapse related to JET at 280 beats/min; despite this treatment and multiple attempts at cardioversion, he developed ventricular fibrillation and died shortly after admission.

Amiodarone was given to an additional 14 patients. In 10 patients, the drug was given by itself and initially resulted in six total successes, two partial successes, and two failures. In most patients, amiodarone resulted in slowing the tachycardia with a significant decrease of the ventricular rate, from a mean rate of 250 beats/min to a mean rate of 120 beats/min, within the first 5 days of treatment. One

of these 10 patients died. This infant had cardiac dysfunction at presentation and JET unresponsive to conventional agents. The lowest ventricular rate in a patient had been 160 beats/min. Antiarrhythmic drugs were discontinued and his ventricular rate increased to 220 beats/min. He then received a single dose of 5 mg/kg amiodarone orally; 4 hours later he died in cardiogenic shock with a temperature of 40° C; at this time he had immediate ventricular pacing but his underlying ventricular rate was 40 beats/min with complete AV block. There was no evidence of infection.

Four children received amiodarone in combination with other drugs; two were treated with amiodarone plus digoxin and propranolol with initial partial success in both children. One of these two children died suddenly after 4 months of treatment; his last ECG had shown JET at 190 beats/min. The other two children were treated with amiodarone plus digoxin and procainamide, with one success and one death. Clinical deterioration in this patient who died was because of pericardial tamponade, likely because of a temporary pacing catheter.

Overall, amiodarone was given to 15 patients. In one patient, the drug was used intravenously as an extreme measure, and he died; one patient who received an oral loading dose died; 13 patients received chronic treatment, and 11 (85%) of these patients benefited from the drug.

The dose of amiodarone that was given to the French patients was much higher than the recommended dose in the United States. These patients received a loading dose of 500 mg/m² (50 mg/kg for a newborn) and were maintained on 250 mg/m²; none of these patients received pacemakers. The U.S. patients received 5–10 mg/kg for loading, with maintenance therapy of 5 mg/kg. Four U.S. patients had implantation of ventricular demand pacemakers to guard against possible sudden complete AV block. None of these patients died. Only one patient had side effects, with skin rash and transient elevation of hepatic transaminase that resolved after decrease of the dose.

Other drugs. Other antiarrhythmic agents used to treat JET included chlorpromazine, phenytoin, quinidine, and flecainide. Phenytoin, in addition to propranolol, was effective in controlling the tachycardia but was discontinued because of ataxia. Chlorpromazine, which had caused the disappearance of JET when used as a premedication for electrophysiological study, was given orally to the patient and resulted in partial success. One patient received intravenous ajmaline and then developed ventricular tachycardia at 300 beats/min; in the same patient, intravenous verapamil caused cardiovascular collapse, and digoxin resulted in ventricular fibrillation. He died at 1 year of age with uncontrolled JET.

His Bundle Ablation

Three patients had transcatheter His ablation (1.5–3 J/kg) (Table 1). The procedure was initially

successful in two patients; in one of the two patients, AV conduction returned 3 days after ablation but JET did not return. Transcatheter His ablation was a failure in the third patient.

Surgical His ablation was attempted in four patients after failure of medical treatment or transcatheter His ablation. In two children it resulted in elimination of the tachycardia with permanent AV block. One of these children had cautery ablation (cryoablation was not available) of the His bundle, which was found to be on the left side of the interventricular septum; he developed ventricular tachycardia (thought to be because of cautery), which subsided over the next 2 weeks. The third child had been treated with digoxin and high doses of propranolol (20 mg/kg) with poor control of tachycardia. At 6 months of age, he had a cardiac arrest. Surgical ablation of the His bundle was then attempted; however, the child died in low cardiac output, JET having returned 2 days after surgery. The last patient was a girl born with JET who had a male sibling who had died previously at 8 months of age. In the young girl, several attempts were made to ablate the His bundle in the catheterization laboratory but unsuccessfully; the surgeon also failed to eliminate JET, and this child died in the operating room.

Follow-up

Deaths. Of the 26 patients, nine (34.6%) died (Table 1). The oldest age at death was 13 months. In comparing those children who died with the survivors, there was no difference in the ventricular rate, age at diagnosis, or duration of the tachycardia.

Among the nine deaths, two were sudden in patients thought to be in good control; three patients had witnessed cardiac arrest associated with uncontrolled JET (two patients fibrillated, and one patient had complete AV block); two patients died immediately after surgical attempt at His bundle ablation; and two patient deaths were related to procedures (one myocardial biopsy and one temporary pacing catheter). In summary, at least five of the deaths (19%) were directly related to the arrhythmia.

Autopsy was performed in three patients. The His bundle of one patient was found to be abnormal, split into irregular longitudinally oriented strands and containing areas of focal degeneration. One patient had nonspecific endocardial fibroelastosis. The final patient was also found to have fibroelastosis of both ventricles with a normal left-sided His bundle.

Survivors. Follow-up among 14 survivors was in the range of 9 months to 12 years (mean, 6.1 years); three patients were unavailable for follow-up.

In six children, treatment was stopped without complications. In five children, amiodarone was stopped between 10 months and 8 years of age (mean, 3.6 years). In these patients, 6 months to 8 years after discontinuing amiodarone (mean, 5.7 years), 24-hour recordings showed normal sinus rhythm; however, slow JET was still present in all, at a rate of 60–110 beats/min (mean, 82 beats/min),

appearing when the sinus rate decreased, especially at night. The combination of digoxin and propranolol was also discontinued in one patient with no recurrence of JET.

Four patients have a pacemaker after His bundle ablation with no medical treatment. Three patients are pacemaker dependent, and one has normal AV conduction without JET.

Four patients are still being treated; three patients are taking amiodarone alone, and one patient is taking a combination of drugs with a ventricular demand pacemaker. After 12–18 months of treatment, slow JET is still present at a rate of 110–150 beats/min with intermittent sinus rhythm.

Discussion

Congenital JET was first described as a distinct entity by Coumel and coworkers³ in 1975. JET, has been reported in older children and adults^{13–16}; however, it seems to be different from congenital JET, and these older children and adults have been excluded from our study. The surface ECG is usually sufficient for diagnosis of JET; electrophysiology study is usually not necessary. Because the noninvasive and invasive management of JET has undergone evolution, this study was performed to evaluate the different treatment strategies.

Treatment seems indicated in infants with symptoms, reduced ventricular function, or rapid rates. The management of the infant with slow JET (less than 150 beats/min) without symptoms is less clear. One of our patients, who was asymptomatic at birth with a ventricular rate of 140 beats/min, returned at 6 weeks of age in cardiovascular collapse with a ventricular rate of 300 beats/min. Because this was only one infant, recommendations cannot be founded statistically, and the risks of medication must be weighed against the potential morbidity and mortality of the arrhythmia.

Amiodarone

Since 1973, all French patients were treated with oral amiodarone, which was found to be effective in controlling the tachycardia without any complications.^{3,5,15} At that time, amiodarone was not available for general use in the United States, and attempts to control JET in U.S. patients occasionally were related to complications and death. In the United States, because digoxin alone had no effect on JET, patients were initially treated with digoxin and propranolol. This combination was not effective in two of three patients, and two children died; one of these children was believed to have good control of his ventricular rate before sudden death, and the other child received very high doses of propranolol. Many other drugs were also tried without significant success. When amiodarone became available as an investigational antiarrhythmic drug in the United States, it was given to JET patients.

Pacing

Four children with “well-compensated” JET died suddenly; one of these children had a slow ventricular rate documented during the terminal event. There has been concern that the pathological process in the area of the AV junction that initially presents as JET might later extend and cause sudden complete AV block. This concept has been bolstered by the appearance at autopsy of His bundle degeneration. Additionally, one patient has been reported in which a Purkinje cell tumor was found in the His bundle,¹⁵ causing JET and bradycardia. For these reasons, four patients received backup pacemakers. There have been no further sudden deaths with this approach.

His Bundle Ablation

The treatment philosophy further evolved to His bundle ablation. It was reasoned that because backup pacemakers were going to be implanted, ablation of the arrhythmogenic area could rid the patient of the need for medication. Two patients, however, died in these procedures. The difficulty of catheter and even surgical ablation of JET from the right side of the heart raises questions about the exact location of the arrhythmogenic area. It is possible that the His bundle is left-sided in these patients, or even that “JET” is actually ventricular tachycardia that originated from the left side of the ventricular septum with activation spreading immediately to the His bundle. This difference will be difficult to resolve electrophysiologically because both will present as tachycardias with the same QRS as sinus-conducted beats; however, ventricular tachycardia should have an extremely localized area on the left septal surface in which the H-V interval is short or even negative.

Current Management

Medical treatment is probably indicated in all patients with congenital JET. The combination of digoxin plus propranolol might be tried; however, if the ventricular rate cannot be reduced below 150 beats/min on routine ECG, amiodarone should be considered. Because of the French experience with no recent sudden deaths in patients treated with amiodarone without a pacemaker, the necessity for permanent pacing remains unsettled. Attempts at catheter and surgical ablation are reserved only for those patients with severe congestive heart failure not responsive to medical management. As even more experience is developed with this rare entity, it is likely that these recommendations will continue to evolve.

References

1. Batisse A, Petit J, Fermont L, Kachaner J: Les tachycardies supraventriculaires du nouveau-né et du nourrisson. *Arch Fr Pédiatr* 1979;36:551–556
2. Brechenmacher C, Coumel P, James TM: De subitaneus mortibus: XVI. Intractable tachycardia in infancy. *Circulation* 1976;53:377–381
3. Coumel P, Fidelle JE, Attuel P, Brechenmacher C, Batisse A, Bretagne J, Clementy J, Gerard R, Grolleau R, Huault G, Mouy A, Nouvailles J, Kachaner J, Ribierre M, Tournieux

- MC: Tachycardies focales hisiennes congenitales: Etude cooperative de sept cas. *Arch Mal Coeur* 1976;69:899-903
4. Fellingner F, Chauvin M, Dickele MC, Geraudel A, Buillemin MD, Soudier G: Tachycardie hisienne chez un enfant de sept ans. *La Press Med* 1985;24:14-21
 5. Fidelle J, Do Ngoc, Attuel P, Coumel P: L'amiodarone dans le traitement des troubles du rythme cardiaque chez l'enfant: A propos de 135 cas. *Arch Mal Coeur* 1980;76:198-205
 6. Gallagher JJ, Svenson RH, Kasell JH: Catheter technique for closed-chest ablation of the atrioventricular conduction system: A therapeutic alternative for the treatment of refractory supraventricular tachycardia. *N Engl J Med* 1982;306:194-196
 7. Garson A, Gillette PC: Junctional ectopic tachycardia in children: Electrocardiography, electrophysiology and pharmacologic response. *Am J Cardiol* 1979;44:298-302.
 8. Garson A, Gillette PC, McNamara DG: Supraventricular tachycardia in children: Clinical features, response to treatment, and long-term followup in 217 patients. *J Pediatr* 1981; 98:875-882
 9. Gaudelus J, Palsky D, Nyiri A, Chiron C, Nathanson M, Dandine M, Guerin F, Perelman R: Tachycardie focale hisienne familiale. *Ann Pediatr (Paris)* 1983;30:107-110
 10. Gaudelus J, Jeandidier B, Giorno JL, Nathanson M, Perelman R: Tachycardie focale hisienne familiale: Une nouvelle observation dans la meme famille. *Ann Pediatr (Paris)* 1984; 31:343-345
 11. Gillette PC, Garson A, Hesslein PS, Karpawich PP, Tierney RC, Cooley DA, McNamara DG: Successful surgical treatment of atrial, junctional and ventricular tachycardia unassociated with accessory connections in infants and children. *Am Heart J* 1981;102:984-991
 12. Gillette PC, Garson A, Porter CJ, Ott DA, McVey P, Zinner A, Blair H: Junctional ectopic tachycardia: New proposed treatment by transcatheter His ablation. *Am Heart J* 1983; 106:619-623
 13. Kachaner J, Batisse A, Billain E, Lucet V: Tachycardies hisiennes, in Kachaner J (ed): *Troubles du Rythme Cardiaque Chez L'enfant*. Paris, 1987, pp 77-80
 14. Petit J, Lancelin B, Cabanis C, Lecanellier E, Charpentier A, Guize L, Maurice P: Tachycardie hisienne chez une adulte porteuse d'une transposition corrigeée des gros vaisseaux. *Arch Mal Coeur* 1979;72:113-117
 15. Rossi L, Piffer R, Turolla E, Frigerio B, Coumel P, James TN: Multifocal Purkinje like tumor of the heart: Occurrence with other anatomic abnormalities in the atrioventricular junction of an infant with junctional tachycardia, Lown-Ganong-Levine syndrome, and sudden death. *Chest* 1985;87:340-343
 16. Ruder MA, Davis JC, Edlar M, Abbott JA, Griffin JC, Seger JJ, Scheinman MM: Clinical and electrophysiologic characterization of automatic junctional tachycardia in adults. *Circulation* 1986;73:930-935

KEY WORDS • supraventricular tachycardia • infants • children • sudden death