

Endovascular β -Radiation to Reduce Restenosis After Coronary Balloon Angioplasty

Results of the Beta Energy Restenosis Trial (BERT)

Spencer B. King III, MD; David O. Williams, MD; Prakash Chougule, MD; J. Larry Klein, MD; Ron Waksman, MD; Richard Hilstead, MBA; Joan Macdonald, PhD; Kris Anderberg, RN; Ian R. Crocker, MD

Background—In the porcine overstretch injury model of restenosis, endovascular β -radiation reduces neointima formation. To determine whether this therapy could be applied to patients with coronary artery disease, a special device was developed to allow delivery of 12 encapsulated $^{90}\text{Sr}/\text{Y}$ sources, measuring a total of 30 mm, to various sites within the coronary arterial tree. This study was designed to evaluate the feasibility of the delivery of 12, 14, or 16 Gy at 2 mm after balloon angioplasty of stenoses of native coronary vessels.

Methods and Results—Delivery of β -radiation was attempted in 23 patients after successful balloon angioplasty. Source delivery was successful in 21 of the 23 patients (91%). There was no in-hospital or 30-day morbidity or mortality. Follow-up quantitative coronary arteriography in 20 patients demonstrated a late loss of 0.05 mm, a late loss index of 4%, and a restenosis rate of 15%. The use of the β -emitter $^{90}\text{Sr}/\text{Y}$ significantly reduced treatment time and operator exposure compared with previous trials with the γ -emitter ^{192}Ir .

Conclusions—In this study, the administration of endovascular β -radiation after angioplasty was safe and feasible and substantially altered the postangioplasty late lumen loss, resulting in a lower-than-expected rate of restenosis. On the basis of these encouraging results, a multicenter, randomized trial with operators and patients blinded to treatment assignment is planned. (*Circulation*. 1998;97:2025-2030.)

Key Words: angioplasty ■ coronary disease ■ radioisotopes ■ restenosis

After coronary artery angioplasty, restenosis of the dilated segment occurs in 30% to 50% of patients and results from elastic recoil, neointima formation, and vascular contracture.¹⁻⁴ The formation of neointima and the perivascular fibrosis that result in late luminal narrowing resemble scar formation seen in other tissues. Low-dose ionizing radiation has been effective in reducing excessive scar formation, as shown in numerous clinical reports of its use in the prevention of keloids.⁵⁻⁷ Radiation has shown similar efficacy in the management of other benign proliferative conditions, such as heterotopic bone formation,⁸ pterygia,^{9,10} Graves' exophthalmos,¹¹ and gynecomastia.¹²

Endovascular radiation has been evaluated in the porcine overstretch balloon injury model of restenosis and was shown to reduce neointima formation in a dose-related manner with both γ - and β -radiation.¹³⁻¹⁶ Endovascular γ -radiation has been found to reduce coronary artery renarrowing after angioplasty¹⁷ and renarrowing of stented coronary arteries with prior restenosis.¹⁸ This study eval-

uates a catheter-based system designed to deliver high-activity β -emitting sources for restenosis prevention in coronary vessels after percutaneous transluminal coronary angioplasty (PTCA).

Methods

This trial was conducted under the first Food and Drug Administration Investigational Device Exemption for a human feasibility trial of endovascular radiation and was approved by the Institutional Review Board and the Radiation Safety Committees of both institutions. The objectives of the study were to evaluate the feasibility of endovascular irradiation using the Beta-Cath System (Novoste Corp) in human coronary arteries, to confirm the operational specifications of the device, to examine the effect of 3 different doses of radiation, and to observe the restenosis parameters compared with a historic control group. Inclusion criteria were age 18 to 80 years; ischemia by symptoms or laboratory testing; intended balloon angioplasty of single, de novo lesions in native coronary vessels; reference vessel diameter of 2.5 to 3.5 mm; lesion length ≤ 15 mm; stenosis severity $> 60\%$; and agreement to return for follow-up examinations, including angiographic follow-up at 6 months. Exclusion criteria were

Received November 3, 1997; revision received February 2, 1998; accepted February 13, 1998.

From the Andreas Gruentzig Cardiovascular Center, Division of Cardiology (S.B.K., J.L.K., R.W., K.A.), and the Department of Radiation Oncology (I.R.C.), Emory University School of Medicine, Atlanta, Ga; the Division of Cardiology (D.O.W.) and the Department of Radiation Oncology (P.C.), Rhode Island Hospital, Brown University, Providence, RI; and Novoste Corp (R.H., J.M.), Norcross, Ga.

Drs King, Williams, Waksman, and Crocker own stock in Novoste Corp, and R. Hilstead and Dr Macdonald are employees of the company.

Correspondence to Dr Spencer B. King III, Director, Andreas Gruentzig Cardiovascular Center, Room F-606, Emory University Hospital, 1364 Clifton Rd NE, Atlanta, Ga 30322.

E-mail sking01@emory.edu

© 1998 American Heart Association, Inc.

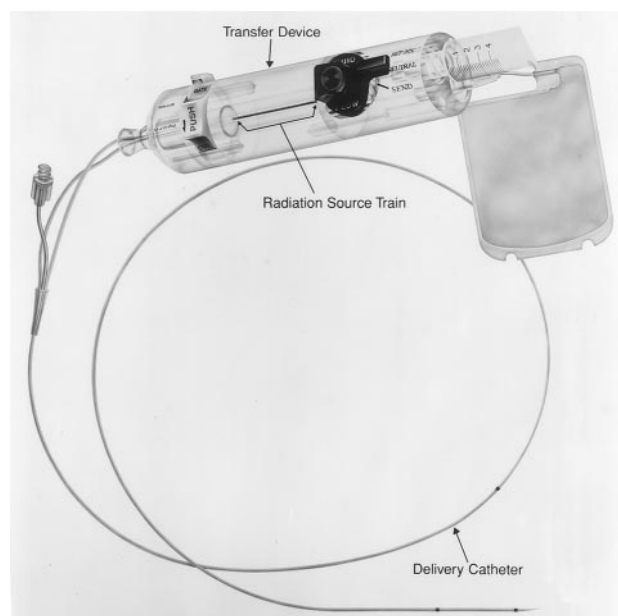


Figure 1. Novoste Beta-Cath System with transfer device containing $^{90}\text{Sr}/\text{Y}$ sources and delivery catheter.

myocardial infarction within 3 days, contraindication to aspirin, ejection fraction $<40\%$, prior chest radiotherapy, an illness that threatened survival within the next 6 months, unprotected left main disease, angiographically visible thrombus at the site of the lesion, serum creatinine >2 mg/dL, pregnancy, and a vessel angle of $>45^\circ$ at the lesion site. Baseline characteristics of the study population were age 57 years (44 to 80 years), male sex 85%, diabetes 15%, hypertension 35%, hyperlipidemia 80%, and current smokers 25%. The reference artery size was 2.88 ± 0.32 mm, and lesion length was 9 mm.³⁻¹⁷ Lesion severity is reflected in Table 2.

Radiation Delivery System

The Beta-Cath System consists of 3 components: (1) the delivery catheter, (2) the transfer device, and (3) the radiation sources (Fig 1). The triple-lumen, over-the-wire delivery catheter (5F) is a closed-ended, flexible coronary catheter with a lumen for hydraulically delivering the train of radiation sources, a second lumen for reversed fluid flow, and a through lumen for passage over a 0.014-in guidewire. The catheter has 2 radiopaque marker bands, 30 mm apart, at the distal end where the radioactive sources reside when deployed. The catheter connects to the transfer device, which houses the sources in a quartz chamber and contains a switching system and a gate. The switch allows forward fluid flow to either transfer the sources to the end of the catheter or return them to the transfer device. The radiation source train consists of 12 stainless steel canisters containing the radioisotope $^{90}\text{Sr}/\text{Y}$ sources and is bounded by 2 gold markers. The gold marker seeds allow easy visualization of the source train with fluoroscopy (Fig 2).

Procedure

In this trial, balloon angioplasty was carried out in standard fashion, with all patients receiving heparin and aspirin before the procedure. After successful dilatation, the balloon catheter was removed, with the guidewire left in place. The radiation catheter, connected to the transfer device, was then inserted over the guidewire and advanced such that the 2 marker bands encompassed the angioplasty site. Once satisfactory positioning of the catheter was confirmed under fluoroscopy, the gate of the transfer device was opened, and the source train was hydraulically delivered down the catheter. During the procedure, minimal pressure and fluid flow were required to maintain the source train at the distal end of the source lumen. After radiation therapy,

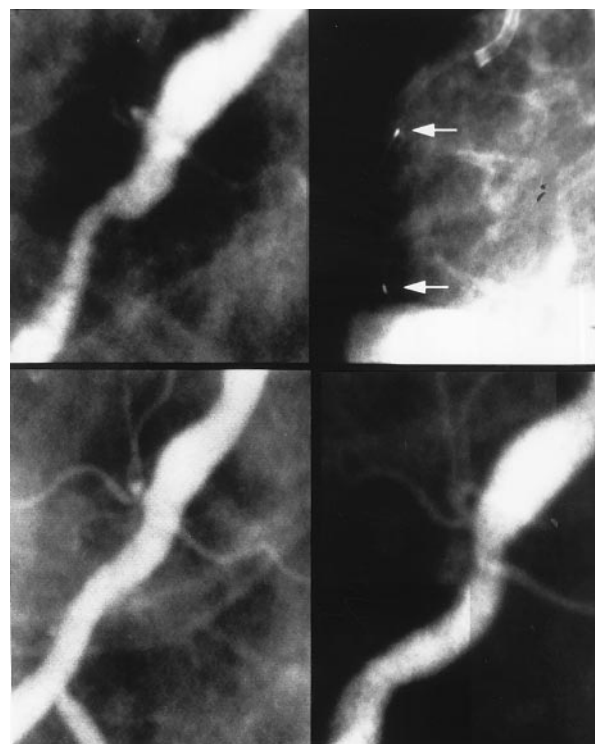


Figure 2. Pictures from representative case from BERT Trial. Top left, Preangioplasty; bottom left, postangioplasty; top right, during treatment with gold marker seeds; and bottom right, 6-month follow-up study.

the source train was returned to the transfer device by reversal of the switching system, which enabled injected fluid to push the train back into the transfer device.

Dosimetry

The 2 source trains used in this study were calibrated at the National Institute of Standards and Technology and included measurement of the dose rate at 2 mm from the center of the source train using both an extrapolation chamber and GafChromic Dosimetry Media. These sources were specifically developed for endovascular radiation and were manufactured to meet all Nuclear Regulatory Commission requirements for axial and longitudinal symmetry. β -Emitters, as opposed to γ -emitters, deposit their dose in a very focal pattern around the catheter and deliver insignificant doses to tissues more than 5 mm from the source train, as shown in Fig 3. In the trial, patients were assigned to receive either 12, 14, or 16 Gy at a distance of 2 mm from the center of the source, producing a 4-mm cylinder of radiation of

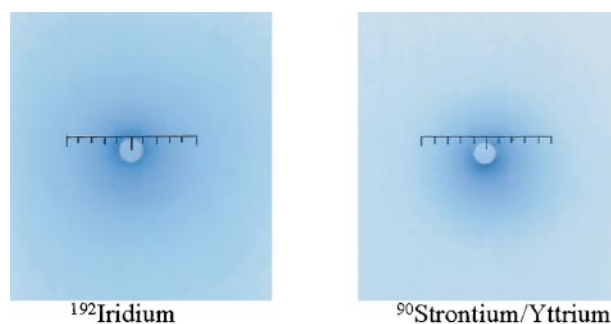


Figure 3. GafChromic film showing difference in deposited dose between β -emitting ($^{90}\text{Sr}/\text{Y}$) and γ -emitting (^{192}Ir) isotopes. Each film was exposed to deliver 14 Gy at 2-mm depth.

TABLE 1. Dose Equivalent Level With γ - and β -Isotopes, μ Sv

	SCRIPPS Trial ^{1E}	BERT*
Dose equivalent at chest surface	Not measured	0.95
Dose equivalent at groin	Not measured	0.25
Dose equivalent to patient	6410	0.43
Dose equivalent to operator per procedure	4000	0.20

*Based on a 3-minute patient exposure time.

this intensity at its outer rim. The catheter measured 5F (diameter, ≈ 1.6 mm), which resulted in approximate centering in the residual lumen of the dilated segments (average post-PTCA lumen diameter being 2.16 mm). It was assumed that cardiac motion would result in additional centering of the catheter in the vessel lumen. Because of variation in thickness of the vessel wall and the eccentric positioning of the lumen within the vessel, it was anticipated that the dose to the vessel wall was heterogeneous. Treatment times varied between 2 minutes 20 seconds and 3 minutes 44 seconds, depending on dose prescribed and source train used. The radiation physicist obtained measurements of the radiation levels in the room before, during, and after the procedure. Dose-equivalent rates at the patient's chest averaged 2.1 mrem/h; at the groin, 0.3 mrem/h; and at the position of the cardiologist performing the procedure, 0.3 mrem/h. This is contrasted in Table 1 with the experience of investigators using γ -radiation for the SCRIPPS Trial, as described by Jani et al.¹⁹

Study Schema

Patients scheduled for planned PTCA of a single, de novo stenosis of a native coronary vessel were approached for participation in the trial. If the patient's physician and the patient agreed, the patient was asked to sign a consent form to participate in the study. Enrollment occurred after successful angioplasty, and randomization was to 1 of 3 doses. Monthly telephone follow-up was done after treatment, and angiographic follow-up was done at 6 months.

Quantitative Coronary Arteriography

Baseline and 6-month quantitative coronary arteriography was performed by a validated core laboratory using the NIH Image System.²⁰ Repeat measurements were performed with the CAAS system.²¹ Angiograms were obtained in 2 views after intracoronary nitroglycerin injection. Optimal views of the lesion were obtained at baseline, and these same projections were reproduced when the posttreatment and 6-month follow-up angiograms were performed. All measurements were made by trained technicians and reviewed by the director of the core angiographic laboratory (J.L.K.), who was blinded as to treatment dose. The clinical investigators did not participate in the angiographic assessment.

Statistical Analysis

Clinical data and the coronary dimensions were reported as mean \pm SD. Comparison between different dose groups was carried out by ANOVA. A value of $P < .05$ was considered significant. Acute gain was defined as the increase in the absolute diameter of the treated segment immediately after the procedure. Late loss was defined as the decrease in absolute diameter of the treated segment from the postprocedure to the 6-month follow-up angiogram. The late loss index was calculated by dividing the late loss by the acute gain.

Results

Between January 21, 1996, and October 25, 1996, 23 patients were enrolled in the study. Two did not receive radiation treatment, 1 because of inability to pass the delivery catheter into a small (2.5-mm) obtuse marginal branch and the second because of an obstruction in the

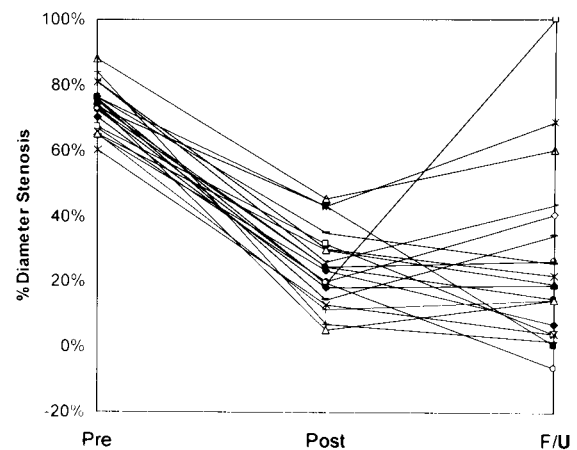


Figure 4. Percent diameter stenosis preangioplasty, postangioplasty, and at 6 months in patients in BERT. F/U indicates follow-up.

source lumen of the delivery catheter. A third patient received radiation treatment after an angioplasty that had resulted in a significant dissection. In this patient, 2 additional coronary interventions were performed within the next several days, making the patient ineligible for angiographic follow-up per protocol. This patient did have angiography 4 months after therapy, revealing no late loss, but was not eligible for inclusion in the angiographic assessment. The remaining 20 patients received the prescribed radiation treatment: 6 patients 12 Gy, 7 patients 14 Gy, and 7 patients 16 Gy. Eight left anterior descending, 8 right coronary, and 4 left circumflex artery lesions were treated. No adverse effects of delivering the catheter were observed. After the radiation was delivered, 2 patients had stents placed in the treated segment because of persistent stenosis. There were no deaths, no myocardial infarctions, and no reinterventions by 30-day follow-up. At 6 months, there were no deaths or myocardial infarctions. Two patients underwent an intervention of the target lesion at the 6-month follow-up visit, and 1 patient had an intervention of an untreated site 5 months after intervention. The percent diameter stenoses before, after, and at 6 months after the angioplasty are shown for all 20 patients in Fig 4. Measurements as defined in the protocol were obtained before PTCA, after PTCA and brachytherapy, and at 6 months by use of the NIH Image method. These were closely correlated to second measurements according to

TABLE 2. Comparison of CAAS and NIH Quantitative Coronary Angiograms on BERT Patients

	Pre-PTCA	Post-PTCA	6-Month Follow-up
Average MLD, mm \pm SD (NIH Image)	0.78 \pm 0.25	2.16 \pm 0.40	2.11 \pm 0.78
Average MLD, mm \pm SD (CAAS)	0.79 \pm 0.25	2.13 \pm 0.42	2.06 \pm 0.71
% Diameter stenosis \pm SD (NIH Image)	73 \pm 7	24 \pm 12	26 \pm 26
% Diameter stenosis \pm SD (CAAS)	73 \pm 6	25 \pm 11	27 \pm 24

MLD indicates minimal lumen diameter.

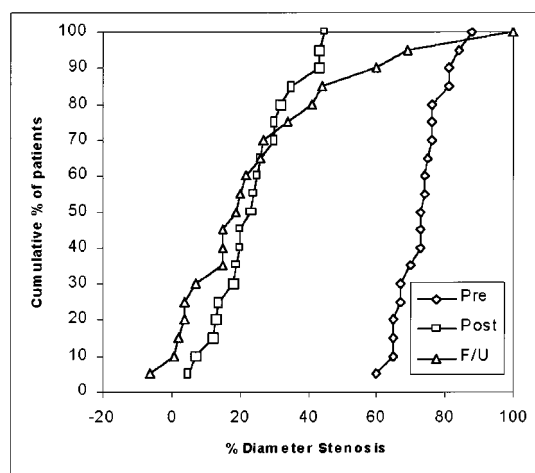


Figure 5. Percent diameter stenosis cumulative distribution curve of patients in BERT. Pre indicates preangioplasty; Post, postangioplasty; and F/U, 6-month follow-up.

the CAAS system (Table 2). The major finding was, by NIH Image criteria, a lower-than-expected late lumen loss of 0.05 mm and late loss index (late loss divided by initial gain) of 4%. There were no significant differences in late loss or late loss index between different dose groups by ANOVA ($P=.58$).

Restenosis, defined by $\geq 50\%$ narrowing at follow-up, occurred in 3 segments. One restenosis was a total occlusion, which may have represented an early thrombotic event. A second restenosis appears to represent a nonhealed dissection. The final lesion that qualified for restenosis measured 60% at follow-up but had measured only 45% after PTCA. The remaining 17 patients did not have narrowing of $\geq 50\%$ at 6-month follow-up. The cumulative distribution curves of minimal lumen diameter and percent stenosis are shown in Figs 5 and 6 and illustrate that most of the treated segments had no late loss and that there was some positive remodeling of the treated segments in 9 of the 20 patients. No aneurysms were observed.

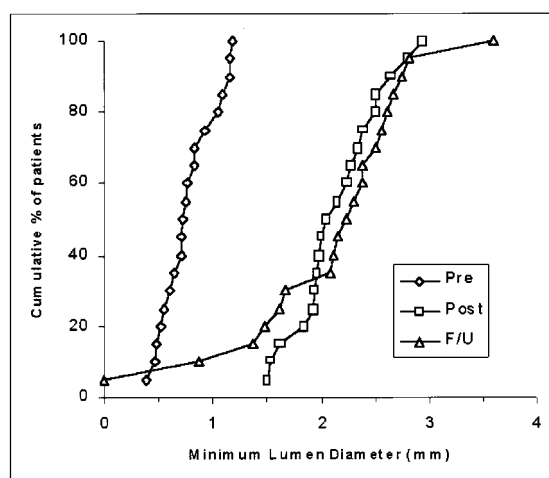


Figure 6. Minimum lumen diameter cumulative distribution curve of patients in BERT. Pre indicates preangioplasty; Post, postangioplasty; and F/U, 6-month follow-up.

Discussion

Three previous studies of endovascular coronary brachytherapy after angioplasty or stenting have been reported. Two of these trials, using γ -radiation, showed a significant reduction in late lumen loss and a beneficial effect on the restenosis rate.^{17,18} The third trial, involving the use of ^{90}Y , showed the feasibility of delivering β -radiation but no evident effect on late loss, late loss index, or restenosis rate.²² The present trial represents the first study in which β -radiation has shown results comparable to those of γ -radiation in altering the luminal renarrowing after coronary angioplasty. Because γ -radiation is highly penetrating and results in increased exposure of the patient and the operators to ionizing radiation, it is desirable to use a radiation source that reduces this effect. Previous animal experiments in our laboratory showed suppression of neointima formation with β -radiation to a degree equal to that previously observed with γ -radiation. The system used in this study was designed specifically for coronary applications with the goal of creating a catheter-based device similar to a balloon catheter that could deliver a high-activity β -radiation source to various segments of the coronary artery tree. The β -radiation source, $^{90}\text{Sr}/\text{Y}$, was chosen because the dose level desired at a depth necessary to treat the coronary artery wall could be achieved without reaching other radiosensitive tissues or endangering the operators during routine coronary interventional procedures. The catheter was successfully delivered in all but one case and reached distal coronary segments without difficulty or complications. Design alterations to improve the ease of delivery and to correct the problem that had resulted in obstruction of the source lumen have been done as a result of the feasibility trial. Radiation measurements at the patient's chest and groin and within the catheterization laboratory confirmed the very low exposures expected with a β -emitter. In contrast, the previously reported absorbed dose equivalent at the operator position with γ -radiation was 2×10^4 times greater than with the β -system.

The striking finding of this feasibility study was the overall lack of luminal renarrowing after angioplasty. In previous studies, such as the Lovastatin Restenosis Trial,²³ lumen diameter loss was 43% of the initial gain (loss index), but in this series it was only 4%. Angiographic restenosis, defined as $\geq 50\%$ stenosis at follow-up, may have been explained in 2 of 3 patients by mechanisms other than neointima formation or negative remodeling. The patient with the total occlusion of the obtuse marginal branch had no improvement in angina after PTCA and may have had an early thrombotic occlusion. The patient with the right coronary artery stenosis at follow-up had an intimal flap that by ultrasound was a persistent dissection without significant neointimal tissue within the lumen.

The distribution of the radiation dose in the vessel wall has been the source of significant discussion. A tenet of radiation therapy for cancer is to attempt to achieve as much homogeneity of dose in the target volume as possible. With endovascular brachytherapy using either γ - or β -emitters, a fairly broad dose range in the vessel wall will

result because of the rapid fall-off in dose with small increases in distance from the source. One potential approach is to use a balloon to center the source in the lumen. This, however, does not ensure centering in the arterial wall, because most coronary lesions are focal and eccentric. It is important to consider, therefore, whether a broad range of radiation doses will inhibit neointima and adventitial scarring. Studies in our laboratory revealed a dose-related response to β -radiation over a broad range (7 to 56 Gy at 2 mm).²⁴ We have not shown any dose at which neointima formation is stimulated in the porcine overstretch coronary model. Furthermore, we are uncertain of the need to deliver doses of ≥ 7 Gy to the entire vessel wall. The positive study reported by Teirstein et al,¹⁸ in which many of the patients received ≤ 8 Gy to the leading edge of the tunica media, would suggest that this may not be necessary. Creating an adequate zone of inhibition surrounding the catheter may suffice to prevent restenosis. Our method of prescribing a dose of 12 to 16 Gy at a radius of 2 mm in arteries with reference diameters of 2.5 to 3.5 mm seemed to achieve this goal.

A point of concern is the doses received in normal tissues. At this time, there is no relevant clinical information as to whether any side effects might be expected in the long term from small volumes of the vessel wall receiving relatively high doses of radiation (>30 Gy) with either a γ - or β -emitter. Animal studies revealed no evidence of acute injury from doses up to 56 Gy at 2 mm in a single fraction delivered by the intracoronary route. We saw no evidence of injury at 6 months in pigs given 14 Gy with the γ -emitter ¹⁹²Ir. Because this was a noncentered, small catheter system, it is possible that some portions of the lumen surface received doses up to 55 Gy. The fact that no late effects from radiation were observed in these studies suggests that it is structures deep to the luminal surface that determine whether radiation-related complications are likely to be observed. Another possibility is that radiation is much better tolerated when only small volumes are treated.

One apparent discrepancy concerns the negative results reported from Verin et al,²² using a similarly penetrating β -isotope, ⁹⁰Y. The major difference between the 2 trials involved the use of the balloon-centering system in the Geneva study and prescription of the radiation dose to the balloon-vessel interface as opposed to 2 mm depth. Even assuming centering of the Beta-Cath delivery catheter in a 3-mm lumen, the surface dose would have been ≈ 21 Gy. This is obviously larger than the 18 Gy prescribed by the Geneva group. The actual dose delivered to deeper tissues with the Beta-Cath catheter (which has no inflated balloon) is significantly higher, because the lumen size after PTCA averaged 2.16 mm in this trial. Using a balloon to center the source in the vessel lumen may displace the target tissues to a depth such that β -radiation may lose its effectiveness.

Conclusions

The feasibility of delivering the β -radiation sources to appropriate coronary artery sites in patients was confirmed. The operational specifications of the Beta-Cath

system were confirmed. No death, myocardial infarction, or surgery occurred in the 6-month follow-up time window. Endovascular β -radiation altered the luminal narrowing response similar to that previously seen in animal studies and in patients treated with γ -radiation. The lack of overall late lumen loss was remarkably different from that observed in previous restenosis trials using similar angiographic methods.

On the basis of these encouraging findings, endovascular β -radiation may be an important therapy for reducing the incidence of restenosis, and a large, randomized trial to test the hypothesis in angioplasty and stent patients is warranted.

Acknowledgments

The authors wish to acknowledge the contributions of Keith Robinson, PhD, and the personnel of the Rich Research Laboratory of the Andreas Gruentzig Cardiovascular Center of Emory University, in which the potential usefulness of β -radiation for preventing restenosis was proven.

References

- Holmes DR Jr, Vlietstra RE, Smith HC, Vetrovec GW, Kent KM, Cowley MJ, Faxon DP, Gruentzig AR, Kelsey SF, Detre KM, van Raden MJ, Mock MB. Restenosis after percutaneous transluminal coronary angioplasty (PTCA): a report from the PTCA registry of the National Heart, Lung and Blood Institute. *Am J Cardiol*. 1984;53:77C–81C.
- Popma JJ, Califf RM, Topol EJ. Clinical trials of restenosis after coronary angioplasty. *Circulation*. 1991;84:1426–1436.
- Gruentzig AR, King SB III, Schlumpf M, Siegenthaler W. Long-term follow-up after percutaneous transluminal coronary angioplasty. *N Engl J Med*. 1987;316:1127–1132.
- Mintz GS, Popma JJ, Pichard AD, Kent KM, Satler LF, Wong C, Honk MK, Kovach JA, Leon MB. Arterial remodeling after coronary angioplasty: a serial intravascular ultrasound study. *Circulation*. 1996;94:35–43.
- Kovalic JJ, Perez CA. Radiation therapy following keloidectomy: a 20 year experience. *Int J Radiat Oncol Biol Phys*. 1989;17:77–80.
- Van den Brenk HAS, Minty CCJ. Radiation in the management of keloids and hypertrophic scar. *Br J Surg*. 1959/1960;47:595–605.
- Inalsingh CHA. An experience in treating 501 patients with keloids. *Johns Hopkins Med J*. 1974;134:284–290.
- MacLennan I, Keys HM, Evarts CM, Rubin P. Usefulness of post-operative hip irradiation in the prevention of heterotopic bone formation in a high risk group of patients. *Int J Radiat Oncol Biol Phys*. 1984;10:49–53.
- Van den Brenk HAS. Results of prophylactic postoperative irradiation in 1300 cases of pterygium. *Am J Radiol*. 1968;103:723–733.
- Wilder RB, Buatt JM, Kittleson JM, Shimm DS, Hevari PM, Rogoff EE, Cassidy JR. Pterygium treated with excision and post-operative beta irradiation. *Int J Radiat Oncol Biol Phys*. 1992;23:533–537.
- Donaldson SS, Bagshaw MA, Kriss JP. Supravoltage orbital radiotherapy for Graves' ophthalmopathy. *J Clin Endocrinol Metab*. 1973;37:276–285.
- Gagnon JD, Moss WT, Stevens KR. Pre-estrogen breast irradiation for patients with carcinoma of the prostate: a critical review. *J Urol*. 1979;121:182–184.
- Wiedermann JG, Marboe C, Amols H, Schwartz A, Weinberger J. Intracoronary irradiation markedly reduces restenosis after balloon angioplasty in a porcine model. *J Am Coll Cardiol*. 1994;23:1491–1498.
- Waksman R, Robinson K, Crocker I, Gravanis M, Cipolla G, King SB III. Endovascular low-dose irradiation inhibits neointima formation after coronary artery balloon injury in swine: a possible role for radiation therapy in restenosis prevention. *Circulation*. 1995;91:1533–1539.
- Weinberger J, Amols H, Ennis R, Schwartz A, Weidemann J, Marboe C. Intracoronary irradiation: dose response for the prevention of restenosis in swine. *Int J Radiat Oncol Biol Phys*. 1996;36:767–775.
- Mazur W, Ali MN, Khan MM, Dabaghi SF, DeFelice CA, Paradis P Jr, Butler EB, Wright AE, Fajardo LF, French BA, Raizner AE. High dose

- rate intracoronary radiation for inhibition of neointimal formation in the stented and balloon-injured porcine models of restenosis: angiographic, morphometric, and histopathologic analyses. *Int J Radiat Oncol Biol Phys*. 1996;36:777-788.
17. Condado JA, Waksman R, Gurdziel O, Espinosa R, Gonzalez J, Burger B, Villoria G, Acquatella H, Crocker I, Seung K, Liprie S. Long-term angiographic and clinical outcome after percutaneous transluminal coronary angioplasty and intracoronary radiation therapy in humans. *Circulation*. 1997;96:727-732.
 18. Teirstein PS, Massullo V, Jani S, Popma J, Mintz G, Russo R, Schatz R, Guarneri E, Steuterman S, Morris N, Leon M, Tripuraneni P. Catheter-based radiotherapy to inhibit restenosis after coronary stenting. *N Engl J Med*. 1997;336:1697-1703.
 19. Jani SK, Massullo V, Steuterman S, Tripuraneni P, Teirstein P. Radiation safety aspects of a coronary irradiation pilot study utilizing manually loaded Ir-192 sources. *J Am Coll Cardiol*. 1997;497A. Abstract.
 20. Klein JL, Boccuzzi SJ, Treasure CB, Manoukian SV, Vogel RA, Bauman GJ, Fischman D, Savage MP, Weintraub WS, for the Lovastatin Restenosis Trial Group. Performance standards and edge detection with computerized quantitative coronary arteriography. *Am J Cardiol*. 1996;77:815-822.
 21. Gronenschild E, Janssen J, Tijdens F. CAAS II: a second generation system for off-line quantitative coronary angiography. *Cathet Cardiovasc Diagn*. 1994;33:61-75.
 22. Verin V, Urban P, Popowski Y, Schwager M, Nouet P, Dorsaz P, Chatelain P, Kurtz J, Rutishauser W. Feasibility of intracoronary β -irradiation to reduce restenosis after balloon angioplasty: a clinical pilot study. *Circulation*. 1997;95:1138-1144.
 23. Weintraub WS, Boccuzzi SJ, Klein JL, Kosinski AS, King SB III, Ivanhoe R, Cedarholm JC, Stillabower ME, Talley JD, DeMaio SJ, O'Neill WW, Frazier JE II, Cohen-Bernstein CL, Robbins DC, Brown CL III, Alexander RW, Lovastatin Restenosis Trial Study Group. Lack of effect of lovastatin on restenosis after coronary angioplasty. *N Engl J Med*. 1994;331:1331-1337.
 24. Waksman R, Robinson K, Crocker I, Wang C, Gravanis M, Cipolla G, Hillstead R, King S III. Intracoronary low dose β -irradiation inhibits neointima formation after coronary artery balloon injury in the swine restenosis model. *Circulation*. 1995;92:3025-3031.