

Effects of Intracoronary β -Radiation Therapy After Coronary Angioplasty An Intravascular Ultrasound Study

David Meerkin, MBBS; Jean-Claude Tardif, MD; Ian R. Crocker, MD; Andre Arsenault, MD; Michel Joyal, MD; Guylaine Lucier, RN; Spencer B. King III, MD; David O. Williams, MD; Patrick W. Serruys, MD; Raoul Bonan, MD

Background—Endovascular radiation is emerging as a potential solution for the prevention and treatment of restenosis. Its effects on the morphology of unstented vessels cannot be determined by angiography and therefore require the use of intravascular ultrasound.

Methods and Results—Through a 5F noncentered catheter for delivery of a $^{90}\text{Sr}/\text{Y}$ source train, 12, 14, or 16 Gy at 2 mm was delivered to native coronary arteries after successful balloon angioplasty in 30 patients. Four patients required stent deployment in the first week. Quantitative coronary angiography and IVUS were performed during the initial procedure and at 6-month follow-up. Binary angiographic restenosis was present in 3 of 30 patients, with target lesion and vessel revascularization performed in 3 and 5 patients, respectively. Angiographic late loss was -0.02 ± 0.60 mm, with a -0.09 ± 0.46 loss index. IVUS demonstrated no significant reduction in lumen area (from 5.69 ± 1.72 mm² after treatment to 6.04 ± 2.63 mm² at follow-up), with no significant change in external elastic membrane area (13.71 ± 4.54 to 14.22 ± 4.71 mm²) over the 6-month follow-up. Wall area was 8.01 ± 3.85 mm² after radiation therapy and 8.19 ± 3.44 mm² at follow-up ($P=\text{NS}$). No significant differences were noted between the different dose groups.

Conclusions— β -Radiation therapy resulted in a low restenosis rate with negligible late loss by angiography. By IVUS, β -radiation was shown to inhibit neointima formation, with no reduction of total vessel area at 6-month follow-up. (*Circulation*. 1999;99:1660-1665.)

Key Words: coronary disease ■ angioplasty ■ restenosis ■ radioisotopes ■ ultrasonics

The problem of restenosis after angioplasty has vexed interventional cardiologists for the past 2 decades. Intracoronary radiation therapy has recently emerged as a promising new approach to prevent restenosis.¹⁻³ Radiotherapy has been shown to inhibit neointima formation in animal models.⁴⁻¹¹ In addition, the restenosis rate and late luminal loss were significantly reduced in the only randomized clinical trial to date using brachytherapy.¹² These results, however, were obtained after coronary stenting in patients presenting with previous restenosis. Whether radiation of nonstented vessels would yield similar results remains to be determined. Indeed, the pathophysiology of restenosis after balloon angioplasty is different from that after coronary stenting and involves a combination of neointima formation and inadequate or deleterious vascular remodeling.¹³⁻¹⁸ Encouraging angiographic results have recently been reported with intracoronary β -radiation therapy after standard balloon angioplasty.¹⁹⁻²¹ Although angiography can determine the effect of β -radiation on luminal dimensions, assessment of its effects

on neointima formation and vessel remodeling required the use of intravascular ultrasound (IVUS).

The objective of this study was to assess the safety and efficacy of 3 different doses of intracoronary β -radiation therapy to alter the restenosis process after balloon coronary angioplasty. In particular, the effects of β -radiation on neointima formation and vascular remodeling after coronary angioplasty were examined by IVUS.

Methods

Patient Population

Patients between 18 and 80 years old with angina or proven ischemia on laboratory testing and scheduled to undergo standard balloon angioplasty of a single de novo lesion in a native coronary artery were eligible for inclusion in the study. The target lesions were to be <15 mm long and to have between 60% and 99% diameter stenosis by angiographic assessment.

Patients were excluded if there was (1) evidence of a myocardial infarction within 3 days before the procedure; (2) contraindication to aspirin; (3) prior chest radiotherapy; (4) life-threatening coexisting

Received July 23, 1998; revision received December 22, 1998; accepted December 29, 1998.

From the Montreal Heart Institute, Montreal, Canada (D.M., J.-C.T., A.A., M.J., G.L., R.B.); Emory University School of Medicine, Atlanta, Ga (I.R.C., S.B.K.); Rhode Island Hospital, Brown University, Providence, RI (D.O.W.); and the Thoraxcenter, Erasmus University Rotterdam, Netherlands (P.W.S.).

Correspondence to Raoul Bonan, MD, Montreal Heart Institute, 5000 Belanger St, Montreal, Quebec, Canada, H1T 1C8. E-mail icm3@connectmhc.net

© 1999 American Heart Association, Inc.

Circulation is available at <http://www.circulationaha.org>

illness; (5) severe peripheral vascular disease; (6) child-bearing potential; (7) anticipated difficulty with follow-up; (8) serum creatinine >2.0 mg/dL; (9) left ventricular ejection fraction $<40\%$; (10) unprotected left main coronary artery disease; (11) lesion angulation $>45^\circ$; (12) intraprocedural angiographic evidence of thrombus, spasm, or dissection; or (13) unsatisfactory PTCA result requiring stent implantation.

The trial was approved by the ethics committee at the Montreal Heart Institute. Written informed consent was obtained from each patient before enrollment and randomization in the trial.

Procedure

The patients were treated with aspirin 325 mg/d started ≥ 1 day before the procedure. An activated clotting time of ≥ 300 seconds was maintained throughout the procedure with intravenous heparin. Baseline coronary angiography and IVUS were performed before angioplasty. A 3.2F IVUS catheter (CardioVascular Imaging Systems) was advanced distal to the treated site to an easily recognizable landmark and withdrawn up to the guiding catheter with an automatic pullback device at a speed of 0.5 mm/s. Balloon angioplasty was then performed according to standard clinical practice. Procedural success was determined by angiography alone and was defined as a residual stenosis $<50\%$ 10 minutes after angioplasty, with an improvement in lumen diameter $>20\%$. After successful angioplasty, patients were randomized to receive 12, 14, or 16 Gy, as calculated at 2 mm from the center of the radiation source without regard to any curvature of the source train. A 5F delivery catheter (Novoste Corp) was correctly positioned at the angioplasty site with 2 radiopaque markers separated by 3 cm. The guidewire was removed from within the vessel, and a 3-cm-long train of $^{90}\text{Sr}/\text{Y}$ seeds was positioned between the aforementioned markers under fluoroscopic visualization. After irradiation, repeat angiography and IVUS examinations were performed. All cineangiograms and IVUS recordings were preceded by the administration of intracoronary nitroglycerin 0.3 mg.

ECGs were obtained immediately after the procedure and the following morning. Creatine kinase and MB fraction were measured before the procedure, at its completion, and 8 and 16 hours later. Patients were discharged the day after the procedure with instructions to take aspirin 325 mg/d indefinitely. Ticlopidine 250 mg twice daily was also given for 15 days if a stent was implanted.

β -Radiation Therapy System

The radiation system used in this study consisted of a series of 12 independent cylindrical seeds delivered as a train in a 5F noncentered catheter. Each seed is composed of radioactive materials ($^{90}\text{Sr}/\text{Y}$) sintered into ceramic and sealed within a cylindrical stainless steel capsule. The seeds are 2.5 mm long and 0.61 mm in diameter. The 12 seeds cover a length of 30 mm, allowing irradiation of the segments proximal and distal to the angioplasty site when a standard 20-mm balloon is used. The prescribed doses of 12, 14, and 16 Gy at 2 mm from the center of the catheter resulted in intracoronary dwell times of 158 to 218 seconds, based on dosimetric measurements as previously described.²¹ Post hoc estimation of delivered dose was performed in each case on the IVUS slice at the minimal lumen diameter (MLD). Measurements were made from the center of the IVUS catheter to the nearest and farthest points of the external elastic membrane (EEM). This allowed calculation of minimal and maximal doses of radiation delivered to the EEM at the MLD. Direct measurements of radiation exposure were performed and recorded by the radiation safety officer at different sites in the room during irradiation therapy.

Follow-Up

Patients were contacted by telephone monthly. Clinical assessment was performed every 3 months. Patients were readmitted for follow-up coronary angiography and IVUS examination 6 months after angioplasty. Those in whom angiography was performed for clinical reasons before the fifth month returned for another angio-

graphic and IVUS examination if there was no definite angiographic evidence of restenosis in the irradiated segment.

Quantitative Angiographic Analysis

Angiography was performed in 2 orthogonal projections before and after angioplasty. The same views were used after radiation therapy and at follow-up examination. Decisions regarding inclusion and procedural success were made by use of an online quantitative angiographic system (Electromed). All procedural and follow-up angiograms were forwarded to the Emory University Angiographic Core Laboratory for measurements by independent observers according to a previously validated method^{21,22} that provided the diameter of the reference segment and the MLD at baseline, after the procedure, and at follow-up. The acute gain (in millimeters) was defined as the MLD after angioplasty minus that before the intervention. Late luminal loss (millimeters) was defined as the reduction in MLD from the angiogram obtained after angioplasty to that obtained at follow-up. Loss index was defined as late luminal loss divided by the acute gain.

IVUS Analysis

IVUS recordings were performed on high-resolution S-VHS tape for offline analysis. All the images were interpreted by experienced technicians supervised by a cardiologist (J.C.T.) blinded to radiation dose. The IVUS studies were analyzed side by side. Great care was taken to ensure that the same and correct anatomic slice was measured in all IVUS studies. The fluoroscopic and angiographic images and audio commentary were used to determine the axial location of the ultrasound transducer and of IVUS landmarks relative to the angioplasty site and to side branches. The use of reproducible landmarks such as the aorto-ostial junction and a known pullback speed facilitated matching of the cross-sectional image. In addition, other IVUS landmarks (side branches, veins, calcifications, fibrotic deposits) were used to confirm matching of the anatomic slice in both studies by use of frame-by-frame review of the images. The cross section selected for serial analysis was the one at the angioplasty site with the smallest lumen area at follow-up. The corresponding slice was then identified on the postirradiation and preangioplasty study. The images were digitized and quantitative analysis was performed with custom-developed software for geometric computations (NIH Image 1.59). Quantitative analysis consisted of measurements of lumen area and the area within the EEM. The EEM was defined as the border between the hypochoic media zone and the surrounding echo-bright adventitia. Wall area was calculated as the difference between EEM and lumen areas. Percent cross-sectional area narrowing was also calculated as wall area times 100 divided by EEM area. When the plaque encompassed the IVUS catheter, the lumen area was assumed to be the size of the catheter.

Degree of calcification and dissection were defined by the degree of arc that they occupied, as previously described.²³

End Points and Statistical Analysis

The changes in lumen, wall, and EEM areas on IVUS were assessed in all patients who underwent both postirradiation and follow-up examinations and who did not require stent deployment. Binary angiographic restenosis was defined as diameter stenosis $\geq 50\%$ at the angioplasty site at follow-up. Other angiographic end points included late luminal loss and the loss index. Clinical end points were death, myocardial infarction, and target lesion revascularization. End points were assessed as early (index procedure to 1 week) and late (8 days until the 6-month angiographic follow-up).

Technical success of the radiation treatment was also assessed, as defined by the ability to pass the closed-end radiation catheter to the lesion site as verified by fluoroscopy, to transfer the radiation source to the distal end of the delivery catheter, and to return it to the transfer device.

All values are provided as proportions or as mean \pm SD. Comparisons of preprocedural with postprocedural and postprocedural with follow-up results were done with Wilcoxon signed rank test with 2-tailed test for significance. Comparison between groups that

TABLE 1. Baseline Clinical and Angiographic Characteristics of the 30 Randomized Patients

Patients, n	30
Age, y	57.4 (34–77)
Male, %	17 (56.7)
Unstable angina, %	7 (23.3)
Prior MI, %	12 (40)
Prior CABG, %	0
LVEF, %	59.7 \pm 2.0
Risk factors, %	
Diabetes mellitus	2 (6.7)
Hypercholesterolemia	15 (50)
Hypertension	12 (40)
Smoking history	26 (86.7)
Artery, %	
Left anterior descending	12 (40)
Circumflex	10 (33.3)
Right coronary artery	8 (26.7)
Lesion characteristics, %	
A	2 (7)
B1	14 (46)
B2	12 (40)
C	2 (7)

received different doses was performed by ANOVA. Statistical significance was indicated by a value of $P < 0.05$.

Results

Procedural and Early Clinical Outcome

A total of 32 patients were recruited between March and June 1997. Because of unsatisfactory angioplasty results requiring immediate stent implantation, 2 patients were not randomized to receive radiation therapy. Therefore, after successful angioplasty, 30 patients were randomized to receive doses of 12, 14, or 16 Gy and underwent intracoronary radiation therapy. The baseline clinical and angiographic characteristics of these patients are shown in Table 1. In 2 patients, baseline preangioplasty IVUS was not performed because, as a result of the severity of the stenoses, the IVUS catheter could not cross the lesion. The radiation catheter and seeds were deployed and the prescribed dose was delivered in all 30 patients, although in 1 patient, device advancement was limited by severe coronary calcification and the delivery catheter could not cover the entire lesion. The radiation therapy was well tolerated by all the patients, with no major complications during treatment. None of the treatments required fractionation, nor were any treatments interrupted prematurely. In 1 patient, a kink in the hydraulic system used for seed deployment occurred after overtightening of the Tuohy-Borst valve and prevented the return of the seeds to the protective housing. The entire system was immediately removed and deposited into the waiting Lucite radioprotective box, with no increased radiation exposure. In another patient, the distal gold marker was not retrieved into the protective housing at the completion of the procedure. All the

TABLE 2. Quantitative Coronary Angiographic Results

(n=30)	Preangioplasty	Postirradiation	Six-Month Follow-Up
Reference vessel	2.55 \pm 0.60	2.72 \pm 0.40	2.66 \pm 0.30
Diameter, mm			
MLD, mm	0.76 \pm 0.26	2.03 \pm 0.35*	2.05 \pm 0.49
Acute gain, mm		1.27 \pm 0.39	
Late luminal loss, mm			−0.02 \pm 0.60
Loss index			−0.09 \pm 0.46
Binary restenosis, %			3 (10)

* $P < 0.01$ vs preangioplasty.

radioactive seeds, however, were safely in the radioprotective housing. There were no significant acute radiation events.

Stent deployment was performed during the initial procedure in 2 of the 30 randomized patients, when major dissections induced by the initial angioplasty became evident only after radiation therapy. Two other patients underwent repeat angioplasty and stent deployment early after the first intervention. The first patient suffered acute vessel closure 8 hours after the initial angioplasty and irradiation, because of a dissection induced distal to the irradiated segment by the guidewire. The other patient presented with a non-flow-limiting dissection 1 week after the initial procedure and underwent repeat angioplasty and stent deployment because of chest pain, despite an unaltered angiographic appearance. There were no creatine kinase or ECG changes except in the patient with acute vessel closure, in whom a Q-wave myocardial infarction was diagnosed.

There was an increase in angiographic MLD from 0.76 \pm 0.26 mm before angioplasty to 2.03 \pm 0.35 mm after the procedure (Table 2). Postprocedural angiographic diameter stenosis was 25.2 \pm 9.9%. The mean minimal lumen area on IVUS increased from 2.49 \pm 1.27 mm² at baseline to 5.69 \pm 1.72 mm² after angioplasty and irradiation. EEM area increased from 12.35 \pm 5.14 to 13.71 \pm 4.54 mm², and wall area decreased from 9.87 \pm 5.08 to 8.01 \pm 3.85 mm², before and after treatment, respectively (Table 3).

Dosimetry and Environmental Exposure

The post hoc assessment of maximum and minimum distances to the EEM and subsequent calculated doses are presented in Figures 1 and 2. The mean maximal and minimal calculated doses at the EEM were 23.56 \pm 8.37 and 9.1 \pm 3.53 Gy, respectively. The mean radiation exposure in the ambient environment was 0.03 μ Sv/h during intracoronary therapy, with means of 18.9 \pm 10.0 and 1.6 \pm 1.2 μ Sv/h at the level of the patient's thorax and groin, respectively. Measurements performed at the level of the operator showed an exposure of 0.4 \pm 0.4 μ Sv/h.

IVUS, Angiographic, and Clinical Follow-Up

IVUS and angiographic follow-up data were obtained in all 30 patients. The mean time to follow-up examination was 178.1 \pm 33.4 days. Angiographic results (Table 2) demonstrated that there was no significant mean late luminal loss (−0.02 \pm 0.60 mm) or mean loss index (−0.09 \pm 0.46). Binary

TABLE 3. IVUS Results of 26 Nonstented Vessels

	Preangioplasty (n=24)†	Postirradiation (n=26)	Six-Month Follow-Up (n=26)
Lumen area, mm ²	2.49±1.27	5.69±1.72*	6.04±2.62*
EEM area, mm ²	12.35±5.15	13.71±4.54*	14.22±4.71*
Wall area, mm ²	9.87±5.08	8.01±3.85*	8.19±3.44*
CSAN, %	77.7±11.9	56.5±11.0*	57.5±14.1*
Calcification, n			
0	9	9	9
<120°	6	8	8
>120°	9	9	9
Dissections, n			
Nil	...	10	19
<90°	...	5	5
91°–180°	...	9	2
181°–270°	...	2	0

CSAN indicates cross-sectional area narrowing.

* $P<0.001$ vs preangioplasty.

†In 2 patients, the lesion was not crossed before angioplasty.

angiographic restenosis occurred in 3 of the 30 randomized patients (10%). Restenosis was present at follow-up in 1 of the 4 randomized patients initially treated with a stent (at the proximal and distal shoulders) and in 2 of the other 26 patients with successful angioplasty but without stent deployment.

IVUS measurements of the 26 patients without stent implantation (Table 3) revealed no reduction in mean minimal lumen area between the period immediately after the procedure (5.69 ± 1.72 mm²) and the follow-up examination (6.04 ± 2.63 mm²) (Figure 3). There was no significant change in mean EEM area between the two examinations (13.71 ± 4.54 versus 14.23 ± 4.71 mm²) (Figure 3). Wall area was 8.02 ± 3.85 mm² after radiation therapy and 8.18 ± 3.44 mm² at follow-up. Percent cross-sectional area narrowing was also unchanged over the 6-month follow-up period ($56.5\pm11.0\%$ to $57.5\pm14.1\%$).

IVUS allowed detection of dissections after the initial procedure in 16 of the 26 patients who did not undergo stenting during the study. Nine of these 16 dissections had resolved at follow-up. There was no correlation between persistent dissections and prescribed dose or measured dose delivered. No coronary aneurysms were detected, and no obvious effect on arterial wall calcification was noted.

There were no deaths, myocardial infarctions, or CABG during the follow-up period. Recurrent angina occurred in 6 of the 30 patients between 8 days and 6 months after the initial procedure. Three patients underwent repeat PTCA for angiographic restenosis at the same site. Two of these were at the site of the previous MLD, with the third demonstrating restenosis at both the proximal and distal shoulders of the implanted stent and irradiated region. Three other patients underwent PTCA for progression of coronary artery disease at other sites in the same (2) or another (1) vessel. Target lesion and vessel revascularization was therefore performed in 3 and 5 of the 30 patients, respectively.

There were no significant differences of IVUS, angiographic, or clinical parameters between different prescribed dose groups or measured dose delivered, as assessed by ANOVA.

Discussion

Endovascular radiotherapy has recently emerged as a promising treatment for the prevention of restenosis.^{1–3} In the only randomized clinical trial to date, Teirstein et al¹² obtained favorable results using γ -radiation (¹⁹²Ir) after coronary stenting in patients with previous restenosis. Intracoronary β -radiation therapy after standard balloon angioplasty has now also been shown to have beneficial results.^{19–21}

IVUS and Restenosis

The pathophysiology of coronary restenosis after standard balloon angioplasty is different from that after stent deployment. Indeed, data from several studies indicate that lumen loss after balloon angioplasty is caused by the combination of neointima formation and inadequate or deleterious vessel remodeling.^{13–18} In contrast, it is now well known that restenosis after coronary stenting is caused almost entirely by tissue hyperplasia.^{24–26} Changes in the arterial wall after radiotherapy could not be described by Teirstein et al because of the systematic use of coronary stents in their study. The minimal use of stents in this IVUS study allowed the assessment of β -radiation effects on neointima formation and vascular remodeling after balloon angioplasty.

There was no significant change in EEM area and no lumen area loss during the follow-up period in our patients. It has already been demonstrated that vessel enlargement may occur after balloon angioplasty to accommodate tissue hyperplasia.¹⁴ Thus, the absence of a significant increase in EEM area may reflect the adequate inhibition of neointima forma-

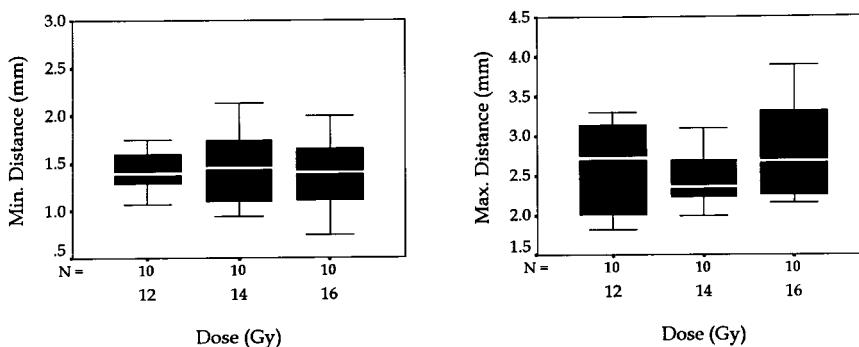


Figure 1. Maximum and minimum measured distances to EEM as measured at MLD for each prescribed dose.

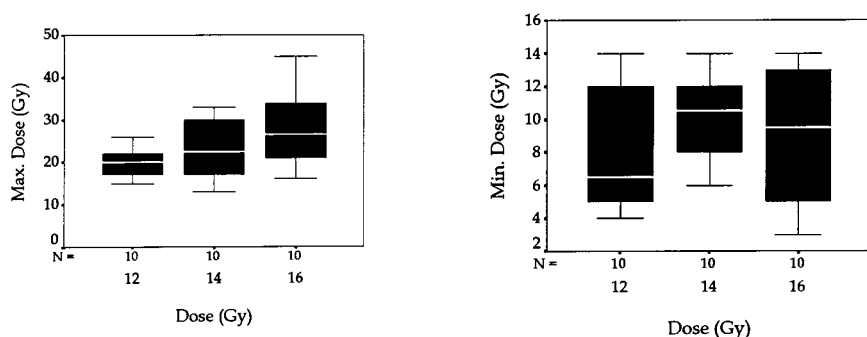


Figure 2. Maximum and minimum calculated doses administered to EEM for each prescribed dose.

tion by radiotherapy. It is nevertheless of interest to note that mean EEM area did not decrease, indicating that on average there was no vessel contraction during the follow-up period.

The inhibition of neointima formation observed suggests that β -radiation therapy resulted in an impairment of smooth muscle cell proliferation and a reduction in extracellular matrix accumulation. Our results are in agreement with recent animal studies that have shown that local radioactivity may effectively control neointima formation after angioplasty.⁴⁻¹¹ The inhibitory effect of β -radiation on neointima formation contrasts with the mechanism of action of the antioxidant probucol in the prevention of restenosis. Indeed, it has been demonstrated that probucol exerts its antirestenotic effect by

improving vascular remodeling, ie, by enhancing compensatory vessel enlargement to accommodate neointima formation.¹⁴

Dissection Outcome

A total of 7 dissections remained open at follow-up, of the 16 that were originally observed immediately after angioplasty and irradiation. Although not specifically reported with IVUS, dissections are usually healed 6 months after angioplasty. Animal studies have demonstrated that most healing is complete at 7 days.^{27,28} The impairment of wound healing after β -radiation therapy appears to be only partial, with maintenance of the ability to close the majority of dissections. This may vary with the specific dose delivered to the dissection site; however, no correlation was found between persistence of dissection and the dose prescribed. Nevertheless, recommendation of the systematic use of stents for dissections after angioplasty and irradiation does not appear to be warranted at this stage.

Study Limitations

This study was small and not placebo-controlled. In addition, the doses of β -radiation delivered were not assessed at the time of source deployment and may have varied from the prescribed dose at 2 mm with theoretical maximum and minimum doses of 55 and 4 Gy at the lumen surface, respectively.²¹ Quantitative IVUS data were restricted to 2-dimensional analysis to determine effects at the site of MLD at follow-up. Three-dimensional analysis could potentially provide more information regarding response of the total irradiated vessel segments. Finally, the follow-up period reported here was relatively short in view of the long-term safety considerations associated with radiation therapy. Longer-term clinical follow-up will be performed and angiographic and IVUS examinations will be repeated 2 years after irradiation. Large randomized clinical trials have been initiated to evaluate the long-term safety and efficacy of β -radiation in reducing restenosis after coronary angioplasty.

Conclusions

This pilot study demonstrates the short- to mid-term safety and efficacy of this noncentered 5F device for delivering β -radiation to the vessel wall after angioplasty. By IVUS, intracoronary β -radiation has been demonstrated to inhibit neointima formation with no reduction of total vessel area at 6-month follow-up.

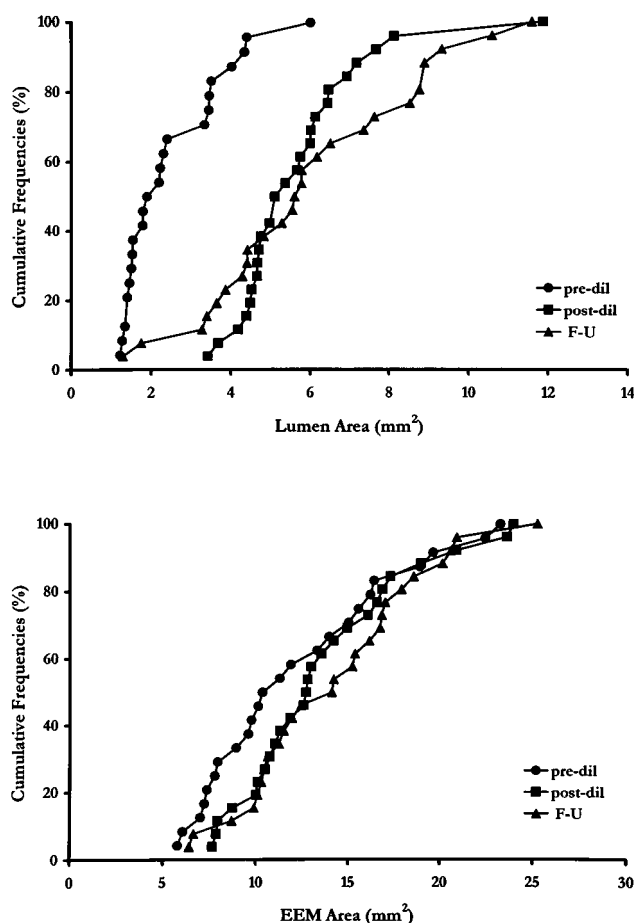


Figure 3. Cumulative distribution curves of lumen and EEM areas as measured by IVUS. Dil indicates dilatation; F-U, follow-up.

Acknowledgments

Dr Tardif is a clinical investigator of the Fonds de Recherche en Santé du Québec. Dr Meerkin is a clinical and research fellow of the Fonds de Recherche en Santé du Québec and a recipient of a fellowship from the American Physicians Fellowship for Medicine in Israel. The authors are indebted to Joanne Vincent for assistance in IVUS analysis.

References

- van der Giessen WG, Serruys PW. β -Particle-emitting stents radiate enthusiasm in the search for effective prevention of restenosis. *Circulation*. 1996;94:2358–2360.
- Condado JA, Waksman R, Gurdziel O, Espinosa R, Gonzalez J, Berger B, Villoria G, Acquatella H, Crocker IR, Seung KB, Liprie SF. Long-term angiographic and clinical outcome after percutaneous transluminal coronary angioplasty and intracoronary radiation therapy in humans. *Circulation*. 1997;96:727–732.
- Bertrand OF, Mongrain R, Lehnert S, Bilodeau L, Tanguay J-F, Laurier J, Côté G, Bourassa MG. Intravascular radiation therapy in atherosclerotic disease: promises and premises. *Eur Heart J*. 1997;17:1385–1395.
- Waksman R, Robinson KA, Crocker IR, Gravanis MB, Cipolla GD, King SB III. Endovascular low-dose irradiation inhibits neointima formation after coronary artery balloon injury in swine. *Circulation*. 1995;91:1533–1539.
- Carter AJ, Laird JR, Bailey LR, Hoopes TG, Farb A, Fischell DR, Fischell RE, Fischell TA, Virmani R. Effects of endovascular radiation from a β -particle-emitting stent in a porcine coronary restenosis model. *Circulation*. 1996;94:2364–2368.
- Laird JR, Carter AJ, Kufs WM, Hoopes TG, Farb A, Nott SH, Fischell RE, Fischell DR, Virmani R, Fischell TA. Inhibition of neointimal proliferation with low-dose irradiation from a β -particle-emitting stent. *Circulation*. 1996;93:529–536.
- Hehrlein C, Gollan C, Donges K, Metz J, Riessen R, Fehsenfeld P, von Hohenberg E, Kubler W. Low-dose radioactive endovascular stents prevent smooth muscle cell proliferation and neointimal hyperplasia in rabbits. *Circulation*. 1995;92:1570–1575.
- Waksman R, Robinson KA, Crocker IR, Wang C, Gravanis MB, Cipolla GD, Hillstead RA, King SB III. Intracoronary low-dose β -irradiation inhibits neointima formation after coronary artery balloon injury in the swine restenosis model. *Circulation*. 1995;92:3025–3031.
- Verin V, Popowski Y, Belenger J, Redard M, Costa M, Widmer M-C, Rouzaud M, Nouet P, Grob E, Schwager M, Kurtz JM, Rutishauser W. Intra-arterial β -irradiation prevents neointimal hyperplasia in a hypercholesterolemic rabbit restenosis model. *Circulation*. 1995;92:2284–2290.
- Weiderman JG, Marboe CH, Amols H, Schwartz A, Weinberger J. Intracoronary irradiation markedly reduces restenosis after balloon angioplasty in a porcine model. *J Am Coll Cardiol*. 1994;23:1491–1498.
- Weiderman JG, Leavy JA, Amols H, Schwartz A, Homma S, Marboe C, Weinberger J. Effects of high dose intracoronary irradiation on vasomotor function and smooth muscle histopathology. *Am J Physiol*. 1994;36:H125–H132.
- Teirstein PS, Massullo V, Jani S, Popma JJ, Mintz GS, Russo RJ, Schatz RA, Guarneri EM, Steurtamen S, Morris NB, Leon MB, Tripuraneni P. Catheter-based radiotherapy to inhibit restenosis after coronary stenting. *N Engl J Med*. 1997;336:1697–1703.
- Mintz GS, Popma JJ, Pichard AD, Kent KM, Satler LF, Wong C, Hong MK, Kovach JA, Leon MB. Arterial remodeling after coronary angioplasty: a serial intravascular ultrasound study. *Circulation*. 1996;94:35–43.
- Côté G, Tardif J-C, Lespérance J, Lambert J, Bourassa M, Bonan R, Gosselin G, Joyal M, Tanguay J-F, Nattel S, Gallo R, Crépeau J. Effects of probucol on vascular remodeling after coronary angioplasty. *Circulation*. 1999;99:30–34.
- Kakuta T, Currier JW, Haudenschild CC, Ryan TJ, Faxon DP. Differences in compensatory vessel enlargement, not intimal formation, account for restenosis after angioplasty in the hypercholesterolemic rabbit model. *Circulation*. 1994;89:2809–2815.
- Gertz SD, Gimple LW, Banai S, Ragosta M, Powers ER, Roberts WC, Perez LS, Sarembock IJ. Geometric remodeling is not the principal pathogenetic process in restenosis after balloon angioplasty: evidence from correlative angiographic-histomorphometric studies of atherosclerotic arteries in rabbits. *Circulation*. 1994;90:3001–3008.
- Lafont A, Guzman LA, Whitlow PL, Goormastic M, Cornhill JF, Chisholm GM. Restenosis after experimental angioplasty: intimal, medial, and adventitial changes associated with constrictive remodeling. *Circ Res*. 1995;76:996–1002.
- Post MJ, Borst C, Kuntz RE. The relative importance of arterial remodeling compared with intimal hyperplasia in lumen narrowing after balloon angioplasty. *Circulation*. 1994;89:2816–2821.
- Meerkin D, Bonan R, Tardif J-C, Arsenault A, Tanguay J-F, Joyal M, Crépeau J, Gosselin G, Lucier G. Reduction of hyperplastic response following balloon angioplasty by β -radiation. *J Am Coll Cardiol*. 1998;31(suppl):222A. Abstract.
- Meerkin D, Bonan R, Crocker IR, Arsenault A, Chougule P, Coen V, Williams DO, Serruys P, King SB III. Efficacy of beta radiation in prevention of post-angioplasty restenosis: an interim report from the Beta Energy Restenosis Trial. *Herz*. 1998;23:356–361.
- King SB III, Williams DO, Chougule P, Klein JL, Waksman R, Hilstead R, Macdonald J, Anderberg K, Crocker IR. Endovascular β -radiation to reduce restenosis after coronary balloon angioplasty: results of the Beta Energy Restenosis Trial (BERT). *Circulation*. 1998;97:2025–2030.
- Klein JL, Manoukian SV, Vogel RA, Beauman GJ, Savage MP, Boccuzzi SJ, Weintraub WS, for the Lovastatin Restenosis Trial Group. Computerized quantitative coronary arteriography: performance standards and edge detection. *Am J Cardiol*. 1996;77:815–822.
- Jain SP, Jain A, Collins TJ, Ramee SR, White CJ. Predictors of restenosis: a morphometric and quantitative evaluation by intravascular ultrasound. *Am Heart J*. 1994;128:664–673.
- Dussaillant GR, Mintz GS, Pichard AD, Kent KM, Satler LF, Popma JJ, Wong SC, Leon MB. Small stent size and intimal hyperplasia contribute to restenosis: a volumetric intravascular ultrasound analysis. *J Am Coll Cardiol*. 1995;26:720–724.
- Hoffman R, Mintz GS, Dussaillant GR, Popma JJ, Pichard AD, Satler LF, Kent KM, Griffin B, Leon MB. Patterns and mechanisms of in-stent restenosis: a serial intravascular ultrasound study. *Circulation*. 1996;94:1247–1254.
- Gershlick AH, Baron J. Dealing with in-stent restenosis. *Heart*. 1998;79:319–323.
- Wilensky RL, March KL, Gradus-Pizlo I, Sandusky G, Fineberg N, Hathaway DR. Vascular injury, repair, and restenosis after percutaneous transluminal angioplasty in the atherosclerotic rabbit. *Circulation*. 1995;92:2995–3005.
- Wilensky RL, Gradus-Pizlo I, Sandusky G, March KL. Vascular repair mechanisms after directional atherectomy or percutaneous transluminal coronary angioplasty in atherosclerotic rabbit iliac arteries. *Am Heart J*. 1996;132:13–22.