

Therapeutic Window for Use of Hyperbaric Oxygenation in Focal Transient Ischemia in Rats

Min Lou, MD; Christoph C. Eschenfelder, MD; Thomas Herdegen, MD;
Stephan Brecht, MD; Günther Deuschl, MD

Background and Purpose—Hyperbaric oxygenation (HBO) is an attractive procedure that has been used frequently in cerebral ischemia. However, depending on the model of cerebral ischemia and HBO protocol, different and conflicting results were obtained in the past. This study was undertaken to reevaluate the effects of single administration of HBO in 2 models of acute cerebral ischemia: transient or permanent focal ischemia in rats. A comparison of the 2 ischemia models was undertaken to search for a putative therapeutic window.

Methods—The intraluminal middle cerebral artery occlusion model (MCAO) was used. The effect of single HBO therapy (3 atm absolute, 60 minutes) on transient or permanent focal ischemia, when applied at different times (3, 6, or 12 hours) after MCAO, was investigated; infarct volume and neurological deficits were assessed at 24 hours and up to 7 days.

Results—HBO had neuroprotective effects on transient MCAO when HBO was initiated within the first 6 hours, while it aggravated the ischemic injury histologically and clinically when initiated 12 hours after MCAO. In permanent MCAO, HBO did not reduce tissue damage regardless of the timing of therapy.

Conclusions—HBO is highly efficient in reducing infarct volume and improving neurobehavioral outcome in transient MCAO within the first 6 hours. HBO at later time points (≥ 12 hours) is harmful by increasing infarct volume. In permanent MCAO, HBO failed to improve infarct volume and clinical outcome. (*Stroke*. 2004;35:578-583.)

Key Words: animal models ■ cerebral infarction ■ hyperbaric oxygenation ■ ischemia
■ middle cerebral artery occlusion ■ outcome ■ time factors ■ rats

Improving tissue oxygenation in stroke is one of the most important treatment strategies. Hyperbaric oxygenation (HBO) in a pressure chamber dramatically increases the oxygen content of blood by physically dissolving oxygen.^{1,2} In mammals, the increased oxygen content of the blood is then released passively in the ischemic tissue and can theoretically penetrate to deeper and more poorly perfused ischemic areas than under normobaric conditions.³ Thus, HBO appears to be an attractive procedure for use in cerebral ischemia.

In the past, several studies have addressed the question of whether HBO might be beneficial in the treatment of acute ischemic stroke in mammals.⁴ However, it is impossible to compare these studies because different stroke models (global ischemia, permanent focal ischemia, or transient focal ischemia) in different species (dogs,⁵ cats,⁶ and rats^{7,8}) have been used to study the effect of HBO. Furthermore, the definition of end points differs among the studies. A traditional method is to define infarct volume as an end point, which is usually achieved by histological analysis. Currently, modern MRI techniques are used to define tissue damage either by replac-

ing histological infarct volumetry⁹ or by comparing histological analysis determined with MRI infarct volume.¹⁰ Other studies use survival rate¹¹ or neurological deficit as primary end points.⁶ In addition, the timing of HBO treatment as well as the HBO protocols varies greatly among the studies, making a comparison of the results more difficult. It is thus not surprising that of the numerous publications in that field, one can find “good evidence” that HBO is or is not beneficial in the treatment of acute stroke in mammals.

Because of these conflicting results, we reevaluated the effects of single administration of HBO in 2 models of acute cerebral ischemia: transient or permanent focal ischemia induced by middle cerebral artery (MCA) occlusion (MCAO) in rats. In each MCAO group, 2 primary end points were to be evaluated: infarct volume, as determined by histological methods, and clinical outcome. It was considered important to compare the 2 models of cerebral ischemia in 1 laboratory to obtain comparable results within the 2 models and to avoid comparison of interlaboratory differences. The study design was chosen to be comparable regarding the ischemia model and the HBO protocol to other, previously published studies

Received June 13, 2003; final revision received October 1, 2003; accepted October 20, 2003.

From the Departments of Neurology (M.L., C.C.E., G.D.) and Pharmacology (T.H., S.B.) Christian-Albrechts University of Kiel, Kiel, Germany, and Department of Neurology, Second Affiliated Hospital, Zhejiang University, Hangzhou, Peoples Republic of China (M.L.).

Drs Lou and Eschenfelder contributed equally to this work.

Correspondence to Christoph Cyrill Eschenfelder, MD, Department of Neurology, Christian-Albrechts University of Kiel, Niemannsweg 147, D-24105 Kiel, Germany. E-mail c.eschenfelder@neurologie.uni-kiel.de

© 2004 American Heart Association, Inc.

Stroke is available at <http://www.strokeaha.org>

DOI: 10.1161/01.STR.0000111599.77426.A0

of transient or permanent MCAO treated with HBO.^{12–14} This study did not seek to elucidate putative neuroprotective or harmful mechanisms of HBO in acute focal cerebral ischemia in rats.

Materials and Methods

Study Design

The local ethics committee approved all experimental protocols. Male Sprague-Dawley rats (weight, 200 g) were used (Charles River, Germany). They were kept under controlled conditions. Animals were randomly assigned to the following groups ($n=10$ in each group). For transient ischemia, animals underwent MCAO for 90 minutes in each of the following subgroups: group A₁, control group, room air, chloral hydrate anesthesia (400 mg/kg body wt) 3 hours after MCAO; group A₂, control group, room air, anesthesia 6 hours after MCAO; group A₃, control group, room air, anesthesia 12 hours after MCAO; group B, HBO starting 3 hours after MCAO; group C, HBO starting 6 hours after MCAO; and group D, HBO starting 12 hours after MCAO. For permanent ischemia, animals were randomized to the following groups: group E, room air; group F, HBO starting 3 hours after MCAO; and group G, HBO starting 6 hours after MCAO. The animals, deeply anesthetized by cardiac perfusion for infarct volumetry, were killed 24 hours or 7 days after onset of transient or permanent MCAO.

Monitoring of Physiological Parameters

Physiological parameters (rectal temperature, arterial pH, PCO₂, PO₂, hemoglobin, hematocrit, glucose, potassium, sodium, calcium, and chloride) were monitored in each group. A polyethylene catheter (pp-50) was inserted through the femoral artery into the abdominal aorta under chloral hydrate (400 mg/kg body wt IP) anesthesia 2 days before MCAO. Blood samples were taken (1) before ischemia, (2) 30 minutes after ischemia, (3) 30 minutes before HBO treatment, and (4) 60 minutes after HBO treatment and analyzed (Radiometer ABL 700).

Transient MCAO

Animals were anesthetized with chloral hydrate (400 mg/kg body wt IP) for all surgical procedures. During surgery, each rat was allowed to breathe spontaneously, and rectal temperature was maintained at 37°C with the use of a heating pad. The right MCA was occluded for 90 minutes with subsequent reperfusion according to the method of Longa et al.¹⁵ Animals that did not demonstrate a significant reduction of regional cerebral blood flow (rCBF) during MCAO or rapid restoration of the laser-Doppler signal during reperfusion were excluded from the study.

Permanent MCAO

The same protocol as described above was used for permanent ischemia. However, for permanent ischemia, the nylon filament was fixed at the external carotid artery by a tight ligature and left in position until the end of the experiments.

Measurement of rCBF

Laser-Doppler flowmetry (Periflux, Perimed) was used to monitor rCBF before, during, and after transient or permanent MCAO. Flow values were recorded every 10 minutes. The area selected for cerebral blood flow (CBF) monitoring corresponded to the MCA territory.

Hyperbaric Oxygenation

HBO was performed in an experimental pressure chamber. During HBO administration, animals could be observed through the transparent acrylic glass. HBO was administered at a pressure of 3 atm absolute (3 ATA) for 1 hour with 100% oxygen, starting at 3 hours (groups B and F), 6 hours (groups C and G), and 12 hours (group D) after MCAO. Arterial blood samples were obtained from a femoral artery catheter for blood gas analysis in the anesthetized animals

during HBO administration without discontinuation of HBO. Compression and decompression were achieved within 5 minutes. After HBO, the femoral artery catheter was removed. The 3 control groups (A₁ to A₃) received the same dose of anesthesia corresponding to time points of HBO. Temperature inside the chamber and rectal temperature were continuously monitored.

Infarct Volume Calculation

Twenty-four hours or 7 days after MCAO, rats were deeply anesthetized with chloral hydrate (400 mg/kg) and perfused intracardially with the use of standard protocols. The entire brain was cut into coronal frozen sections (40 μ m). Every 20th slice of the brain was mounted on a glass slide and stained with cresyl violet. In total, 14 sections of each brain were stained and analyzed. Sections were digitalized with the use of a scanner and analyzed by a blinded investigator using ImageJ (National Institutes of Health). To eliminate brain edema, the corrected infarct volume was calculated as described in detail by Schäbitz et al.¹⁶

Evaluation of Neurological Deficits

The neurological status of each rat was evaluated daily for 7 days after MCAO by a blinded observer. Two neurological grading systems were used to assess the effects of MCAO and HBO: the Bederson score¹⁷ and the Garcia score.¹⁸

Statistical Analysis

Statistical analysis was performed with the use of 1-way ANOVA and the post hoc Bonferroni test for pairwise comparisons if a significant difference was found. A probability value <0.05 was considered significant.

Results

Physiological Parameters

HBO increased arterial PO₂ values rapidly out of the range of detection; PCO₂ remained in a normal range over a 60-minute exposure to HBO. All other physiological parameters (particularly temperature and glucose) remained within the normal range and were not significantly different between the groups. HBO did not alter the temperature inside the pressure chamber, nor did HBO change the body temperature of the animals during HBO (data not shown).

Regional Cerebral Blood Flow

In transient MCAO, an immediate decrease of the blood flow displayed the correct position of the filament at the origin of the MCA. The low blood flow was maintained at approximately 20% of the preischemic baseline level during cerebral ischemia (mean \pm SD, 20.61 \pm 2%). After withdrawal of the filament, the blood flow increased, followed by persistent hypoperfusion (approximately 70% to 80% of baseline) until the end of the recording period (mean \pm SD, 76.82 \pm 3.12%). No significant difference in rCBF was seen between HBO-treated and untreated rats. For permanent cerebral ischemia, the blood flow was maintained at approximately 20% of the baseline until the end of the experiment. In these groups rCBF was not significantly different.

Neurological Evaluation

At baseline, the neurological status was equal between the groups. In transient MCAO, early HBO administration resulted in an improved outcome. With the use of the Garcia grading system, HBO treatment both 3 and 6 hours after MCAO significantly improved the neurological outcome in

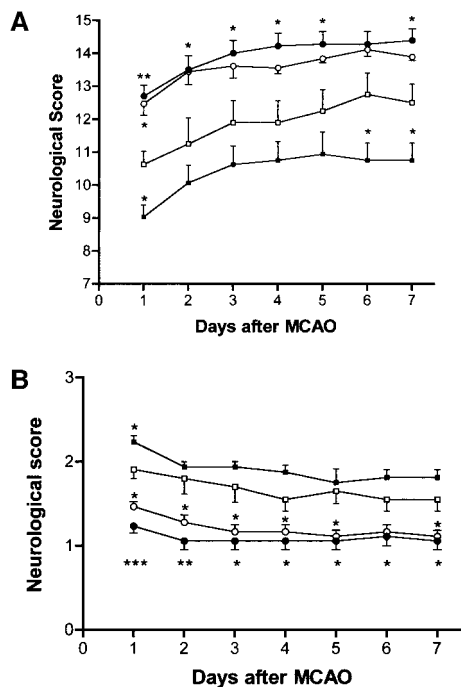


Figure 1. Neurological scores after transient MCAO assessed over a 7-day period. A, According to the Garcia grading system, both the 3- and 6-hour treatment groups exhibited significantly improved neurological function (higher score). In contrast, the neurological deficit was increased after HBO treatment at 12 hours after ischemia. B, According to the Bederson grading system, treatment with HBO 3 hours after cerebral ischemia improved neurobehavioral outcome (lower score), while HBO treatment 12 hours after ischemia significantly worsened neurological outcome. Open squares indicate control; filled circles, 3-hour HBO; open circles, 6-hour HBO; and filled circles, 12-hour HBO. Values are mean \pm SEM.

rats subjected to transient MCAO. This effect persisted over the observation period of 7 days. A significant worsening of the neurological score was detected when HBO treatment was started 12 hours after MCAO (Figure 1A). With the use of the Bederson score, treatment with HBO 3 hours after cerebral ischemia showed an improved neurobehavioral outcome, while a worse outcome was detected in rats treated with HBO 12 hours after MCAO (Figure 1B). In permanent MCAO, no significant difference could be detected between the HBO-treated or control groups with the use of the 2 grading systems (Figure 2).

Infarct Volumetry

Transient MCAO

Infarct volume was analyzed 24 hours or 7 days after MCAO. Tissue sections stained with cresyl violet showed a reproducible infarct zone involving the frontoparietal neocortex, caudate putamen, and globus pallidus in control animals. Between the 3 control groups, no difference in infarct volume was detected 24 hours after MCAO: A₁, 191 \pm 31 mm³; A₂, 195 \pm 36 mm³; A₃, 198 \pm 43 mm³. Thus, only 1 control group is shown in Figure 3. At 24 hours after MCAO, a significant reduction of infarct volume was found when administration of HBO took place 3 or 6 hours after transient MCAO. Total infarct volume was reduced by 70% (mean, 191 \pm 31 mm³

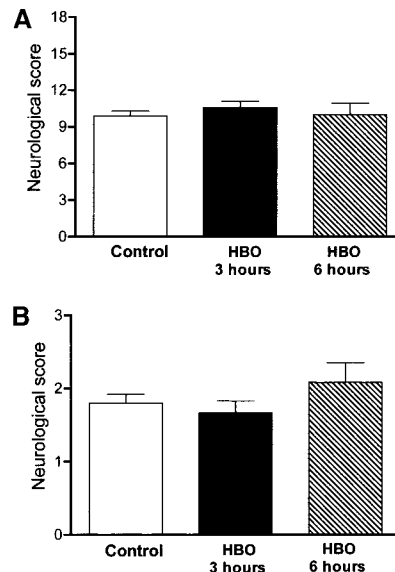


Figure 2. In the permanent ischemia group, no significant differences were detected at 24 hours according to the grading systems of Garcia (A) and Bederson (B).

[group A₁] versus 57 \pm 19 mm³ [group B]; $P < 0.01$) at 3 hours and 44% (mean, 107 \pm 35 mm³ [group C]; $P < 0.01$) after 6 hours (Figure 3, left). Cortical infarct volume was reduced by 91% (mean, 122 \pm 19 mm³ [group A₁] versus 11 \pm 10 mm³ [group B]; $P < 0.01$) at 3 hours and 51% (mean, 60 \pm 35 mm³ [group C]; $P < 0.01$) after 6 hours (Figure 3, left). Striatal infarct volume was reduced up to 33% (mean, 69 \pm 16 mm³ [group A₁] versus 46 \pm 16 mm³ [group B]; $P < 0.05$) at 3 hours and 30% (mean, 48 \pm 19 mm³ [group C]; $P < 0.05$) after 6 hours (Figure 3, left). However, infarct volume in the cortex was significantly increased by 32% in rats treated with HBO 12 hours after MCAO (152 \pm 32 mm³ [group D]; $P < 0.05$) compared with control [group A₁]. Total infarct volume was increased when HBO was initiated 12 hours after ischemia (224 \pm 38 mm³ [group D]) but did not reach significance (Figure 3, left).

Histological analysis of the brain sections obtained 7 days after MCAO confirmed the neuroprotective effect of early HBO administration. Total infarct volume was reduced by 54% in the 3-hour HBO group and 52% in the 6-hour HBO group. Infarct volume was increased by 27% in the 12-hour HBO group (Figure 4).

Permanent MCAO

Infarct volumetry 24 hours after permanent MCAO revealed reproducible large infarcts. Quantitative analysis showed that the infarct volume in both cortex and subcortical area was not significantly different in the rats receiving HBO treatment and controls (Figure 3, right). Total infarct volume was 264 \pm 59 mm³ (group E), 243 \pm 43 mm³ (group F), and 206 \pm 80 mm³ (group G). Additionally, subanalysis of cortical and striatal infarct volume did not show significant differences. Therefore, experiments with permanent MCAO were stopped after infarct volumes were analyzed. It was assumed that HBO administration in permanent MCAO at a later time point would again fail to induce a reduction of infarct volume.

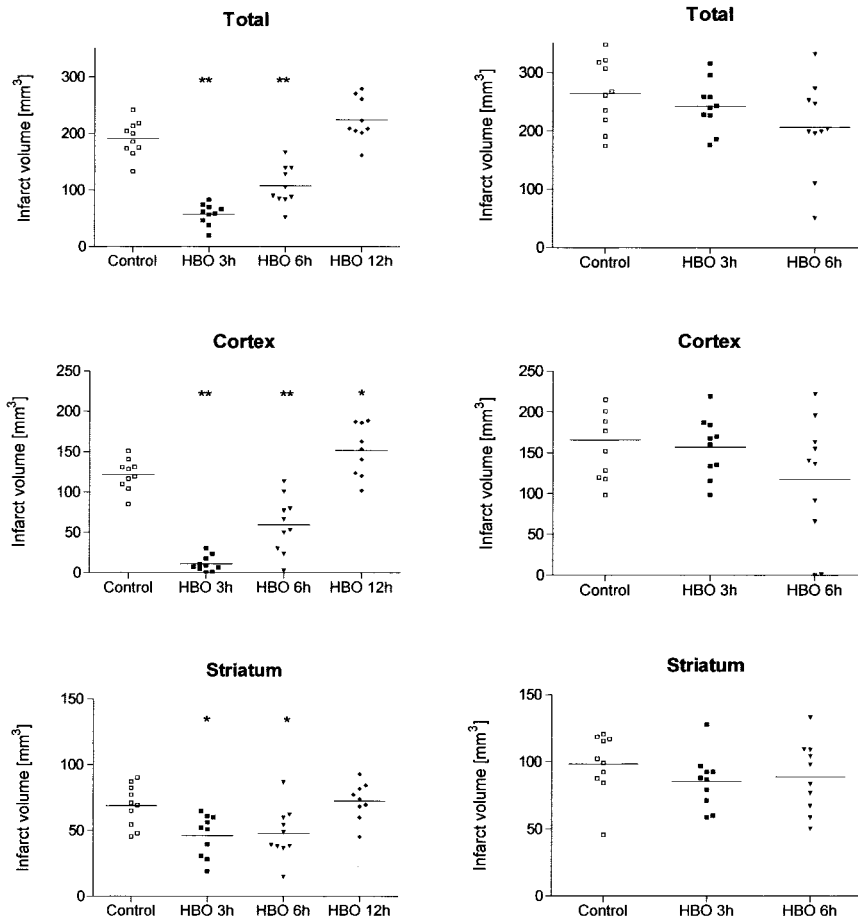


Figure 3. Infarct volumetry assessed 24 hours after MCAO. Left, Transient MCAO; right, permanent MCAO. Total (hemispheric), cortical, and subcortical (striatal) infarct volumes are displayed separately. Data are presented as a scatter dot blot showing each individual value (n=10 per group) and mean (bar). **P*<0.05, ***P*<0.01.

Discussion

Our study continued and extended the current knowledge of HBO in acute focal cerebral ischemia. The primary end points of the study were the evaluation of 2 different ischemia models (transient and permanent MCAO) treated with HBO to search for a putative therapeutic window and to compare the neurological outcome with histological findings.

The main finding of our study is the long-lasting beneficial effect of HBO on infarct volume reduction and improvement of clinical outcome in a time-dependent manner in the model of transient MCAO in the rat. Our results demonstrate that animals treated within the first 6 hours after transient MCAO have a significantly improved neurobehavioral outcome, which is strongly related to decreased infarct size for up to 7 days. This finding is in accordance with a previously published and comparable study by Badr et al,¹² in which HBO administration within the first 6 hours after transient MCAO led to a reduction of infarct volume, which was accompanied by an improvement of clinical outcome in rats. However, in the present study we extended the results found by Badr et al by investigating the effect of HBO over a period of 7 days and in 2 different models of ischemia, combined with a more detailed analysis of infarct volume.

It was important for our study to simultaneously investigate transient and permanent MCAO to achieve reproducible infarcts in the animals. Our internal control did not indicate the occurrence of methodological errors while MCAO was

performed because of the good reproducibility of the infarcts in both models. Insufficient MCAO and inadvertent subarachnoid hemorrhage are the most common complications of the intraluminal thread model. Previous researchers have demonstrated that monitoring of rCBF by laser-Doppler flowmetry in the cerebral cortex supplied by MCA is indispensable to monitor adequate MCAO and is highly sensitive in recognizing subarachnoid hemorrhage. Successful cerebral ischemia was confirmed by an immediate decrease in ipsilateral CBF in the MCA territory to 20% to 30% of baseline and an abrupt increase in blood flow to approximately 70% of baseline after the monofilament was drawn.¹⁹ In the present study our rCBF measurement data showed a reduction of rCBF in all groups to approximately 20% of baseline during MCAO, indicating the fulfillment of the requested standard.

The putative interference of anesthesia used in our experiments with either neuroprotection or worsening of the injury seen at 12 hours after transient MCAO was carefully considered and investigated. Control groups were treated with the same dose of chloral hydrate as the treatment groups after MCAO at corresponding time points. Thus, the influence of anesthesia used in the present study does not seem to account for the presented results.

Our infarct volumetry displays more information than previously published studies because of the subanalysis of total infarct volume compared with cortical and striatal infarct volume and because of the infarct volumetry per-

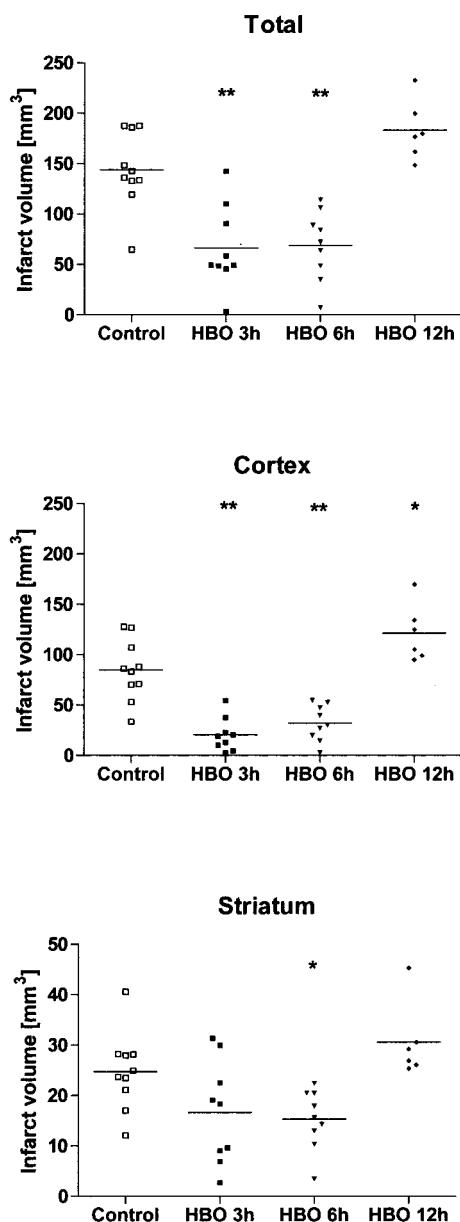


Figure 4. Infarct volumetry obtained 7 days after transient MCAO. Total (hemispheric), cortical, and subcortical (striatal) infarct volumes are displayed separately. Data are presented as a scatter dot blot showing each individual value ($n=10$ for control, 3-hour HBO, and 6-hour HBO; $n=6$ for 12-hour HBO) and mean (bar). * $P<0.05$, ** $P<0.01$.

formed 7 days after MCAO. As shown, reduction of infarct volume was most prominent in the cortical areas and less prominent in the deeper striatal areas. The spatial pattern of tissue salvage induced by HBO suggests that after reperfusion, HBO is able to rescue the still viable though nonfunctioning tissues in the outer areas of the infarct, which are anatomically better supplied by pial collaterals than the infarct core. Thus, early HBO administration may stop the process of ischemic infarct growth by rapidly restoring oxygen and energy to the ischemic but still viable tissue.²⁰ The infarct core, however, experienced a severe ischemic injury during transient MCAO and usually is irreversibly

damaged within minutes.²¹ Thus, reperfusion and HBO treatment are not sufficient to restore all cell function and survival in the core. It may be speculated that the neuroprotective effect of early HBO administration is related to an improved and rapid energy supply to the ischemic tissue. Administration of HBO at 12 hours after transient MCAO led to increased cortical infarct volume. The underlying mechanism remains unclear because none of the underlying mechanisms were addressed in our study. Speculation regarding the possible mechanisms of HBO in focal cerebral ischemia should therefore be limited and carefully undertaken.

In our study animals that were exposed to permanent MCAO did not show any reduction of infarct volume or improvement on a neurobehavioral level. In other studies in which permanent MCAO as a model of focal ischemia was used, administration of HBO also failed to reduce infarct volume, even when given 10 minutes after the onset of permanent ischemia.⁹ Apparently, permanent MCAO is a severe insult that may overwhelm any beneficial effect of HBO therapy. Furthermore, because of the suspected severe ischemic injury, administration of HBO in severely ischemic tissue could result in an augmented susceptibility of mitochondria to oxidative stress, which has been shown to exacerbate cerebral infarct after permanent focal cerebral ischemia in mice.²²

In conclusion, we demonstrated a therapeutic window for the single use of HBO in transient but not permanent MCAO in rats. The presented results provide evidence for the use of HBO up to 6 hours after transient MCAO on the basis of the 2 end points investigated: infarct volume and clinical outcome. Administration of HBO in permanent MCAO did not alter infarct size or neurobehavioral outcome.

Acknowledgments

This work was supported in part by a grant from the Christian-Albrechts University of Kiel, Kiel, Germany, for Min Lou, MD student at the Department of Neurology, Christian-Albrechts University of Kiel. The authors gratefully acknowledge Ulrich M. Carl, MD, for construction and provision of the pressure chamber.

References

- Sheffield PJ. Measuring tissue oxygen tension: a review. *Undersea Hyperb Med.* 1998;25:179–188.
- Nairn JR, Power GG, Hyde RW, Forster RE, Lambertsen CJ, Dickson J. Diffusing capacity and pulmonary capillary blood flow at hyperbaric pressures. *J Clin Invest.* 1965;44:1591–1599.
- Elinskii MP, Rafikov AM, Ivanova NE, Kesaev SA. Therapeutic use of hyperbaric oxygenation in ischemic strokes [in Russian]. *Zh Nevropatol Psikhiatr Im S S Korsakova.* 1984;84:1321–1325.
- Berrouscho J, Schwab S, Schneider D, Hacke W. Hyperbaric oxygen therapy (HBO) after acute focal cerebral ischemia [in German]. *Nervenarzt.* 1998;69:1037–1044.
- Iwatsuki N, Takahashi M, Ono K, Tajima T. Hyperbaric oxygen combined with nicardipine administration accelerates neurologic recovery after cerebral ischemia in a canine model. *Crit Care Med.* 1994;22:858–863.
- Weinstein PR, Anderson GG, Telles DA. Results of hyperbaric oxygen therapy during temporary middle cerebral artery occlusion in unanesthetized cats. *Neurosurgery.* 1987;20:518–524.
- Shiokawa O, Fujishima M, Yanai T, Ibayashi S, Ueda K, Yagi H. Hyperbaric oxygen therapy in experimentally induced acute cerebral ischemia. *Undersea Biomed Res.* 1986;13:337–344.
- Kawamura S, Yasui N, Shirasawa M, Fukasawa H. Therapeutic effects of hyperbaric oxygenation on acute focal cerebral ischemia in rats. *Surg Neurol.* 1990;34:101–106.

9. Hjelde A, Hjelstuen M, Haraldseth O, Martin D, Thom R, Brubakk O. Hyperbaric oxygen and neutrophil accumulation/tissue damage during permanent focal cerebral ischaemia in rats. *Eur J Appl Physiol.* 2002;86:401–405.
10. Singhal AB, Dijkhuizen RM, Rosen BR, Lo EH. Normobaric hyperoxia reduces MRI diffusion abnormalities and infarct size in experimental stroke. *Neurology.* 2002;58:945–952.
11. Ruiz E, Brunette DD, Robinson EP, Tomlinson MJ, Lange J, Wieland MJ, Sherman R. Cerebral resuscitation after cardiac arrest using hetastarch hemodilution, hyperbaric oxygenation and magnesium ion. *Resuscitation.* 1986;14:213–223.
12. Badr AE, Yin W, Mychaskiw G, Zhang JH. Dual effect of HBO on cerebral infarction in MCAO rats. *Am J Physiol.* 2001;280:R766–R770.
13. Sunami K, Takeda Y, Hashimoto M, Hirakawa M. Hyperbaric oxygen reduces infarct volume in rats by increasing oxygen supply to the ischemic periphery. *Crit Care Med.* 2000;28:2831–2836.
14. Veltkamp R, Warner DS, Domoki F, Brinkhous AD, Toole JF, Busija DW. Hyperbaric oxygen decreases infarct size and behavioral deficit after transient focal cerebral ischemia in rats. *Brain Res.* 2000;853:68–73.
15. Longa EZ, Weinstein PR, Carlson S, Cummins R. Reversible middle cerebral artery occlusion without craniectomy in rats. *Stroke.* 1989;20:84–91.
16. Schabitz WR, Sommer C, Zoder W, Kiessling M, Schwaninger M, Schwab S. Intravenous brain-derived neurotrophic factor reduces infarct size and counterregulates Bax and Bcl-2 expression after temporary focal cerebral ischemia. *Stroke.* 2000;31:2212–2217.
17. Bederson JB, Pitts LH, Tsuji M, Nishimura MC, Davis RL, Bartkowski H. Rat middle cerebral artery occlusion: evaluation of the model and development of a neurologic examination. *Stroke.* 1986;17:472–476.
18. Garcia JH, Wagner S, Liu KF, Hu XJ. Neurological deficit and extent of neuronal necrosis attributable to middle cerebral artery occlusion in rats: statistical validation. *Stroke.* 1995;26:627–634; comment 635.
19. Schmid-Elsaesser RZS, Hungerhuber E, Baethmann A, Reulen HJA. Critical reevaluation of the intraluminal thread model of focal cerebral ischemia: evidence of inadvertent premature reperfusion and subarachnoid hemorrhage in rats by laser-Doppler flowmetry. *Stroke.* 1998;29:2162–2170.
20. Anderson DC, Bottini AG, Jagiella WM, Westphal B, Ford S, Rockswold GL, Loewenson RB. A pilot study of hyperbaric oxygen in the treatment of human stroke. *Stroke.* 1991;22:1137–1142.
21. Pulsinelli W. Pathophysiology of acute cerebral ischemia. *Lancet.* 1992;359:533–536.
22. Murakami K, Kondo T, Kawase M, Li Y, Sato S, Chen SF, Chan PH. Mitochondrial susceptibility to oxidative stress exacerbates cerebral infarction that follows permanent focal cerebral ischemia in mutant mice with manganese superoxide dismutase deficiency. *J Neurosci.* 1998;18:205–213.