

Conjugate Eye Deviation in Acute Stroke

Incidence, Hemispheric Asymmetry, and Lesion Pattern

Oliver C. Singer, MD; Marek C. Humpich, MD; Helmut Laufs, MD; Heiner Lanfermann, MD;
Helmuth Steinmetz, MD; Tobias Neumann-Haefelin, MD

Background and Purpose—The authors studied clinical features and lesion patterns associated with conjugate eye deviation (CED) in acute stroke.

Methods—Consecutive patients with supratentorial stroke (<6 hours after symptom onset) were prospectively recruited. CED was classified according to the National Institute of Health Stroke Scale (NIHSS) item “gaze palsy” as being forced, partial, or absent. Lesion patterns on diffusion-weighted images (DWI) were analyzed in 46 patients using a normalization procedure for direct comparisons between patients. Perfusion data were analyzed for a subset of patients.

Results—Partial CED was found in 7 (6%) and forced CED in 31 (26.7%) of 116 patients. Forced and partial CED were associated with higher initial NIHSS scores compared with patients without CED (16 and 10 versus 5; $P<0.05$). DWI lesion volume was larger in patients with CED (103.24 ± 102.4 mL, mean \pm SD) as compared with patients without CED (17 ± 34.98 mL, $P<0.001$). CED was more frequent in right hemispheric stroke (44.6% versus 23%, $P<0.02$). DWI pattern analysis in patients with CED with right hemispheric stroke revealed a network of affected regions, including basal ganglia and temporoparietal cortex. In left hemispheric CED, lesions were larger than in patients without CED, but no consistent pattern could be established. In a subset of selected patients with CED, a small temporoparietal perfusion deficit was sufficient to elicit CED.

Conclusions—Selective dysfunction of cortical areas involved in spatial attention and control of eye movements is sufficient to cause CED in patients with acute stroke. However, in the majority of cases, CED is an indicator of large infarcts involving more than one area, including both cortical and subcortical structures. (*Stroke*. 2006;37:2726-2732.)

Key Words: acute ■ conjugate eye deviation ■ frontal eye field ■ magnetic resonance imaging
■ spatial neglect ■ stroke

The association between stroke and conjugate eye deviation (CED) was first described in 1865 by Prévost.¹ Subsequent studies examined the frequency of CED in stroke and found CED to be present in approximately 20% of patients with stroke.^{2–4} In supratentorial stroke, CED is directed almost exclusively toward the affected hemisphere and is—in a subset of patients—accompanied by ipsilateral deviation of the head. In observational studies, CED was associated with severe clinical symptoms, poor outcome, and increased mortality.^{2,5}

Pathophysiologically, dysfunction of cortical regions (or subcortical fiber tracts) involved in the control of voluntary eye movements is considered to be responsible for CED in stroke.² It is believed that the frontal eye field (FEF, Brodmann area [BA] 6 or 8) is an important area in this context, but the crucial structures are not exactly known.^{6–8}

Tanaka et al⁹ demonstrated that a small ischemic lesion affecting the FEF can indeed cause CED. They described an

82-year-old patient with isolated acute CED to the right resulting from a single diffusion-weighted imaging (DWI) lesion in the caudal part of the right middle frontal gyrus. In contrast, Tijssen et al¹¹ prospectively studied brain lesion morphology in patients with CED using computed tomography 7 to 10 days after symptom onset and found no direct involvement of the FEF, a finding that was corroborated by a recent study.¹⁰ Thus, the mechanisms leading to CED (common involvement of a circumscribed brain area, ie, the FEF versus “network damage,” ie, ischemia of a critical volume of cortical or subcortical tissue) remain incompletely understood.

Therefore, we systematically analyzed clinical and imaging correlates of CED in a large single-center population of patients with acute stroke. The aim of the study was to identify lesion patterns associated with CED in acute stroke.

Received June 6, 2006; final revision received July 7, 2006; accepted August 3, 2006.

From the Department of Neurology (O.C.S., M.C.H., H.Laufs, H.S., T.N.-H.) and the Institute for Neuroradiology (H.Lanfermann), J.W. Goethe-University, Frankfurt am Main, Germany.

Both O.C.S. and M.C.H. contributed equally to this study.

Correspondence to Oliver C. Singer, MD, Department of Neurology, J.W. Goethe-University Frankfurt am Main, Schleusenweg 2-16, D-60528 Frankfurt/Main, Germany. E-mail o.singer@em.uni-frankfurt.de

© 2006 American Heart Association, Inc.

Stroke is available at <http://www.strokeaha.org>

DOI: 10.1161/01.STR.0000244809.67376.10

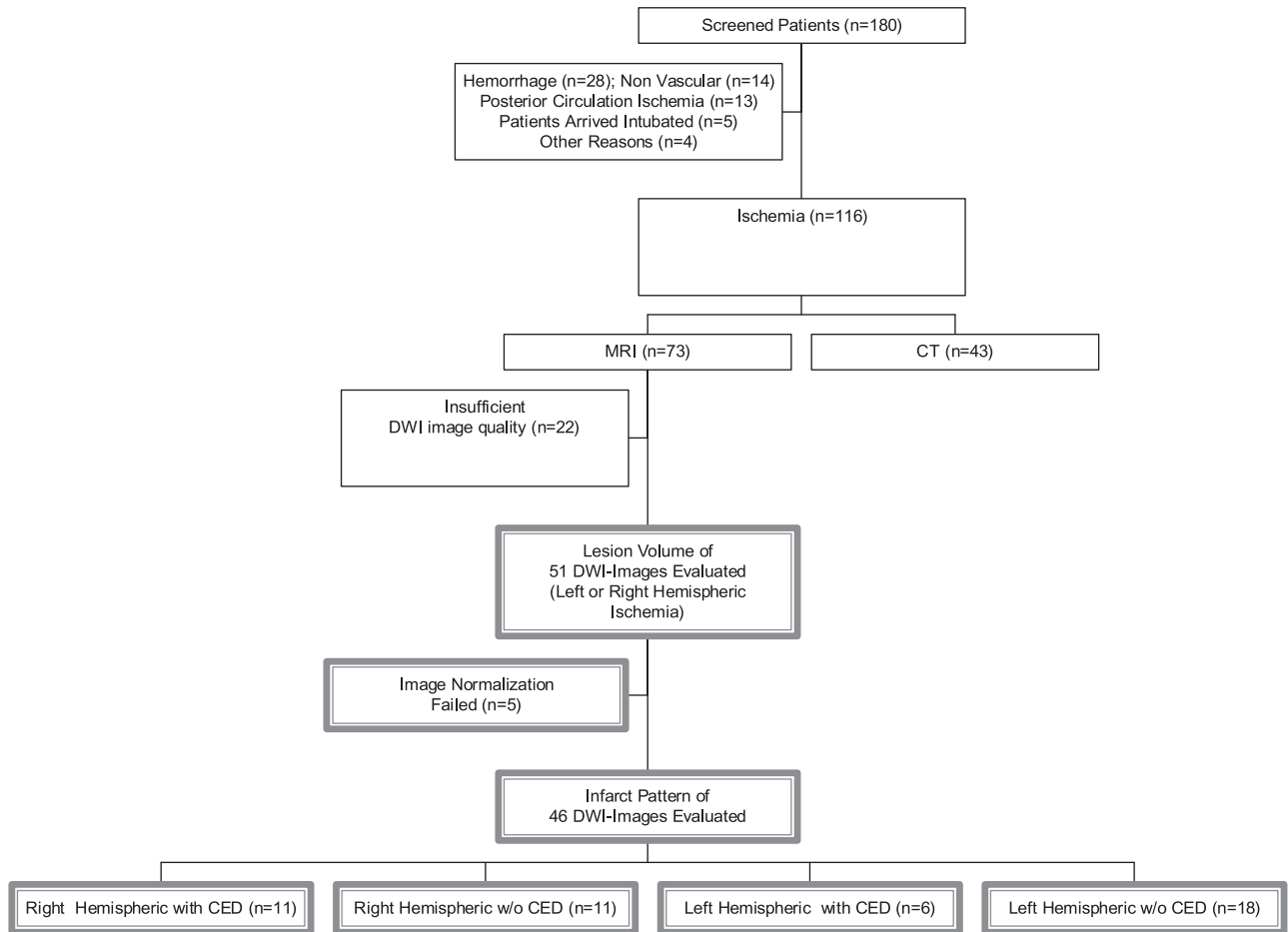


Figure 1. Study cohort.

Methods

Study Population

During a study period of 12 months, 180 consecutive patients with the clinical suspicion of acute stroke (<6 hours after symptom onset) were prospectively screened. Of these, 64 were excluded resulting from the following reasons: intracerebral hemorrhage (n=28), posterior circulation ischemia (n=13), final nonvascular diagnosis (n=14), analgesedation (n=5), and incomplete data sets (n=4). Of the remaining 116 patients with cerebral ischemia, 73 (62.9%) underwent our MRI stroke protocol immediately after admission (Figure 1).

Stroke severity was classified according to the National Institute of Health Stroke Scale (NIHSS) score. CED was classified in the study according to the NIHSS criteria for the item “best gaze” as normal (0), partial gaze palsy (1), and forced deviation or total gaze paresis not overcome by the oculocephalic maneuver (2). Stroke severity at discharge from the hospital was assessed using the modified Rankin Scale (mRS). The study was approved by the local ethics committee and informed consent was obtained from the patients or a legal representative before enrollment in the study.

MRI Protocol

The MRI protocol (1.5 T MR scanner; Siemens Magnetom Vision) included diffusion- and perfusion-weighted imaging (DWI, PWI), MR angiography, and conventional imaging. DWI was performed with a single-shot EPI spin-echo sequence: echo time, 123 ms; flip angle, 90°; field of view, 230×230 mm; matrix, 128×128; slices, 19; slice thickness, 6 mm; gap, 1.2 mm; and b=1000 with the diffusion gradient in one direction. For bolus-tracking PWI, a gradient-echo EPI sequence (echo time, 60.7 ms; field of view,

240×240 mm; matrix, 128×128; slice thickness, 5 mm; gap, 1 mm) was used. Forty T2*-weighted images for each of the 12 slices at intervals of 2 seconds were obtained. The contrast agent (0.1 mmol/kg Gd-DTPA, Magnevist; Schering) was injected into an antecubital vein using a power injector at a rate of 5 mL/second followed by a flush with 10 mL saline.

Image Postprocessing

Assessment of lesion volumes on DWI images was performed using the software package MRVision (MRVision Co). The areas of hyperintensity on DWI images were manually traced on each slice, summed, and multiplied with the slice thickness and interslice gap, resulting in a volume measure. Afterward, images were normalized to the Talairach-space¹² using the Automated Image Registration algorithm¹³ included in the software package MEDX (Medical

TABLE 1. Basic Clinical Data of All 116 Patients Included in the Study*

Criteria	n	%
Sex, male	71	61
Age, years	70±13	
Hemisphere, left	61	52.6
NIHSS	9±7	
MRI at admission	73	62.9
Time onset/admission, min	127±78	

*Total NIHSS score (not corrected for gaze/head palsy). Values are given as mean±SD.

TABLE 2. Frequency of Partial and Forced CED in All Patients With Anterior Circulation Ischemia (n=116)

Criteria	n	%
No CED	78	67.2
Partial CED	7	6
Forced CED	31	26.7

Numerics, Inc). Lesion plots were created on a voxel-by-voxel basis indicating the frequency of infarction of each voxel (overlay image). For final illustration, the lesion plots were superimposed on a common T1 template using MRICro software (www.mricro.com).

In a separate analysis, perfusion data (time to peak maps) of 4 patients with particularly small deficits (less than one fourth of the middle cerebral artery [MCA] territory) were processed according to the method used for DWI images. A time-to-peak delay threshold of >6 seconds (in comparison to the unaffected MCA territory) was chosen before the generation of overlay lesion plots to limit analysis to critically hypoperfused areas.¹⁴ In all 4 patients, DWI lesions were smaller than the perfusion deficit (data not shown in detail).

Statistical Analysis

Statistical analysis was performed using SPSS for Windows, Version 11.5. The Mann-Whitney *U* test was used to compare differences in acute clinical and imaging parameters (including age, gender, NIHSS, affected hemisphere, initial lesion on DWI) between groups, unless stated otherwise. A *P* value <0.05 was considered statistically significant. For analysis of CED, the study population was dichotomized in patients with (forced or partial) or without CED. To exclude a bias caused by grouping the patients according to the NIHSS item "gaze palsy," this item was excluded from the total NIHSS score for comparison of the severity of neurologic deficits of both patient groups ("cNIHSS" = corrected NIHSS). For outcome analysis at hospital discharge, a logistic regression model was used, including the covariates CED, age, and cNIHSS. For this regression model,

mRS scores at discharge were dichotomized into favorable outcome (mRS 0 to 2) and unfavorable outcome (mRS 3 to 6).

Results

Table 1 gives an overview of basic clinical and demographic data of the study population (n=116). Seventy-eight patients (67.2%) had no CED, whereas 7 (6%) presented with partial and 31 (26.7%) with forced CED (Table 2). Irrespective of the affected hemisphere and after correction for the NIHSS item "gaze palsy," both the presence of forced and partial CED were associated with significantly higher cNIHSS scores on admission (16 and 10 versus 5; *P*<0.001 for forced versus no CED and *P*<0.05 for partial versus no CED) (Figure 2).

CED was significantly more frequent in patients with right hemispheric as compared with patients with left hemispheric ischemia (43.6 versus 23%, *P*<0.01, Figure 3). cNIHSS scores did not differ significantly in right (mean cNIHSS=9) or left hemispheric (mean cNIHSS=8, *P*=0.34) stroke when all patients (with and without CED) were analyzed. However, patients with CED resulting from left hemispheric ischemia had a significantly higher cNIHSS as compared with patients with CED resulting from right hemispheric ischemia (17 versus 13, *P*<0.05, Table 3).

Modified Rankin scores at hospital discharge were significantly higher and the proportion of patients with favorable outcome (mRS ≤2) was significantly lower in patients with CED as compared with patients without CED (Table 4). However, after inclusion of the cNIHSS score at admission in a logistic regression model, CED no longer remained a significant predictor of mRS at discharge. This is attributable to a significant correlation (*r*=0.64, *P*<0.001, Spearman rank

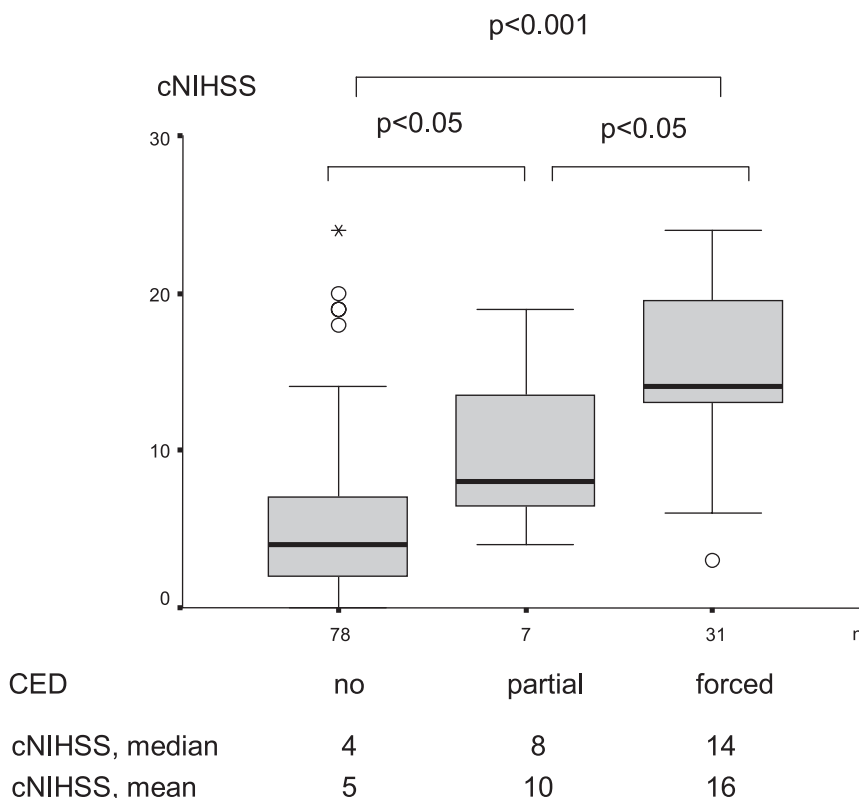


Figure 2. Box plot of cNIHSS scores with respect to the presence of any degree of CED irrespective of the affected hemisphere. (For the item gaze palsy, see "Materials and Methods" for details.) cNIHSS values are given as median and mean values. Mann-Whitney *U* test was used for statistical analysis. (— indicates minimum and maximum; furthermore, 25th, 50th (median), and 75th percentiles are shown as well as extreme values (o, *).

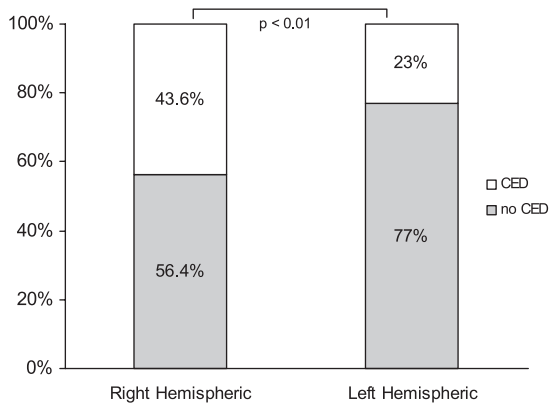


Figure 3. Relative frequency of CED (dichotomized for partial and forced vs no CED) in patients with right or left hemispheric ischemia (n=116), Mann-Whitney *U* test.

test) between the NIHSS item CED and the overall cNIHSS score (corrected for the CED item). No significant differences of the mRS at discharge were found when patients with left or right hemispheric CED were compared (data not shown).

Average DWI lesion volume was 48 ± 78 mL, being significantly larger in patients with CED (103 ± 102 mL) as compared with patients without CED (17 ± 34 mL) irrespective of the affected hemisphere ($P < 0.001$, Mann Whitney *U* test). In patients without CED, there was a significant difference between lesion volumes in right and left hemispheric ischemia, being larger in left hemispheric ischemia, indicating that smaller lesions are sufficient for the development of CED in right hemispheric stroke (4.5 ± 9 mL versus 24.2 ± 42 mL, $P < 0.05$, Mann Whitney *U* Test) (Table 3).

DWI lesion patterns differed between patients with and without CED depending on the affected side (Figure 4). In right hemispheric ischemia, patients without CED had exclusively small cortical DWI lesions affecting the central middle cerebral artery territory (periinsular and adjacent cortex; Figure 4B) but not the basal ganglia. In patients with left hemispheric ischemia without CED, DWI lesions often in-

TABLE 4. Outcome Data (mRS at hospital discharge) of 113 Patients of the Study Population (n=3 data sets incomplete)

Criteria	n	Days in Hospital	mRS at Discharge	'Favorable' Outcome (mRS ≤ 2), n (%)
No CED	78	8 ± 6 †	2 ± 2 †	48 (62%)†
CED	35	14 ± 9 †	4 ± 2 †	7 (20%)†

*Data are given as mean \pm SD unless stated otherwise; † $P < 0.01$ between patients with and without CED (Mann-Whitney *U* test). Favorable outcome was defined as a mRS score of 0–2 at discharge. Using a logistic regression model including cNIHSS at admission, CED no longer remained a significant predictor for favorable outcome at discharge.

involved substantially larger areas, including the basal ganglia, parietotemporal and frontal cortex (Figure 4E).

In patients with CED, lesion patterns were similar in left and right hemispheric ischemia with frequent involvement of extensive cortical and subcortical areas (Figure 4A and 4D).

Figure 4C and 4F show differential (subtraction) images of the original lesion plots of patients with CED subtracted by DWI-positive areas in patients without CED. The differential lesion analysis (Figure 4) assumes that the involvement of DWI-positive areas in patients without CED is not sufficient to cause CED. Conversely, the remaining areas on the differential maps may be crucial for the development of CED.

In left hemispheric ischemia, no such areas (>1 mL) were detected being exclusively affected in $>50\%$ of patients with CED (Figure 4F). In right hemispheric ischemia, basal ganglia structures (caudate nucleus, putamen) and the right inferior parietal lobule (BA 40) were affected in more than two thirds of patients with CED but not in patients without CED.

PWI data of 4 selected patients with CED and a particularly small perfusion deficit are plotted in Figure 5. Areas affected in all 4 patients included predominantly the inferior parietal lobule (BA 40) and the supramarginal gyrus (BA 40), and the middle and superior temporal gyrus (BA 21 and 39) and parts of the insula (BA 13). Basal ganglia and frontal cortical tissue were spared in 3 of the 4 patients. These data

TABLE 3. Basic Clinical and Imaging Parameters of the Whole Patient Population (n=116, upper panel) and of the Subgroup of Patients Receiving MRI of Sufficient Quality (n=51, lower panel) With Respect to the Affected Hemisphere and the Presence or Absence of CED*

	Right Hemisphere (n=55)		Left Hemisphere (n=61)	
	Yes (n=24)	No (n=31)	Yes (n=14)	No (n=47)
Age, year	69.1 ± 13.6	70.8 ± 14.2	72.3 ± 13.4	69 ± 11.9
Sex, male (n, %)	14 (58.3%)	17 (58%)	7 (50%)	33 (70.2%)
Time onset at admission, min	118 ± 68	129 ± 83	107 ± 78	136 ± 80
cNIHSS	13 ± 5 †‡	6 ± 6 †	17 ± 6 †‡	5 ± 5 †
Subgroup Analysis	Yes (n=11)	No (n=12)	Yes (n=7)	No (n=21)
Time onset at admission, min	120 ± 59	152 ± 98	99 ± 95	123 ± 51
cNIHSS	12 ± 4 †‡	5 ± 4 †	20 ± 3 †‡	8 ± 6 †
DWI lesion volume, mL	94.9 ± 114 †	4.5 ± 9.1 †‡	116.3 ± 87.8 †	24.2 ± 42 †‡

*Patients with partial or forced CED were pooled. DWI lesion volume was analyzed in 51 patients receiving acute MRI of diagnostic quality; † $P < 0.01$ between patients with the same hemisphere affected with respect to the presence or absence of CED; ‡ $P < 0.05$ between patients with the same oculomotor signs (CED yes/no) with respect to the affected hemisphere (left or right) (Mann-Whitney *U* test). (For gaze/head palsy, see "Materials and Methods" details). Values are given as mean \pm SD.

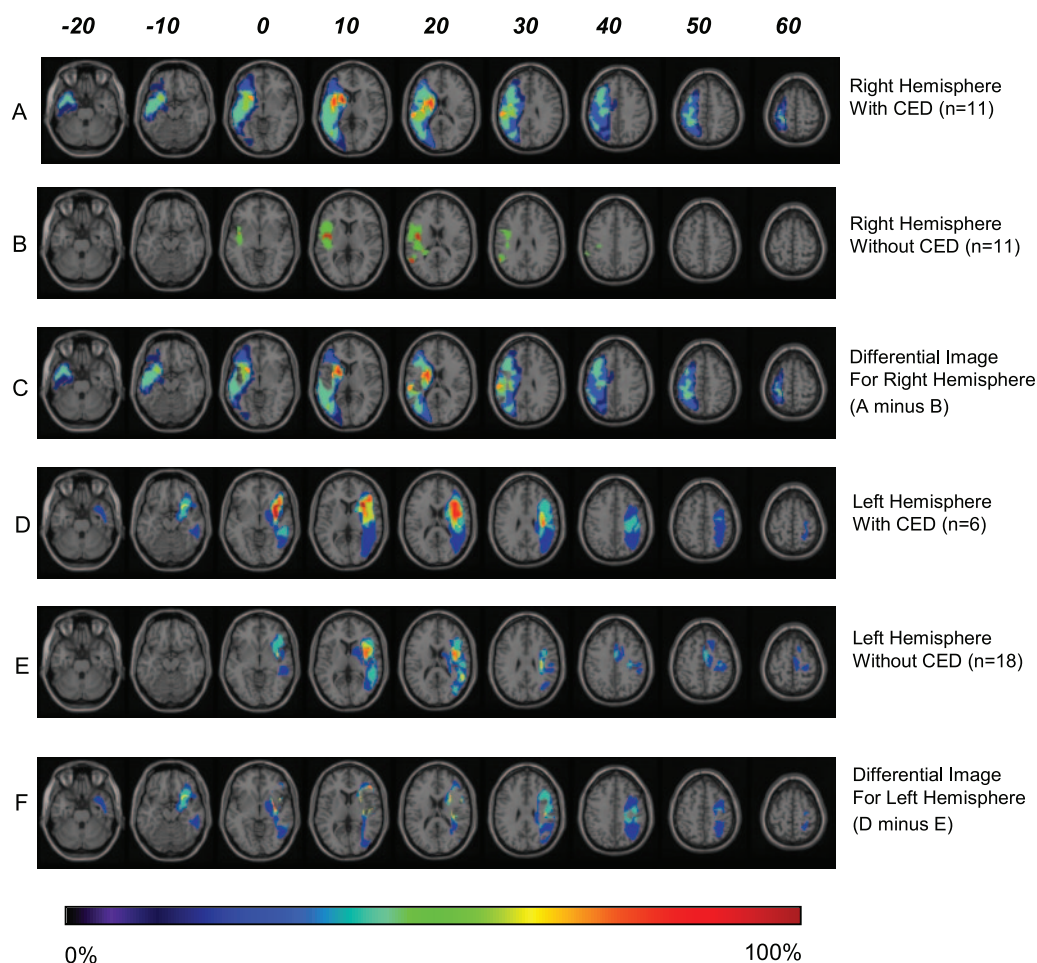


Figure 4. Color-coded lesion overlay plots. Every line shows 9 axial slices of a representative MCA territory. The Talairach z-coordinates 12 of each axial slice are given. Lesion plots calculated from DWI images were superimposed on a T1-weighted template. The color scale (0% to 100%) illustrates the relative frequency of each voxel being localized in the DWI-positive area. (A) Lesion pattern of patients with right hemispheric stroke and CED. (B) Patients with right hemispheric stroke without CED. (C) Differential image of A and B. Color-coded voxels represent areas being only affected in patients with right hemispheric ischemia and CED. (D) Lesion pattern of patients with left hemispheric stroke and CED. (E) Patients with left hemispheric stroke without CED. (F) Differential image of D and E. Color-coded voxels represent areas being only affected in patients with left hemispheric ischemia and CED.

underline that circumscribed perfusion deficits in parietotemporal structures can elicit CED.

Discussion

The present study investigated the clinical relevance and imaging correlates of the sign “conjugate eye deviation” in patients with acute anterior circulation stroke. The major findings of the study are: (1) CED is associated with severe neurologic deficits on admission and at hospital discharge

as well as with larger DWI lesion volume, especially in left hemispheric ischemia; (2) CED is more frequent in patients with right hemispheric ischemia; (3) selective dysfunction of cortical areas involved in spatial attention and control of eye movements is sufficient to cause CED in patients with acute stroke; and (4) however, in the majority of cases, CED is an indicator of large infarcts involving more than one area, frequently both cortical and subcortical structures.

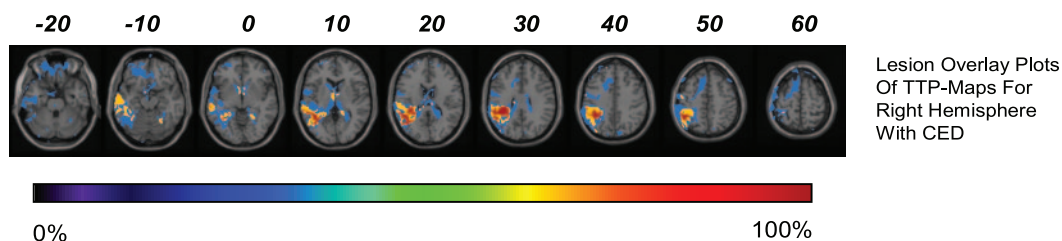


Figure 5. Lesion overlay plots of TTP maps of 4 patients with right hemispheric stroke presenting with CED and a small perfusion deficit (<25% of the affected MCA territory). TTP threshold was set to >6 seconds as compared with the contralateral MCA territory.

To our knowledge, no similarly comprehensive MRI data on lesion size and distribution in patients with CED in acute ischemic stroke have been published to date. In addition to the clinical notion of a higher prevalence of CED in right hemispheric ischemia, the higher susceptibility of the right hemisphere to CED is established by the fact that DWI lesions in left hemispheric stroke without CED were significantly larger than in right hemispheric stroke without CED, indicating that smaller DWI lesions can elicit CED in right hemispheric ischemia. Furthermore, 5 of 11 (45%) right hemispheric patients with CED had an initial DWI lesion volume smaller than the average DWI lesion volume of left hemispheric patients without CED in contrast to only 2 of 7 (29%) left hemispheric patients with CED.

In patients with CED attributable to right hemispheric ischemia, basal ganglia structures (caudate nucleus, putamen) and the inferior parietal lobule (BA 40) were frequently affected, but not in patients without CED. Right hemispheric lesions restricted to the basal ganglia or thalamus have been reported previously to evoke CED or spatial neglect,^{15–18} highlighting the importance of subcortical structures. On the other hand, patients with basal ganglia damage often have large infarcts resulting from MCA mainstem occlusion; thus, it is at least theoretically possible that CED in these patients is attributable to the simultaneous involvement of other structures in addition to the basal ganglia.

Our perfusion data clearly demonstrate that relatively small cortical lesions are sufficient to cause CED. Unlike in the case study by Tanaka et al,⁹ we found circumscribed perfusion deficits (with smaller DWI lesions) in right hemispheric temporoparietal tissue (BA 21, 39, and 40). This region is regarded as being crucial for spatial attention, which is predominantly lateralized to the right hemisphere.^{19–21} Furthermore, BA 39 and 40 are in the vicinity of the human parietal eye field, closely linking eye movements and spatial attention in healthy subjects.^{22,23} Chedru et al²⁴ have suggested a relationship between eye movement disorders and disorders of spatial attention (neglect). Additionally, spontaneous ipsilesional gaze and head deviation in patients with subacute right hemispheric stroke and proven spatial neglect was observed in contrast to normal oculomotor findings in patients with right hemispheric stroke without neglect.²⁵

Analysis of DWI lesion patterns in left hemispheric stroke revealed that similar cortical and subcortical areas were affected in patients with and without CED, and rather small areas, predominantly located at the border zones of the MCA territory, were exclusively affected in single patients with CED. Importantly, in left hemispheric ischemia, no larger areas could be identified being exclusively affected in all patients with CED, suggesting that no single structure, in particular not the FEF, is mandatory for the induction of CED, a finding being in line with a previous computed tomography-based study.¹⁰

The present study has the following limitations. DWI lesions do only partially reflect penumbral tissue and regularly underestimate the area of functionally impaired tissue. Therefore, a systematic analysis of PWI data would have been desirable but was not possible in the present study, partly as a result of frequent motion artifacts prohibiting the

image postprocessing (ie, spatial normalization) of PWI data. No systematic follow up concerning the duration of CED in patients with stroke was done. We did not perform extensive neuropsychologic examinations (ie, testing for spatial neglect) basically as a result of time constraints because most patients were potential candidates for thrombolytic therapy. The NIHSS is known to be more sensitive for left hemispheric ischemia and may underestimate lesion volume in right hemispheric stroke.²⁶ Therefore, the higher cNIHSS scores in patients with CED resulting from left as compared with right hemispheric ischemia have to be interpreted with caution, especially because DWI lesion volumes in patients with CED do not differ significantly in right and left hemispheric stroke.

Taken together, both the findings of our study as well as previous work on CED in acute stroke are best integrated in the following concept. In selected patients, small lesions affecting areas involved in either spatial attention or control of eye movements are sufficient to cause CED. These areas include the basal ganglia, the FEF, and parietal eye field as well as neighboring temporoparietal cortical regions involved in spatial attention. Involvement of multiple of these regions increases the likelihood of CED, which explains why there is a robust association between DWI lesion size and CED as well as among cNIHSS, CED, and clinical outcome at hospital discharge. The difference in the occurrence of CED between right and left hemispheric strokes is attributable to the predominant representation of spatial attention in the right hemisphere.

Sources of Funding

This work was supported by a research grant of the Deutsche Forschungsgemeinschaft Ne 569/3-1 and by the J.W. Goethe University Frankfurt.

Disclosures

None.

References

- Prevost J. De la déviation conjuguée de yeux et de la rotation de la tête dans certains cas d'hémiplégie. 1868. Thesis.
- De Renzi E, Colombo A, Faglioni P, Gibertoni M. Conjugate gaze paresis in stroke patients with unilateral damage. An unexpected instance of hemispheric asymmetry. *Arch Neurol*. 1982;39:482–486.
- Mohr J, Rubinstein LV, Kase C. Gaze palsy in hemispherical stroke: the NINCDS stroke data bank. *Neurology*. 1984;34(suppl 1):199.
- Okinaka S, Toyokura Y, Nakamura H, Kuroiwa Y, Tsubaki T. A contribution to the study of pathogenesis of conjugate deviation of eyes in cerebral apoplexy. *Folia Psychiatr Neurol Jpn*. 1952;6:125–137.
- Tijssen CC, Schulte BP, Leyten AC. Prognostic significance of conjugate eye deviation in stroke patients. *Stroke*. 1991;22:200–202.
- Blanke O, Landis T, Seeck M. Electrical cortical stimulation of the human prefrontal cortex evokes complex visual hallucinations. *Epilepsy Behav*. 2000;1:356–361.
- Paus T. Location and function of the human frontal eye-field: a selective review. *Neuropsychologia*. 1996;34:475–483.
- Petit L, Clark VP, Ingeholm J, Haxby JV. Dissociation of saccade-related and pursuit-related activation in human frontal eye fields as revealed by fMRI. *J Neurophysiol*. 1997;77:3386–3390.
- Tanaka H, Arai M, Kubo J, Hirata K. Conjugate eye deviation with head version due to a cortical infarction of the frontal eye field. *Stroke*. 2002;33:642–643.
- Ringman JM, Saver JL, Woolson RF, Adams HP. Hemispheric asymmetry of gaze deviation and relationship to neglect in acute stroke. *Neurology*. 2005;65:1661–1662.

11. Tijssen CC, van Gisbergen JA, Schulte BP. Conjugate eye deviation: side, site, and size of the hemispheric lesion. *Neurology*. 1991;41:846–850.
12. Talairach J, Tournoux P. *Co-planar Stereotactic Atlas of the Human Brain*. New York: Thieme Medical; 1988.
13. Woods RP, Cherry SR, Mazziotta JC. Rapid automated algorithm for aligning and reslicing PET images. *J Comput Assist Tomogr*. 1992;16: 620–633.
14. Neumann-Haefelin T, Witsack HJ, Wenserski F, Siebler M, Seitz RJ, Modder U, Freund HJ. Diffusion- and perfusion-weighted MRI. The DWI/PWI mismatch region in acute stroke. *Stroke*. 1999;30:1591–1597.
15. Chung CS, Caplan LR, Yamamoto Y, Chang HM, Lee SJ, Song HJ, Lee HS, Shin HK, Yoo KM. Striatocapsular haemorrhage. *Brain*. 2000;123: 1850–1862.
16. Chung CS, Caplan LR, Han W, Pessin MS, Lee KH, Kim JM. Thalamic haemorrhage. *Brain*. 1996;119:1873–1886.
17. Karnath HO, Himmelbach M, Rorden C. The subcortical anatomy of human spatial neglect: putamen, caudate nucleus and pulvinar. *Brain*. 2002;125:350–360.
18. Bartanusz V, Daniel RT, Villemure JG. Conjugate eye deviation due to traumatic striatal–subthalamic lesion. *J Clin Neurosci*. 2005;12:92–93.
19. Mort DJ, Malhotra P, Mannan SK, Rorden C, Pambakian A, Kennard C, Husain M. The anatomy of visual neglect. *Brain*. 2003;126:1986–1997.
20. Karnath HO, Fruhmann Berger M, Kuker W, Rorden C. The anatomy of spatial neglect based on voxelwise statistical analysis: a study of 140 patients. *Cereb Cortex*. 2004;14:1164–1172.
21. Kim YH, Gitelman DR, Nobre AC, Parrish TB, LaBar KS, Mesulam MM. The large-scale neural network for spatial attention displays multi-functional overlap but differential asymmetry. *Neuroimage*. 1999;9: 269–277.
22. Himmelbach M, Erb M, Karnath HO. Exploring the visual world: the neural substrate of spatial orienting. *Neuroimage*. 2006; 32:1747–1759.
23. Pierrot-Deseilligny C, Milea D, Muri RM. Eye movement control by the cerebral cortex. *Curr Opin Neurol*. 2004;17:17–25.
24. Chedru F, Leblanc M, Lhermitte F. Visual searching in normal and brain-damaged subjects (contribution to the study of unilateral inattention). *Cortex*. 1973;9:94–111.
25. Fruhmann-Berger M, Karnath HO. Spontaneous eye and head position in patients with spatial neglect. *J Neurol*. 2005;252:1194–1200.
26. Fink JN, Selim MH, Kumar S, Silver B, Linfante I, Caplan LR, Schlaug G. Is the association of National Institutes of Health Stroke Scale scores and acute magnetic resonance imaging stroke volume equal for patients with right- and left-hemisphere ischemic stroke? *Stroke*. 2002;33: 954–958.