

## Case Reports

# Sleep Apnea as a Feature of Bulbar Stroke

J.J.M. Askenasy, MD, PhD, and I. Goldhammer, MD

**Medullary disorders can be associated with a sleep apnea syndrome. The present patient developed a sleep apnea syndrome with approximately 25 episodes of apnea or hypopnea during each hour of sleep following a lateral medullary infarction. The presence of predisposing factors and involvement of respiratory centers in the area of the medullary lesion may determine the appearance of sleep apnea with brainstem infarction. Investigation of breathing during sleep may be helpful in such cases. (*Stroke* 1988;19:637-639)**

The respiratory neurons are located in the reticular formation of the medulla oblongata. They are closely related to motor activity centers of the upper respiratory tract involving the tongue and pharynx. The larynx ventilation undergoes changes during rapid eye movement (REM) and non-REM sleep as a consequence of changes in the reticular system of the medulla oblongata.<sup>1</sup> The anatomic proximity of the centers controlling breathing, sleep, and upper respiratory tract motility suggests a close physiologic interrelationship. Sleep in general and REM sleep in particular depress upper respiratory tract motor function, favoring and accentuating respiratory disturbances.

Sleep apnea has been reported in medullary infarction, high cervical cordotomy, syringobulbia, bulbar poliomyelitis, olivopontocerebellar degeneration, near-drowning, neoplasms, hindbrain abnormalities, multiple sclerosis, and trauma (Table 1).<sup>2-19</sup> Of the medulla oblongata disorders, vascular disturbance is the most frequent cause of respiratory sleep distress.<sup>2-5,16</sup>

### Case Report

A 49-year-old man with no history of hypertension or obesity suffered a left Wallenberg's syndrome. The clinical signs consisted of hoarse voice, intractable hiccup, left Horner's syndrome, mild skew deviation, left soft palate palsy, left vocal cord paralysis, ataxia (left more than right), right dissociated hemianalgesia with no left face hemianalgesia, right Babinski's sign, and Romberg's sign. Following the stroke the patient had severe difficulty in swallowing. Routine laboratory examinations were normal. Computed tomography (CT scan) with and without contrast done at the time of admission showed no abnormality. Fine cuts through the posterior fossa could not be obtained because of temporary technical limitations.

During the next 10 days, as his swallowing disturbance improved, very noisy snoring appeared, with

abrupt pauses accounting for apneic spells. An ear-nose-throat examination revealed a long uvula and a septum deviation occluding his left nostril. Based on anamnestic data collected from his wife, there was no history of loud snoring or respiratory arrest before the brainstem stroke. Sleep was monitored for two nights following an adaptation night, using a routine polygraphy technique. The routine polygraphy consisted of electroencephalography, electro-oculography, electromyography, breathing monitoring, and closed-circuit television. Breathing monitoring consisted of nasal-oral airflow, rib-abdominal cages, and ear oximetry. The mean data for two nights showed 150 episodes of apnea and hypopnea per night's sleep. Hypopnea was defined as apneic episodes lasting 5-10 seconds. Apnea was defined as apneic episodes lasting >10 seconds. The total number of apneic and hypopneic episodes per hour of sleep representing the apnea-hypopnea index was 25.0. The diagnosis of a sleep apnea syndrome is made when there are >30 breath arrests lasting >10 seconds during a night's sleep. Sleep apnea has been categorized as central, obstructive, or mixed. Central apnea is present when the respiratory center fails to contract the diaphragm. Obstructive apnea is characterized by the blockage of air flow in the upper airway despite the presence of diaphragm contraction. Of the total 150 episodes of apnea and hypopnea, 99 were obstructive or mixed and 51 were of the central type. Fifty apneic episodes were associated with <85% O<sub>2</sub> saturation and 10 with 80% O<sub>2</sub> saturation, that is, with a Pao<sub>2</sub> of ≤50 mm Hg. At this level of hypoxia, pulmonary vasoconstriction can occur, which may predispose to pulmonary and systemic hypertension and lead to worsening hypoxia. No cardiac changes were found.

The longer apneic episodes occurred during REM sleep, while the patient was sleeping on his back and rarely on his right side, but never while sleeping on his left side. The apneic episodes that did not affect O<sub>2</sub> desaturation lightened the level of his sleep. The lightening was marked by very frequent switches from sleep stage 2 and REM stage to sleep stage 1 when compared with a normal routine polysomnogram. Morning tiredness and a need to nap after lunch

From the Neurological Department of Sackler School of Medicine, Tel Aviv University, Israel.

Address for correspondence: J.J. Askenasy, MD, PhD, Ben Yehuda Street 79, Hertzlia 46498, Israel.

Received April 8, 1987; accepted November 10, 1987.

**TABLE 1. Sleep Apnea in Medulla Oblongata Disorders; Review of Literature 1951–1986**

Frequency	Disorders	References
1	Bulbar stroke	2, 3, 4, 5
	High cervical cordotomy	6, 7, 8, 9
2	Syringobulbia	10, 11, 12
3	Bulbar poliomyelitis	13, 14
4	Olivopontocerebellar degeneration	12, 15
5	Near-drowning (bulbar ischemia)	16
6	Bulbar neoplasms	17
7	Hindbrain abnormalities	18
8	Multiple sclerosis	19
9	Medullary trauma	2

Decreasing order of frequency according to number of published observations.

developed. Using a continuous positive-airway-pressure mask, his apnea index was reduced to 7.0 and his sleep apnea improved significantly.

### Discussion

The effects of sleep on breathing consist of a reduced respiratory drive in non-REM sleep and complex alterations in REM sleep.<sup>20</sup> Upper airway resistance increases during sleep due to a decrease in upper airway muscle tone.<sup>21</sup> This decrease in respiratory drive was first underlined by Kleitman.<sup>22</sup>

The diagnosis of a sleep apnea syndrome is made when there are  $\geq 30$  apneic episodes with a duration of  $\geq 10$  seconds during a night's sleep, equal to an apnea index of 5 for 6 hours of sleep.<sup>23,24</sup> Following a left medullary infarction, the present patient developed a sleep apnea syndrome. His breathing disorder suggested that the behavioral control system was adequate during wakefulness, but during sleep apneas of obstructive, central, and mixed type appeared.<sup>25</sup> Abnormal brainstem evoked potentials in adults with both central and obstructive sleep apnea suggest the involvement of the reticular system in the breathing control of both types.<sup>26</sup>

Patients suffering from medullary diseases associated with sleep apnea are at higher risk for automatic respiratory failure during sleep.

In mammals, three aggregations of rhythmic respiratory neurons in the medulla oblongata were described: the dorsal and ventral respiratory nuclei in the lower medulla and the nucleus parabrachialis medialis in the upper medulla<sup>27</sup> (Figure 1). To generate a normal respiratory pattern the three centers require vestibulocerebellar regulation of the tonus of supraglottic, genioglossal, pharyngolaryngeal, diaphragmatic, and intercostal muscles. Disorders of the vestibulocerebellar system, such as olivopontocerebellar degeneration, may cause sleep apnea due to impaired function of the respiratory muscles.<sup>12,15</sup>

The proximity of the hypnogenic and somatic upper respiratory airway centers may explain the association of lateral medullary infarction with sleep apnea. The type and severity of the apnea-hypopnea index may depend on the number of injured neurons and axons and on the compensatory function of the contralateral undamaged respiratory centers. This compensatory function may vary between individuals and may play an important role in sleep apnea. Unilateral lesions may provoke sleep apnea in individuals whose compensatory capacity is weak or in whom congenital abnormal control of respiration exists.<sup>28</sup> Bilateral damage of all three respiratory nuclei may result in failure of automatic respiration, termed Ondine's curse.<sup>29</sup>

Breathing distress can occur after high cervical cordotomy.<sup>6-9</sup> The role played by the high cervical cord in breathing varies between subjects and may constitute another factor in determining the development of sleep apnea. A long uvula and septal deviation may also have been predisposing factors in our patient.

A good adaptation to obstruction through an open right nostril may explain the absence of sleep apnea when he was sleeping on the already-occluded left nostril and may explain its presence when he was lying on his right side. The presence of the most severe apnea while he was sleeping on his back supports recent studies showing that the supine position favors obstructive sleep apnea.<sup>30,31</sup>

In conclusion, it is recommended that the possibility of the association of medullary disorders with sleep apnea in patients with predisposing factors and a certain topography of the lesion be taken into consideration. In patients with snoring and respiratory arrests following bulbar stroke, supervising or monitoring breathing during sleep is indicated.

### References

1. Parmeggiani PL: Integrative aspects of hypothalamic influences on respiratory brain stem mechanisms during wakefulness and sleep, in Von Euler C, Lagercrantz H (eds): *Central Nervous Control Mechanisms in Breathing. Wenner Gren Center Symposium Series*. Oxford, Pergamon Press, 1979, vol 32, pp 53–68
2. Devereux MW, Keane JR, Davis RL: Automatic respiratory failure associated with infarction of the medulla. *Arch Neurol* 1973;29:46–52
3. Hunziker A, Frick P, Regli F, Rossier PH: Zentralbedingte chronische alveolar Hypoventilation bei Malazien in der Medulla Oblongata (Beitrag zum Wallenberg Syndrom). *Dtsch Med Wochenschr* 1964;89:676–680
4. Chaudhary BA, Elguindi AS, King DW: Obstructive sleep apnea after lateral medullary syndrome. *South Med J* 1982; 75:65–67

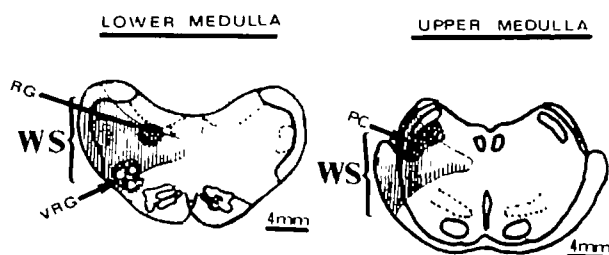


FIGURE 1. Putative respiratory centers incorporated in bulbar stroke. DRG, dorsal respiratory nucleus; VRG, ventral respiratory group; PC, nucleus parabrachialis medialis; WS, Wallenberg stroke, thrombosis of circumferential artery. Modified from Poiras and Parent<sup>27</sup> with authors' permission.

5. Levin BE, Margolis G: Acute failure of automatic respiration secondary to a unilateral brainstem infarct. *Ann Neurol* 1977;1:583-586
6. Mullan S, Hosobuchi Y: Respiratory hazards of high cervical cord percutaneous cordotomy. *J Neurosurg* 1968;28:291-297
7. Krieger AJ, Rosomoff HL: Sleep-induced apnea: A respiratory and autonomic dysfunction syndrome following bilateral percutaneous cervical cordotomy. *J Neurosurg* 1974;39:168-180
8. Belmusto L, Brown E, Owens G: Clinical observations on respiratory and vasomotor disturbances as related to cervical cordotomies. *J Neurosurg* 1963;20:225-232
9. Tenicela R, Rosomoff HL, Feist J, Safar P: Pulmonary function following percutaneous cordotomy. *Anesthesiology* 1968;29:7-16
10. Adelman S, Dinner DS, Garen H, Little J, Nickerson P: Obstructive sleep apnea in association with posterior fossa neurologic disease. *Arch Neurol* 1984;41:509-510
11. Rodman T, Resnick ME, Berkovitz RD, Fennelly JF, Olivia J: Alveolar hypoventilation due to involvement of the respiratory centre by obscure disease of the CNS. *Am J Med* 1962;32:203-217
12. Haponik EF, Givens D, Angelo J: Syringobulbia-myelia with obstructive sleep apnea. *Neurology* 1983;33:1046-1049
13. Sarnoff S, Wittenberger J, Affeldt J: Hypoventilation syndrome in poliomyelitis. *JAMA* 1951;174:30-34
14. Plum F, Swanson AG: Abnormalities in control regulation of respiration in acute and convalescent poliomyelitis. *Arch Neurol Psychiatry* 1958;80:267-285
15. Chokroverty S, Sachdeo R, Masden J: Autonomic dysfunction and sleep apnea in olivopontocerebellar degeneration. *Arch Neurol* 1984;41:926-931
16. Beal MF, Richardson EP, Brandstetter R, Hedley-Whyte E, Hohberg FH: Localized brainstem ischemic damage and Ondine's curse after near-drowning. *Neurology* 1983;33:717-721
17. Guilleminault C, Venicut W: *Sleep Apnea Syndromes. Kroc Foundations Series*. New York, Allan R Liss Inc, 1978, vol 11
18. Krieger A: Respiratory failure as a surgical risk in patients with hindbrain abnormalities. *Heart Lung* 1973;2:546-551
19. Boor JW, Johnson RJ, Canoles L, Dunn DP: Reversible paralysis of automatic respiration in multiple sclerosis. *Arch Neurol* 1977;34:686-689
20. McGinty DJ: Physiological equilibrium and the control of sleep states, in McGinty DJ (ed): *Brain Mechanism of Sleep*. New York, Raven Press Publishers, 1985, pp 361-384
21. Orem JM: Behaviour of respiratory cells during NREM sleep, in McGinty DJ (ed): *Brain Mechanism of Sleep*. New York, Raven Press Publishers, 1985, pp 341-359
22. Kleitman N: *Sleep and Wakefulness*. Chicago/London, University of Chicago Press, 1963
23. Guilleminault C, Cumiskey J, Dement WC: Sleep apnea syndrome - Recent advances. *Adv Intern Med* 1980;26:347-372
24. Guilleminault C, Eldridge FL, Tilkian A, Simmons FB, Dement WC: Sleep apnea syndrome due to upper airway obstruction. *Arch Intern Med* 1972;137:296-300
25. Guilleminault C, Tilkian A, Dement W: The sleep apnea syndrome. *Annu Rev Med* 1976;27:465-487
26. Snyderman NL, Johnson JT, Moller M, Thearle PB: Brainstem evoked potentials in adult sleep apnea. *Ann Otol Rhinol Laryngol* 1982;91:597-598
27. Poitras D, Parent H: Atlas of the distribution of monoamine containing nerve cell bodies in the brain stem of the cat. *J Comp Neurol* 1978;179:699-717
28. Brouillette R, Thach BA: Neuromuscular mechanisms maintaining extrathoracic airway potency. *J Appl Physiol* 1979;46:772-779
29. Severinghaus JW, Mitchell RA: Ondine's curse: Failure of respiratory centre automatically while awake (abstract). *Clin Res* 1962;10:122
30. DeKoninck J, Gagnon P, Lallier S: Sleep positions in the young adult and their relationship with the subjective quality of sleep. *Sleep* 1983;6:52-59
31. Cartwright RD: Effect of sleep position on sleep apnea severity. *Sleep* 1984;7:110-114

---

KEY WORDS • sleep apnea • brainstem • cerebrovascular disorders