

Pure Sensory Stroke Due to a Pontine Lacune

M. Hommel, MD, G. Besson, MD, P. Pollak, MD, F. Borgel, MD,
J.F. Le Bas, MD, and J. Perret, MD

A 53-year-old hypertensive man presented with the sudden onset of an isolated lemniscal sensory syndrome of the entire left side of his body. Magnetic resonance images showed a small lacune in the right paramedian pons corresponding to the location of the medial lemniscus. (*Stroke* 1989;20:406–408)

In 1965, Fisher¹ described the clinical syndrome of pure sensory stroke (PSS), consisting of a persistent or transient hemisensory disturbance. He concluded that the responsible lesion was a lacunar infarct in the posteroventral nucleus of the contralateral thalamus. Only two additional patients have been studied pathologically, corroborating this hypothesis.² Since then, lesions involving the thalamocortical^{3,4} or subthalamic^{5,6} sensory pathways have been described. The only pontine lesion responsible for a PSS syndrome was a hematoma.⁶ We report a case of PSS resulting from a pontine lacunar infarct, studied with magnetic resonance imaging (MRI).

Case Report

A 53-year-old man developed a sensation of pins and needles in his left arm, which lasted for a few hours. He was hospitalized 10 days later, after the onset of numbness and tingling over the entire left side of his body. Light touch or the rubbing of clothes on any part of his left side increased the tingling sensations.

On examination there was hypesthesia for discriminative and light touch sensation over his entire left side. Joint position and vibration senses were also decreased in his left limbs. However, pain and temperature sensation and stereognosis were within normal limits. With his eyes open, tests of limb coordination were normal, but ataxia was present when he was tested with his eyes closed. Power in his limbs, visual fields, cranial nerves, and tendon reflexes were normal, and Babinski's sign was absent. Neuropsychological examination was normal. His symptoms and signs cleared within 36 hours. The patient had a history of hypertension,

myocardial infarction, and peripheral vascular disease and smoked cigarettes. A computed tomogram (CT scan) without contrast enhancement on the day of admission was normal.

MRI was performed 9 days after the onset of the stroke using a CGR Magniscan with a 0.5-T superconducting magnet. Joined axial T2-weighted (spin-echo: repetition time [TR]=2000 msec, echo time [TE]=60 or 120 msec) images were obtained from the medulla to the vertex with a slice thickness of 9 mm. A sharply delineated hyperintense signal was shown in the right paramedian pons at the junction of the basis pons and the tegmentum (Figure 1). Joined T1 (gradient echo: TR=300 msec, TE=14 msec) images, centered on the lesion, were acquired in the frontal plane with a slice thickness of 9 mm. A hypointense signal was shown at the junction of the upper one third and lower two thirds of the pons in the right paramedian area (Figure 2).

Discussion

Only four cases of PSS have been studied pathologically; three were thalamic lacunes,^{1,2} and one was a slit hemorrhage in the posterior limb of the internal capsule.³ CT scan is usually normal, presumably because of the smaller size of lacunes in PSS than in other lacunar syndromes,⁷ and CT-documented thalamic lacunes have seldom been reported.^{4,8,9} The sensitivity of MRI is higher than that of CT in the diagnosis of lacunar infarcts, and thalamic lacunes have been reported in two of three cases of PSS.¹⁰ However, thalamic hematomas may also be responsible for PSS.^{4,11} Fisher¹ stated that a PSS could arise from a lesion anywhere along the sensory pathways from the cortex to the medulla, and lesions on the thalamocortical pathways have been reported^{3,4}; however, only two hematomas have been reported in the subthalamic sensory pathways.^{5,6} In our case a normal CT scan, a well-delineated homogeneous hyperintense signal on T2-weighted MRI, and a hypointense signal on T1-weighted MRI in the paramedian part of the

From the Clinique Neurologique (M.H., G.B., P.P., F.B., J.P.) and the MRI Unit (J.F.L.B.), Centre Hospitalier Universitaire Grenoble, Grenoble, France.

Address for correspondence: M. Hommel, Clinique Neurologique, BP 217 X, 38043 Grenoble, Cedex, France.

Received June 2, 1988; accepted September 1, 1988.

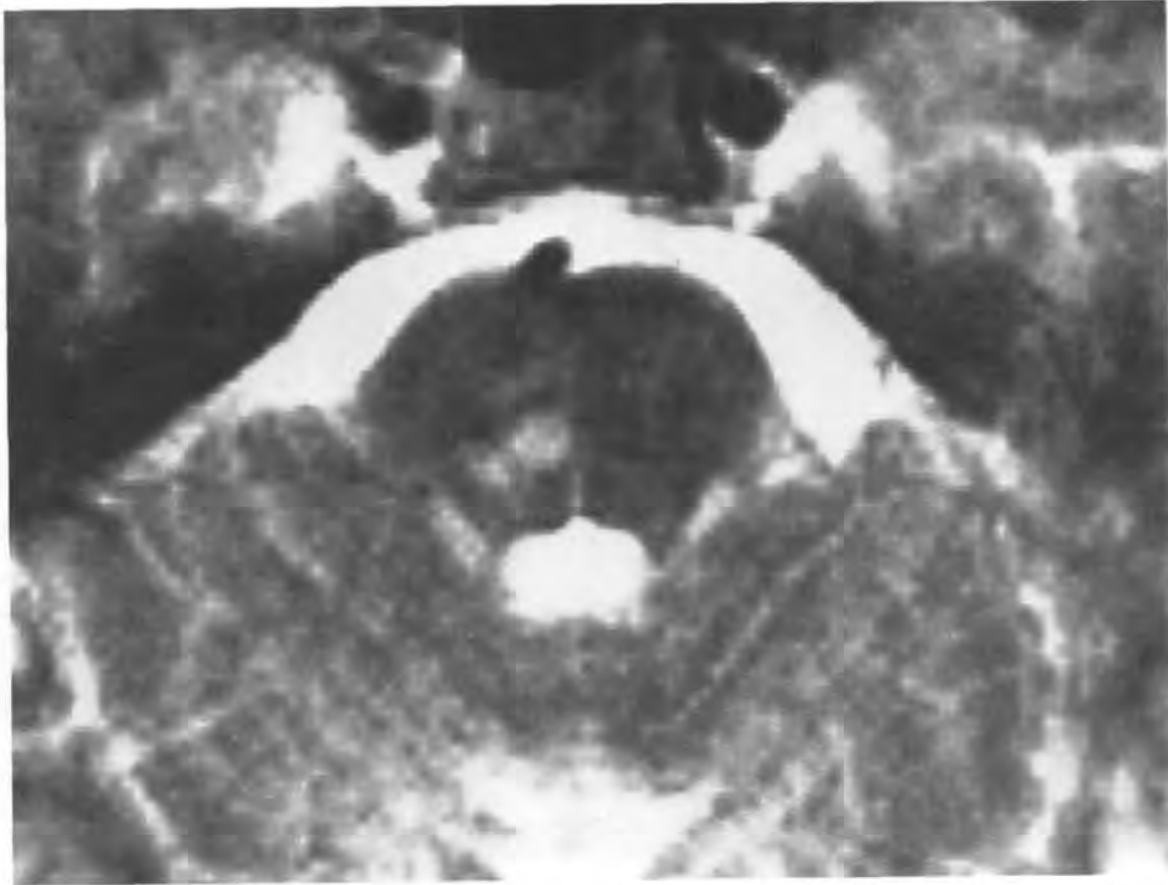


FIGURE 1. Axial T2-weighted magnetic resonance image showing hyperintense signal in right paramedial tegmentum of pons in 53-year-old hypertensive man with pure sensory stroke.

pons at the junction of the basis pons and the tegmentum are consistent with a lacunar infarct corresponding to the location of the medial lemniscus. As in the reported case of a pontine hemorrhage presenting as PSS,⁶ only medial lemniscal sensory modalities were involved, with preservation of the spinothalamic forms. This selective sensory loss was predicted for brainstem lacunes¹ but is not specific for this topography as it has been described from a thalamic lacune¹² and in a small cortical infarct.¹³ It has been suggested that numbness of the abdomen and trunk in PSS is a sign indicative of a thalamic site of the lesion.¹⁴ Our pontine lacune case presented with this symptom; therefore, the localizing value of this clinical finding may be unreliable. Taking into account the low mortality due to PSS, neuropathologic verification is rarely possible; thus, MRI appears to be most valuable in the topographic delineation of lacunar infarcts.

Acknowledgment

The authors thank Dr. J. Bamford for the translation of the manuscript.

References

1. Fisher CM: Pure sensory stroke involving face, arm and leg. *Neurology* 1965;15:76–80
2. Fisher CM: Thalamic pure sensory stroke: A pathologic study. *Neurology* 1978;28:1141–1144
3. Groothuis DR, Duncan GW, Fisher CM: The human thalamocortical sensory path in the internal capsule: Evidence from a small capsular hemorrhage causing a pure sensory stroke. *Ann Neurol* 1977;2:328–331
4. Rosenberg NL, Koller R: Computerized tomography and pure sensory stroke. *Neurology* 1981;32:217–220
5. Tuttle PV, Reinmuth OM: Midbrain hemorrhage producing pure sensory stroke. *Arch Neurol* 1984;41:794–795
6. Graveleau P, Decroix JP, Samson Y, Masson M, Cambier J: Déficit sensitif isolé d'un hémicorps par hématome du pont. *Rev Neurol (Paris)* 1986;142:788–790
7. Robinson RK, Richey ET, Kase CS, Mohr JP: Somatosensory evoked potentials in pure sensory stroke and related conditions. *Stroke* 1985;5:818–823
8. Landi G, Anzalone N, Vaccari U: CT scan evidence of posterolateral thalamic infarction in pure sensory stroke. *J Neurol Neurosurg Psychiatry* 1984;47:570–571
9. Gorsselink EL, Lodder J: Pure sensory stroke with lacunar infarction in the posterior ventral thalamus on CT. *Clin Neurol Neurosurg* 1985;87:45–46
10. Rothrock JF, Lyden PD, Hesselink JR, Brown JJ, Healy ME: Brain magnetic resonance imaging in the evaluation of lacunar stroke. *Stroke* 1987;18:781–786
11. Azouvi P, Pappata S, Baron JC, Bousser MG, Laplane D: Attaque sensitive pure par hématome thalamique. *Rev Neurol (Paris)* 1988;144:212–214
12. Sacco RL, Bello JA, Traub R, Brust JCM: Selective proprioceptive loss from a thalamic lacunar stroke. *Stroke* 1987;18:1160–1163
13. Dérouesné C, Mas JL, Bolgert F, Castaigne P: Pure sensory stroke caused by a small cortical infarct in the middle cerebral artery territory. *Stroke* 1984;15:660–662

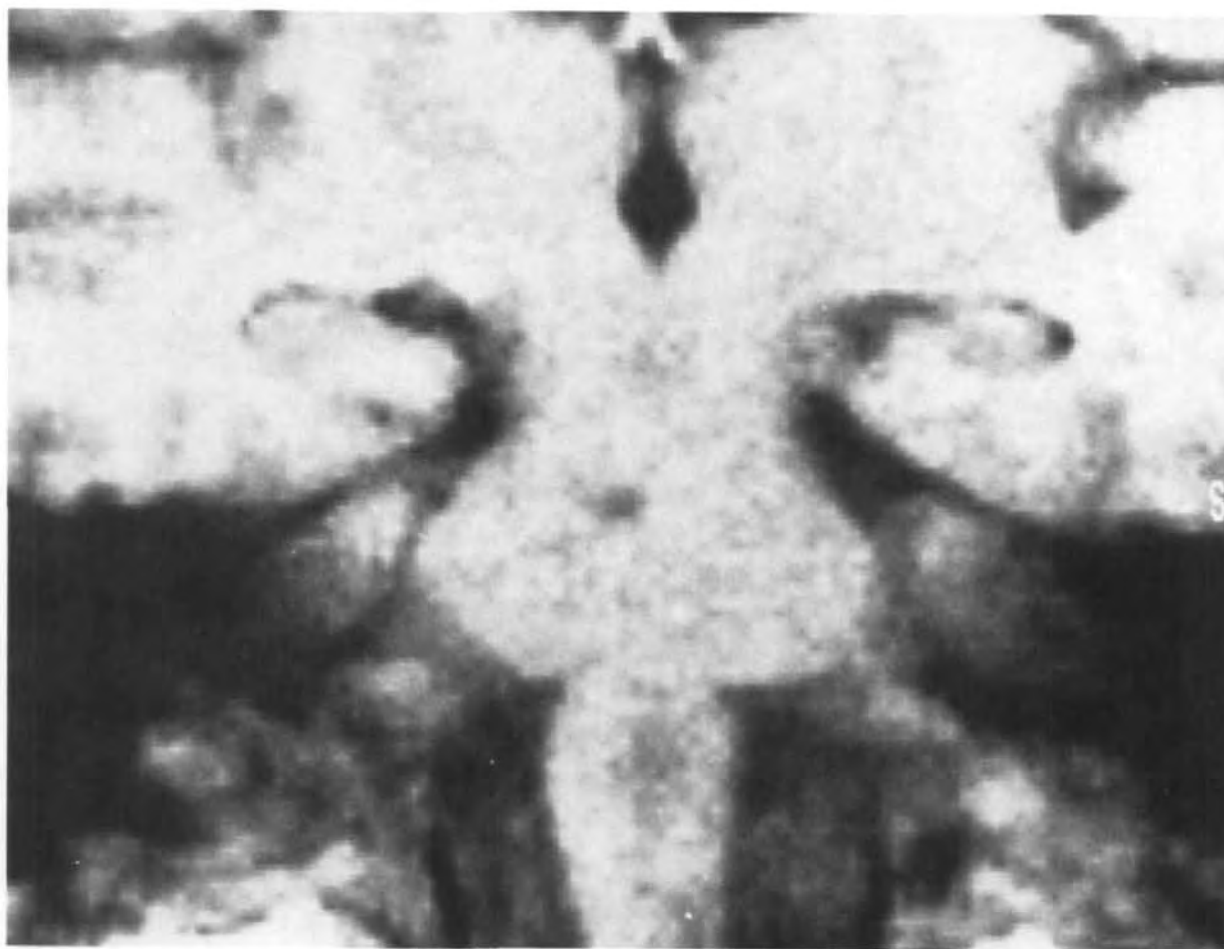


FIGURE 2. *Frontal T1-weighted magnetic resonance image showing hypointense signal in right paramedian area at junction of upper one third and lower two thirds of pons in 53-year-old hypertensive man with pure sensory stroke.*

14. Fisher CM: Pure sensory stroke and allied conditions. *Stroke* 1982;13:434-447

KEY WORDS • hemiplegia • lacunar infarction • magnetic resonance imaging