

# Hypoperfusion and Vasoreactivity in the Thalamus and Cerebellum After Stroke

Yasuo Sakashita, MD; Hiroshi Matsuda, MD; Kiyoshi Kakuda, MD; and Masaharu Takamori, MD

**Background and Purpose:** Cerebellar hypoperfusion in the contralateral hemisphere after stroke is well studied and termed crossed cerebellar diaschisis. However, studies of hypoperfusion in the ipsilateral thalamus have been few. The purpose of this study was to investigate the prevalence of hypoperfusion and vasoreactivity to acetazolamide in the thalamus and cerebellum after stroke.

**Methods:** We studied cerebral blood perfusion in the thalamus and cerebellum of 14 patients with unilateral cerebral infarction using [ $^{123}\text{I}$ ]isopropylidoamphetamine single-photon emission computed tomography ( $^{123}\text{I}$ -IMP SPECT). We also administered acetazolamide-stressed  $^{123}\text{I}$ -IMP SPECT to determine vasodilator capacity in these two areas. Regions of interest were drawn over the bilateral thalami and bilateral cerebellar cortices, and asymmetry indexes were obtained.

**Results:** We found ipsilateral thalamic hypoperfusion in 12 (85.7%) and contralateral cerebellar hypoperfusion in 11 (78.6%) of 14 patients. Hypoperfusion was improved ( $p < 0.01$  by the Wilcoxon signed rank test) in 11 (91.7%) of the 12 patients with ipsilateral thalamic hypoperfusion and in seven (63.6%) of the 11 patients with contralateral cerebellar hypoperfusion.

**Conclusions:** Hypoperfusion in the ipsilateral thalamus and contralateral cerebellum is common, and vasoreactivity to acetazolamide is preserved in both the thalamus and the cerebellum with hypoperfusion. (*Stroke* 1993;24:84–87)

**KEY WORDS** • acetazolamide • cerebellum • cerebral blood flow • thalamus • tomography, emission computed

Cerebral infarcts are known to be associated with cerebral hypoperfusion<sup>1</sup> and hypometabolism<sup>2</sup> in distant areas of the brain. In the 1870s, Brown-Sequard described the concept that brain lesions produced excitatory and inhibitory effects causing disruption of function in regions distant from the site of damage.<sup>3</sup> Hypoperfusion in the cerebellum contralateral to the lesion is frequently observed. Baron et al<sup>2</sup> first described this phenomenon and termed it "crossed cerebellar diaschisis." Remote effects on cerebral perfusion have been observed in regions other than the contralateral cerebellum.<sup>4,5</sup> However, reports dealing with hypoperfusion in areas other than the cerebellum are rare, and the prevalence and characteristics of blood flow changes in the thalamus after stroke remain unclear.

We report on cerebral perfusion changes in the thalamus and cerebellum after stroke measured by using [ $^{123}\text{I}$ ]isopropylidoamphetamine ( $^{123}\text{I}$ -IMP) single-photon emission computed tomography (SPECT). Additionally, we performed acetazolamide-stressed  $^{123}\text{I}$ -IMP SPECT to investigate vasodilator capacity<sup>1</sup> in the

thalamus and cerebellum in which hypoperfusion was observed.

## Subjects and Methods

### Subjects

We examined 14 consecutive patients (patient group: eight men and six women; mean  $\pm$  SD age  $76.2 \pm 7.3$  years) with unilateral cerebral hemispheric ischemic lesions confirmed by magnetic resonance imaging. Profiles of the patients are shown in Table 1. All lesions were confined to the area that receives blood from the middle or anterior cerebral artery. No vascular lesions in the thalamus or cerebellum were observed in any patient. To demonstrate the reproducibility of SPECT, five patients (reproducibility group: four men and one woman, age  $72.0 \pm 11.5$  years) with unilateral cerebral infarction who fulfilled the same criteria as above participated. The mean interval from onset of symptoms to the first SPECT examination was  $12.2 \pm 5.54$  days for the patient group and  $11.2 \pm 6.14$  days for the reproducibility group. No significant difference in this interval between these two groups was demonstrated by Student's  $t$  test. Six normal subjects (normal group: five men and one woman, age  $66.0 \pm 10.5$  years) free of neurological deficits and cerebral lesions underwent SPECT without acetazolamide to establish the normal range of the asymmetry index (AI, defined below). There was no significant difference in age among these three groups, as determined by Student's  $t$  test. Informed consent was obtained from all patients and normal subjects.

From the Departments of Neurology (Y.S.) and Radiology (K.K.), Tonami General Hospital, Tonami, and the Departments of Nuclear Medicine (H.M.) and Neurology (M.T.), Kanazawa University School of Medicine, Kanazawa, Japan.

Address for correspondence: Yasuo Sakashita, MD, Department of Neurology, Tonami General Hospital, 1-61 Shintomi-Cho, Tonami, Toyama 939-13, Japan.

Received July 21, 1992; final revision received September 4, 1992; accepted September 24, 1992.

TABLE 1. Profile of Patients

Pt	Age (yr)	Sex	Lesion	Aphasia	Neglect*	Ataxia	Days from onset to 1st SPECT
1	87	F	R MCA (including Cx)	No	Yes	No	10
2	81	M	R MCA	No	No	No	5
3	77	F	R basal ganglia	No	Yes	No	16
4	69	F	L basal ganglia+DWM	No	No	Yes	10
5	68	M	L MCA	No	No	Yes	14
6	81	F	L MCA-ACA	Yes	No	No	22
7	68	F	L MCA	Yes	No	No	18
8	82	M	L MCA	No	No	No	10
9	72	M	L ACA (including Cx)	Yes	Yes	No	6
10	78	M	L MCA	No	No	No	13
11	80	F	L MCA	No	No	No	10
12	86	M	L basal ganglia	Yes	No	No	8
13	61	M	L MCA	No	No	Yes	7
14	77	M	L ACA	No	No	No	22

SPECT, single-photon emission computed tomography; F, female; M, male; R, right; L, left; MCA, middle cerebral artery territory; Cx, cerebral cortex; DWM, deep white matter; ACA, anterior cerebral artery territory.

\*Visual unilateral spatial neglect examined by line bisection test.<sup>6</sup>

### Single-Photon Emission Computed Tomography

Brain perfusion studies using 148 MBq (4 mCi) of  $^{123}\text{I}$ -IMP with or without acetazolamide were carried out. The SPECT system was a rotating gamma camera (GCA-901A, Toshiba, Tokyo, Japan) combined with an image-processing minicomputer (GMS-550U, Toshiba). System resolution was 12 mm at full-width half-maximum for  $^{123}\text{I}$ -IMP. A SPECT study without acetazolamide was performed by collecting projection data 20 minutes after injection of  $^{123}\text{I}$ -IMP. A SPECT study with acetazolamide was performed separately with  $^{123}\text{I}$ -IMP injected 10 minutes after a parenteral injection of 1 g acetazolamide. For all subjects, data were acquired from 60 angles ( $6^\circ$ -steps,  $360^\circ$ ) for 30 seconds per angle. Projection data were processed with Butterworth filters. For analysis, in each subject regions of interest (ROIs) were drawn over the bilateral thalami and bilateral cerebellar cortices. The AI was calculated as  $200 \times (C_R - C_L) / (C_R + C_L)$ , where  $C_R$  is the mean reconstructed counts for the right ROI and  $C_L$  is the mean reconstructed counts for the left ROI in each SPECT study.

### Reproducibility of Asymmetry Index

To exclude the possibility that the interval from the first to the second SPECT study might produce AI changes in the patient group, we examined the reproducibility of AI. Reproducibility in the thalamus and cerebellum was evaluated as the absolute change of AI between the first and second studies in the reproducibility group. The patient group received the first SPECT study without acetazolamide followed by a second SPECT study with acetazolamide. The reproducibility group received the first SPECT study without acetazolamide followed by a second SPECT study, again without acetazolamide. The interval from the first to the second study was  $12.9 \pm 4.27$  days for the patient group and  $9.20 \pm 2.99$  days for the reproducibility group. There was no significant difference in this interval between these two groups by Student's *t* test.

### Results

#### Case Report (Patient 12)

An 86-year-old man with right hemiparesis was admitted. Magnetic resonance imaging of his head demonstrated infarction in the left basal ganglia and mild atrophy of the right temporal lobe. Magnetic resonance angiography of the cerebral vessels demonstrated moderate atherosclerotic change in the cerebral arteries, while severe stenotic change was not observed in the basilar and posterior cerebral arteries. Eight days after the onset of right hemiparesis, the first SPECT study, without acetazolamide (Figure 1, A and B), was performed; AI was 15.4 in the thalamus and 18.3 in the cerebellum. The second SPECT study, with acetazolamide (Figure 1, C and D), was performed 21 days after onset of symptoms; AI in the thalamus decreased to 3.01 and AI in the cerebellum to 5.15.

#### Normal Values

Mean  $\pm$  SD AI in the normal group was  $3.85 \pm 1.58$  in the thalamus and  $3.13 \pm 1.04$  in the cerebellum. Reproducibility of AI was  $1.90 \pm 0.98$  in the thalamus and  $1.50 \pm 1.38$  in the cerebellum. We judged that hypoperfusion was evident when a patient had an AI greater than the mean  $\pm 2$  SD of normal AI (i.e., AI greater than 7.01 in the thalamus and 5.21 in the cerebellum). We considered that acetazolamide stress was effective for improving AI when the AI decrease was greater than the mean  $\pm 2$  SD of the reproducibility of AI (i.e., an AI decrease of greater than 3.86 in the thalamus and 4.26 in the cerebellum).

#### SPECT Without Acetazolamide

Twelve of the 14 patients had AI values higher than 7.01 in the thalamus. In these patients, blood flow in the ipsilateral thalamus was less than in the thalamus contralateral to the lesion. Eleven of the 14 patients had AI values greater than 5.21 in the cerebellum, and blood flow in the cerebellum contralateral to the lesion was lower than in the ipsilateral region. These results indi-

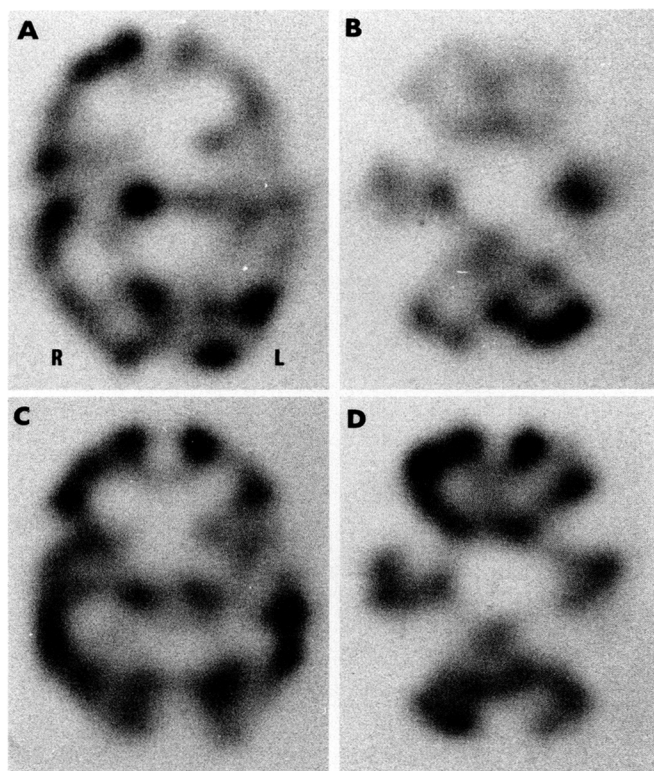


FIGURE 1. [ $^{123}\text{I}$ ]Isopropylidoamphetamine single-photon emission computed tomograms with (bottom) and without (top) acetazolamide infusion in patient 12. Without acetazolamide infusion, ipsilateral thalamic (A) and contralateral cerebellar (B) hypoperfusion is evident. After acetazolamide infusion, hypoperfusion in thalamus (C) and cerebellum (D) is lessened. R, right side of patient; L, left side of patient.

cate that ipsilateral thalamic hypoperfusion was present among 85.7% of the patients and contralateral cerebellar hypoperfusion among 78.6%. Mean  $\pm$  SD AI was  $14.0 \pm 5.79$  in the thalamus and  $12.2 \pm 6.19$  in the cerebellum.

#### SPECT With Acetazolamide

In 11 of the 12 patients with ipsilateral thalamic hypoperfusion, acetazolamide-stressed SPECT demonstrated AI decreases of greater than 3.86 in the thalamus compared with the AI of SPECT without acetazolamide. Among the 11 patients who had an abnormal AI in the thalamus demonstrated by the first SPECT study, only patient 3 (with a basal ganglia lesion) did not show a significant AI decrease with acetazolamide stress. In seven of the 11 patients with contralateral cerebellar hypoperfusion, acetazolamide-stressed SPECT demonstrated AI decreases of greater than 4.26 in the cerebellum compared with the AI of SPECT without acetazolamide. These results indicate that 91.7% of the patients with ipsilateral thalamic hypoperfusion and 63.6% of the patients with contralateral cerebellar hypoperfusion improved with acetazolamide stress. Mean  $\pm$  SD AI decreased to  $5.49 \pm 3.62$  in the thalamus and  $6.43 \pm 5.39$  in the cerebellum. AIs for both the thalamus (Figure 2) and the cerebellum (Figure 3) improved significantly with acetazolamide stress, as examined by the Wilcoxon signed rank test.

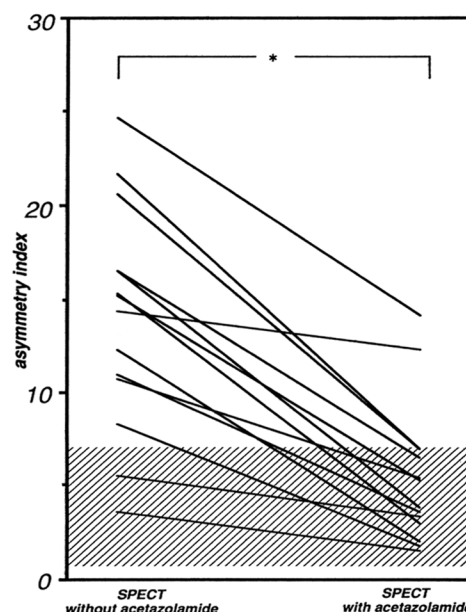


FIGURE 2. Plot of changes in asymmetry index (AI) in thalamus of each patient between single-photon emission computed tomography (SPECT) with and without acetazolamide stress. Shaded area shows mean  $\pm$  2 SD AI in thalamus of six normal subjects. \* $p < 0.01$  by Wilcoxon signed rank test.

#### Discussion

The results demonstrate a high prevalence of hypoperfusion after unilateral hemispheric cerebrovascular lesions in both the ipsilateral thalamus and the contralateral cerebellum. There have been few clinical studies of hypoperfusion in the ipsilateral thalamus, while hy-

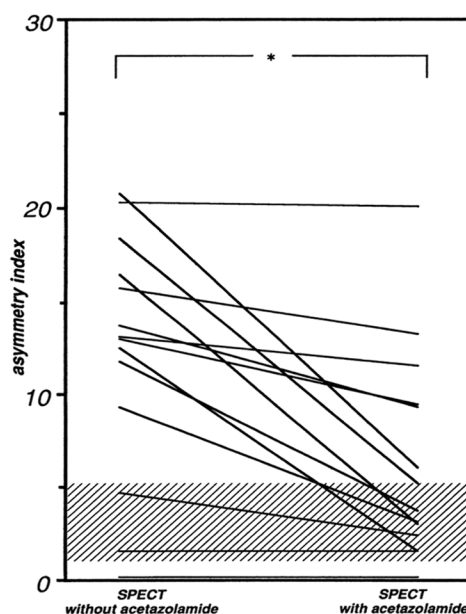


FIGURE 3. Plot of changes in asymmetry index (AI) in cerebellum of each patient between single-photon emission computed tomography (SPECT) with and without acetazolamide stress. Shaded area shows mean  $\pm$  2 SD AI in cerebellum of six normal subjects. \* $p < 0.01$  by Wilcoxon signed rank test.

hypoperfusion in the contralateral cerebellum has attracted much interest.<sup>2,4,5,7</sup> Kuhl et al<sup>4</sup> studied cerebral blood flow and the cerebral metabolic rate for glucose and reported that ipsilateral thalamic dysfunction was observed in five of 10 patients with ischemic stroke. Wise et al<sup>5</sup> observed decreases of about 30–40% in cerebral blood flow and the cerebral metabolic rate for oxygen in the thalamus ipsilateral to cerebral infarction. An experimental study<sup>8</sup> confirmed that local blood flow in the thalamus decreased on the ischemic side in rats with middle cerebral artery occlusion. Our results are consistent with these reports even though ipsilateral thalamic hypoperfusion was more frequently observed.

Acetazolamide is a potent carbonic anhydrase inhibitor, exhibiting complete physiological inhibition of carbonic anhydrase in the red blood cells within 1 minute after the rapid intravenous injection of 1 g of the drug.<sup>9</sup> Acetazolamide has been used to test cerebral vasodilatory capacity.<sup>1</sup> The intravenous injection of acetazolamide increases both cerebral and cerebellar blood flow within minutes in normal subjects.<sup>1,10</sup> Patients with impaired cerebrovascular hemodynamic reserve show an attenuated or abolished response to acetazolamide in the region of affected perfusion.<sup>1,10</sup> Our results demonstrate that 91.7% of the patients with ipsilateral thalamic hypoperfusion and 63.6% of the patients with contralateral cerebellar hypoperfusion showed improved AI after acetazolamide stress. Bogsrud et al<sup>7</sup> reported that blood flow was increased by the effect of acetazolamide in the contralateral cerebellum with hypoperfusion and concluded that the cerebellar vasodilatory capacity was intact. Our results indicate that the vasodilatory response to acetazolamide after stroke is also well preserved in the thalamus.

Improvement of hypoperfusion with acetazolamide was highly evident in both the thalamus and the cerebellum in the present study. To our knowledge, only Matsuda et al<sup>11</sup> have reported acetazolamide effects on ipsilateral thalamic hypoperfusion, using technetium-99m hexamethylpropyleneamine oxime SPECT. They reported that six of 10 patients showed hypoperfusion in the thalamus ipsilateral to the lesion. After acetazolamide infusion, all six patients with thalamic hypoperfusion showed augmented perfusion in the affected thalamus compared with the unaffected side.<sup>11</sup> Our results are consistent with these results. We believe that ours is the first report of hypoperfusion and vasodilatory capacity in the thalamus and cerebellum after stroke using <sup>123</sup>I-IMP SPECT, which provides high-quality images to detect mild ischemic lesions.<sup>12</sup>

Contralateral cerebellar atrophy is observed after stroke.<sup>13–16</sup> Similarly, ipsilateral thalamic atrophy may be clinically observed after stroke.<sup>17</sup> Fujie et al<sup>18</sup> reported progressive shrinkage of the thalamus following middle cerebral artery occlusion in rats and speculated that retrograde degeneration may play an important role. Kataoka et al<sup>19</sup> reported decreased glucose utilization in the thalamus after middle cerebral artery occlusion. They also reported synaptic terminal degen-

eration in the thalamus and suggested that retrograde degeneration of thalamic neurons occurs after thalamocortical pathway injury.<sup>19</sup> The clinical importance of diaschisis is controversial. Because we did not undertake a long-term follow-up study, we cannot conclude whether disturbed vasodilatory capacity as demonstrated by acetazolamide stress is predictive of thalamic atrophy after stroke. However, thalamic hypoperfusion due to decreased metabolic demand may be a cause of thalamic atrophy after stroke.

## References

1. Vorstrup S: Tomographic cerebral blood flow measurements in patients with ischemic cerebrovascular disease and evaluation of the vasodilatory capacity by acetazolamide test. *Acta Neurol Scand Suppl* 1988;114:1–48
2. Baron JC, Boussier MG, Comar D, Castaigne P: "Crossed cerebellar diaschisis" in human supratentorial infarction. (abstract) *Ann Neurol* 1980;8:128
3. Feeney DM, Baron J-C: Diaschisis. *Stroke* 1986;17:817–830
4. Kuhl DE, Phelps ME, Kowell AP, Metter EJ, Selin C, Winter J: Effects of stroke on local cerebral metabolism and perfusion: Mapping by emission computed tomography of <sup>18</sup>FDG and <sup>15</sup>NH<sub>3</sub>. *Ann Neurol* 1980;8:47–60
5. Wise RJS, Bernardi S, Frackowiak RSJ, Legg NJ, Jones T: Serial observations on the pathophysiology of acute stroke: The transition from ischaemia to infarction as reflected in regional oxygen extraction. *Brain* 1983;106:197–222
6. Sakashita Y: Visual attentional disturbance with unilateral lesions in the basal ganglia and deep white matter. *Ann Neurol* 1991;30:673–677
7. Bogsrud TV, Rootwelt K, Russell D, Nyberg-Hansen R: Acetazolamide effect on cerebellar blood flow in crossed cerebral-cerebellar diaschisis. *Stroke* 1990;21:52–55
8. Tamura A, Graham DI, McCulloch J, Teasdale GM: Focal cerebral ischaemia in the rat: 2. Regional cerebral blood flow determined by [<sup>14</sup>C]iodoantipyrine autoradiography following middle cerebral artery occlusion. *J Cereb Blood Flow Metab* 1981;1:61–69
9. Maren TH: Carbonic anhydrase: Chemistry, pharmacology, and inhibition. *Physiol Rev* 1967;47:595–781
10. Højer-Pedersen E: Effect of acetazolamide on cerebral blood flow in subacute and chronic cerebrovascular disease. *Stroke* 1987;18:887–891
11. Matsuda H, Tsuji S, Sumiya H, Higashi S, Kinuya K, Tonami N, Hisada K, Yamashita J: Acetazolamide effect on vascular response in areas with diaschisis as measured by Tc-99m HMPAO brain SPECT. *Clin Nucl Med* 1992;17:581–586
12. Nakano S, Kinoshita K, Jinnouchi S, Hoshi H, Watanabe K: Comparative study of regional cerebral blood flow images by SPECT using xenon-133, iodine-123 IMP, and technetium-99m HM-PAO. *J Nucl Med* 1989;30:157–164
13. Hassin GB: Crossed atrophy of the cerebellum: Pathologic study of a case. *Arch Neurol Psychiatry* 1935;33:917–928
14. Streifling AM, Ulrich H: Crossed cerebellar atrophy: An old problem revisited. *Acta Neuropathol (Berl)* 1982;57:197–202
15. Baudrimont M, Gray F, Meininger V, Escourolle R, Castaigne P: Atrophie cérébelleuse croisée après lésion hémisphérique survenue à l'âge adulte. *Rev Neurol (Paris)* 1983;139:485–495
16. Chung HD: Retrograde crossed cerebellar atrophy. *Brain* 1985;108:881–895
17. Tamura A, Tahira Y, Nagashima H, Kirino T, Gotoh O, Hojo S, Sano K: Thalamic atrophy following cerebral infarction in the territory of the middle cerebral artery. *Stroke* 1991;22:615–618
18. Fujie W, Kirino T, Tomukai N, Iwasawa T, Tamura A: Progressive shrinkage of the thalamus following middle cerebral artery occlusion in rats. *Stroke* 1990;21:1485–1488
19. Kataoka K, Hayakawa T, Yamada K, Mushiroi T, Kuroda R, Mogami H: Neuronal network disturbance after focal ischemia in rats. *Stroke* 1989;20:1226–1235