

Skin Blood Pressure in the Forehead in Patients With Internal Carotid Lesions

BY P. E. NIELSEN, M.D., P. HÜBBE, M.D., AND H. LØNSMAN POULSEN, M.D.

Abstract:
Skin Blood Pressure in the Forehead in Patients With Internal Carotid Lesions

■ The skin blood pressure was measured in the forehead using a photoelectric method in 12 subjects with occlusion and 16 subjects with arteriosclerotic stenosis of the internal carotid artery and compared to 18 normal subjects. The skin blood pressure was in average 37 mm Hg (SD 15) in the patients with occlusion, 44 mm Hg (SD 16) in the patients with stenosis, and 46 mm Hg (SD 10) in the normal subjects. During interruption of the blood supply from the external carotid artery (manual compression of the ipsilateral superficial temporal artery), the skin blood pressure was reduced in average 14 mm Hg in the patients with internal carotid occlusion, 8 mm Hg in the patients with stenosis, and not at all in the normal subjects. Skin blood pressure measured on the arm was in all groups 10 to 20 mm Hg higher than the diastolic arm blood pressure. It is emphasized that this method, as well as other methods using extracerebral registration in an attempt to evaluate the intracerebral arteries, is interesting from a hemodynamic point of view, but is of less diagnostic value in the single patient when compared to the arteriographical investigation.

Additional Key Words
arteriolar blood pressure
photoelectric technique

collateral circulation in internal carotid lesions
internal carotid artery occlusion blood pressure
photoelectric plethysmography

Introduction

□ Various methods have been used during the last decade in an attempt to diagnose arteriosclerotic lesions in the intracerebral arteries by using measurements of the structures situated outside the skull. The methods have included ophthalmodynamometric studies,¹ measurements of pulse wave velocities,² thermographic studies,³ and recently indirect measurements of systolic blood pressure or flow measurements in the supraorbital artery using an ultrasonic technique.^{4, 5}

Reduction in skin blood pressure measured indirectly using a photoelectric technique or isotope clearance technique seems to be well correlated to the degree of arterial lesions in the deeper lying arteries in the legs.⁶⁻¹⁰ Therefore, we decided to evaluate the photoelectrical method in patients with internal carotid artery lesions using measurements in the frontal region, in the area where some of the collaterals between the external carotid artery (superficial temporal artery) and the internal carotid artery (supraorbital artery) are situated.

Methods

The study included three groups of subjects: 12 patients aged 47 to 82 years with occlusion of the internal carotid artery, 16 patients aged 51 to 79 years with arteriosclerotic stenosis

of the internal carotid artery, and 18 normal subjects aged 23 to 68 years. The arteriosclerotic lesions were diagnosed by ordinary arteriographical study with injection of contrast medium in the common carotid artery.

The method of measuring the skin blood pressure by using a photoelectric technique has previously been described in detail^{8, 9, 11} and shall be summarized briefly. A photoelectric probe (a cylinder 15 mm in width and 6 mm in height), containing a lamp (5 V) and a photoresistance unit (cadmium sulphide photoconductive cell), is taped to the frontal area about 3 cm from the midline and about 2 cm above the supercilium. Light is sent into the skin. Without any compression the photoresistance will record reflected light and the registered curve in normal subjects is quite similar to an ordinary pulse curve (photoelectric plethysmography). Using high counterpressure on the probe, the skin will be squeezed empty of blood, and the intensity of the reflected light will be almost constant (fig. 1). By slowly decreasing the counterpressure during registration of the intensity of the reflected light, it will be seen that the inflow of blood into the skin area beneath the probe begins at a fairly well defined counterpressure, which we have designated "the skin blood pressure." The counterpressure can easily be measured using an ordinary blood pressure cuff. In this study we have used a 10 x 60 cm cuff placed around the head.

In all subjects the following procedures have been followed: The subjects were placed in the supine position. The photoelectrical probe was placed in the frontal area as described, and double measurements of the skin blood pressure were performed on both sides, but only the results from the side where arteriographical investigation was carried out will be discussed. The skin blood pressure was measured twice on the lateral side of the right upper arm simultaneously with auscultatory measurements of the arm blood pressure using a 12 x 26 cm cuff. The diastolic blood

From the Departments of Neurology, Clinical Physiology and Internal Medicine C, Bispebjerg Hospital, DK-2400 Copenhagen, Denmark.

Reprint requests to Dr. Nielsen.

SKIN BLOOD PRESSURE IN PATIENTS WITH INTERNAL CAROTID LESIONS

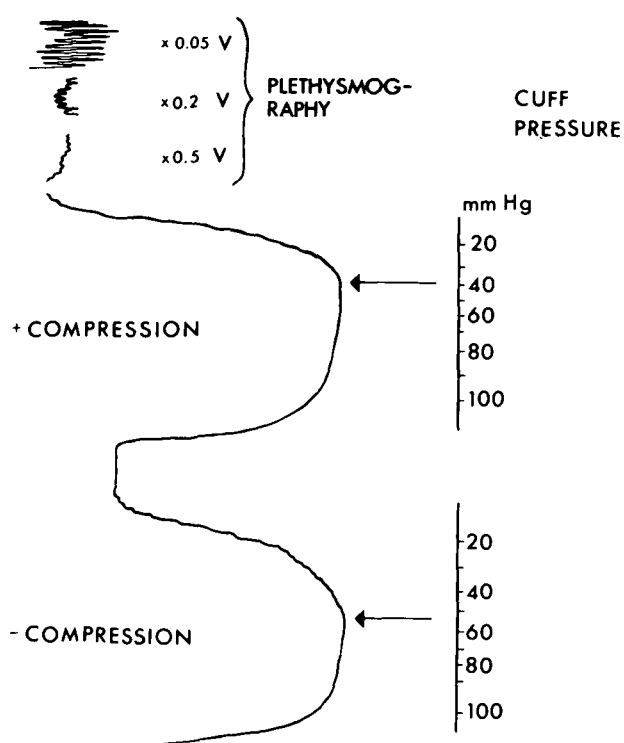


FIGURE 1

Skin blood pressure recorded from the forehead in a 57-year-old man with occlusion of the internal carotid artery. The two lower curves illustrate the measurement with and without compression of the superficial temporal artery. The plethysmographic curves above are recorded from the forehead with the photoelectric probe taped to the skin and using different amplification of the signal of reflected light.

pressure was recorded at the cessation of the Korotkoff sounds (phase V).

The paired t-test has been used in the statistical analysis.

TABLE 1

Skin Blood Pressure Measured by Photoelectric Technique in the Forehead in Patients With Arteriosclerotic Lesions in the Internal Carotid Artery Compared to Normal Subjects

		Skin blood pressure				Arm blood pressure	
		Forehead			Arm (mm Hg)	Systolic (mm Hg)	Diastolic (mm Hg)
		- Compression of superficial temporal artery (mm Hg)	+ Compression of superficial temporal artery (mm Hg)				
Internal carotid artery							
Occlusion	12	Mean	37	23	107	153	87
		SD	15	12	21	16	12
		Range	20 - 55	2 - 41	87 - 147	130 - 175	75 - 110
Stenosis	16	Mean	44	36	98	160	89
		SD	16	17	14	23	12
		Range	10 - 65	5 - 65	74 - 115	95 - 180	65 - 115
Normal subjects	18	Mean	46	45	82	114	72
		SD	10	11	12	10	6
		Range	25 - 70	18 - 88	65 - 145	100 - 190	65 - 105

Results

The results appear in table 1. In the forehead the skin blood pressure was in average between 37 and 46 mm Hg in the three groups and lowest among the patients with occlusion of the internal carotid artery. None of these differences are statistically significant. During compression of the superficial temporal artery the skin blood pressure was unchanged among the normal subjects, while a decrease was demonstrated among the patients with arteriosclerotic lesions of the internal carotid artery (in average 8 mm Hg among the patients with stenosis [$P < 0.05$] and 14 mm Hg among the patients with occlusion [$P < 0.01$]). The individual results appear in figure 2. It will be seen that in the three groups the individual values vary a good deal. Among 15 subjects in whom compression of the superficial temporal artery reduced the skin blood pressure by more than 10 mm Hg, only one had no arteriosclerotic lesions. In 9 of the 12 subjects with occlusion of the internal carotid artery the skin blood pressure was reduced more than 10 mm Hg during interruption of the blood supply from the external carotid artery.

Of these 12 subjects, six showed, at arteriography, retrograde filling of the intracranial vessels through the ophthalmic artery, and six did not show any anastomoses between the extracranial and intracranial vascular systems. However, no difference was found in the reduction of the skin blood pressure in the two groups.

Discussion

In previous investigations the skin blood pressure has been found to be about 10 to 20 mm Hg above the corresponding diastolic arm blood pressure, when measuring the skin blood pressure either on the arm or in the ankle region with the probe placed above an area without underlying bone.⁸⁻¹¹ This corresponds well to the skin blood pressure measured in these sub-

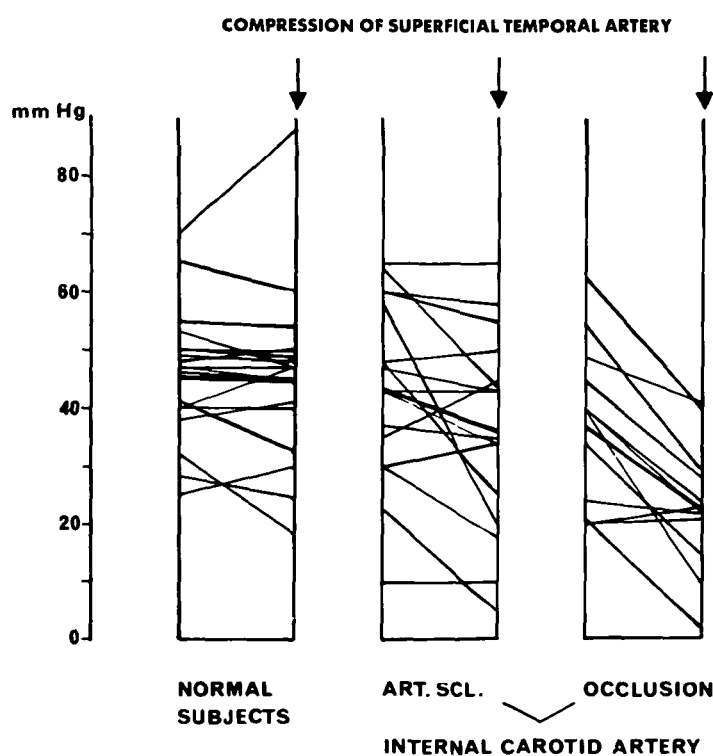


FIGURE 2

The individual skin blood pressures and mean values in the three groups of subjects. Values given in the right columns (arrows) are recorded during compression of the superficial temporal artery, and values in the left columns are recorded without manual compression of this artery.

jects in the upper arm. Previously we have discussed this skin blood pressure, and we have argued in favor of the pressure being an indirect measurement of the systolic blood pressure in the arteries of the skin.^{8, 9, 11} Another theory is that the skin blood pressure reflects the systemic blood pressure in the deeper lying arteries, as the skin blood pressure is fairly well correlated to systolic and diastolic as well as mean blood pressure in these arteries.¹⁰

Among our normal subjects the skin blood pressure in the forehead was in average about 45 mm Hg. This is about 20 mm Hg lower than the systolic blood pressure measured indirectly in the supraorbital artery by Wyatt et al.⁴ using an ultrasonic device and counterpressure produced by a little box placed directly over the artery. These authors also demonstrated that the systolic blood pressure in the supraorbital artery was reduced in arteriosclerotic subjects with intermittent claudication.

The explanation of the lower skin blood pressure in the forehead compared to the skin blood pressure on the arm is probably caused by the position of the cylindrical probe between the cuff and the bone, resulting in a higher pressure just beneath the probe than in the compressing cuff ("foreign body effect"). Low indirectly measured blood pressure in the skin

area just above the underlying bone has recently been demonstrated by Chavatzas and Jamieson,¹² who measured the skin blood pressure in the area just above the tibia compared to the opposite side of the leg where muscular tissue is underlying.

The clinical use of the reported measurements is of questionable value, mainly due to the individual variation in the reported groups of patients, and especially due to the fact that the collateral circulation within the brain might vary in patients with arteriosclerotic lesions of the internal carotid artery. Furthermore, severe arteriosclerotic lesions in the intracerebral arteries might be seen without affecting the supply of the ophthalmic artery arising from the internal carotid artery. In this statement the method is no better nor worse than other methods mentioned in the Introduction (ophthalmodynamometry, thermography, ultrasound technique, pulse wave velocity measurements). At present the final diagnosis of an arteriosclerotic lesion of the internal carotid artery can be made only by means of arteriography.

References

1. Eastcott HHG: Carotid-vertebral insufficiency. In Eastcott HHG (ed): Arterial Surgery. London, Pitman, p 145-179, 1969

SKIN BLOOD PRESSURE IN PATIENTS WITH INTERNAL CAROTID LESIONS

2. Price TR, Heck AF: Opacity pulse propagation measurement and thermometry in the evaluation of carotid occlusive vascular disease: Correlations with angiography. *Stroke* **3**:601-603, 1972
3. Mowdsley C, Samuel E, Sumerling MD, et al: Thermography in occlusive cerebrovascular diseases. *Brit Med J* **3**: 521-524, 1968
4. Wyatt AP, Ratnavel K, Loxton GE: The technique and possible application of supraorbital artery blood pressure estimation. *Brit J Surg* **60**:741-743, 1973
5. Brockenbrough EC: Screening for the prevention of stroke: Use of a Doppler flowmeter. University of Washington School of Medicine, Seattle
6. Nilsén R, Dahn I, Lassen NA, et al: On the estimation of local effective perfusion pressure in patients with obliterative arterial disease by means of external compression over a Xenon-133 depot. *Scand J Clin Lab Invest* **19** (Suppl 99):29-30, 1967
7. Dahn I, Lassen NA, Westling H: Blood flow in human muscles during external pressure or venous stasis. *Clin Sci* **32**:467-473, 1967
8. Nielsen PE, Poulsen HL, Gyntelberg F: Arterial blood pressure in the skin measured by a photoelectric probe and external counterpressure. *Vasa* **2**:65-74, 1973
9. Nielsen PE, Poulsen HL, Gyntelberg F: Skin blood pressure measured by a photoelectric probe and external counterpressure. *Scand J Clin Lab Invest* **31** (Suppl 128):137-141, 1973
10. Holstein P, Lassen NA: Radioisotope clearance technique for measurement of distal blood pressure in skin and muscles. *Scand J Clin Lab Invest* **31** (Suppl 128):143-147, 1973
11. Gyntelberg F, Nielsen PE, Poulsen HL: Skin blood pressure in hypertensive subjects measured by photoelectric technique. *Scand J Clin Lab Invest* **33**:45-51, 1974
12. Chavatzas D, Jamieson C: Measurement of skin blood pressure. *Lancet* **1**:711-712, 1974