

neurogenic hyperventilation." However, in the presence of coexistent hypoxia in varying degree in many of these patients, it is difficult to differentiate "central neurogenic hyperventilation" from reflex hyperpnea.¹⁸

All patients with respiratory pattern abnormalities showed varying degrees of respiratory alkalosis (most severe in patients with tachypnea, less severe in the presence of CSR and least obvious in the presence of CSV). The underlying mechanism for the development of respiratory alkalosis in acute stroke is not clear. However, it is probably related to a combination of both neurogenic factors and hypoxic drive.

Impedance pneumography appears to be a useful technique for detecting respiratory pattern abnormalities which would otherwise often not be detected in the usual clinical setting. The method permits constant monitoring of respiratory patterns but does not provide accurate information on volumetric pulmonary changes. However, in conjunction with intermittent measurements of pulmonary ventilation and arterial gas studies, this technique may prove to be useful in further elucidating complex neurogenic influences on respiration.

This study also suggests that the types of respiratory pattern changes seen in patients with acute brain stem infarction may have a prognostic significance. Quantitation of these abnormal respiratory patterns may thus provide useful

prognostic information in the observation and management of patients with acute brain stem lesions.

References

1. Lee MC, Klassen AL, Resch JA: Respiratory pattern disturbances in ischemic cerebral vascular disease. *Stroke* 5: 612-616, 1974
2. Plum F, Posner JB: The pathological physiology of signs and symptoms of coma. In Plum F, Posner JB (eds): *Diagnosis of Stupor and Coma*. Second edition. Philadelphia, FA Davis Co, chap 1, pp 1-59, 1972
3. Plum F: Neurological integration of behavioral and metabolic control of breathing. In Porter R (ed): *Breathing: Hering-Breuer Centenary Symposium* (Ciba Symposium). London, J and A Churchill, pp 159-181, 1970
4. Plum F, Swanson AG: Central neurogenic hyperventilation in man. *Arch Neurol Psychiat* 81: 535-549, 1959
5. Plum F, Alvord EC: Apneustic breathing in man. *Arch Neurol* 10: 101-112, 1964
6. Brown HW, Plum F: The neurologic basis of Cheyne-Stokes respiration. *Am J Med* 30: 849-860, 1961
7. Rout MW, Lane DJ, Wollner L: Prognosis in acute cerebrovascular accidents in relation to respiratory pattern and blood gas tensions. *Br Med J* 3: 7-9, 1971
8. North JB, Jennett S: Abnormal breathing patterns associated with acute brain damage. *Arch Neurol* 31: 338-344, 1974
9. North JB, Jennett S: Impedance pneumography for the detection of abnormal breathing patterns associated with brain damage. *Lancet* 2: 212-213, 1972
10. Geddes LA, Hoff HE, Hickman DM, et al: The impedance pneumograph. *Aerospace Med* 33: 28-33, 1962
11. Hamilton LH, Beard JD, Kory RC: Impedance measurement of tidal volume and ventilation. *J Appl Physiol* 20: 565-568, 1965
12. Plum F, Brown HW: The effect on respiration of central nervous system disease. *Ann NY Acad Sci* 109: 915-931, 1963
13. Plum F: Hyperpnea, hyperventilation and brain dysfunction. *Ann Intern Med* 76: 328, 1972

Hemodynamic Derangement for the Induction of Cerebrovascular Fat Deposition in Normotensive Rats on a Hypercholesterolemic Diet

YUKIO YAMORI, M.D., PH.D.,* RYOICHI HORIE, M.D.,†
MASAYASU SATO, M.D.,‡ AND MASAICHI FUKASE, M.D., PH.D.§

SUMMARY Cerebrovascular ring-like fat deposition, which was noted only in hypertensive rats but never observed in normotensive rats even after they had been fed a high-fat cholesterol (HFC) diet for a long time, was successfully developed in the posterior communicating or other cerebrobasal arteries in normotensive rats fed an HFC diet for ten weeks after bilateral or unilateral carotid artery

ligation or basilar artery ligation. These posterior communicating arteries with fat deposits were clearly dilated to a significant extent. These findings corroborated the fact that not only high blood pressure but also hemodynamic derangements induced by hypertension or other causes were important factors for the development of fat deposition in cerebral arteries.

Introduction

THE EXTREMELY RAPID development of ring-like arterial fat deposition in spontaneously hypertensive rats (SHR) fed a high-fat cholesterol (HFC) diet for two weeks

was first reported by Yamori¹ and its detailed mechanism was studied in SHR and other experimental hypertensive rats.²⁻⁴ Our previous studies further showed that fat depositions quickly developed even in the circle of Willis, especially in stroke-prone spontaneously hypertensive rats (SHRSP) and other experimental hypertensive rats on an HFC diet.^{5,6} Because normotensive Wistar-Kyoto (WK) rats and antihypertensive agent-treated experimental hypertensive rats on an HFC diet never had cerebrovascular fat deposition, hypertension was confirmed as the decisive factor for cerebrovascular fat deposition. We observed the dis-

From the Departments of *Pathology, †Neurosurgery, and ‡Psychiatry, Faculty of Medicine, Kyoto University, Sakyo-ku, Kyoto, Japan, and the Japan Stroke Prevention Center, Izumo, Japan. §Japan Stroke Prevention Center, Izumo, Japan.

This study was supported by grants from the Japan Ministry of Education, the Science and Technology Agency of the Japanese Government, and NIH (HL 17754).

tribution of cerebrovascular ring-like fat deposition in more than 300 hypertensive rats on an HFC diet. The initial ring-like deposits were located near such branchings as the carotid fork, basilar head and vertebrobasilar junction.⁶ Moreover, ring-like fat deposits in mesenteric arteries developed in relation to segmental increase in vascular permeability caused by vasoconstriction and dilation in hypertensive rats.^{3, 4} These findings suggested that hemodynamic alteration induced by hypertension might be an important local factor for arterial fat deposition. Consequently, we experimentally tried to induce ring-like fat deposition in the cerebral arteries in "normotensive" rats by artificial hemodynamic derangements.

Methods

Twenty-four normotensive WK rats, 60 days old, and five WK rats, 40 days old, were operated on as follows under pentobarbital anesthesia (40 mg per kilogram, i.p.) to induce artificial hemodynamic derangements in the cerebrobasal arteries.

Carotid arteries were bilaterally or unilaterally ligated with great care in order to prevent vagal irritation or injury which might cause cerebral hypoxia due to respiratory dis-

turbances. (All 40-day-old WK rats were used for bilateral carotid artery ligation.)

Basilar arteries were ligated after being exposed with a cervical transclival approach⁷ by a microsurgical technique.

Sham operations were performed as follows: the pontine arteries were exposed through the cervical transclival approach and two pontine arteries were bilaterally electrocoagulated at their origin from the basilar artery.

These operated rats were fed an HFC diet (20% suet, 5% cholesterol and 2% cholic acid) with 1% salt in the drinking water for ten weeks.¹⁻⁶

The serum cholesterol level (Zurkowski's method⁸), tail blood pressure (a pulse-pick up method⁹ without anesthesia), and body weight were measured while these rats were on the HFC diet.

In order to observe the deposition in the cerebrobasal arteries, 75% barium sulfate with 10% gelatin was perfused through an aortic cannula after the preperfusion of 200 ml of heparinized physiological saline (at 38°C), with the pressure equal to the systolic pressure of individual rats (checked before perfusion). The brain was removed after being kept at -20°C in a freezer for one hour, fixed with 10% cold formalin and stained by Sudan III (barium contrasted Sudan staining method [BCSS method]^{6, 9}). Fat deposits were observed not only macroscopically but also by light or electron microscopic techniques after the preparation of ultrathin sections from the specimens refixed in osmium tetroxide and embedded in Epon.

Diameters of the carotid and basilar portions in the posterior communicating arteries were measured with a micrometer by use of a microscope.

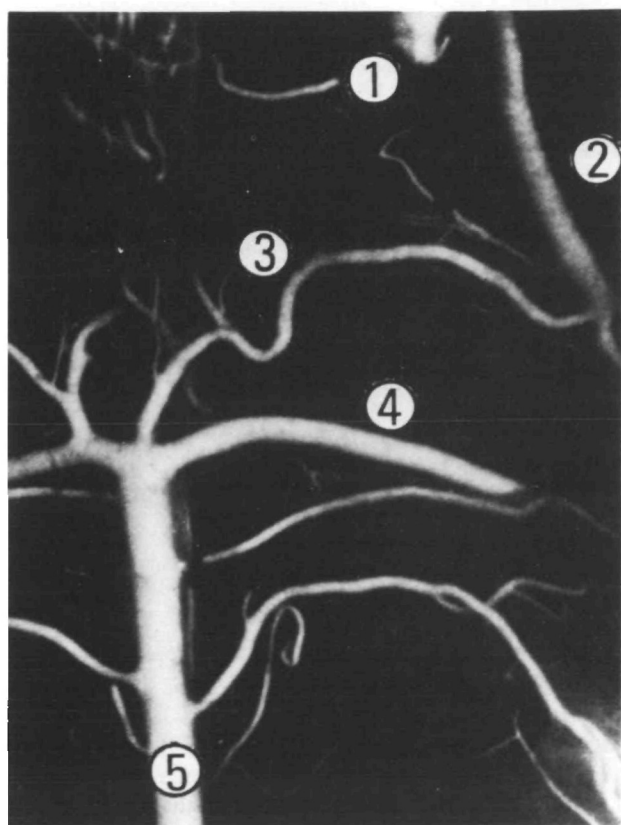


FIGURE 1A. Ring-like fat deposits in the cerebrobasal arteries induced by artificial hemodynamic derangement in normotensive WK rats on an HFC diet for ten weeks from the age of 60 days. Encircled numbers (1 to 5) indicate internal carotid artery, the carotid portion of the posterior communicating artery, the basilar portion of the posterior communicating artery, the superior cerebellar artery and the basilar artery, respectively. Cerebrobasal arteries in non-operated control WK rats; no fat deposits are observed.

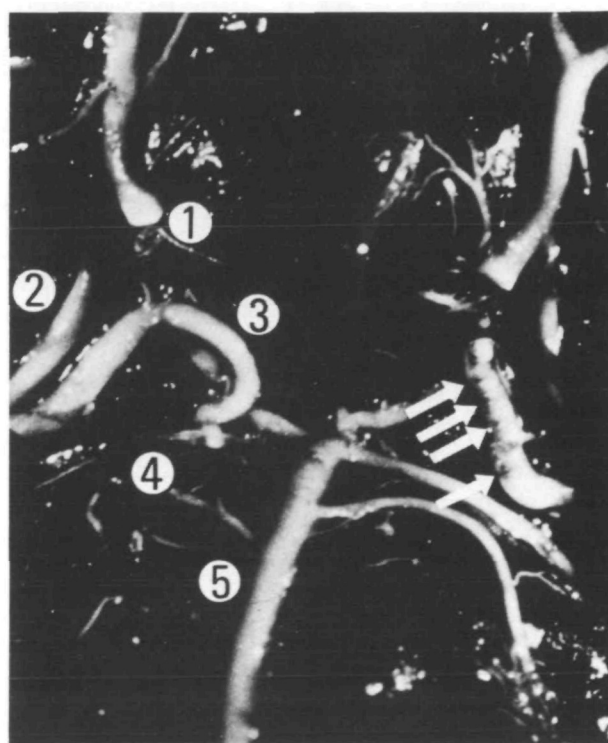


FIGURE 1B. Cerebrobasal arteries in WK rats after bilateral carotid ligation. Multiple ring-like fat deposits are observed at the basilar portion of left posterior communicating artery. See legend of figure 1A for explanation of numbers.

TABLE 1 Acute Fat Deposition in the Circle of Willis Caused by Artificial Hemodynamic Derangements in WK Rats on an HFC Diet for Ten Weeks From the Age of 60 Days

		Carotid artery ligation		Basilar artery ligation	Pontine A. coagulation (sham operation)
		Bilateral	Unilateral		
Fat deposition					
Post. Comm. A.					
	Bilateral	+	4	0	0
	Unilateral		2	3	0
		—	0	3	6
Diameter					
Post. Comm. A.					
	Carotid portion (mm)		4.0 ± 0.1*	2.7 ± 0.1*	1.8 ± 0.2†
	Basilar portion (mm)		3.8 ± 0.1*	2.5 ± 0.1*	2.9 ± 0.1*
Serum cholesterol level (mg/dl)			533 ± 35	549 ± 21	540 ± 25
Blood pressure (mm Hg)			117 ± 6	116 ± 7	110 ± 4
Weight gain (gm)			56.7 ± 7.7	53.3 ± 7.3	53.3 ± 4.0
					47.5 ± 6.3

*Significant differences from the sham-operated group ($P < 0.01$).†Significant differences from the sham-operated group ($P < 0.05$).

Post. Comm. A. = posterior communicating artery.

Results

Figure 1 shows acute fat deposition in the circle of Willis of WK rats on an HFC diet for ten weeks from the age of 60 days after operation. All numerical data are summarized in table 1. All six bilateral ligations, four of six unilateral carotid ligations, and three of six basilar ligations resulted in the development of fat deposition in the posterior communicating artery.

These deposits were noted bilaterally (in four cases) or unilaterally (in two cases) after bilateral carotid ligation, unilaterally on the ligated side after unilateral carotid ligation, and unilaterally on either side after basilar artery ligation. However, electrocoagulation of pontine arteries as a sham operation never resulted in fat deposition.

The group of five young WK rats, in which carotid arteries were bilaterally ligated at the age of 40 days, showed more widespread distribution of fat deposition; three of them had ring-like fat deposits in the posterior cerebral and posterior communicating arteries bilaterally, one of them in the basilar artery, and the other one in the posterior cerebral artery bilaterally.

These fat depositions were ring-like and completely similar to those observed in hypertensive rats on an HFC diet.¹⁻⁶ Histological study also confirmed that these arterial

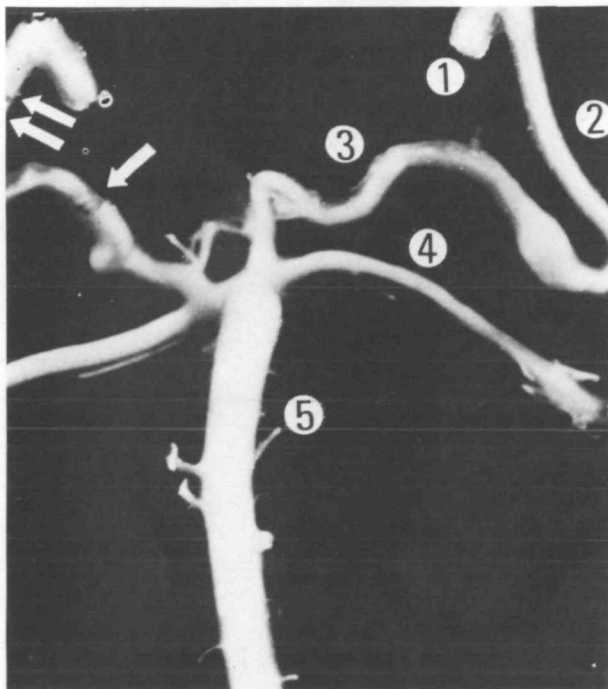


FIGURE 1C. Extirpated cerebrobasal arteries of WK rats after bilateral carotid ligation. Some ring-like fat deposits are noted at the carotid and basilar portions of the right posterior communicating artery. See legend of figure 1A for explanation of numbers.

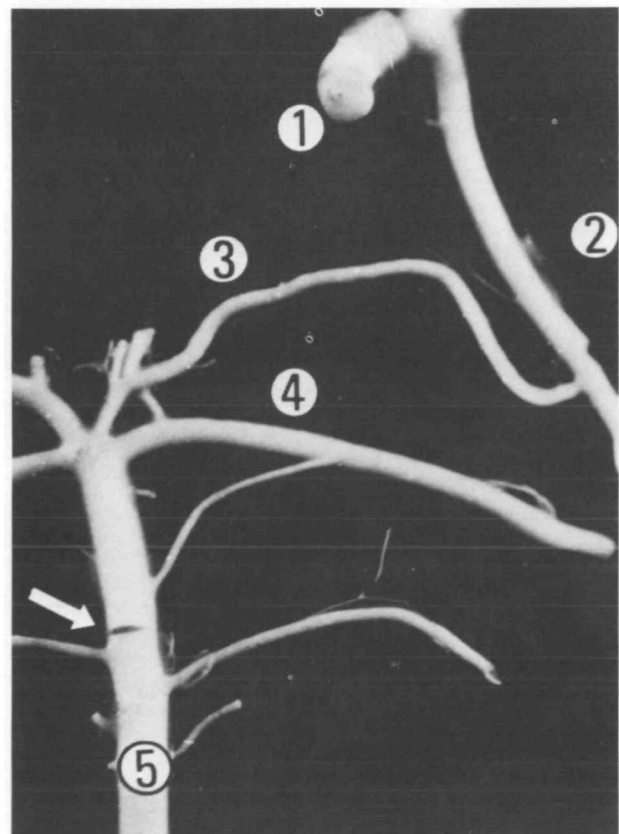


FIGURE 1D. Extirpated cerebrobasal arteries of WK rats after right carotid ligation. A clear ring of fat deposit is noted at the basilar artery. See legend of figure 1A for explanation of numbers.

lesions were similar to those in hypertensive rats^{3, 4}: the intima was thickened and contained foam cells⁵ and the media consisted of markedly vacuolated smooth muscle cells (fig. 2).

It was clearly noted that the regions with ring-like fat deposition were dilated and frequently elongated into an S-shape. The diameters at the carotid and basilar portions of the posterior communicating artery in the groups of bilateral and unilateral carotid and basilar artery ligations were significantly larger than the diameters at the non-dilated communicating artery in the sham-operated group. Such marked dilatations were far beyond the normal variations, although the basilar portions of the posterior communicating arteries were variable in diameter. The fat deposits were located mainly at the extended wall of elongated and dilated arteries. Serum cholesterol level, blood pressure and gain in body weight showed no significant differences among four experimental groups, including the sham-operated group.

Discussion

An extremely rapid development of ring-like fat deposition "in the mesenteric arteries" of SHR on an HFC diet was reported first by Yamori,¹ and subsequently Yamori et al.^{5, 6} confirmed the same ring-like fat deposition "in the circle of Willis" by their new technique used to demonstrate fat deposition in the cerebral arteries as a whole (BCSS method). The significance of acute arterial fat deposition as a model for studies on the initiation mechanism of atherosclerosis or arteriosclerosis was further studied by our previous reports.³⁻⁶ The process of ring-like fat deposition was speculated upon from some experimental findings as follows: Repetition of vasoconstriction and vasodilatation causes a segmental increase in vascular permeability, which is followed by ring-like fat deposition, especially in the media of vasodilated regions. The fat deposition accelerates the degeneration of the media which further dilates the arterial wall and increases the permeability, and results in the rapid development of marked ring-like lesions. Moreover, our previous observations³⁻⁶ confirmed the following two findings concerning the pathogenetic factors for fat deposition in cerebrobasal arteries.

(1) The predilection sites of ring-like fat deposition in the cerebral arteries were arterial bifurcations in the cerebrobasal arteries.^{5, 6} This finding suggested a relationship between hemodynamics of cerebral blood flow and fat deposition in the cerebral arteries.

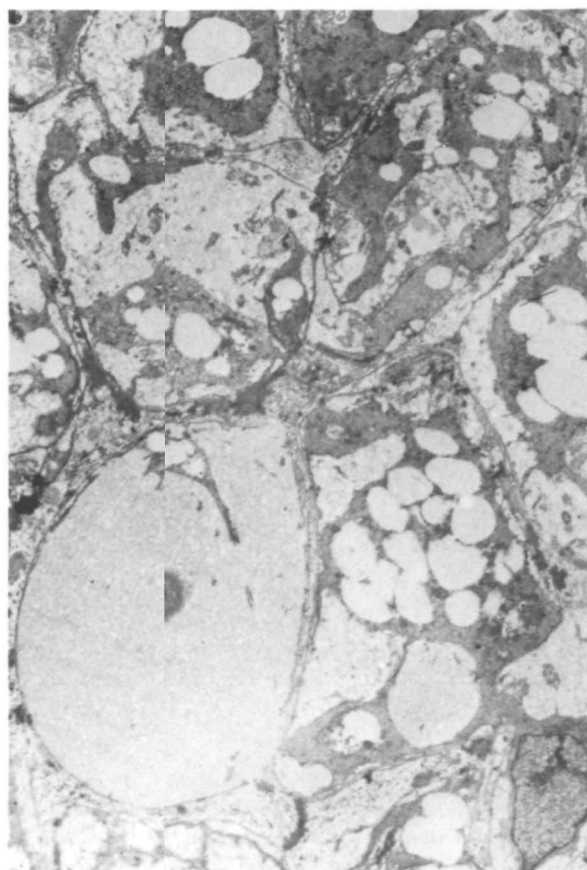
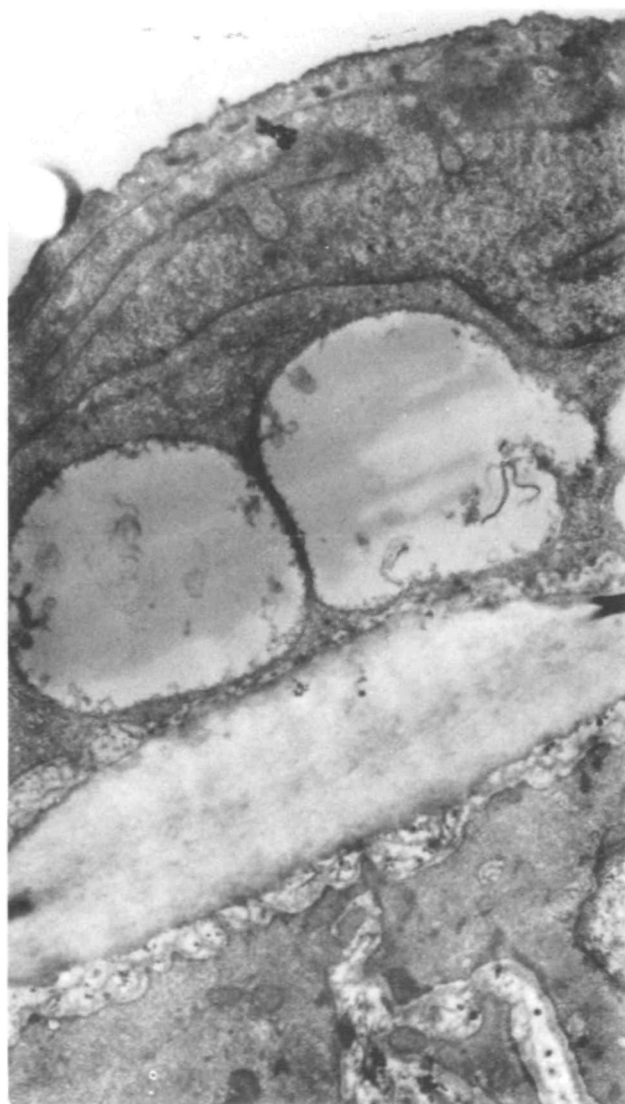


FIGURE 2. Electron microscopic findings on the cerebrobasal artery with fat deposits. Left: Thickening of intima with foam cell formation. Right: Marked vacuolization of smooth muscle cells with fat deposition.

(2) The decisive importance of hypertension in the arterial fat deposition was observed, especially in the cerebral arteries.^{5,6} Namely, it was noted that normotensive WK rats on an HFC diet never had fat deposition and that even SHR rarely had fat deposition in the cerebral artery under normotensive conditions (in the prehypertensive stage or under treatment by antihypertensive agents) in contrast to some grade of fat deposition noted in the mesenteric arteries in these SHR. In fact, many of our experimental cases revealed that blood pressure and the severity of fat deposition in the cerebral arteries showed a positive co-relationship.⁶

Based on these two experimental findings, we speculated about the possibility of inducing fat deposition in the cerebral arteries of "normotensive" rats, and succeeded in making ring-like fat depositions as observed in "hypertensive" rats and in the cerebral arteries of "normotensive" WK rats on an HFC diet after bilateral or unilateral carotid ligation or basilar ligation. The predilection sites of fat deposition in normotensive rats after these operations were the posterior communicating arteries, which frequently showed an elongation and were significantly dilated in the diameter because of the compensatory increase in blood flow. This experimental success clearly indicates the importance of hemodynamic derangement in arterial fat deposition. The hemodynamic concept of atherosclerosis was suggested from experiments by Texon et al.,¹⁰ who observed atherosclerosis of the S-shaped carotid artery autotransplanted into the femoral artery in dogs fed cholesterol plus propylthiouracil. Our findings suggest that hemodynamic derangement induces fat deposition directly through intimal damage to increase permeability or through arterial wall extension which causes permeability increase.

Although our previous works¹⁻⁶ were the first to prove the importance of hypertension in fat deposition of the cerebral arteries in rats, accumulating experimental evidence obtained mainly in dogs and rabbits also has indicated that hypertension is the contributing factor in atherogenesis.¹¹⁻¹⁶ Our present experiments generated the hypothesis that

hemodynamic derangements induced by hypertension altered endothelial permeability which predisposed to lipid deposition and finally resulted in atherogenesis.

References

1. Yamori Y: Metabolic pathology of vasculatures in hypertension and vascular lesions in spontaneously hypertensive rats. *Trans Soc Path Jap* 63: 226-227, 1974
2. Yamori Y, Sato M, Horie R, et al: Experimental studies on atherogenesis. 1. Acute arterial fat deposition in various hypertensive rats. *Jap Heart J* 16: 302-304, 1975
3. Yamori Y, Sato M, Horie R, et al: Experimental studies on atherogenesis. 2. Mechanism of acute arterial fat deposition in hypertensive rats. *Jap Heart J* 16: 305-308, 1975
4. Yamori Y, Hamashima Y, Horie R, et al: Pathology of acute arterial fat deposition in spontaneously hypertensive rats. *Jap Circ J* 39: 593-600, 1975
5. Yamori Y, Horie R, Otsubo K, et al: Studies on stroke in stroke-prone SHR. 2. Cerebrovascular fat deposition and cerebrovascular permeability. *Jap Heart J* 16: 332-335, 1975
6. Yamori Y, Horie R, Sato M, et al: Hypertension as an important factor for cerebrovascular atherogenesis in rats. *Stroke* 7: 120-125, 1976
7. Ohta T, Chokyu M, Nishimura S: Experimental study on cerebral vasospasm: Especially on postspastic biphasic vasodilatation. *Brain and Nerve* 24: 427-435, 1972
8. Zurkowski P: A rapid method for cholesterol determination with a single reagent. *Clin Chem* 10: 451-453, 1964
9. Yamori Y, Tomimoto K, Ooshima A, et al: Developmental course of hypertension in the SHR-substrains susceptible to hypertensive cerebrovascular lesions. *Jap Heart J* 15: 209-210, 1974
10. Texon M, Imparato AM, Lord JW Jr: The hemodynamic concept of atherosclerosis. The experimental production of hemodynamic arterial disease. *Arch Surg* 80: 47-53, 1960
11. Wilens SL: The effect of postural hypertension on the development of atheromatosis in rabbits fed cholesterol. *Am J Path* 19: 293-304, 1943
12. Moss WG, Kiely JP, Neville JB, et al: Effect of experimental renal hypertension on experimental cholesterol atherosclerosis. *Fed Proc* 10: 94, 1951
13. Moses C: Effect of oral inositol phosphatide on development of experimental atherosclerosis. *Geriatrics* 9: 325-326, 1954
14. Heptinstall RH, Barkley H, Porter KA: The relative roles of blood cholesterol level and blood pressure level in the production of experimental aortic atheroma in rabbits. *Angiology* 9: 84-87, 1958
15. Sako Y: The effect of hypertension on experimental atherosclerosis. *Surg Forum* 11: 176-178, 1960
16. Pick R, Johnson PJ, Glick G: Deleterious effects of hypertension on the development of aortic and coronary atherosclerosis in stump-tail macaques (*Macaca speciosa*) on an atherogenic diet. *Circulation Research* 35: 472-482, 1974