

Intracoronary γ -Radiation Therapy After Angioplasty Inhibits Recurrence in Patients With In-Stent Restenosis

Ron Waksman, MD; R. Larry White, MD; Rosanna C. Chan, PhD; Bill G. Bass, PhD;
Lisa Geirlach, RN; Gary S. Mintz, MD; Lowell F. Satler, MD; Roxana Mehran, MD;
Patrick W. Serruys, MD; Alexandra J. Lansky, MD; Peter Fitzgerald, MD; Balram Bhargava, MD;
Kenneth M. Kent, MD; Augusto D. Pichard, MD; Martin B. Leon, MD,
for the Washington Radiation for In-Stent Restenosis Trial (WRIST) Investigators

Background—Treatment of in-stent restenosis presents a critical limitation of intracoronary stent implantation. Ionizing radiation has been shown to decrease neointimal formation within stents in animal models and in initial clinical trials. We studied the effects of intracoronary γ -radiation therapy versus placebo on the clinical and angiographic outcomes of patients with in-stent restenosis.

Methods and Results—One hundred thirty patients with in-stent restenosis underwent successful coronary intervention and were then blindly randomized to receive either intracoronary γ -radiation with ^{192}Ir (15 Gy) or placebo. Four independent core laboratories blinded to the treatment protocol analyzed the angiographic and intravascular ultrasound end points of restenosis. Procedural success and in-hospital and 30-day complications were similar among the groups. At 6 months, patients assigned to radiation therapy required less target lesion revascularization and target vessel revascularization (9 [13.8%] and 17 [26.2%], respectively) compared with patients assigned to placebo (41 [63.1%, $P=0.0001$] and 44 [67.7%, $P=0.0001$], respectively). Binary angiographic restenosis was lower in the irradiated group (19% versus 58% for placebo, $P=0.001$). Freedom from major cardiac events was lower in the radiation group (29.2% versus 67.7% for placebo, $P<0.001$).

Conclusions—Intracoronary γ -radiation used as adjunct therapy for patients with in-stent restenosis significantly reduces both angiographic and clinical restenosis. (*Circulation*. 2000;101:2165-2171.)

Key Words: restenosis ■ angioplasty ■ revascularization ■ radioisotopes

In-stent restenosis after successful intracoronary stent implantation has become a major clinical problem. It occurs in 7% to 37% of patients who undergo stent implantation and is dependent on patient characteristics, lesion morphology, and procedural technique.¹⁻³ Serial intravascular ultrasound studies have demonstrated that in-stent restenosis results primarily from neointimal tissue proliferation distributed either focally or diffusely over the entire length of the stent.^{4,5} The recurrence rate after treatment for in-stent restenosis varies among reported series but remains high (>30%) regardless of treatment modalities, including balloon angioplasty,⁶⁻⁸ rotational atherectomy,⁹ excimer laser ablation,¹⁰ and repeat stenting.^{11,12} The diffuse pattern of in-stent restenosis (>10 mm length) is associated with even higher rates of recurrence and presents a therapeutic challenge.¹¹

See p 2130

Studies with intracoronary ionizing radiation using γ - and β -emitters after intervention delivered by catheter-based systems have demonstrated a reduction in neointimal formation in porcine coronary models.¹³⁻¹⁶ Clinical feasibility studies in patients have suggested reduced postangioplasty restenosis after γ - and β -radiation therapy.^{12,17,18} In the present study, we report the results from a prospective, randomized, double-blind trial examining the effectiveness and safety of intracoronary catheter-based γ -radiation therapy compared with placebo as an alternative for patients requiring treatment for in-stent restenosis.

Methods

This clinical trial was sponsored by an Investigational Device Exemption granted by the Food and Drug Administration to the

Received August 2, 1999; revision received December 6, 1999; accepted December 10, 1999.

From the Cardiology Research Foundation, Division of Cardiology (R.W., G.S.M., R.M., A.J.L., M.B.L., L.F.S., L.G., B.B., K.M.K., A.D.P.), and the Washington Cancer Institute (R.L.W., R.C.C., B.G.B.), Washington Hospital Center, Washington DC; The Interventional Cardiology Department Thoraxcenter (P.W.S.), Erasmus University, Rotterdam, the Netherlands; and the Intravascular Ultrasound Core Laboratories (P.F.), Stanford University, Calif.

The Principal Investigator is consultant to several companies who develop devices for vascular brachytherapy.

Reprint requests to Dr Ron Waksman, Cardiology Research Institute, Department of Medicine, Washington Hospital Center, 110 Irving St NW, Suite 4B-1, Washington, DC 20010.

© 2000 American Heart Association, Inc.

Circulation is available at <http://www.circulationaha.org>

principal investigator (R.W.) and approved by the Institutional Review Board and the Radiation Safety Committee at the Washington Hospital Center. The study was monitored by an external data and safety-monitoring board, which met at 1, 3, 6, and 12 months after the initiation of the study. Informed consent was obtained from all patients before study enrollment.

Selection of Patients

The study population consisted of 130 consecutive patients, 30 to 80 years of age, with previous intracoronary stent implantation in native coronaries ($n=100$) or in aortocoronary venous bypass grafts ($n=30$). Patients presented with symptoms of angina and angiographic evidence of in-stent restenosis. Angiographic entry criteria included diameter stenosis $\geq 50\%$ within the stent treatment site in vessels that were 3.0 to 5.0 mm in diameter and had a lesion length <47 mm in patients who underwent successful ($<30\%$ residual stenosis without complications) angioplasty with the use of (alone or in combination) balloons, ablative devices, or additional stents. Main exclusion criteria were patients with recent (<72 -hour) acute myocardial infarction, ejection fraction $<20\%$, prior irradiation treatment to the chest, evidence of angiographic thrombus, and multiple lesions in the same vessel.

Study Protocol

Before intervention, an angiogram and an intravascular ultrasound study (3.2F catheter with motorized pullback at 0.5 mm/s, Cardiovascular Imaging Systems) were performed to determine lesion length and vessel size. Focal lesions (<10 -mm length) were treated with balloon dilatation, and diffuse lesions (≥ 10 -mm length) underwent initial ablation with use of either an excimer laser or rotational atherectomy, which was then followed by balloon dilatation. Additional stents were used, as required, to optimize final angiographic results or to cover unstented portions of the lesion (including edge dissection). In preparation for radiation treatment, the patient was sedated, and the activated clotting time was maintained at >300 seconds with intravenous heparin. Two leaded shields (2-in thickness) were placed in proximity on either side of the table to minimize radiation exposure in the room. A closed end-lumen 5.0F noncentered catheter (Medtronic Vascular Interventional) was inserted into the vessel and positioned to span the lesion length. The patient was randomly assigned to receive a nylon ribbon (0.0030-in diameter) containing different seed trains of either placebo or ^{192}Ir (Best Medical International). The radiation oncologist hand-loaded the ribbon from a lead container positioned on a cart next to the table into the closed end-lumen catheter. The cardiologist documented by angiography accurate positioning of the source to cover the entire lesion site plus at least a 4-mm overlap of normal segments on each end. All catheterization laboratory personnel left the room during the dwell period for active source radiation or placebo treatment, except for the radiation safety officer, who measured exposure rates at various locations. Patients were carefully monitored from the control room adjacent to the catheterization laboratory. At the end of the treatment, the radiation oncologist entered to the room and retrieved the ribbon into the shielded lead container, and the medical personnel returned once the radiation exposure reached background values. A final angiogram and an intravascular ultrasound study were performed. If significant reduction in luminal dimensions was observed, further balloon dilatation or stent implantation was used to obtain optimal final results. Patients received routine postangioplasty care, including treatment with ticlopidine (250 mg orally, twice daily for 1 month), regardless of whether additional stents were implanted.

Radiation Details and Dosimetry

The prescribed dose was 15 Gy to a distance of 2.0 mm from the surface of the source for vessels between 3.0 and 4.0 mm or 15 Gy to a distance of 2.4 mm for vessels >4.0 mm in diameter. Different trains of seeds were used (5, 9, or 13 to cover total lengths of 19, 36, and 51 mm, respectively). All seeds were equal in length (3 mm separated with a 1-mm space), with a mean specific activity of 25.3 ± 3.5 mCi. Monte Carlo calculations detected maximum dose to

the near wall of ≤ 45 Gy, whereas the minimum dose to the far wall was ≥ 7.3 Gy.

End Points and Follow-Up

The primary clinical end point was the cumulative composite outcome defined as the occurrence of death, myocardial infarction, and repeat TLR at 6 months. Important secondary angiographic end points at 6 months were restenosis (defined as diameter stenosis $\geq 50\%$), the magnitude of late loss, and the late loss index. All patients had clinical follow-up evaluations at 1, 3, 6, and 12 months after the procedure. At 6 months, repeat coronary angiography and intravascular ultrasound studies were performed.

Angiographic Analysis

Quantitative coronary angiographic analysis was performed independently by 2 core angiographic laboratories blinded to the treatment assignment. The Thoraxcenter laboratory used the CASS-II system (Pie Medical), and the Washington Hospital Center laboratory used the CMS-GFT system (Medis). Angiographic binary restenosis at follow-up (angiograms 4 to 8 months after treatment) was defined as $\geq 50\%$ diameter narrowing within the stent and in the segment including the stent plus its edges (within 5 mm). A luminal diameter of 0 mm was imputed in the presence of a total occlusion at baseline or at follow-up. Acute gain (in millimeters) was defined as the change in the stent MLD from baseline to the final procedural angiogram. Late loss (in millimeters) was defined as the change in stent MLD from the final to the follow-up angiogram, and the arithmetic loss index within the stent was defined as the ratio of late loss to acute gain.

Intravascular Ultrasound Analysis

Two independent core laboratories, at Stanford University and at the Washington Hospital Center, blinded to the treatment protocols independently analyzed the procedural and follow-up studies. Both procedural and follow-up studies were analyzed at every 1-mm axial length, including the stented segment and a 5-mm length proximal and distal to the stent edges of the stent. By use of computerized planimetry, the stent and luminal cross-sectional areas of each image slice were traced manually, and the cross-sectional area of intimal hyperplasia (tissue volume) present within the stent on each image slice was calculated. Intimal plaque volumes were calculated by Simpson's rule. The growth of tissue within the stent struts at follow-up was calculated as the intimal area (or volume) at follow-up minus the intimal area (or volume) immediately after the procedure.

Statistical Analysis

The target sample size of 130 patients (with previous stent implantation in 100 native coronaries and 30 saphenous vein grafts with separate randomization) was determined (80% power and 95% confidence) to demonstrate a 50% reduction in the composite clinical end point. Data were recorded prospectively and were forwarded to the data-coordinating center at the Washington Hospital Center. All clinical events were independently adjudicated by an external committee that reviewed source-documented data in a blinded fashion.

Outcomes were analyzed according to the "intention-to-treat" principle. Results are expressed as mean \pm SD. The Student *t* test was used to compare continuous variables; the χ^2 test or Fisher exact test was used to compare categorical values. The TLR, TVR, and the composite clinical end point were analyzed by use of Kaplan-Meier survival curves, with differences between the 2 treatment groups compared by the log-rank test. A value of $P < 0.05$ was considered significant.

Results

Between February 1997 and January 1998, 130 patients with in-stent restenosis were enrolled. Baseline clinical and angiographic characteristics of the treatment groups are shown in Tables 1 and 2, respectively. Overall, 48% had diabetes, 60% had previous treatment of in-stent restenosis, and 75% had a

TABLE 1. Baseline Clinical Characteristics of 130 Patients With In-Stent Restenosis Assigned to Radiation Therapy (^{192}Ir) or Placebo

Characteristic	^{192}Ir Group (n=65)	Placebo Group (n=65)
Age, y	63.2±10.9	62.3±10.2
Male sex, %	66	72
Hyperlipidemia, %	83	89
Hypertension, %	72	68
Diabetes mellitus, %	39	45
Previous myocardial infarction, %	45	45
Unstable angina, %	82	68
Multivessel disease, %	65	56
Previous CABG, %	57	51
Previous PTCA, %	100	100
Previous in-stent restenosis, %	47	39
Ejection fraction	0.47±0.11	0.50±0.11

Values are mean±SD or percentages of patients. Values of *P*, calculated to the differences between placebo and ^{192}Ir , were not significant.

diffuse pattern of in-stent restenosis (lesion length >10 mm) with a mean lesion length of 28.8±12.4 mm.

Procedural Details and Early Outcome

The distribution of devices and number of seeds used are shown in Table 2. Balloon angioplasty alone was used in only 14 (10.7%) lesions. Atheroablative devices were most frequently used: rotational atherectomy in 60% of native coronaries and excimer laser in 90% of vein grafts. Restenting was performed in 46 (35.4%) lesions because of either tissue prolapse (in 26 lesions) or the necessity to cover edge dissections (in the remaining 20 lesions). Most lesions were treated with a 13-seed ribbon with an average of 10.9±2.7 seeds per lesion to cover an average length of 41.31±11.8 mm. The dwell time was 22.0±5.3 minutes to deliver the prescribed dose and was tolerated well by most of the patients. However, 4 patients (2 from each group), including 1 from the placebo group who did not complete the treatment because of persistent ischemia, required dose fractionation. Radiation exposure rates during treatment were as follows: patient's chest, 5.0±0.2 R/h; catheterization table, 650±120 mR/h; 1 m from the table, 107±35 mR/h; behind the lead shield, 53±24 mR/h; and at the control room, 0.23±0.06 mR/h (background levels). All procedures were free of major adverse events, and only 2 patients required vascular access site repair. There were no deaths, subacute closure, or Q-wave myocardial infarctions in hospital or after 30 days. Creatine kinase-MB elevations >3 times baseline were detected in 11% of the irradiated group versus 8% of the placebo group (*P*=NS).

Angiographic Results

Follow-up angiography was performed at a mean of 188±59 days in 59 patients (90.7%) from the irradiated group and at a mean of 151±71 days in 59 patients (90.7%) from the placebo group. The quantitative angiographic results of both core laboratories were similar (Table 3). The cumulative

TABLE 2. Angiographic and Procedural Characteristics According to Study Groups

Variable	^{192}Ir Group (n=65)	Placebo Group (n=65)
Target vessels		
Left main, %	5	3
LAD	28	25
LCx	23	23
RCA	21	26
SVG	23	23
Lesions		
Location		
Ostial, %	23	28
Proximal, %	28	28
Mid, %	38	32
Distal, %	11	12
Mean lesion length, mm	28.8±12.4	26.7±11.3
Lesion length >10 mm, %	73	75
Total occlusion, %	6	8
Bifurcation, %	35	34
Device used, %		
Balloon alone	9	12
Rotational atherectomy	45	48
Laser angioplasty	35	34
Stent alone	11	6
Additional stents	40	31
Seeds		
Length		
5 seeds (19 mm), %	8	14
9 seeds (35 mm), %	35	34
13 seeds (51 mm), %	57	52
Delivery success, %	100	98.5
Dwell time, min	22.6±6.7	21.3±3.4

Values are mean±SD or percentages of patients. LAD indicates left anterior descending coronary artery; LCx, left circumflex coronary artery; RCA, right coronary artery; and SVG, saphenous vein graft.

Values of *P*, calculated to the differences between placebo and ^{192}Ir , were not significant.

distribution curves for minimum luminal diameter (MLD) are shown in Figure 1. Compared with placebo, radiation therapy resulted in a significant reduction in restenosis both within the stent (67% reduction, *P*<0.001) and in the segment including the stent edges (63% reduction, *P*=0.001). The radioactive ribbon/lesion length ratio was 0.92; the placebo ribbon/lesion length ratio was 0.96. In 72% of patients with edge effect, the source length did not cover the entire treated lesion length. The greatest treatment benefit was within the stent; a higher late loss was observed in the segment including the stent edges (0.36±0.74) versus the segment only including the stent (0.22±0.84, *P*=0.04). The predominant angiographic pattern of restenosis in the irradiated group was at the edges, with a mean lesion length of 10±3.1 mm, compared with a diffuse pattern of recurrence in the placebo group, with a mean lesion length of 21±10.2 mm (*P*=0.005).

TABLE 3. Angiographic Results at 6 Months

Variable	WHC Core Lab		Thoraxcenter Core Lab		P
	¹⁹² Ir (n=59)	Placebo (n=59)	¹⁹² Ir (n=59)	Placebo (n=59)	
At baseline					
Reference vessel, mm	2.71±0.53	2.72±0.56	NA	NA	0.9
MLD, mm	0.94±0.42	0.81±0.42	NA	NA	0.07
Degree of stenosis, %	65±14	70±14	NA	NA	0.06
After procedure					
Reference vessel, mm	2.79±0.50	2.85±0.50	2.87±0.52	2.89±0.58	0.54
MLD, mm	2.23±0.52	2.25±0.5	1.94±0.51	1.96±0.50	0.84
Degree of stenosis, %	19±15	20±15	24±9	25±9	0.69
At 6 mo					
Reference vessel, mm	2.90±0.52	2.87±0.58	2.52±0.85	2.32±0.82	0.79
MLD, mm	2.03±0.93	1.24±0.77	1.57±0.73	1.06±0.58	0.0001
Degree of stenosis, %	30±30	57±21	37±22	52±21	0.0001
Changes in MLD					
Immediate luminal gain, mm	1.29±0.53	1.44±0.53	NA	NA	0.12
Late luminal loss, mm	0.22±0.84	1.00±0.69	0.38±0.67	0.89±0.67	<0.0001
Late loss index, mm	0.16±0.73	0.70±0.46	NA	NA	0.0001
Restenosis of stent only, % of patients	19	58	16	48	0.0001
Restenosis of stent and edges, % of patients	22	60	NA	NA	0.0001

Values are mean±SD or percentages of patients. WHC indicates Washington Hospital Center; NA, not applicable. Values of *P* were calculated to the differences between placebo and ¹⁹²Ir for the WHC core lab. There were no statistically significant differences between the laboratories.

There was no evidence of perforation or aneurysm formation in the irradiated group.

Intravascular Ultrasound Results

The intravascular ultrasound results analyzed by 2 independent core laboratories confirmed the angiographic results (Table 4). In 25 (53.2%) of the lesions from the irradiated group, there was an increase in luminal dimensions and a

regression in the neointimal tissue at 6 months. The neointimal tissue volume measured 59.6±40.3 mm³ after radiation and 57.4±36.3 mm³ at follow-up. An example of tissue regression is shown in (Figure 2). None of the patients in the placebo group showed an increase in luminal dimensions or a regression of tissue volume; the posttreatment tissue volume increased from 72.8±72.7 to 132.8±137.4 mm³ at follow-up.

Late Clinical Events

Clinical follow-up at 30 days, 6 months, and 12 months was obtained in all patients. Event-free survival (freedom from death, myocardial infarction, and repeat revascularization) was greater for patients assigned to radiation compared with placebo (Table 5). Late thrombosis was associated with non-Q-wave myocardial infarction in 5 of 6 patients from the irradiated group and in 2 of 2 patients from the control group. At 6 months, freedom from target lesion revascularization (TLR) and target vessel revascularization (TVR) was 86% and 74%, respectively, in the irradiated group versus 37% and 32%, respectively, in the placebo group (*P*=0.001). Between 6 and 12 months, there was an increase of 9.3% in TLR and 7.6% in TVR in the irradiated group only (Table 5, Figure 3).

A multiple logistic regression analysis indicated that radiation therapy was the only predictor of freedom from angiographic or clinical restenosis (*P*=0.0001). Subanalysis of patients with native coronaries showed similarly reduced TVR in the irradiated (16%) versus placebo (66%) patients, with a reduction of major cardiac events (32% versus 72%, both *P*=0.001). In the 30 vein graft patients, there was also a

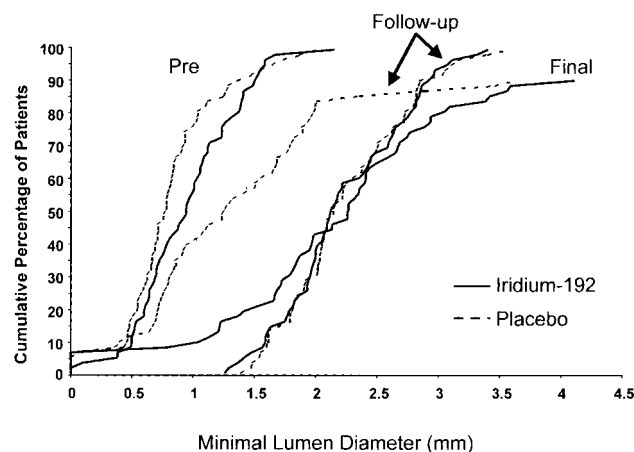


Figure 1. Cumulative distribution curves for MLD before and immediately after intervention and at follow-up in patients with in-stent restenosis assigned either to placebo or γ -radiation with ¹⁹²Ir. Curves are similar before and after procedure for both treatment groups. Curve at follow-up for placebo group is shifted to the left; curve for irradiated group overlaps postprocedure curves.

TABLE 4. Intravascular Ultrasound Results at 6 Months

Variable	WHC Core Lab		Stanford Core Lab		<i>P</i>
	¹⁹² Ir (n=54)	Placebo (n=57)	¹⁹² Ir (n=37)	Placebo (n=38)	
Change in mean stent CSA, mm ²	0.19±0.59	0.07±0.57	NA	NA	0.30
Change in mean luminal area, mm ²	0.61±1.64	1.97±1.58	0.18±0.91	1.87±1.75	0.0004
Change in mean minimal luminal CSA, mm ²	0.38±1.94	1.91±1.58	0.13±0.75	2.31±1.54	<0.0001
Change in volume of tissue growth, mm ³	3.13±38.43	54.98±60.13	2.16±19.17	50.0±69.3	<0.0001
Decrease in mean luminal volume, mm ³	7.87±42.08	56.37±65.19	NA	NA	<0.0001

Values are mean±SD. Values of *P* were calculated to the differences between placebo and ¹⁹²Ir for the WHC core lab. CSA indicates cross-sectional area. There were no statistically significant differences between the laboratories.

lower incidence of TVR in the irradiated group (6.7%) versus the placebo group (53.3%, *P*=0.014) and fewer overall major cardiac events in the irradiated group (20%) versus the placebo group (53.3%, *P*=0.058).

Discussion

Intracoronary stenting involves >60% of all coronary interventions performed today. As a result, in-stent restenosis, especially in its diffuse pattern, remains a serious medical problem. The present study demonstrates that intracoronary γ -radiation, as adjunct therapy to intervention for the treatment of in-stent restenosis, is feasible, effective, and safe without periprocedural adverse events compared with placebo. The patients in the present study represent the “real world” of severe in-stent restenosis, the “frequent fliers” of coronary intervention. The high-risk patient profiles and the nature of the disease may explain the high event rates for the overall cohort, with a mortality of 5.2% at 6 months. Nevertheless, radiation therapy showed a dramatic reduction (>60%) in clinical restenosis, which was supported by angiographic and intravascular ultrasound indices. Several feasibility studies using intracoronary ionizing radiation after angioplasty or stenting have been reported. Among these, 2 studies used γ -radiation: a registry for de novo lesions¹⁷ and a small randomized study for patients with restenosis who were treated with stenting.¹² Both studies reported a reduction

in the angiographic late loss and restenosis frequency associated with the use of ¹⁹²Ir. Lower angiographic indices of restenosis were also reported with β -emitters, such as strontium Sr 90/yttrium Y 90¹⁸ and phosphorus P 32. However, none of these studies specifically targeted a patient population of in-stent restenosis. The present study demonstrates an important therapeutic application for intracoronary γ -radiation, which specifically addresses a disease state (diffuse in-stent restenosis) that currently lacks acceptable alternative treatments. The angiographic analysis demonstrated a striking reduction in late loss for the irradiated group compared with placebo group, and in >50% of irradiated patients, the MLD at follow-up was unchanged. These findings were corroborated by the ultrasound analysis, which showed convincing evidence of intimal hyperplasia regression after radiation. Interestingly, the late loss was found to be less at the center of the lesion compared with the edges, where catheter placement was less precise, and there was a dose drop-off by as much as 30%. These findings support the importance of accurate dosimetry and suggest that better coverage of the lesion by treating longer margins may further reduce the restenosis rate at the edges. Overall, the dosimetry strategy for the present study was effective despite the lack of centering of the radiation catheter and without the use of intravascular ultrasound imaging to determine minimum and maximum doses to the tunica media as previously proposed

TABLE 5. Major Cardiac Events at 6 and 12 Months After Procedure

Event	¹⁹² Ir (n=65)		Placebo (n=65)		<i>P</i>
	6 mo	12 mo	6 mo	12 mo	
Death	3 (4.6)	4 (6.2)	4 (6.2)	4 (6.2)	NS
Q-wave MI	0	0	0	0	...
Non-Q-wave MI	6 (9.2)	6 (9.2)	5 (7.7)	6 (9.2)	NS
Late thrombosis	5 (7.6)	6 (9.2)	2 (3.5)	2 (3.5)	NS
TLR	9 (13.8)	15 (23.0)	41 (63.1)	41 (63.1)	<0.001
TVR	17 (26.1)	22 (33.8)	44 (67.6)	44 (67.6)	<0.001
Death, Q-wave MI, and TVR	19 (29.2)	23 (35.3)	44 (67.6)	44 (67.6)	<0.001

Values are number of patients, with percentages for that group in parentheses. NS indicates not significant.

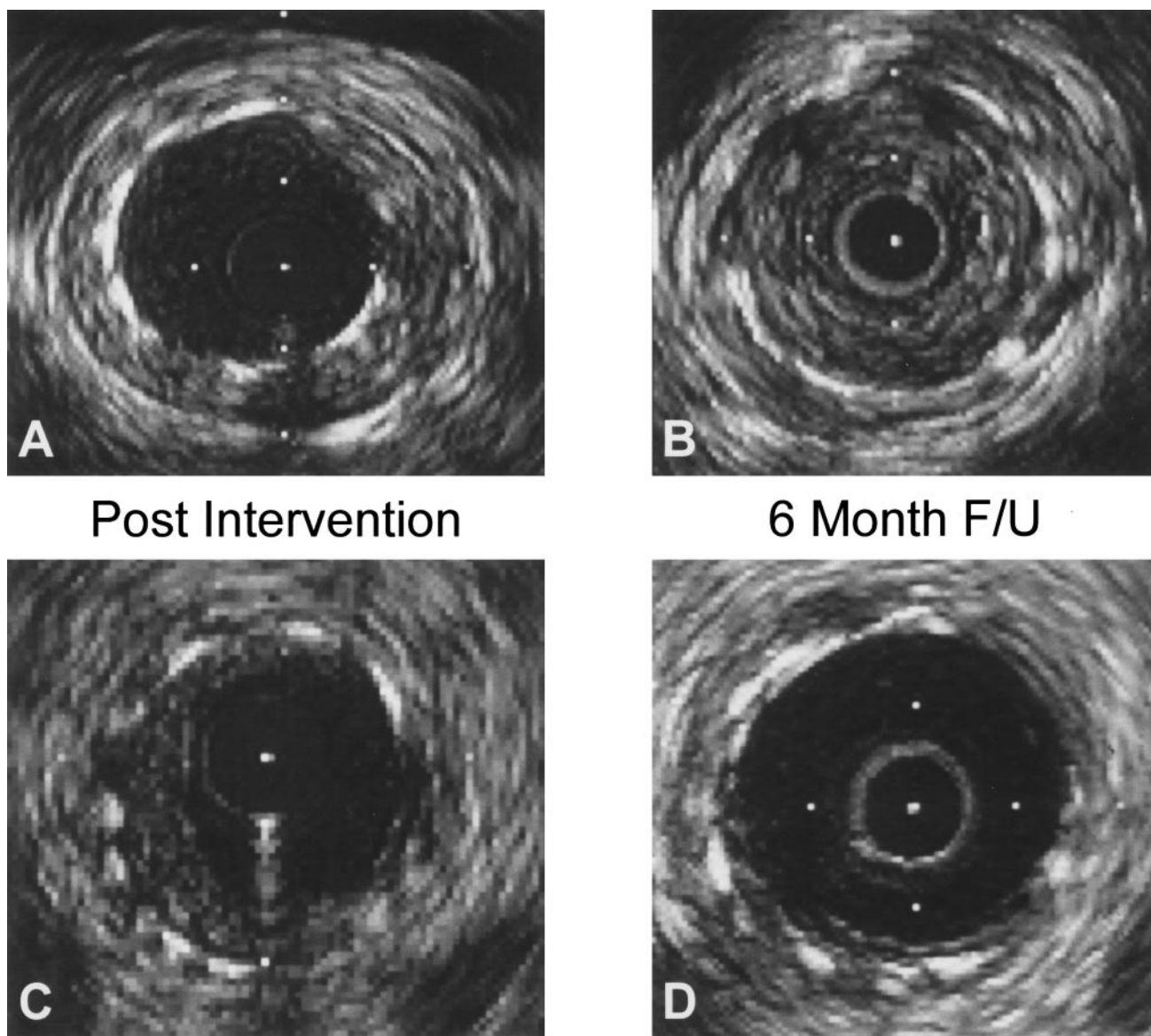


Figure 2. Intravascular study of patient with in-stent restenosis who was treated with rotational atherectomy and assigned to placebo. Immediate postprocedural result (A) is contrasted to 6-month follow-up, showing late neointimal tissue growth (B). The same patient was treated again with rotational atherectomy but was also given radiation therapy; the immediate result, with minimal residual tissue (C), was improved at 6-month study (D), suggesting neointimal regression.

in the Scripps Coronary Radiation to Inhibit Intimal Proliferation Post Stenting (SCRIPPS) study.¹² The lack of early and late adverse events supports the notion that the therapeutic and toxic windows for ¹⁹²Ir are sufficiently broad to accommodate a simple fixed dosimetry scheme. The late thrombosis seen more in the irradiated group was reported in other radiation trials using β -emitters^{19,20} and seems to be a complication of the radiation therapy that will require further investigation and treatment strategy, such as prolonged antiplatelet therapy.²⁰

An important observation is the increase in the revascularization rate between 6 and 12 months in the irradiated group only. Although these changes do not affect the clinical benefit observed in the treated versus placebo groups, they do suggest that radiation may delay in part the biological processes and that a late “catch-up” phenomena or late

thrombosis will ultimately minimize the long-term benefit of radiation. In addition, caution should be observed concerning the potential risk of late effects of radiation, which may occur 10 years after treatment, as previously reported with the use of external radiation.²¹

All clinical interventional practitioners agree that in-stent restenosis is a compelling dilemma that mandates an immediate solution. On the basis of the encouraging and convincing results of the present study, we submit that intracoronary γ -radiation using ¹⁹²Ir is an important and viable therapeutic option for patients who suffer from recurrence of in-stent restenosis.

Acknowledgments

This study was supported in part by a nondirected grant from the Pergament Center for Cardiovascular Research. We wish to ac-

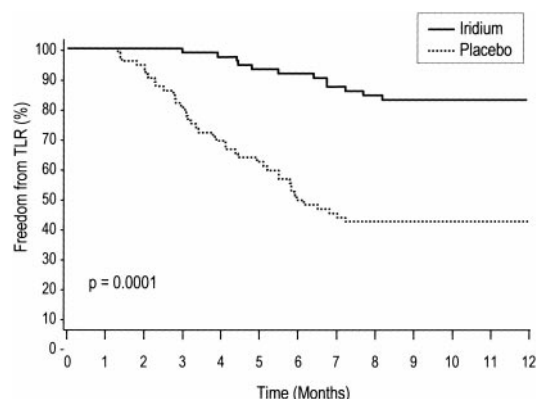


Figure 3. Kaplan-Meier Curves for TLR in irradiated (iridium) group vs placebo group.

knowledge the invaluable assistance of the following individuals during the execution of the clinical trial: Michael Porrazzo, MD, Juliana Simmons, MD, and Pamela Bailey Randolph, MD (Washington Cancer Institute Washington Hospital Center, Washington DC); Manel Sabate, MD (Thoraxcenter, Erasmus University, Rotterdam, the Netherlands); Thosaphol Limpijankit, MD (Stanford University California); and Ann Greenberg (Cardiology Research Foundation, Washington Hospital Center, Washington, DC).

References

- Bauters C, Hubert E, Prat A, Bougrimi K, Van Belle E, McFadden EP, Amouyel P, Lablanche JM, Bertrand M. Predictors of restenosis after coronary stent implantation. *J Am Coll Cardiol.* 1998;31:1291–1298.
- Morice MC, Aubry P, Benveniste E, Bourdennec C, Commeau, and the MUST Investigators. The MUST trial: acute results and six-month clinical follow-up. *J Invasive Cardiol.* 1998;10:257–263.
- Dussailant GR, Mintz GS, Pichard AD, Kent KM, Satler LF, Popma JJ, Wong SC, Leon MB. Small stent size and intimal hyperplasia contribute to restenosis: a volumetric intravascular ultrasound analysis. *J Am Coll Cardiol.* 1995;26:720–724.
- Hoffmann R, Mintz GS, Dussailant GR, Popma JJ, Pichard AD, Satler LF, Kent KM, Griffin J, Leon MB. Patterns and mechanisms of in-stent restenosis: a serial intravascular ultrasound study. *Circulation.* 1996;94:1247–1254.
- Hoffmann R, Mintz GS, Mehran R, Pichard AD, Kent KM, Satler LF, Popma JJ, Wu H, Leon MB. Intravascular ultrasound predictors of angiographic restenosis in lesions treated with Palmaz-Schatz stents. *J Am Coll Cardiol.* 1997;31:43–49.
- Baim DS, Levine MJ, Leon MB, Levine S, Ellis SG, Schatz RA. Management of restenosis within the Palmaz-Schatz coronary stent (the U. S. multicenter experience). *Am J Cardiol.* 1993;71:364–366.
- Gordon PC, Gibson CM, Cohen DJ, Carrozza JP, Kuntz RE, Baim DS. Mechanisms of restenosis and redilatation within coronary stents: quantitative angiographic assessment. *J Am Coll Cardiol.* 1993;21:1166–1174.
- Mehran R, Mintz GS, Popma JJ, Pichard AD, Satler LF, Kent KM, Griffin J, Leon MB. Mechanisms and results of balloon angioplasty for the treatment of in-stent restenosis. *Am J Cardiol.* 1996;78:618–622.
- Sharma SK, Duvvuri S, Dangas G, Kini A, Vidhun R, Venu K, Ambrose JA, Marmur JD. Rotational atherectomy for in-stent restenosis: acute and long-term results of the first 100 cases. *J Am Coll Cardiol.* 1998;32:1358–1365.
- Mehran R, Mintz GS, Satler LF, Pichard AD, Kent KM, Bucher TA, Popma JJ, Leon MB. Treatment of in-stent restenosis with excimer laser coronary angioplasty: mechanisms and results compared to PTCA alone. *Circulation.* 1997;96:2183–2189.
- Mintz GS, Mehran R, Waksman R, Pichard AD, Kent KM, Satler LF, Leon MB. Treatment of in-stent restenosis. *Semin Interv Cardiol.* 1998;3:117–121.
- Teirstein PS, Massullo V, Jani S, Popma JJ, Mintz GS, Russo RJ, Schatz RA, Guarneri EM, Steuterman S, Morris NB, Leon MB, Tripuraneni P. A double-blinded randomized trial of catheter-based radiotherapy to inhibit restenosis following coronary stenting. *N Engl J Med.* 1997;336:1697–1703.
- Wiedermann JG, Marboe C, Amols H, Schwartz A, Weinberger J. Intracoronary irradiation markedly reduces restenosis after balloon angioplasty in a porcine model. *J Am Coll Cardiol.* 1994;23:1491–1498.
- Waksman R, Robinson KA, Crocker IR, Gravanis MB, Cipolla GD, King SB III. Endovascular low-dose irradiation inhibits neointima formation after coronary artery balloon injury in swine: a possible role for radiation therapy in restenosis prevention. *Circulation.* 1995;91:1533–1539.
- Waksman R, Robinson KA, Crocker IR, Gravanis MB, Palmer SJ, Wang C, Cipolla GD, King SB III. Intracoronary radiation before stent implantation inhibits neointima formation in stented porcine coronary arteries. *Circulation.* 1995;92:1383–1386.
- Waksman R, Robinson KA, Crocker IR, Wang C, Gravanis MB, Cipolla GD, Hillstead RA, King SB III. Intracoronary low dose β -irradiation inhibits neointima formation after coronary artery balloon injury in the swine restenosis model. *Circulation.* 1995;92:3025–3031.
- Condado JA, Waksman R, Gurdil O, Espinosa R, Gonzalez J, Burger B, Villoria G, Acquatella H, Crocker IR, Seung KB, Liprie SF. Long-term angiographic and clinical outcome after percutaneous transluminal coronary angioplasty and intracoronary radiation therapy in humans. *Circulation.* 1997;96:727–732.
- King SB, Williams DO, Chougule P, Klein JL, Waksman R, Hilstead R, MacDonald J, Andergerg K, Crocker IR. Endovascular β -radiation to reduce restenosis after coronary balloon angioplasty results of the Beta Energy Restenosis Trial (BERT). *Circulation.* 1998;97:2025–2030.
- Costa MA, Sabaté M, van der Giessen WJ, Kay IK, Cervinka P, Ligthart JMR, Serrano P, Coen VLMA, Levendag PC, Serruys PW. Late coronary occlusion after intracoronary brachytherapy. *Circulation.* 1999;100:789–792.
- Waksman R. Late thrombosis after radiation: sitting on a time bomb. *Circulation.* 1999;100:780–782.
- Corn BW, Trock BJ, Goodman RL. Irradiation related ischemic heart disease. *J Clin Oncol.* 1990;8:41–50.