

Silent Mitral Insufficiency in Acute Myocardial Infarction

By JAMES S. FORRESTER, M.D., GEORGE DIAMOND, M.D.,
SHELDON FREEDMAN, M.D., HOWARD N. ALLEN, M.D.,
WILLIAM W. PARMLEY, M.D., JACK MATLOFF, M.D.,
AND H. J. C. SWAN, M.B., PH.D., F.R.C.P.

SUMMARY

Severe mitral insufficiency in the absence of an audible murmur was diagnosed by left ventricular angiography in three patients with power failure secondary to acute myocardial infarction during evaluation for mechanical circulatory assist and surgery. Mitral valve prolapse was present in two patients. Postmortem examination did not reveal an anatomic basis for the mitral insufficiency: the valve, papillary muscles, and supporting structures were all grossly normal. A single papillary muscle removed at surgery revealed a marked decrease in force development (0.22 g/mm^2 vs $0.62 \pm 0.22 \text{ g/mm}^2$ in eight normal papillary muscles from patients with rheumatic heart disease). During isoproterenol stimulation, force development in this muscle decreased 20%, whereas in the normal muscles force development increased $73 \pm 31\%$. Microscopically, all papillary muscles revealed evidence of extensive necrosis. Silent mitral insufficiency in acute myocardial infarction, therefore, was probably related to diminished flow velocity across the mitral valve secondary to diminished myocardial contractility. Failure to recognize and treat this entity may contribute significantly to the genesis of power failure and ultimate mortality.

Additional Indexing Words:

Papillary muscle dysfunction
Surgery in acute myocardial infarction

Cardiogenic shock
V wave

Heart failure

THE COMPLICATION of variable degrees of acute mitral insufficiency accompanying acute myocardial infarction is recognized with considerable frequency, depending to a great extent upon the care and

persistence of the examiner. Thus, Heikkila reported the remarkable incidence of 55% in 195 consecutive subjects with myocardial infarction, studied prospectively.¹ The basis for such diagnosis is the recognition of a systolic murmur on physical examination, and only scattered case reports have documented the presence of mitral insufficiency by angiographic techniques.^{2,3} In the absence of a ruptured papillary muscle, however, the magnitude of mitral insufficiency is usually thought to be of little clinical significance.⁴ This point of view may be questioned in myocardial infarction, where in the presence of low and fixed stroke volume even small-volume mitral insufficiency is probably of hemodynamic significance.

From the Departments of Cardiology and Pathology, Cedars-Sinai Medical Center, and the Department of Medicine, University of California at Los Angeles, Los Angeles, California.

Supported in part by National Institutes of Health contract PH-43-68-1333 (Myocardial Infarction Research Unit) and U. S. Public Health Service grant 5-SO1-RR-05468.

Address for reprints: James S. Forrester, M.D., Department of Cardiology, Cedars of Lebanon Hospital, 4833 Fountain Avenue, Los Angeles, California 90029.

Received June 7, 1971; revision accepted for publication July 28, 1971.

Table 1

Clinical Data

Patient	Age (years)	Sex	Previous MI	HR after MI	Previous hypertension	Cardiac drugs*
H.S.	45	M	—	30	+	Morphine
L.R.	60	M	+	120	—	Lidocaine
G.K.	66	M	+	6	—	Quinidine Morphine Atropine

*At time of catheterization.

Abbreviations: MI = myocardial infarction; HR = heart rate.

With the advent of more aggressive management of power failure in acute myocardial infarction, coronary angiography and left ventricular angiography are being employed prior to circulatory assist or surgical intervention. This report documents severe, silent mitral insufficiency complicating acute myocardial infarction in three patients, which was discovered as part of the intensive evaluation that must precede such therapy, and was unsuspected on clinical grounds. The failure to recognize this complication in the case of power failure may at least in part account for the failure of therapy in some patients.

Clinical and Hemodynamic Characterization

Three patients with acute myocardial infarction, persistent pulmonary edema, and severe power failure were studied prior to consideration for surgery or mechanical circulatory assistance. Although no murmurs were noted on careful, repeated physical examination, a third heart sound was present in all patients (table 1).

Right- and left-heart catheterizations were performed using standard techniques. Cardiac outputs were determined by injection of indocyanine green into the pulmonary artery with sampling from the left femoral artery. Thermodilution coronary sinus flow was determined in one patient by the method of Ganz et al.⁵ Left ventricular end-diastolic volume (EDV) and end-systolic volume (ESV) were determined by single-plane ventriculography according to the method of Greene et al.⁶ Left ventricular ejection fraction was calculated as the ratio $(EDV - ESV)/EDV$. The mitral regurgitant fraction was determined as 1.00 minus the ratio of forward stroke volume (calculated by dye dilution) divided by the angiographic stroke volume $(EDV - ESV)$. Coronary arteriography was performed by the Judkins technique.

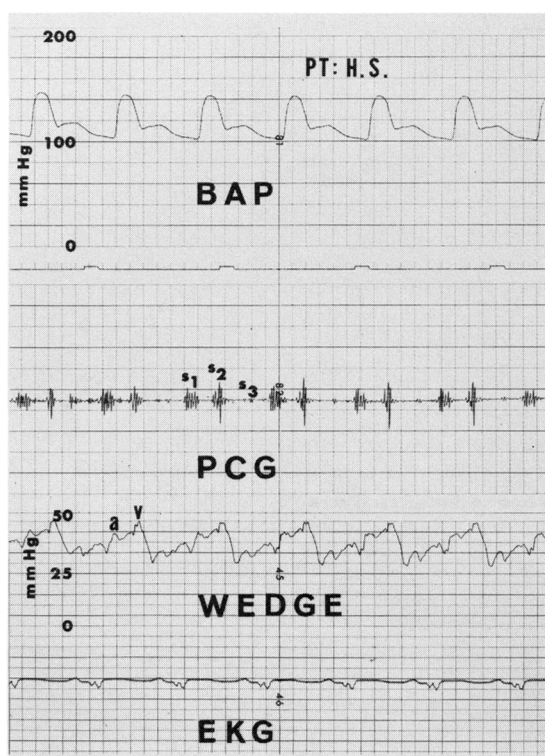


Figure 1

Simultaneous brachial arterial pressure (BAP), phonocardiogram (PCG), wedge pressure, and electrocardiogram (EKG) in a patient (H. S.) with silent mitral regurgitation. Auscultation revealed a prominent third heart sound (S_3) but no systolic murmur. A V wave of 48 mm Hg was seen in the wedge pressure tracing. S_1 = first heart sound; S_2 = second heart sound; a = "a" wave.

Hemodynamic findings are summarized in table 2, and angiographic results are shown in table 3. A simultaneous phonocardiogram and intracardiac pressure tracing recorded just following angiography are shown in figure 1.

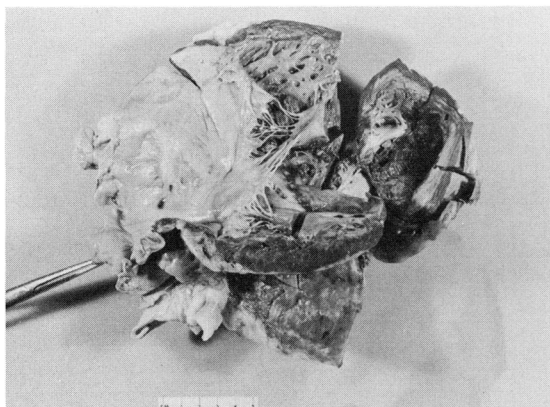


Figure 2

Minimally dilated mitral valve with normal chordae and leaflets in patient L. R. There is extensive myocardial infarction and mural thrombus involving the left ventricle.

Anatomic Findings

Two of the three patients (H. S. and G. K.) underwent emergency surgery on the basis of their clinical and hemodynamic evaluations. In each case the procedure included left ventricular aneurysmectomy and left anterior-descending-aortico-coronary artery bypass.

The first patient died at operation and the second died 8 days postoperatively, possibly from intercurrent infection. The third patient died 6 hours after cardiac catheterization during medical therapy for cardiogenic shock. Surgical and postmortem findings are tabulated in table 4.

Pathologic examination of the hearts of these three patients revealed the mitral valve structure to be normal in all cases. There was minimal gross derangement in papillary muscle structure, and no frank necrosis was visible (fig. 2). On microscopic examination of the papillary muscles, extensive necrosis was present in five of the six papillary muscles (fig. 3). The posterior papillary muscle of patient H. S., which was utilized in isolated papillary muscle studies, was not examined microscopically.

Special Studies

The left ventricular papillary muscle from patient H. S. was studied in a myograph in vitro. The results were compared with eight human papillary muscles removed from patients with rheumatic heart disease at the time

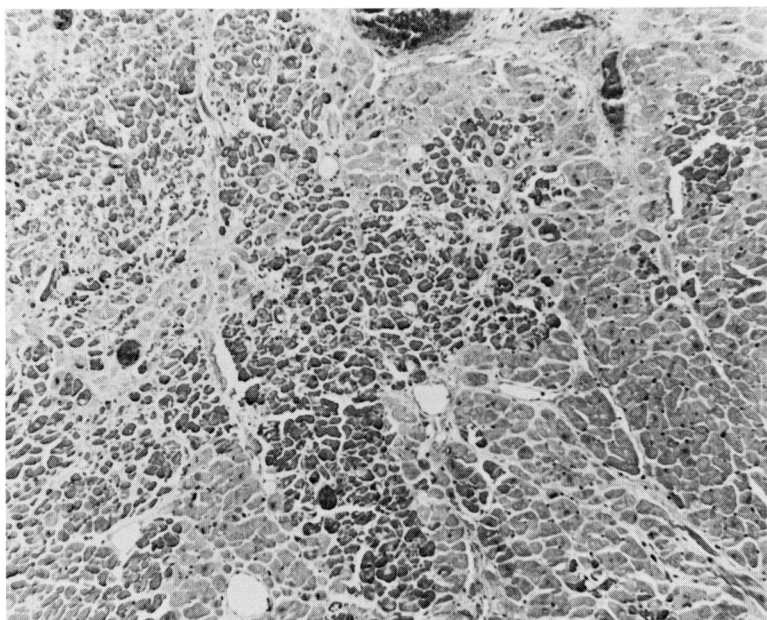


Figure 3

Acute infarction of papillary muscle in patient H. S. showing irregular eosinophilic acellular muscle fibers. (Hematoxylin and eosin, $\times 50$.)

Table 2

Hemodynamics

Pt	CI (liters/min/m ²)	HR (beats/min)	SI (cc/min/m ²)	PCW (mm Hg)	V wave (mm Hg)	BP (mm Hg)	PA (mm Hg)	LV dp/dt (mm Hg/sec)	RA (mm Hg)	A-V diff. (vol %)
H.S.	2.07	150	14	40	49	95/70	65/30	790	15	8.5
L.R.	0.55	108	5	38	45	124/90	58/32	980	8	7.0
G.K.	1.80	100	18	30	36	120/96	62/30	436	12	10.4

Abbreviations: CI = cardiac index; HR = heart rate; SI = stroke index; PCW = pulmonary capillary wedge pressure; V wave = amplitude of V wave from wedge; BP = systemic arterial pressure; PA = pulmonary arterial pressure; LV dp/dt = peak rate of rise of left ventricular pressure; RA = right atrial pressure; A-V diff. = systemic arteriovenous oxygen difference; LVET = left ventricular ejection time; MSER = mean systolic ejection rate; SWI = left ventricular stroke work index; SVR = systemic vascular resistance; PVR = pulmonary vascular resistance; CSF = coronary sinus flow; MVO₂ = myocardial oxygen consumption; LE = transmyocardial lactate extraction; LVEDP = left ventricular end-diastolic pressure; EF = LV ejection fraction; RF = LV mitral regurgitant fraction.

of mitral valve replacement. Each muscle was bathed with Krebs-bicarbonate solution at 34°C, aerated with 95% O₂ and 5% CO₂, and stimulated 12 times/minute with mass platinum electrodes at a voltage 10% above threshold. Isometric force development at the top of the length-tension curve was recorded on a Hewlett Packard 7848A recorder.

The single papillary muscle from the infarction patient revealed striking abnormalities in function. The force development of this muscle, normalized for cross-sectional area, was 0.22 g/mm², which was substantially below the force developed by the other eight muscles, which was 0.62 ± 0.22 g/mm² (mean \pm SD). Following the addition of 10⁻⁵ M isoproterenol to the bath in vitro, the force developed by the muscle from H. S. fell 20%, while force in the other muscles increased $73 \pm 31\%$.

Discussion

Although mitral insufficiency of significant magnitude may be tolerated by an otherwise normal heart for many years, its development in an acutely infarcted heart is probably of far greater hemodynamic significance. Unpublished data from this laboratory have revealed that angiographic grade II mitral insufficiency is often associated with a regurgitant volume equal to forward stroke volume, and that in angiographic grade IV mitral insufficiency regurgitant volume is several times that of forward stroke volume. In the three patients reported, regurgitant volume averaged four

times stroke volume, although this estimate may be falsely high due to the inherent errors in measurement of ejection fraction by angiography and forward stroke volume by indicator dilution in this low range. Since stroke volume in many patients with acute myocardial infarction is fixed⁸ in the low normal range, however, even a small degree of regurgitation may result in significant reduction in forward cardiac output, and larger degrees of insufficiency may result in hemodynamic alterations incompatible with survival. In this context it is of interest that the three patients reported all had severe derangement of hemodynamic status to a strikingly similar degree.

Three lines of evidence support the hypothesis that the major mechanism which induces insufficiency of the mitral valve in this patient group is apparently papillary muscle necrosis without rupture. Both the anterior and posterior papillary muscles showed evidence of extensive damage microscopically. These anatomic data provide a structural basis for the severe functional derangement of the single papillary muscle studied in vitro, and might be expected to result in valvular dysfunction. Thus, mitral valve prolapse was present in two of the three patients studied by left ventricular angiography. The contribution of annular dilatation to the magnitude of mitral insufficiency seems to be minimal. In two patients the annular circumference was within the upper range of normal, and in the

LVET (sec)	MSER (cc/sec/m ²)	SWI (g-m/beat/ m ²)	SVR (dyne-sec- cm ⁻⁵)	PVR (dyne-sec- cm ⁻⁵)	CSF (cc/min)	MVO ₂ (cc/O ₂ /min)	LE (%)	LVEDP (mm Hg)	EF	RF
0.20	69	8.9	1,490	226				36	0.42	0.83
0.20	25	5.0	8,190	706				30	0.33	0.91
0.28	64	19.1	2,300	235	111	14.8	-14	32	0.31	0.75

third patient only moderate dilatation of the ring was observed.

Recently, Cheng⁹ has emphasized that the degree of angiographic mitral regurgitation correlated poorly with the intensity of systolic murmurs in patients with ventricular aneurysms. Since the diagnosis of mitral insufficiency in acute myocardial infarction until now has rested upon physical examination, the incidence of silent mitral insufficiency is unknown, and definitive angiographic data in less critically ill patients with acute myocardial infarction are not likely to be generated. The diagnosis of mitral insufficiency, however, may be established with reasonable certainty

at the bedside by use of the recently described pulmonary artery balloon catheter.¹⁰ Figure 4 illustrates this hemodynamic manifestation using the criteria of giant V waves in the pulmonary capillary wedge pressure tracing in a patient with supportive physical findings. Three additional individuals in a group of 40 consecutive patients with acute myocardial infarction have thus been identified as having silent mitral insufficiency. All three patients had moderately severe congestive heart failure, but survived with medical therapy.

The mechanism by which significant degrees of mitral insufficiency may exist in the absence of an audible murmur was not established. The marked reduction in cardiac output and myocardial contractility in this patient group would suggest that significant decreases in flow velocity across the valve is a major factor. Silent mitral insufficiency of significant magnitude has been observed, however, in patients with rheumatic heart disease studied by left ventricular angiography¹¹ in whom cardiac output was not depressed to shock levels.

The clinical significance and appropriate therapy of this syndrome remain to be established. In terms of medical therapy of shock patients, the presence of mitral regurgitation under the conditions described might favor a pharmacologic agent that would increase papillary muscle contractility and decrease peripheral vascular resistance. Isoproterenol would be an agent of choice. The single papillary muscle study, however, suggests that this agent might result in further deterioration of ventricular function. If silent mitral insufficiency does occur in a population of nonshock patients, it is likely that a surgically correctable lesion may be present in

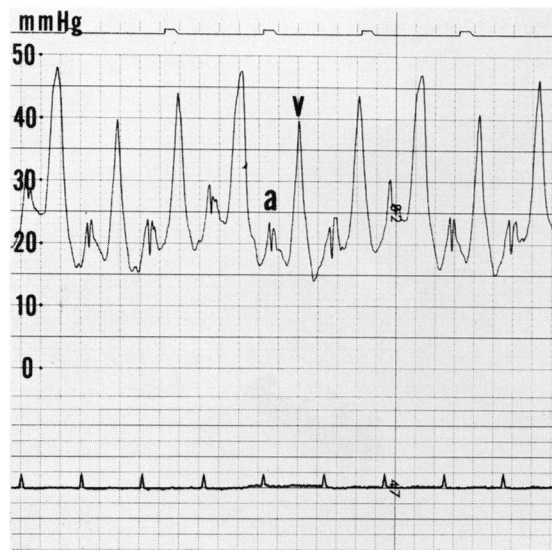


Figure 4

Diagnosis of mitral insufficiency in a patient with acute myocardial infarction by the recognition of giant V waves in the pulmonary capillary wedge pressure tracing. The recording was obtained by a pulmonary artery balloon catheter. The patient had a grade II holosystolic murmur consistent with mitral insufficiency. a = "a" wave.

Table 3

Angiography

Patient	Left ventricle		Mitral valve		Coronary arteries								
	Contour	Motion	Structure	Function	LAD		LCA		RCA				
					Occl.	Runoff	Occl.	Runoff	Occl.	Runoff			
H.S.	Enlarged, mitral thrombus	AL akinesis, apical aneurysm	Posterior prolapse	3+ systolic and diastolic regurgitation	100%	—	—	75%	+	RCA	100%	±	—
L.R.	Enlarged	AL akinesis, apical aneurysm	No prolapse	4+ systolic regurgitation	100%	—	—	25%	+	—	100%	—	—
G.K.	Enlarged	AL aneurysm	Anterior prolapse	4+ systolic and diastolic regurgitation	100%	+	—	100%	—	—	100%	+	—

Abbreviations: LAD = left anterior descending; LCA = left circumflex; RCA = right coronary artery; Occl. = occlusion; Col. = collaterals; AL = antero-lateral; + = adequate; ± = faint; — = absent.

Table 4

Postmortem Findings

Patient	Papillary muscles		Left atrium and valve		Left ventricle				
	Gross	Microscopic	Annulus (cm)	Left atrial size	Chordae and leaflets	Location of infarct	Heart wt (g)	Thickness of myocardium (cm)	Size and location of aneurysm
H.S.	Anterior muscle yellow, soft, mottled	Eosinophilic muscle with absent nuclei consistent with acute infarction	14	Dilated	Normal	Acute: septum, lateral wall Old: posterior wall	595	0.8 to 1.4	Anteroapical 11 cm in greatest dimension (surgical specimen)
L.R.	Anterior and posterior muscles fibrotic and thinned	Large areas of necrosis involving both papillary muscles with focal hyalinization	12	Dilated and hypertrophied	Normal	Acute: posterior wall Old: septum and anterior-lateral wall	710	0.2 to 2.0	Anteroseptal 30% of left ventricle
G.K.	Anterior and posterior muscles unremarkable	Recent infarction with scattered leukocytes and focal fibrosis	11	Dilated	Normal	Acute: lateral wall Old: septum and posterior wall	590	0.3 to 1.3	Anterior 9 cm in greatest dimension (surgical specimen)

some individuals prior to the onset of cardiogenic shock. Furthermore, failure to recognize or treat this entity during an acute surgical revascularization procedure may result in an unsuccessful outcome, even when coronary blood flow is restored to normal levels. Finally, since refractory pulmonary congestion characterized all three patients in this study, this complication should suggest the presence of silent mitral insufficiency in patients with acute myocardial infarction.

References

1. HEIKKILÄ J: Mitral incompetence complicating acute myocardial infarction. *Brit Heart J* **29**: 162, 1967
2. HOLLOWAY DH, WHALEN RE, MCINTOSH HD: Systolic murmur developing after myocardial ischemia or infarction: Differential diagnosis. *JAMA* **191**: 883, 1965
3. TAVEL ME, CAMPBELL RW, ZIMMER JF: Late systolic murmurs and mitral regurgitation. *Amer J Cardiol* **15**: 719, 1965
4. BASHOUR FA: Mitral regurgitation following myocardial infarction: The syndrome of papillary mitral regurgitation. *Dis Chest* **48**: 118, 1965
5. GANZ W, TAMURA K, MARCUS HS, DONOSO R, YOSHIDA S, SWAN HJC: Measurement of coronary sinus blood flow by continuous thermodilution in man. *Circulation* **44**: 181, 1971
6. GREENE DG, CARLISLE R, GRANT C, BUNNELL IL: Estimation of left ventricular volume by one-plane cineangiography. *Circulation* **35**: 61, 1967
7. PARMLEY WW, SONNENBLICK EH: Relation between mechanics of contraction and relaxation in mammalian cardiac muscle. *Amer J Physiol* **216**: 1084, 1969
8. RUSSELL RO JR, RACKLEY CE, POMBO J, HUNT D, POLANIN C, DODGE HT: Effects of increasing left ventricular filling pressure in patients with acute myocardial infarction. *J Clin Invest* **49**: 1539, 1970
9. CHENG TO: Incidence of ventricular aneurysm in coronary artery disease: An angiographic appraisal. *Amer J Med* **50**: 340, 1971
10. SWAN HJC, GANZ W, FORRESTER JS, MARCUS H, DIAMOND G, CHONETTE D: Catheterization of the heart in man with use of a flow-directed balloon-tipped catheter. *New Eng J Med* **283**: 447, 1970
11. SCHRIRE V, VOGELPOEL L, NELLEN M, SWANEPOEL A, BECK W: Silent mitral incompetence. *Amer Heart J* **61**: 723, 1961