

Diagnosis of Prosthetic Mitral Valve Malfunction with Combined Echo-Phonocardiography

93

BRUCE R. BRODIE, M.D., WILLIAM GROSSMAN, M.D., LAMBERT McLAURIN, M.D.,
PETER J. K. STAREK, M.D., AND ERNEST CRAIGE, M.D.

SUMMARY Fifty-three patients were studied with combined echo-phonocardiography or phonocardiography alone following prosthetic mitral valve replacement. In sixteen of these patients, clinical deterioration developed, and all subsequently underwent cardiac catheterization and/or surgery. Two patients came to autopsy. Included in this group of sixteen patients were five with obstructed prostheses, six with paravalvular regurgitation, and five with left ventricular dysfunction. Measurements were made of the time interval from the aortic valve closure sound to the peak opening of the mitral prosthesis determined echocardiographically or to the mitral prosthetic opening click (A_2 -MVO). Echocardiographic studies of left ventricular wall motion were also performed. The A_2 -MVO interval was significantly shortened

($P < 0.01$) with prosthetic valve obstruction ($.05 \pm .02$ sec) and paravalvular regurgitation ($.05 \pm .01$ sec) compared with normally functioning prostheses (Starr-Edwards ball valves $.10 \pm .02$ sec, Lillehei-Kaster tilting disc prostheses $.09 \pm .01$ sec). Shortening of this interval was not specific for these conditions because it was sometimes shortened with left ventricular dysfunction. Echocardiographic studies of left ventricular wall motion were helpful in distinguishing among prosthetic valve obstruction, paravalvular regurgitation and left ventricular dysfunction. The combined echo-phonocardiographic technique was especially helpful in detecting malfunction of tilting disc prostheses, because the technique enables measurement of the A_2 -MVO interval in the absence of an audible opening click.

□ **HEMODYNAMIC DETERIORATION** following prosthetic mitral valve replacement is commonly due to either left ventricular dysfunction, paravalvular regurgitation, or prosthetic valve obstruction, and it may be difficult to recognize and differentiate among these possibilities. Phonocardiography has been helpful in the diagnosis of prosthetic valve dysfunction by detecting changes in the intensity and timing of the prosthetic mitral opening click.¹⁻¹⁵ But some of the newer tilting disc prostheses do not consistently produce an opening click, so phonocardiography alone may not be applicable.¹⁶ We have used a combined echo-phonocardiographic technique that has special application to such a tilting disc prosthesis but applies to other prostheses as well. Our experience with this technique suggests that it is useful in the detection and diagnosis of prosthetic valve dysfunction.

Methods

Subjects

Combined echo-phonocardiography or, in some cases, phonocardiography alone, was performed in 53 patients following prosthetic mitral valve replacement. In this group were 27 patients with Lillehei-Kaster tilting disc prostheses, 24 patients with Starr-Edwards ball valve prostheses, one patient with a Beall floating disc prosthesis and one patient with a Kay-Shiley floating disc prosthesis. Sixteen of these patients exhibited clinical deterioration sufficient to require cardiac catheterization, surgery, or to come to autopsy. Of these 16 patients, five had prosthetic valve obstruction, six

had paravalvular regurgitation and five had left ventricular dysfunction (table 1). (One patient with paravalvular regurgitation underwent right heart catheterization only and is not included in table 1.)

Echo-Phonocardiography

Phonocardiograms were obtained from the four standard precordial areas with a Cambridge MC IV multichannel recorder using Leatham suction microphones. Echocardiograms were recorded with a Smith-Kline Ekoline 20-A ultrasonoscope interfaced to the Cambridge recorder. Echos of the interventricular septum, left ventricular posterior wall and mitral valve prosthesis were obtained by scanning techniques previously described.¹⁷ A lead II of the electrocardiogram (ECG) was recorded simultaneously with the echo-phonocardiogram.

The following measurements were made: 1) The time from the first high frequency component of the aortic valve closure sound to the peak opening of the mitral prosthesis as determined by the echocardiogram (A_2 -MVO). The technique is illustrated in figure 1. In patients who had only phonocardiograms recorded, the A_2 -MVO interval was measured as the time from the aortic closure sound to the first high frequency component of the mitral prosthetic opening click. 2) The echocardiographic left ventricular end-diastolic dimension (EDD), measured at the peak of the QRS of the ECG, and the end-systolic dimension (ESD), measured at the time of the aortic closure sound. Both of these measurements were taken as the vertical distance between echoes from the endocardial surfaces of the septum and the left ventricular posterior wall (fig. 1).

All measurements were taken to the nearest .01 sec or 1 mm and represent a mean obtained from five consecutive cardiac cycles. Analysis of differences in the A_2 -MVO intervals between normally functioning prostheses and malfunctioning prostheses was made using an unpaired *t*-test. Left ventricular septal motion was considered to be normal if the

From the Departments of Medicine and Surgery, University of North Carolina School of Medicine, Chapel Hill, North Carolina, and the C. V. Richardson Cardiac Catheterization Laboratory.

Supported by USPHS Grant 5 T01 HL05727-09. Dr. Grossman is an Established Investigator of the American Heart Association.

Address for reprints: Bruce R. Brodie, M.D., Department of Medicine, School of Medicine, University of North Carolina, Chapel Hill, North Carolina 27514.

Received June 2, 1975; revision accepted for publication August 7, 1975.

TABLE 1. Hemodynamic Data in Patients with Obstructed Mitral Prostheses, Paravalvular Mitral Regurgitation and Left Ventricular Dysfunction

Patient	CI (L/min/m ²)	EF	LVEDP (mm Hg)	PAW		MAP (mm Hg)	Angio MR	MVG (mm Hg)	MVA (cm ²)	Ave. rate of fall of LV pressure (mm Hg/sec)
				Mean (mm Hg)	A/V (mm Hg)					
<i>Obstructed Prosthesis</i>										
1.			mitral prosthesis obstructed with thrombus at necropsy							
2.			mitral prosthesis obstructed with thrombus at surgery							
3.	2.1		14	32	32/40	90	0	22	0.9	1059
4.	1.7	—	25	35	—/45	80	—	21	0.8	—
5.	2.7	.56	13	28	—/40	100	0	18	1.0	1000
<i>Paravalvular Regurgitation</i>										
6.	1.7	.50	18	30	—/50	90	3+			964
7.	2.3	—	12	25	—/60	75	4+			662
8.	2.9	.52	10	14(25*)	—/28(60*)	75	4+			550
9.	1.8	.45	22	26	22/46	82	4+			615
10.			paravalvular defect (3mm × 7mm) found at necropsy							
<i>Left Ventricular Dysfunction</i>										
11.	2.0	.21	28	30	—/40	90	1+			764
12.	1.5	.17	40	35	36/32	90	0			553
13.	1.9	.35	25	29	—/42	95	0			533
14.	2.1	.56	20	28	—/35	90	1+			889
15.	1.6	.45	25	35	35/45	110	1+			1671

*Values obtained with exercise.

Abbreviations: CI = cardiac index; EF = ejection fraction; LVEDP = left ventricular end-diastolic pressure; PAW = pulmonary artery wedge pressure; MVG = mean mitral valve gradient in diastole; MVA = mitral valve area; MAP = mean arterial pressure; Angio MR = degree of mitral regurgitation assessed by angiography: none (0), mild (1+), moderate (2+), moderately severe (3+), severe (4+).

septum moved posteriorly more than two mm from end diastole to end systole, paradoxical if it moved anteriorly more than two mm from end diastole to end systole and hypokinetic if it moved less than two mm in either direction from end diastole to end systole.¹⁸

Cardiac Catheterization and Angiography

Right and left heart catheterization was performed in

fifteen patients (table 1) and right heart catheterization alone was performed in one patient. The brachial arteriotomy approach was used and left ventricular and pulmonary artery wedge pressures were recorded with #8 fluid-filled catheters. Cardiac output was measured with the Fick method. Left ventriculography was performed in the right anterior oblique projection and particular care was taken to ensure that the catheter did not interfere with

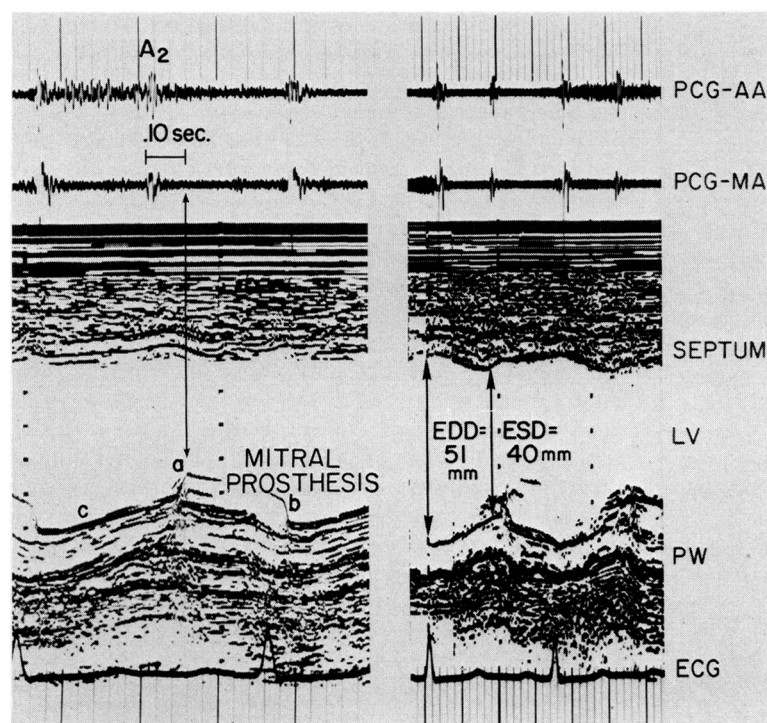


FIGURE 1 Combined echo-phonocardiogram in a patient with a normally functioning Lillehei-Kaster tilting disc mitral prosthesis. Phonocardiograms taken in the mitral area (PCG-MA) and aortic area (PCG-AA) are recorded at the top and the electrocardiogram (ECG) is recorded below. Mitral prosthetic opening is shown by a and mitral prosthetic closure by b. This echo is considered to be the disc movement. The valve ring within which the disc seats is represented by c. The peak opening of the prosthesis occurs .10 sec after the aortic valve closure sound (A₂) as shown in the left panel. The right panel shows normal motion of the interventricular septum and posterior wall (PW). The left ventricular (LV) internal dimension at end diastole (EDD) and end systole (ESD) are at the upper limits of normal.

prosthetic valve function. Mitral regurgitation was assessed by angiography as absent, mild, moderate, moderately severe or severe. Prosthetic valve obstruction was assessed by the mean pressure gradient across the mitral valve in diastole (MVG) and from the calculated mitral orifice area.¹⁹ Left ventricular dysfunction was diagnosed if at least two of the following three criteria were met: 1) an ejection fraction of less than .50; 2) a left ventricular end-diastolic pressure of more than 15 mm Hg and/or; 3) a cardiac index of less than 2.5 L/min/m² in the absence of significant valvular disease.

In addition, the average rate of fall of left ventricular pressure was measured as the difference between the left ventricular pressure at the level of the incisura of the arterial pressure tracing and the lowest left ventricular pressure, divided by the time interval over which this pressure fall occurred.

Results

Interval from Aortic Closure Sound to Mitral Opening

The A₂-MVO interval was significantly shortened ($P < 0.01$) with prosthetic valve obstruction (.05 ± .02 sec, mean ± SD) and paravalvular regurgitation (.06 ± .01 sec) compared with normally functioning prostheses (Starr-Edwards ball valves .10 ± .02 sec, Lillehei-Kaster tilting disc prostheses .09 ± .01 sec). See table 2.

A₂-MVO intervals in 29 patients with Lillehei-Kaster tilting disc prostheses are shown in figure 2. In patients with

normally functioning prostheses, the intervals ranged from .07 to .12 sec as previously reported by Gibson.¹⁶ The intervals were significantly shorter than this in patients with obstructed prostheses (.03 to .06 sec) and in patients with paravalvular regurgitation (.05 and .06 sec). The intervals in patients with left ventricular dysfunction were either short or normal (.06 to .10 sec).

A₂-MVO intervals in 24 patients with Starr-Edwards ball valve mitral prostheses, one patient with a Beall floating disc prosthesis and one patient with a Kay-Shiley floating disc prosthesis are shown in figure 3. In patients with normally functioning Starr-Edwards prostheses, the intervals ranged from .08 to .13 sec, which is in close agreement with previous studies.²⁰⁻²² Patients with paravalvular regurgitation had intervals that were considerably shorter than the normally functioning group (.04 to .07 sec). There were two patients with obstructed prostheses. One, with a Kay-Shiley floating disc prosthesis, had an A₂-MVO interval of .05 sec and the other with a Starr-Edwards ball valve prosthesis, had an interval of .08 sec. There were two patients with catheterization-documented left ventricular dysfunction. One had a shortened A₂-MVO interval of .06 seconds; the other patient, with a Beall floating disc prosthesis, had a prolonged interval (.15 sec). There was no evidence of sticking of the disc by cineangiography to account for the long A₂-MVO interval in the patient with the Beall prosthesis.

Previous observers have reported prolongation of the A₂-MVO interval and marked variation of this interval from beat to beat in patients with prosthetic valve obstruction,^{2-4, 6-8, 10, 11} but this was not observed in our series. This finding is presumably due to obstruction to the normal passage of the poppet resulting in a delay in the peak opening of the poppet.

Echocardiographic Findings

Table 2 lists the echo-phonocardiographic data in patients with obstructed prostheses, paravalvular regurgitation and left ventricular dysfunction. Patients with paravalvular

TABLE 2. Echo-Phonocardiographic Data in Patients with Obstructed Mitral Prostheses, Paravalvular Mitral Regurgitation and Left Ventricular Dysfunction

Patient	Prosthesis	A ₂ -MVO (sec)	EDD (mm)	ESD (mm)	Septal motion
Obstructed Prosthesis					
1.	L-K	.05	32	23	Paradoxical
2.	K-S	.05	—	—	—
3.	L-K	.03	42	22	Normal
4.	L-K	.06	31	28	Paradoxical
5.	S-E	.08	61	50	Normal
Mean ± SD		.05 ± .02*			
Paravalvular Regurgitation					
6.	S-E	.05	58	32	Normal
7.	S-E	.04	—	—	—
8.	S-E	.07	—	—	—
9.	L-K	.06	48	30	Normal
10.	L-K	.05	50	28	Normal
Mean ± SD		.05 ± .01*			
Left Ventricular Dysfunction					
11.	L-K	.07	62	52	Hypokinetic
12.	L-K	.10	70	62	Paradoxical
13.	Beall	.15	—	—	—
14.	L-K	.06	52	40	Hypokinetic
15.	S-E	.06	52	42	Hypokinetic
Mean ± SD		.09 ± .04			

*The A₂-MVO interval was significantly shortened with prosthetic valve obstruction and paravalvular regurgitation compared with normally functioning prostheses (Starr-Edwards ball valves .10 ± .02 seconds, Lillehei-Kaster tilting disc prostheses .09 ± .01 seconds).

Abbreviations: L-K = Lillehei-Kaster tilting disc prosthesis; K-S = Kay-Shiley floating disc prosthesis; S-E = Starr-Edwards ball valve prosthesis; A₂-MVO = aortic closure sound-mitral valve opening interval; EDD = left ventricular end-diastolic dimension; ESD = left ventricular end-systolic dimension; SD = standard deviation.

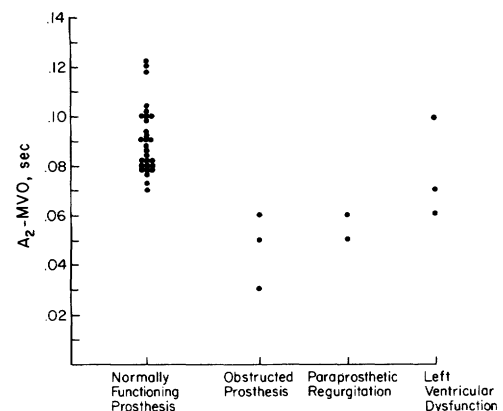


FIGURE 2 Aortic closure sound to mitral valve opening intervals (A₂-MVO) in 29 patients with Lillehei-Kaster tilting disc mitral prostheses. Patients with normally functioning prostheses have intervals ranging from .07 to .12 seconds. Patients with obstructed prostheses and paravalvular regurgitation have intervals considerably shorter than this while patients with left ventricular dysfunction have intervals that are short or normal.

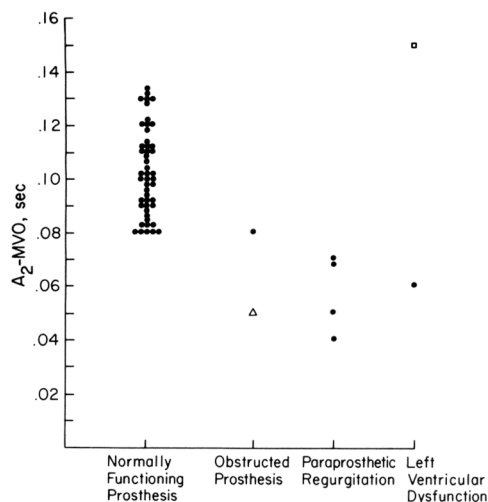


FIGURE 3 Aortic closure sound to mitral valve opening intervals (A_2 -MVO) in 24 patients with Starr-Edwards ball valve mitral prostheses (solid dots) and one patient each with a Beall floating disc prosthesis (open square) and a Kay-Shiley floating disc prosthesis (open triangle). Patients with normally functioning Starr-Edwards prostheses have intervals ranging from .08 to .13 sec. Patients with obstructed prostheses and paravalvular regurgitation have intervals that are generally shorter than this. There are two patients with left ventricular dysfunction; one with a short and one with a long A_2 -MVO interval.

regurgitation and left ventricular dysfunction tended to have large left ventricular dimensions²³ (normal EDD: 40–50 mm), while patients with obstructed prostheses tended to have smaller ventricular dimensions although this was also dependent on the nature of the preoperative valve disease. Posterior wall motion was characteristically sluggish with left ventricular dysfunction but was normal with prosthetic valve obstruction and paravalvular regurgitation in the absence of left ventricular dysfunction. Septal motion was paradoxical in two of four patients with obstructed prostheses and hypokinetic or paradoxical in all four patients with left ventricular dysfunction. In contrast to this, all patients with paravalvular regurgitation had normal vigorous septal motion. Examples of echocardiograms from patients with paravalvular regurgitation and left ventricular dysfunction are shown in figure 4.

There was one patient (patient 1, table 2) with a Lillehei-Kaster tilting disc prosthesis who may have had diminished poppet excursion (normal excursion: 7–12 mm for the Lillehei-Kaster prosthesis¹⁶) but the echogram of the prosthesis was not of sufficient technical quality to be certain of this.

Illustrative Case Histories

The following case histories illustrate how the echo-phonocardiographic data may be helpful in the evaluation of prosthetic valve dysfunction.

CASE 1 (PATIENT 3, TABLE 2)

A 54-year-old housewife with rheumatic mitral stenosis underwent mitral valve replacement with a Lillehei-Kaster tilting disc prosthesis in 1974. One month later she was readmitted to the hospital with acute shortness of breath. The blood pressure was 120/70 mm Hg and the pulse 100 beats/min and regular. The jugular veins were markedly distended and rales could be heard in the lower lung fields. A right ventricular lift was present but the left ventricular apex was quiet. The mitral prosthetic closure sound was clearly audible and there were no murmurs or gallops. The chest X-ray showed pulmonary edema. The prothrombin time was fifteen seconds with a control of twelve seconds.

An echo-phonocardiogram was obtained and showed a short A_2 -MVO interval of .03 sec and normal left ventricular dimensions (EDD 42 mm, ESD 22 mm). Prosthetic valve obstruction was suspected, confirmed at cardiac catheterization, and at surgery both sides of the prosthesis were found to be partially occluded with thrombus.

Comment. The clinical presentation in this patient is typical of patients with prosthetic valve obstruction in our series. The acute onset of pulmonary edema, inadequate anticoagulation, short A_2 -MVO interval and normal echocardiographic left ventricular dimensions are characteristic features.

CASE 2 (PATIENT 4, TABLE 2)

A 57-year-old housewife with rheumatic heart disease underwent aortic and mitral valve replacement with Lillehei-Kaster tilting disc prostheses for aortic and mitral stenosis in 1973. She did well until late 1974 when she was admitted

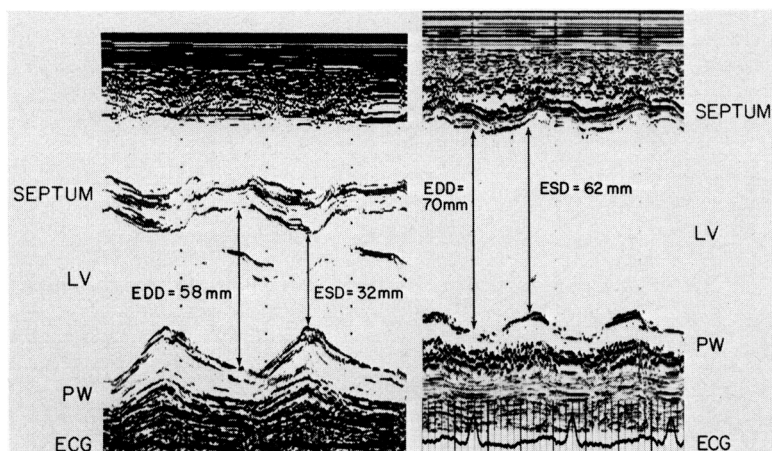


FIGURE 4 Echocardiograms of the left ventricle in a patient with paravalvular regurgitation (left panel, patient 6 in table 2) and a patient with left ventricular dysfunction (right panel, patient 12 in table 2). The electrocardiogram (ECG) is recorded below. The end-diastolic dimensions are large in both patients but the patient with paravalvular regurgitation has vigorous motion of the interventricular septum and posterior wall (PW) while the patient with left ventricular dysfunction has paradoxical septal motion and hypokinetic posterior wall motion. ESD = end-systolic dimension, LV = left ventricular chamber.

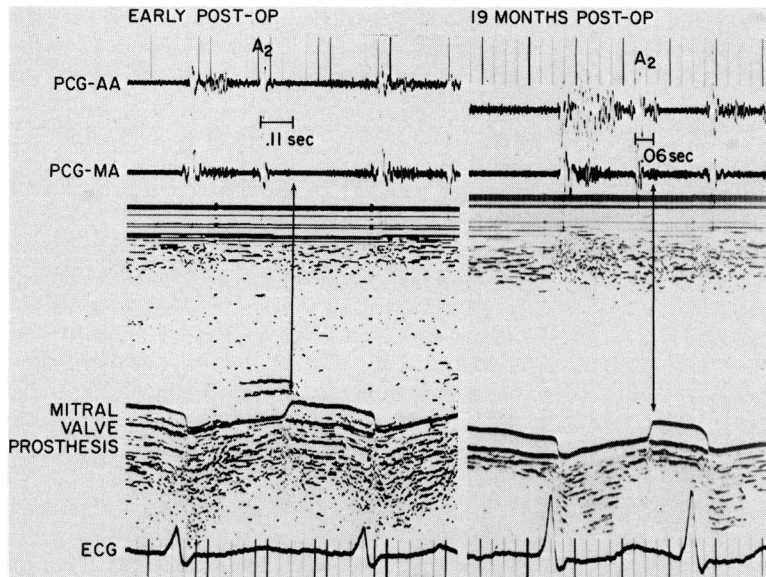


FIGURE 5 Combined echo-phonocardiogram in a patient (patient 4 in table 2) with a Lillehei-Kaster tilting disc mitral prosthesis. Phonocardiograms from the aortic area (PCG-AA) and mitral area (PCG-MA) are recorded at the top and the electrocardiogram (ECG) is recorded at the bottom. The tracing at the left was taken in the early postoperative period when the A_2 -MVO interval was normal (.11 sec). Nineteen months later, thrombosis of the prosthesis developed and the A_2 -MVO interval shortened to .06 sec. There was some variation in the A_2 -MVO interval in the second tracing due to the presence of atrial fibrillation and varying R-R intervals, but an average of measurements from five consecutive cycles also yielded a value of .06 sec.

with dyspnea and cough although she was in no acute distress. The blood pressure was 110/70 mm Hg and the pulse 130 beats/min and regular. The carotid pulse was brisk and there was no jugular venous distension. There were rales at the bases of the lung fields. The aortic and mitral prosthetic closure sounds were clearly audible and there was a systolic ejection murmur in the aortic area. The chest X-ray showed slight cardiomegaly, pulmonary congestion and a small left lower lobe pulmonary infiltrate. The electrocardiogram showed atrial flutter with 2:1 atrioventricular block. The prothrombin time was 13 seconds with a control of 12 seconds.

She was treated for pneumonia and again given anticoagulants. An echo-phonocardiogram was obtained which showed shortening of the A_2 -MVO interval to .06 sec from a previous value of .11 sec in the early postoperative period as shown in figure 5. The echocardiographic left ventricular dimensions were small (EDD 31 mm, ESD 28 mm) and the interventricular septum moved paradoxically. Because of these findings mitral valve obstruction was suspected, confirmed at cardiac catheterization, and she underwent successful mitral valve replacement. At surgery the disc excursion was diminished by encroachment of subvalvular scar tissue.

Comment. This patient was not acutely ill and mitral obstruction was not obvious by the usual clinical parameters. The short A_2 -MVO interval was the primary reason for suspecting prosthetic valve obstruction and proceeding with cardiac catheterization. This case illustrates the value of the A_2 -MVO interval in the early detection of prosthetic valve obstruction and shows how serial echo-phonocardiographic tracings are helpful.

CASE 3 (PATIENT 6, TABLE 2)

A 30-year-old farmer with rheumatic mitral stenosis underwent mitral valve replacement in 1969. A Starr-Edwards ball valve prosthesis was inserted into a heavily calcified mitral annulus. Postoperatively, there was a persistent systolic murmur and in 1970 he underwent repeat mitral

and tricuspid valve replacement with Starr-Edwards ball valve prostheses for mitral paravalvular and tricuspid regurgitation. He did fairly well until 1973 when he was readmitted to the hospital with increasing dyspnea and edema. The pulse was 90 and irregular. There were marked jugular venous distension, peripheral edema and rales in the lower lung fields. There were prominent right and left ventricular apical impulses. The closure sounds of the prostheses were clearly audible and there were two opening clicks following the second heart sound. An apical pansystolic murmur was present. The chest X-ray showed marked cardiomegaly and moderate pulmonary congestion.

An echo-phonocardiogram was obtained which showed a narrow A_2 -MVO interval of .05 sec (fig. 6) and large ventricular dimensions (EDD 58 mm, ESD 32 mm) with vigorous septal and posterior wall motion (fig. 4, left panel). At cardiac catheterization the patient was found to have severe paravalvular mitral regurgitation, and he subsequently underwent successful surgical replacement with a Lillehei-Kaster tilting disc prosthesis. Postoperatively the A_2 -MVO interval lengthened to .08 sec and the ventricular dimensions decreased (EDD 50 mm, ESD 25 mm).

Comment. This patient illustrates the characteristic echo-phonocardiographic findings with paravalvular regurgitation: a short A_2 -MVO interval and large left ventricular dimensions with vigorous septal and posterior wall motion. The echocardiogram shown in figure 6 was very helpful in identifying the mitral and tricuspid opening clicks. It may be quite difficult to identify prosthetic opening and closing sounds from the phonocardiogram alone in patients with multiple prostheses.

CASE 4 (PATIENT 11, TABLE 2)

A 55-year-old woman with longstanding rheumatic mitral stenosis underwent mitral valve replacement with a Lillehei-Kaster tilting disc prosthesis in 1974. Three months later she was readmitted with progressive dyspnea. The blood pressure was 140/80 mm Hg and the pulse 80 and regular. There were rales in both lower lung fields but no jugular

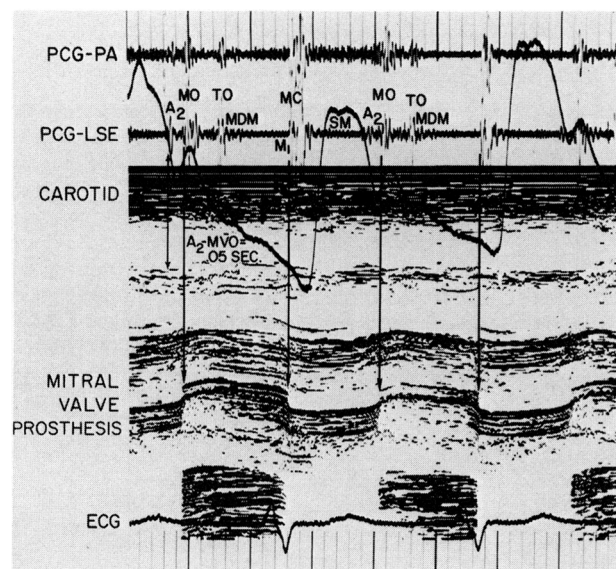


FIGURE 6 Combined echo-phonocardiogram and carotid artery tracings taken in a patient (patient 6 in table 2) with Starr-Edwards mitral and tricuspid ball valve prostheses and mitral paravalvular regurgitation. Phonocardiograms from the pulmonic area (PCG-PA) and left lower sternal edge (PCG-LSE) are recorded above and the electrocardiogram (ECG) is recorded below. The echocardiogram helps to identify the mitral opening click (MO) and tricuspid opening click (TO) and facilitates measurement of the A_2 -MVO interval. The interval is shortened (.05 sec) due to the presence of paravalvular mitral regurgitation. A_2 = aortic closure sound, MDM = mid-diastolic murmur, MC = mitral closure sound, M_1 = mitral valve closure, SM = systolic murmur.

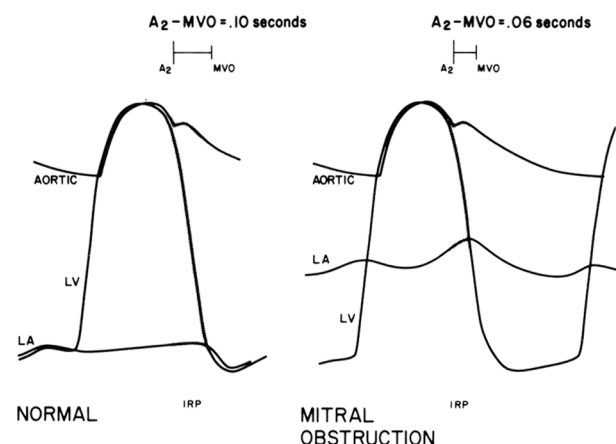


FIGURE 7 Schematic drawings of aortic, left ventricular (LV) and left atrial (LA) pressure tracings which illustrate the determinants of the isovolumic relaxation period and the A_2 -MVO interval. The isovolumic relaxation period (IRP) begins when the left ventricular pressure is at the level of the incisura of the aortic pressure and ends when the left ventricular pressure falls below the left atrial pressure. Peak mitral valve opening (MVO) occurs shortly after the crossover of left atrial and left ventricular pressures. The aortic closure sound (A_2) is coincident with the incisura of the aortic pressure tracing which is separated from the left ventricular pressure by an interval which has been termed "hangout." The tracings on the left are normal and result in a normal A_2 -MVO interval. The tracings on the right are representative of mitral obstruction and the elevation of the left atrial pressure results in early mitral valve opening and a short A_2 -MVO interval.

venous distention or peripheral edema. The left ventricular apex was not palpable. The prosthetic closure sound was clearly audible and there were no murmurs. There was a question of a third heart sound. Chest X-ray showed cardiomegaly and pulmonary vascular congestion. The prothrombin time was 36 seconds with a control of 12 seconds but had been 15 seconds with a control of 12 seconds one week prior to admission.

An echo-phonocardiogram showed an A_2 -MVO interval of .07 sec which had shortened from a value of .11 sec in the early postoperative period. The echocardiographic left ventricular dimensions were large with hypokinetic septal and posterior wall motion (EDD 70 mm, ESD 62 mm). She underwent cardiac catheterization and was found to have severe left ventricular dysfunction and a normally functioning mitral prosthesis.

Comment. This patient presented a very difficult diagnostic problem. The A_2 -MVO interval had shortened to .07 sec which is at the lower limits of normal for this prosthesis and the echocardiographic left ventricular dimensions were large with poor septal and posterior wall motion. These findings are consistent with left ventricular dysfunction alone but it was difficult to exclude co-existing prosthetic valve obstruction. Cardiac catheterization was required to exclude this possibility.

Discussion

The A_2 -MVO interval depends primarily^{24, 25} on the duration of the isovolumic relaxation period.* The isovolumic relaxation period, in turn, is determined by three hemodynamic variables: 1) aortic pressure at the time of aortic valve closure; 2) left atrial pressure at the time of mitral valve opening; and 3) the rate of fall of left ventricular pressure. The mechanism by which these factors influence the A_2 -MVO interval is illustrated in figures 7 and 8. The left panel of figure 7 shows a schematic representation of normal left atrial, left ventricular and aortic pressures which result in a normal A_2 -MVO interval. Mitral stenosis or mitral prosthetic valve obstruction characteristically elevates the left atrial pressure and causes early opening of the mitral valve and shortening of the A_2 -MVO interval²⁴ as shown in the right panel of figure 7. Paravalvular regurgitation is usually associated with a large left atrial v wave which also results in early mitral valve opening and shortening of the A_2 -MVO interval¹³ as illustrated in the left panel of figure 8. The changes produced by left ventricular dysfunction are more complex. The left atrial pressure will generally be elevated but the rate of fall of the left ventricular pressure will generally be diminished.²⁷ These two factors influence the duration of the isovolumic relaxation period in different directions as illustrated in the right panel of figure 8; consequently, the A_2 -MVO interval may be either shortened, normal, or prolonged.

*The A_2 -MVO interval and isovolumic relaxation time are not identical. The aortic valve closure sound (A_2) is coincident with the incisura of the aortic pressure tracing which is separated from the left ventricular pressure by an interval that has been given the descriptive term "hangout."²⁶ This interval is normally about .01 sec but may be prolonged in certain diseased states such as aortic stenosis.²⁶ Peak mitral valve opening (MVO) occurs a short period after the crossover of the left atrial and left ventricular pressure tracings. See figure 7 for the relationship of A_2 and MVO to the isovolumic relaxation period.

Our findings are in agreement with these considerations. Patients with obstructed prostheses and paravalvular regurgitation almost uniformly had shortened A_2 -MVO intervals. Patients with left ventricular dysfunction were variable; some had short and some had long A_2 -MVO intervals. Interestingly, the one patient with left ventricular dysfunction and a prolonged A_2 -MVO interval (patient 13, table 1) also had the slowest rate of fall of left ventricular pressure.

Paravalvular regurgitation, prosthetic valve obstruction, and left ventricular dysfunction may all result in shortening of the A_2 -MVO interval so this measurement alone is usually insufficient to allow distinction among these possibilities. Echocardiographic studies of the left ventricle may be very helpful in this distinction. Patients with obstructed prostheses tend to have small left ventricular dimensions while patients with paravalvular regurgitation and left ventricular dysfunction generally have large ventricular dimensions although this also depends on the nature of the preoperative valve disease. Serial echocardiograms may be helpful in this regard. Posterior wall motion is sluggish in patients with left ventricular dysfunction but is generally normal with prosthetic valve obstruction and paravalvular regurgitation in the absence of left ventricular dysfunction. Septal motion is frequently abnormal following cardiac surgery¹⁸ and this is often the case in patients with obstructed prostheses and left ventricular dysfunction. In contrast, patients with paravalvular regurgitation have normal vigorous septal motion as shown in this study and by others.¹⁵ *Hypokinetic or paradoxical septal motion makes significant mitral paravalvular regurgitation unlikely.*

A number of previous observers have reported the value of phonocardiography in the diagnosis of prosthetic valve malfunction.¹⁻¹⁵ Prosthetic valve obstruction (due to thrombosis, tissue ingrowth or poppet variance) can cause the following phonocardiographic changes: 1) The closing sound

may diminish in intensity.²⁻⁴ 2) The opening click may diminish in intensity or disappear altogether.^{1, 4, 5, 7} 3) The A_2 -MVO interval may become prolonged and vary from beat to beat.^{2-4, 6-8, 10, 11} (This is thought to be due to obstruction to the normal passage of the poppet resulting in delay of the peak opening of the poppet.) 4) The A_2 -MVO interval may be shortened.⁹ Paraprosthetic mitral regurgitation has been associated with the following phonocardiographic changes: 1) The opening click may be diminished or absent due to dehiscence of the prostheses.¹²⁻¹⁴ 2) The A_2 -MVO interval may be shortened.^{13, 15}

Mitral ball-valve prostheses, such as the Starr-Edwards prosthesis, and floating disc prostheses, each usually produce a clearly audible opening click. Some of the newer tilting disc prostheses, such as the Lillehei-Kaster prosthesis, do not produce an opening sound of any magnitude; consequently, the phonocardiographic findings listed above are of little help in the diagnosis of malfunction of these prostheses. The use of combined echo-phonocardiography is especially helpful in detecting malfunction of these prostheses because it enables measurement of the A_2 -MVO interval in the absence of an audible opening click.

Some important limitations of this study must be pointed out. First, there are varying degrees of severity of left ventricular dysfunction, paravalvular regurgitation and prosthetic valve obstruction so that values of the A_2 -MVO interval and echocardiographic left ventricular dimensions might be expected to form a continuum with normal values. Our patients had moderately severe to severe hemodynamic lesions and this is probably why there was such a good separation between groups in our study. Second, the A_2 -MVO interval may be influenced by a number of factors other than the presence of left ventricular dysfunction, prosthetic valve obstruction or paravalvular regurgitation. A low cardiac output and slow heart rate, for example, can diminish the mitral valve gradient and left atrial pressure and result in a normal isovolumic relaxation time and a normal A_2 -MVO interval despite significant mitral valve obstruction. Variations in blood pressure directly affect the isovolumic relaxation period and the A_2 -MVO interval. Coexisting aortic valve disease may potentially influence the A_2 -MVO interval by causing changes in aortic diastolic blood pressure, elevation of the left atrial pressure or prolongation of the hangout time of the aortic valve closure sound. Third, echocardiographic studies of left ventricular wall motion may be influenced by coexisting pathology such as tricuspid regurgitation or left ventricular dysynergy which may make interpretation difficult. In the context of these limitations, combined echo-phonocardiography may be very helpful in the assessment of prosthetic valve dysfunction.

In summary: 1) The A_2 -MVO interval is substantially shortened with prosthetic mitral valve obstruction and paravalvular mitral regurgitation and is useful in the detection of these conditions. This interval is not specific for these conditions because it is sometimes shortened with left ventricular dysfunction. 2) Echocardiographic studies of the left ventricle are helpful in distinguishing among prosthetic valve obstruction, paravalvular regurgitation and left ventricular dysfunction. 3) Combined echo-phonocardiography is especially useful in detecting malfunction of mitral tilting disc prostheses, because it enables measurement of the A_2 -MVO interval in the absence of an audible opening click.

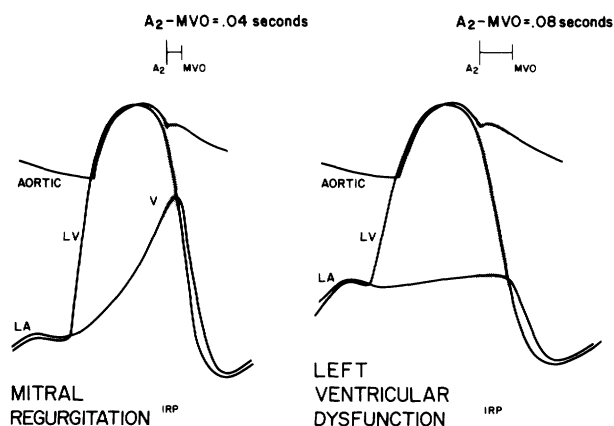


FIGURE 8 Schematic drawings of aortic, left atrial (LA) and left ventricular (LV) pressure tracings representative of mitral regurgitation (left) and left ventricular dysfunction (right). Mitral regurgitation is associated with large left atrial v waves (v) which result in early mitral valve opening and a short A_2 -MVO interval. Left ventricular dysfunction is associated with elevation of the left atrial pressure, which tends to shorten the A_2 -MVO interval, and a diminished rate of fall of left ventricular pressure, which tends to prolong the A_2 -MVO interval. The net result is that the interval may be either shortened, normal or prolonged.

Addendum

Since the manuscript was submitted for publication, we have seen three additional patients with mitral prosthetic valve dysfunction. One patient with a Starr-Edwards ball mitral prosthesis had an A₂-MVO interval of .07 seconds, an echocardiographic EDD of 49 mm, an ESD of 33 mm and normal septal motion. A second patient with a Lillehei-Kaster tilting disc prosthesis had an A₂-MVO interval of .06 seconds, an EDD of 50 mm, an ESD of 33 mm and normal septal motion. Both of these patients had severe para-valvular regurgitation documented by cardiac catheterization and underwent surgical correction. The third patient with a Lillehei-Kaster tilting disc prosthesis had an A₂-MVO of .03 seconds, an EDD of 42 mm, an ESD of 36 mm and paradoxical septal motion. This woman, who was in the 35th week of pregnancy, was found to have severe obstruction of the mitral orifice at cardiac catheterization and a heavily thrombosed prosthesis at surgery. Surgery was performed prior to delivery of the child; the patient did well but the baby did not survive.

Acknowledgment

We acknowledge and appreciate the help and cooperation of Dr. Benson R. Wilcox, Dr. Gordon F. Murray, Dr. Claude Smith and Dr. Lewis Williams who performed the surgery and participated in the care of many of these patients. We also gratefully acknowledge the technical assistance of Ms. Sally Moos and Ms. Carla Wolfe who obtained and processed much of the echophonocardiographic data and we appreciate the secretarial help of Ms. Sara Spinks, Ms. Emmy Woodall and Ms. Rhonda McClure in preparing the manuscript.

References

- Spencer FC, Trinkle JK, Reeves JT: Successful replacement of a thrombosed mitral ball-valve prosthesis. *JAMA* **194**: 191, 1965
- Sanderson RG, Hall AD, Thomas AN: The clinical diagnosis of ball variance in a mitral valve prosthesis. *Ann Thorac Surg* **6**: 473, 1968
- Leatherman LL, Leachman RD, McConn RG, Hallman GL, Cooley DA: Malfunction of mitral ball-valve prostheses due to swollen poppet. *J Thorac Cardiovasc Surg* **57**: 160, 1969
- McHenry MM, Smeloff EA, Fong WY, Miller GE, Ryan PM: Critical obstruction of prosthetic heart valves due to lipid absorption by Silastic. *J Thorac Cardiovasc Surg* **59**: 413, 1970
- Connolly DC, Harrison CE, Ellis FH Jr: Ball variance in a Starr-Edwards prosthetic mitral valve causing acute pulmonary edema (diagnosis by auscultation before onset of symptoms). *Mayo Clinic Proc* **45**: 20, 1970
- Craige E, Hutchin P, Sutton R: Impaired function of cloth-covered Starr-Edwards mitral valve prosthesis. Detection by phonocardiography. *Circulation* **41**: 141, 1970
- Lee SJK, Zaragoza AJ, Callaghan JC, Couves CM, Sterns LP: Malfunction of the mitral valve prosthesis (Cutter-Smeloff). *Circulation* **41**: 479, 1971
- Schluger J, Mannix EP Jr, Wolf RE: Auscultatory and phonocardiographic sign of ball variance in a mitral prosthetic valve. *Am Heart J* **81**: 809, 1971
- Wise JR, Webb-Peploe M, Oakley CM: Detection of prosthetic mitral valve obstruction by phonocardiography. *Am J Cardiol* **28**: 107, 1971
- Pfeifer J, Goldschlager N, Sweatman T, Gerbode F, Selzer A: Malfunction of ball valve prosthesis due to thrombus. *Am J Cardiol* **29**: 95, 1972
- Belenkie I, Carr M, Schlant RC, Nutter DO, Symbas PN: Malfunction of a Cutter-Smeloff mitral ball valve prosthesis: Diagnosis by phonocardiography and echocardiography. *Am Heart J* **86**: 399, 1969
- Leachman RD, Cokkinos DVP: Absence of opening click in dehiscence of mitral valve prosthesis. *N Engl J Med* **281**: 461, 1969
- Willerson JT, Kastor JA, Dinsmore RE, Mundth E, Buckley MJ, Austen WG, Sanders CA: Non-invasive assessment of prosthetic mitral para-valvular and intra-valvular regurgitation. *Br Heart J* **34**: 561, 1972
- Aravanis C, Toutouzas P, Stavrou S: Disappearance of opening sound of Starr-Edwards mitral valve due to valvular detachment. *Br Heart J* **34**: 1314, 1972
- Miller HC, Gibson DG, Stephens JD: Role of echocardiography and phonocardiography in diagnosis of mitral paraprosthesis regurgitation with Starr-Edwards prostheses. *Br Heart J* **35**: 1217, 1973
- Gibson TC, Starek PJK, Moos S, Craige E: Echocardiographic and phonocardiographic characteristics of the Lillehei-Kaster mitral valve prosthesis. *Circulation* **49**: 434, 1974
- Feigenbaum H: Clinical applications of echocardiography. *Prog Cardiovasc Dis* **14**: 531, 1972
- Burgraff GW, Craige E: Echocardiographic studies of left ventricular wall motion and dimensions after valvular heart surgery. *Am J Cardiol* **35**: 473, 1975
- Herman MV, Cohn PF, Gorlin R: Resistance to blood flow by stenotic valves: Calculation of orifice area. In *Cardiac Catheterization and Angiography*, edited by Grossman W. Philadelphia, Lea & Febiger, 1974, p 88
- Zitnik RS, Burchell HB: A phonocardiographic study of patients with total prosthetic mitral valve replacement. *Dis Chest* **44**: 11, 1963
- Hultgren HN, Hubis H: A phonocardiographic study of patients with the Starr-Edwards mitral valve prosthesis. *Am Heart J* **60**: 306, 1965
- Najmi M, Segal BL: Auscultatory and phonocardiographic findings in patients with prosthetic ball-valves. *Am J Cardiol* **16**: 794, 1965
- Popp RL, Harrison DC: Cardiac chamber size and volume: Echographic measurement of cardiac chamber dimensions, volume and ventricular function. In *Ultrasound in the Diagnosis of Cardiovascular-pulmonary Disease*, edited by Joyner CR. Chicago, Year Book Medical Publishers, 1974, p 75
- Craige E: Phonocardiographic studies in mitral stenosis. *N Engl J Med* **257**: 650, 1957
- Oriol A, Palmer WH, Nakhjavan F, McGregor M: Prediction of left atrial pressure from the second sound-opening snap interval. *Am J Cardiol* **16**: 184, 1965
- Shaver JA, Nadolny RA, O'Toole JD, Thompson ME, Reddy PS, Leon DF, Curtiss EI: Sound pressure correlates of the second heart sound: An intracardiac sound study. *Circulation* **49**: 316, 1974
- McLaurin LP, Rolett EL, Grossman W: Defective left ventricular relaxation in congestive heart failure. *Circulation* **50** (Suppl III): III-45, 1974