

# Double Ventricular Parasystole

## Supernormal Phase of Conduction as a Mechanism of Intermittent Parasystole. Report of a Case

KAZUMASA HIEJIMA, M.D., AND TING D. POH, M.D.

**SUMMARY** A rare case of spontaneous double ventricular parasystole was studied in depth, together with a critical review of similar cases in the literature. The discussion was focused on 1) the variation of the shortest interectopic interval (SIEI), 2) entrance block and its failure, 3) supernormality as a mechanism of intermittence, and 4) effects of lidocaine and atropine on such an arrhythmia. In double ventricular parasystole a greater than usual variation in the SIEI tended to occur in one of the two parasystolic groups. If, however, such variations were too great in the face of otherwise parasystolic rhythm, presence of intermittence was confirmed.

**IN CLINICAL ELECTROCARDIOGRAPHY** incidence of double ventricular parasystole is extremely rare, whether it arises from 1) two spontaneous ectopic pacemakers,<sup>1-4</sup> or 2) the combination of a spontaneous and an artificial pacemaker,<sup>5-7</sup> or 3) the combination of two artificial pacemakers.<sup>8-10</sup> Such rare cases as these provide a unique opportunity to study interactions between the three pacemakers (one sinus) over more than a single parasystole. Recently, Steffens<sup>6</sup> demonstrated a case of double ventricular parasystole (one artificial) in which the mechanism of intermittent ventricular parasystole was shown to be due to a temporary failure of the entrance block. Furthermore, he found that the fixed coupling of the first beat of an intermittent series was a consequence of temporary entrance block failure rather than a manifestation of a more complex mechanism.

The purpose of this paper is to report our study of a rare case of spontaneous double ventricular parasystole in which one parasystolic beat was fired coincident with the supernormal phase of conduction of another parasystolic beat, which took on the pattern of intermittence. The latter pattern is most likely due to a temporary loss of the entrance block.

### Report of a Case

A 63-year-old Japanese male was admitted to the university hospital, his chief complaints being palpitation and dyspnea. Prior to admission he had been treated in the outpatient clinic for diabetes mellitus and hypertension. On admission, among significant findings were cyanosis of the lip, pitting edema of the lower extremities, arrhythmias, and an elevated blood pressure of 190/90 mm Hg. There was no audible murmur or gallop. The lungs were loaded with moist rales. Chest X-ray demonstrated an eccentric cardiomegaly

A temporary loss of the entrance block was deemed primarily responsible for the intermittency. That is to say, invasion, discharge, and resetting of one parasystolic focus by another parasystolic impulse during the supernormal phase of the ventricle was considered the cause of an intermittence.

In a strict sense, this is the first report in the literature in which the supernormality was clearly indicated as one mechanism of intermittent ventricular parasystole. The advantage of the concept of double ventricular parasystole as compared to single parasystole in defining such a mechanism is stressed.

and the lungs presented a butterfly-shaped central density covering both hilar regions. An admission electrocardiogram showed frequent ectopic beats, and an acute myocardial infarction could not be ruled out completely. An intravenous bolus injection of lidocaine 100 mg followed by a continuous i.v. drip (2 mg/min) was administered which was continued overnight reaching a total dose of 2,360 mg as of the next morning. Oxygen inhalation was given via nasal cannula along with administration of diuretics (furosemide). No digitalis was used.

### Interpretation of the Electrocardiogram

Figure 1 represents the admission electrocardiogram in which three types of ventricular complexes were noted. The dominant sinus beat was labeled by R and the ectopic beats by R1 and R2, respectively. On lead V<sub>1</sub>, R1 demonstrated qrR' pattern with a duration of 0.14 sec and R2 demonstrated rSr's' pattern with a duration of 0.13 sec, suggesting that both originated in the left ventricle. The coupling intervals of these ectopic beats to the preceding sinus beats were variable, and there was no association between R1 and R2. When the interectopic intervals, i.e., R1-R1 and R2-R2 were measured, the former was found to be equal to or a multiple of one of the following number — 137, 138, 139; 140, 144\* — and the latter was either equal to or a multiple of one of the following number — 186, 188, 189, 190. An analysis of a long rhythm strip revealed that the sinus rate was 78 beats/min and there was no directly measurable ectopic cycle length with both the R1 and the R2 parasystole groups. The shortest interectopic intervals, including those calculated from long interectopic intervals, ranged between 133–146 (with a mean and standard error of  $138.72 \pm 3.69$ ) for R1, and 174–192 ( $182.60 \pm 4.64$ ) for R2. Thus the rates of two independent ectopic rhythms corresponded to 43 beats/min (R1) and 33/min (R2), respectively.

Figure 2 is the tracing obtained at a different time, shortly after admission. It illustrates various types of fusion beats. Tracing A shows fusion of R and R1 (beat 8), tracing B, fu-

From the First Department of Internal Medicine, and Institute for Cardiovascular Diseases, Tokyo Medical and Dental University, Tokyo, Japan; and Second Department of Internal Medicine, Yokohama City University School of Medicine, Yokohama, Japan.

Address for reprints: Ting D. Poh, M.D., 112 Yamashita-cho, Naka-ku, Yokohama, Japan 231.

Received March 10, 1975; revision accepted for publication August 11, 1975.

\*These numbers and all subsequent numbers are measurements in hundredths of a second.

sion of R and R2 (beat 7), and tracing C, fusion of R1 and R2. As it is clearly seen in figure 1 and figure 2, the presence of varying coupling intervals, fusion beats, and mathematically related interectopic intervals suggest an operation of independent ectopic pacemakers, and therefore, a parasystole. Furthermore, the operation of parasystole in this case is twofold, i.e., there are two independent ectopic foci which are manifest and their activities are not related to the dominant sinus rhythm. This particular case therefore can well be diagnosed as a double ventricular parasystole.

Figure 3 is the tracing obtained on a different date. In this tracing the R1-R1 intervals were almost constant, with a narrow range of variation among the shortest interectopic intervals (136-140). The intervals of R2-R2, however, showed a greater than usual variation, with a difference of 0.32 second between the longest (220) and the shortest interectopic intervals (188) when those directly measurable ones were compared. Moreover, if the calculated shortest interectopic interval (178) was taken for comparison, the above figure became 0.42 sec, which far exceeded the range of 0.08 to 0.27 seconds given by Chung as an acceptable range of variation in the shortest interectopic intervals. However, coupling of varying forms of R2 to either the preceding sinus beats or the R1 ectopic beats was present and fusion of R and R2 (beats 20 and 24) was also present. Therefore, intermittence was proposed as the reason that a

mathematical relationship among the R2-R2 cycle intervals was absent.

The fact that in the middle strip there was an abrupt prolongation of the R2-R2 interval, from 188 to 220 first attracted our attention. In this tracing the sinus rate was 83 beats/min without appreciable sinus arrhythmia. The group R1 ectopic beats demonstrated a continuous parasystole, with a mean cycle length of 136, corresponding to a rate of 44 beats/min. The group R2 ectopic beats showing the features of intermittent parasystole had a rate of 32 beats/min with a mean cycle length of 184. The Q-T interval of R2 beat could not be sharply defined but the peak of T wave was clearly inscribed. The fact that a certain R1 in the latter portion of the middle strip (beat 21) occurred at the terminal portion of T wave of the preceding R2 (beat 20) tempted us to consider that this particular R1 must have propagated within the supernormal phase of conduction of the preceding R2 beat. Because of this, a conduction abnormality around the R2 focus must have been altered, causing a temporary loss of the entrance block. This loss of block would allow invasion of R1 impulse into the R2 focus and subsequent discharge as well as resetting of R2. The above postulation is also supported by the observation that the R1 in question (beat 21) had depolarized the R2 focus prematurely at its supernormal phase of conduction. Clearly then, the long R2-R2 interval of 220 should be broken down

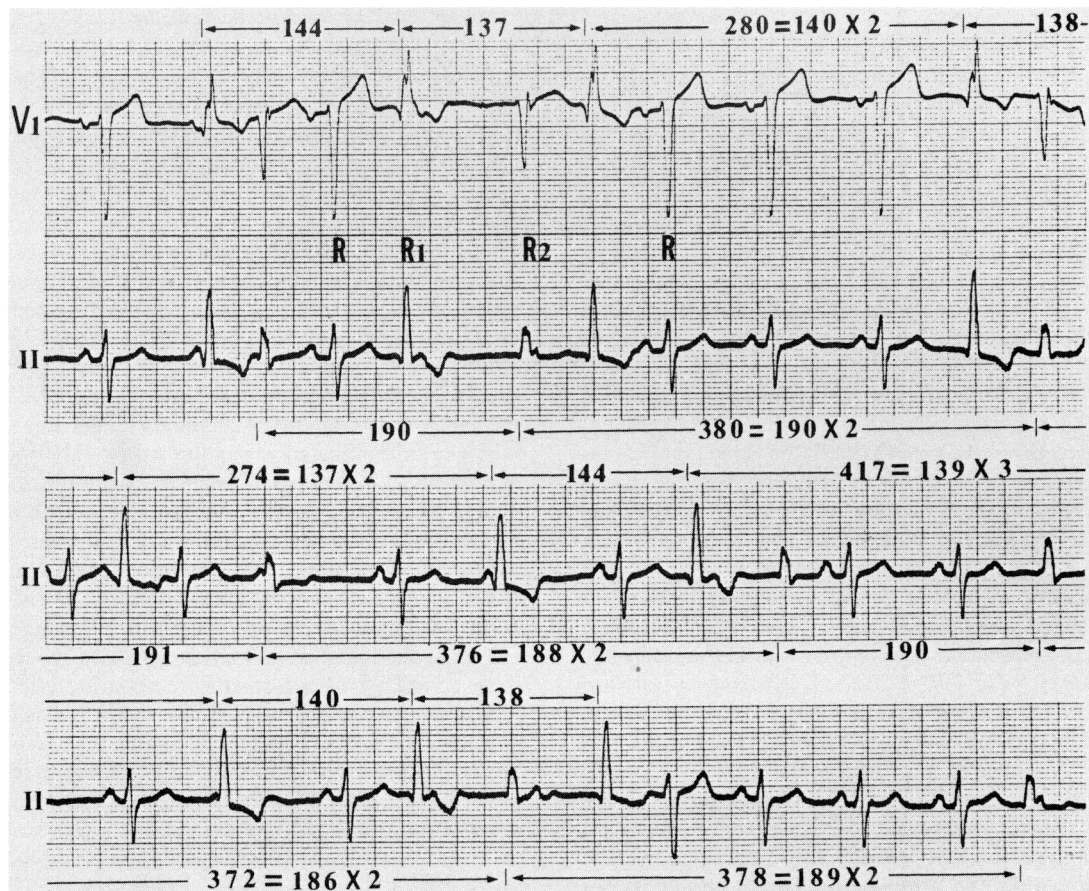


FIGURE 1. An electrocardiogram taken on admission; continuous tracings. Numbers (in hundredths of a second) indicated above and beneath each strip show the R1-R1 as well as R2-R2 interval times.

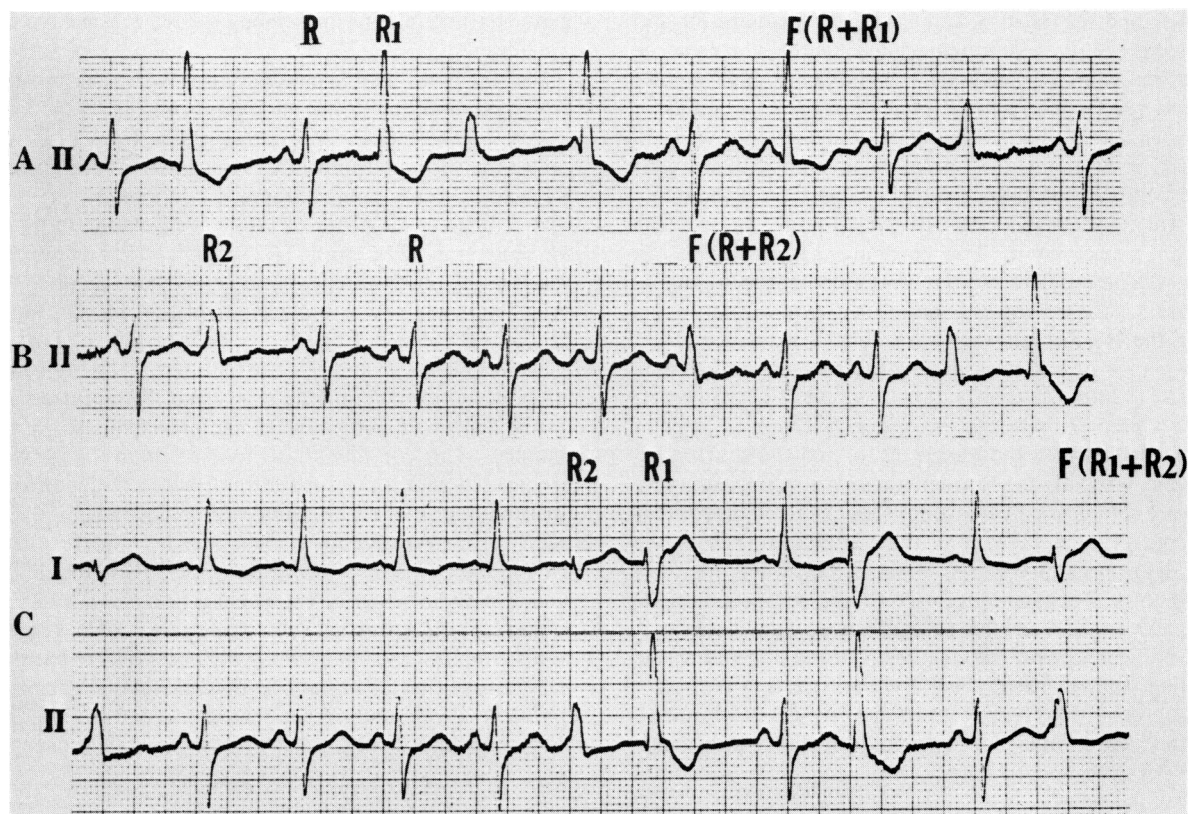


FIGURE 2. Various types of fusion beats in ECG taken shortly after the one illustrated in figure 1.

to 42 plus 178 in which the former (R2-R1 interval) represents a fixed coupling interval of R1 to the preceding R2, and the latter represents the parasystolic escape interval. We believe that in this way a series of intermittent R2s continued from the twentieth to the twenty-ninth R2, with an ectopic cycle length of 178.

An analysis of the long strip following the recording illustrated in figure 3 revealed that the same phenomenon had occurred as many as three times and that it always occurred in a predictable fashion whenever the R1 arose a very short time after the preceding R2 (table 1).

Figure 4 is another example of this phenomenon in which the long R2-R2 interval was 216 and the coupling interval of R1 to the preceding R2 was 42. In all the three manifest instances there was a very short fixed coupling between the interrupting R1 and the preceding R2. In two instances, the R2-R1 interval measured 0.42 second and in the remaining one instance, it was 0.38 second.

It is of special interest to note that a similar mechanism seemed to have also been operative throughout the initial portion of the middle strip of figure 3 where the ostensible R2-R2 interval was  $404 = 202 \times 2$ . Measuring forward from the eleventh R2 (last beat in the upper tracing) one can plot the estimated discharging point of next R2 in the first portion of the middle strip by adding the mean cycle length of 184. The calculated point falls slightly after the QRS complex of the sinus beat (beat 13). The predicted R2 is not apparent in the tracing; it was obviously concealed because it occurred within the absolute refractory period of the associated sinus beat. However, an action potential must

have been generated within the R2 focus. A concealed R2 beat is assumed to carry the same effect as a manifest R2 beat insofar as its effect on the electrophysiological properties of the myocardium surrounding the R2 focus is concerned. It is conceivable, therefore, that the fourteenth R1 must have fallen within the supernormal phase of the concealed R2 beat, and thus, a temporary loss of the protective entrance block around the R2 focus ensued. The coupling interval of the fourteenth R1 to the preceding concealed R2 beat measured 42, and hence, the R2-R2 interval of  $404 = 202 \times 2$  actually should be 184 plus 220. The latter should be further broken down into 42 plus 178. Analyzing the interval 404 as 184, 42, and 178 indicates that intermittence in this instance was limited to only one beat.

Table 1 was prepared in order to clarify the above stated unique relationship between the R1 and the R2, as revealed by their behaviors under certain circumstances. The entire available long rhythm strips were used for measurements of R2-R1 intervals whenever the R2 occurred ahead of the R1. Both the immediately\* preceding and following R2-R2 intervals to the manifest as well as concealed R2-R1 intervals were compared to see whether a resetting effect was exhibited by the very short R2-R1 intervals. It was shown that whenever the R2-R1 intervals fell within the narrow range of 38 to 42 resetting of the following cycle occurred.

As the last step to finally establishing the R2 parasystole as an intermittent parasystole, the first parasystolic beat of

\*Here, "immediately" means that the R2s comprising R1-R1 intervals were used as the measuring point for both the preceding and following R2-R2 intervals.

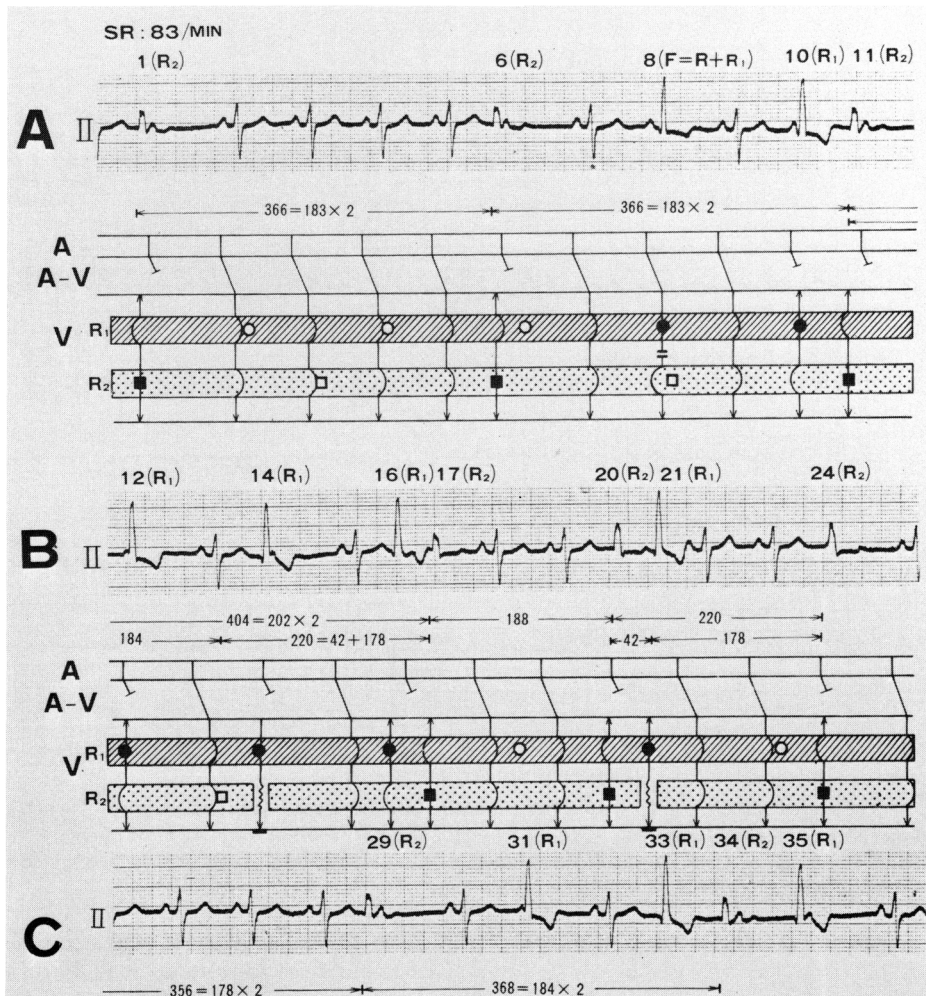


FIGURE 3. An electrocardiogram taken on a different date. A, B, C are continuous tracings. Patient was receiving lasix and lidocaine at the time of recording. Standard diagramming conventions apply except for inclusions of two columns within the ventricular level for the purpose of indicating the presence of two parasystolic foci. ● indicates manifest discharging point of R1. ■ represents manifest discharging point of R2. ○ represents the estimated discharging point of R1 while □ indicates estimated discharging point of R2 (concealed R1 and R2). The striped bar represents protection at the level of R1 focus whereas the stippled bar represents protection at the level of R2 focus. Unidirectional arrows that circumbent both striped and stippled bars indicate sinus beats that do not interrupt the double parasystolic rhythm. Bidirectional arrows that circumbent the stippled bar indicate R1 parasystolic beats that do not interrupt the R2 parasystolic rhythm. Bidirectional arrows that circumbent the striped bar indicate R2 parasystolic beats that do not interrupt R1 parasystolic rhythm. Bidirectional arrows with a zigzag portion transecting the blank spaces of the stippled bar represent R1 parasystolic impulses which invade, depolarize, and reset the R2 focus. Solid short black bars at the bottom of the diagram of tracing B indicate supernormal phase of conduction of either manifest or concealed R2 parasystolic beat.

each intermittent series was examined to see whether coupling to the preceding dominant beats was fixed. We found that there was no fixed coupling of the first R2 beat of each intermittent series to the preceding sinus beats. However, as was clearly shown previously, there was fixed coupling of the said R2 beats to the immediately following R1 beats. We believe this is not surprising because 1) a double ventricular parasystole exists, 2) both R1 and R2 beats are regular, 3) the discharge rate of R1 is faster than that of R2, and 4) hence, the R1 can be regarded as the dominant pacemaker relative to R2, and 5) because the fixed coupling of R1 to R2 is direct implication of premature depolarization of R2 by R1, it can be used as evidence for the phenomenon of reset-

ting of R2 focus — in other words, intermittency. The most likely diagnosis of this interesting case is therefore 1) spontaneous double ventricular parasystole and 2) transition of one of the two continuous parasystoles to an intermittent parasystole.

#### Effect of Drugs

Following an intravenous injection of lidocaine in a dose of 100 mg, there was a transient decrease in the appearance of R1 and complete disappearance of R2. A tracing taken seven minutes after lidocaine demonstrated the following changes, without an appreciable change in the sinus rate (table 2).



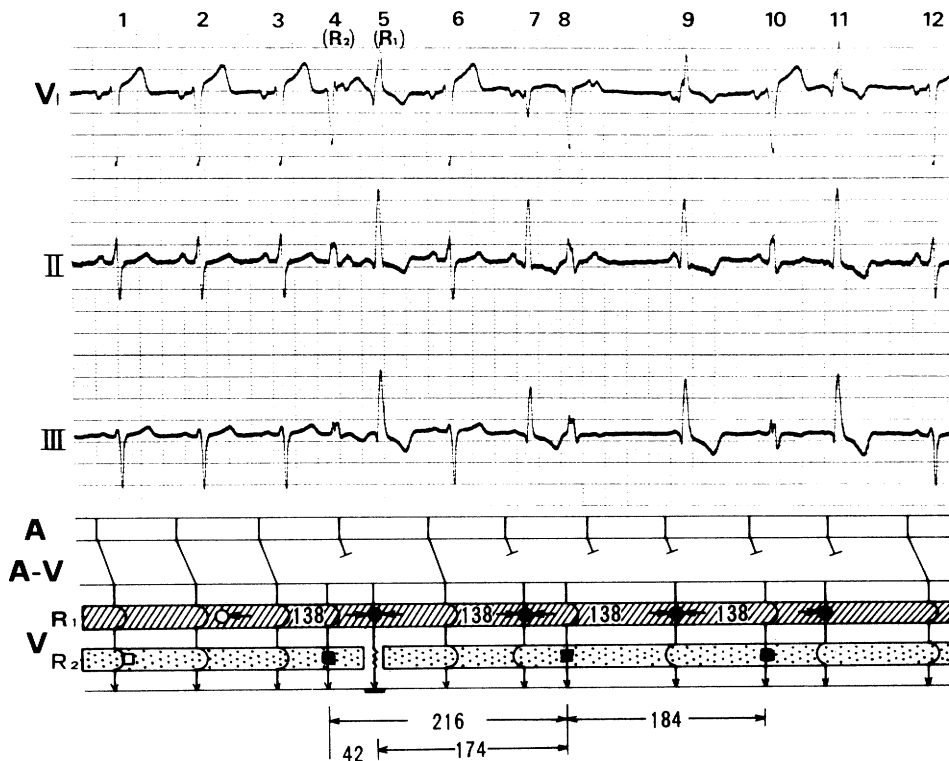


FIGURE 4. Another rhythm strip in which a same phenomenon as seen in figure 3 was demonstrated. When R1 occurs at the supernormal phase of R2, that is, when the R2-R1 interval is critically short, a temporary loss of the entrance block around the R2 focus ensues with subsequent depolarization and resetting of the R2 focus. All the symbols used for explanation of the mechanism involved are the same as figure 3.

- 1) Decrease in the number of R1 (from 22 to 10/min)
- 2) Disappearance of R2
- 3) Decrease in the number of directly measurable shortest R1-R1 interval. All but one R1-R1 interval became multiples of the shortest interectopic interval.
- 4) Decrease in the frequency of fusion beats
- 5) Prolongation of R1-R1 interval (mean 133.36 to 170.90)
- 6) Increase in the variation of R1-R1 intervals ( $SD \pm 3.72$  to  $\pm 11.98$ )

These changes however were of transient nature, and once an intravenous drip infusion of lidocaine was established all the features of the pre-lidocaine stage were restored including reappearance of R2.

As regards the effect of atropine the following changes were observed one and one half minutes after an intravenous injection of 1.0 mg (table 3).

- 1) No change in R1-R1 intervals
- 2) No change in R2-R2 intervals
- 3) A decrease in the appearance of R1 (from 18 down to 13/min)
- 4) An increase in the frequency of fusion beats between R and R2.

The reason the number of R1 has decreased following an administration of atropine can be attributed to an acceleration of sinus rate because this increased the chances that the ectopic R1 would fall within the refractory period of the sinus

beat. By the same token, an increased sinus rate clearly gave rise to increased appearance of R-R2 fusion beats when the sinus rate approached half the rate of R2.

With improvement of congestive heart failure propagation of R2 has subsided in this patient. Another attempt of administering atropine at this juncture yielded essentially the same effect as previously. Ashner's maneuver as well as inhalation of amyl nitrite has also failed to cause specific changes on the rhythm.

### Discussion

Although recent experiences with the artificial pacemaker<sup>6-11</sup> drew our attention to the problem of multifocal parasystole, a spontaneous occurrence of such arrhythmia has been considered extremely rare. As far as spontaneous double ventricular parasystole goes, only four cases could be found in the literature,<sup>2,3</sup> and very recently, two rhythm strips with features of double ventricular parasystole have been presented by El-Sherif and Samet.<sup>4</sup> The case under discussion appears to satisfy the diagnostic criteria for double ventricular parasystole except for one aspect which concerns the variation of the shortest interectopic interval (SIEI) in one of the two coexisting parasystoles.

### The Interectopic Interval

It has been generally believed that the SIEIs in parasystole vary only a few hundredth of a second.<sup>12-14</sup> Watanabe considered that a difference of 0.10 second or greater

TABLE 1. Relationship of R2-R1 Interval to the Immediately Following R2-R2 Interval

Preceding R2-R2	Mani- fest R2-R1	Immediately following R2-R2
528 (179 × 3)	34	364 (182 × 2)
370 (185 × 2)	50	370 (185 × 2)
180	53	374 (187 × 2)
186	50	354 (177 × 2)
178	57	376 (188 × 2)
180	44	364 (182 × 2)
370 (185 × 2)	44	370 (185 × 2)
536 (179 × 3)	35	705 (176 × 4)
366 (183 × 2)	36	704 (176 × 4)
368 (184 × 2)	74	185
186	49	364 (182 × 2)
186	49	364 (182 × 2)
*182	38	216 216 - 38 = 178
180	53	372 (186 × 2)
*366 (183 × 2)	42	404 404 - 42 - 183 = 179
*188	42	220 220 - 42 = 178

Preceding R2-R2	Calcu- lated R2-R1	Immediately following R2-R2
364 (182 × 2)	55	352 (176 × 2)
536 (178.7 × 3)	51	356 (178 × 2)
354 (177 × 2)	54	533 (177.7 × 3)
533 (177.7 × 3)	32	690 (172.5 × 4)
184	32	522 (174 × 3)
*530 (176.7 × 3)	38	754 754 - 38 = 716 = 179 × 4
*182	42	597 597 - 42 = 555 = 185 × 3
or		
42 + 179 + (188 × 2) = 597		
359 (179.5 × 2)	56	356 (178 × 2)
366 (183 × 2)	55	376 (188 × 2)
356 (178 × 2)	54	365 (182.5 × 2)
*366 (183 × 2)	42	404 42 + 178 + 184 = 404

\*Indicates a critically short R2-R1 interval.

between single and calculated cycle length was unusually great.<sup>15</sup> Chung, however, made a careful review of electrocardiograms of previously published parasystole, only to find out there was, in fact, marked variation in the SIEIs. According to him the variations ranged from 0.08 to 0.27 second.<sup>16</sup>

In single parasystole, while there is no precisely constant interectopic interval,<sup>16-18</sup> we have found that in majority of the published cases, variations in the SIEIs were less than 0.18 second. In double ventricular parasystole however, the range of variations in the SIEI can at times become greater than usual. In two cases of double ventricular parasystole reported by Chung, Walsh, and Massie,<sup>1</sup> one group (their group B) of the two concurrently discharging parasystoles showed narrow ranges of variations — 0.07 sec (Case 1) and 0.02 sec (Case 2) — while the other group (their group A) demonstrated wide ranges of variations of 0.18 sec (Case 1) and 0.22 sec (Case 2), respectively. On the other hand, a case reported by Roelandt, Pool, and Schamroth<sup>3</sup> showed little ranges of variations in the SIEIs with both the two groups — 0.06 sec (their group E1) and 0.03 sec (their group E2), respectively. Our case showed a different feature in which one parasystole (R1) exhibited a small range of variation (0.07 second in a single strip, 0.13 second in records taken at different times), while the other (R2) shifted to an intermit-

TABLE 2. Prolongation of the Shortest R1-R1 Intervals Immediately after an Intravenous Injection of Lidocaine (100 mg)

Before	After
132	180
*135	173 (×4)
136 (×3)	194 (×2)
132	164 (×2)
*132	181 (×3)
133 (×5)	162 (×2)
133	180 (×3)
137 (×4)	160 (×4)
130	161 (×5)
*130	154 (×2)
134 (×3)	
143	
133	
132	
*137 (×4)	
132	
130	
128	
140	
136 (×3)	
130	
129	
133.36 ± 3.72	170.90 ± 11.98

Numbers with parentheses are the shortest calculated interectopic intervals.

\*Indicates fusion beat.

tent parasystole at one time or another, showing a sudden and great variation of the interectopic intervals which could not be reduced to simple multiples of the SIEI.

El-Sherif and Samet<sup>4</sup> reported that when there were more than three concurrently discharging parasystolic foci existing in the ventricle, wide variations of the SIEIs were seen in records taken at different times. This finding together with our finding on double ventricular parasystole contrasts sharply with the experiences gained with single parasystole

TABLE 3. Effect of Atropine on Double Ventricular Parasystole

R1-R1 Interval		R2-R2 Interval	
Before	After	Before	After
136 (×2)	*144 (×3)	182 (×2)	184
139 (×6)	145	176 (×3)	179 (×3)
*145 (×5)	145	174 (×3)	184
136	145	182 (×2)	179
134 (×2)	139 (×6)	185	*179
134 (×2)	141	181	183
*146 (×2)	*144	181 (×2)	185 (×4)
140	144 (×7)	186 (×2)	184
138	*141 (×2)	186 (×2)	172 (×2)
138 (×4)	139	184 (×2)	*186
145 (×2)	137	177 (×3)	181 (×3)
138	140	180 (×2)	*185
139	144	184 (×2)	172 (×2)
141 (×6)		192 (×2)	*186 (×2)
138		189 (×2)	180 (×2)
133			*185
139 (×4)			
138 (×2)			

138.72 ± 3.69 142.15 ± 2.97 182.60 ± 4.64 181.50 ± 4.33

Following an intravenous injection of atropine, 1.0 mg, no changes were seen in the shortest interectopic intervals of both R1 and R2 parasystoles. Parentheses indicate shortest calculated interectopic intervals.

\*Fusion beats.

in which the discharging rate of the ectopic focus can often remain surprisingly stable for a prolonged period of time — five months in a case of Scherf and Boyd<sup>19</sup> and seven years in a case of Watanabe.<sup>15</sup>

Since multiple ventricular parasystoles arise most often in heavily drugged hearts with advanced pathology, those factors contributing to the fluctuation of the interectopic interval such as 1) changing discharge<sup>4, 14, 20</sup> rate, 2) irregular firing of the parasystolic focus,<sup>21</sup> 3) varying degrees of exit block and/or exit delay,<sup>14, 19, 22, 23</sup> and 4) conduction delay of the impulse penetrating into the parasystolic focus or a transient depression of the parasystolic focus,<sup>24</sup> should be more readily exhibited than in cases of single parasystoles. Furthermore, it is conceivable that coexistence of multiple ectopic foci *per se* would yield a delicate interectopic interaction which will not only contribute to the fluctuation of the interectopic interval but also might give rise to an intermittency such as the one seen in our case.

#### *Temporary Failure of the Entrance Block and Intermittence*

Both entrance block and exit block<sup>12, 25</sup> have long been the prerequisite in explaining parasystoles. The entrance block was postulated to be a complete block in one direction (unidirectional block)<sup>23, 26</sup> and the exit block a partial block in the other direction. Validity of this postulation was sufficiently confirmed by deductive analyses of electrocardiograms<sup>23</sup> and by basic experiments using the microelectrode technique.<sup>26, 27</sup>

At this juncture, however, one is reminded of an opposing concept elaborated by Scherf and associates<sup>17, 19</sup> regarding the mechanism of the protection. They refused to use the term “protection block” on the assumption that the phenomenon of protection could be understood without invoking a conduction disturbance in the tissues surrounding the parasystolic focus. We feel, however, that the two major concepts regarding the mechanism of “protection” are in reality two sides of one coin. Those who favor the term *protection* (Scherf, Schamroth and others)<sup>14, 28</sup> put emphasis on the electrophysiological properties (one aspect of the phenomenon), whereas those who favor the term *protection block* (Katz, Langendorf, Pick and others)<sup>12, 23, 24</sup> view the problem from the wider pathophysiological point of view (the other aspect of the same phenomenon). The experimental data derived from studies at the cellular level<sup>26, 27</sup> attested to the validity of both concepts and neither of the two views has disproved the other. In fact, in the light of present knowledge the arguments are now moot.

A finer mechanism of protection has recently been clarified by Cohen, Langendorf, and Pick.<sup>24</sup> According to these investigators the parasystolic center is protected from supraventricular and other ventricular ectopic impulses early in its cycle by its own refractoriness, and late in the cycle by diastolic depolarization. Between these two areas of protection a “period of susceptibility” exists during which supraventricular beats can penetrate, discharge, and reset the parasystolic focus. The latter sequence would be named intermittence by the ECG recordings. In their study, when both the early and the late protections were confirmed, the zone of susceptibility was limited to a short time interval of

approximately 30 msec early in the diastole. In all the six cases of intermittent parasystole studied by them the reason for intermittence was temporary failures of the entrance block which were effected by the supraventricular beats falling within the “zone of susceptibility”.

Steffens<sup>8</sup> who reported a case of intermittent ventricular parasystole due to entrance block failure has also shown that the reason for failure of the entrance block was a possible preferred penetration<sup>27</sup> of parasystolic focus by a sinus capture beat which occurred early in diastole.

In our case figure 3 indicated just such a relationship: the interrupting R1 occurred very early in the diastole of the preceding R2 at about the terminal portion of its T wave. An analysis of this relationship with long rhythm strips revealed that the interrupting R1s always occurred at a very short time (R2-R1 intervals of 0.38 to 0.42 sec) after the beginning of QRS complexes of the preceding R2s. We were therefore inclined to believe that the interrupting R1 occurred at the supernormal phase of the preceding R2 beats. The supernormality was then accounted for by temporary loss of the entrance block with subsequent discharge and resetting of R2. A similar relationship was also found with concealed R2-R1 intervals which served as further evidence in support of our view.

#### *Supernormality as a Mechanism of Intermittent Ventricular Parasystole*

Supernormality can elicit an unexpected response.<sup>29-33</sup> In our case, an unexpected response was manifested by a sudden prolongation of the R2-R2 interval, which was clearly related to an occurrence of R1 at the supernormal phase of R2 beat. Postulation of supernormality to account for penetration of parasystolic focus and resultant intermittence is not entirely new. Scherf and Boyd<sup>19</sup> postulated the supernormal phase of atrioventricular conduction to explain a sudden lengthening of the interectopic interval in their case of intermittent atrioventricular junctional parasystole. It should be noted, however, that in our case, both the interrupting R1 and the disturbed R2 were ventricular ectopic beats. Therefore the temporal relationship of R1 to R2 was as clear as it could be, and the effects of supernormal conduction as well as supernormal excitability within the ventricle could be directly taken into account without much postulation. When R1 occurred at the supernormal phase of R2 conduction in the area of protection block around the R2 focus must have improved momentarily. At the same time, the R2 focus must have been depolarized at its supernormal period during which R1 served as a premature beat. Such a depolarization is characterized by a nearly total action potential<sup>29, 30, 33</sup> with a steep upstroke (phase 0). The membrane potential at this point is closed to the resting level and therefore, the slow diastolic depolarization (phase 4) starts anew without alteration in its slope. Thus, the parasystolic focus was reset at the very moment of depolarization and the parasystolic escape interval was equal, or nearly so, to the parasystolic cycle length.<sup>8</sup> Had the interrupting R1 been a sinus beat, the concept of supernormality could not have been used as a cause of intermittence because the sinus beat can only reach the ventricle after an atrioventricular (A-V) delay. This is indeed an advantage of the concept of double

ventricular parasystole, as compared to single parasystole, in interpreting the finer mechanisms taking place at the ventricular level. In fact, one may speculate why an early sinus impulse in single parasystole never has the same discharging and resetting effect as does an extraneous ventricular impulse — probably the delay in A-V junction does not permit the sinus impulse to reach the parasystolic pacemaker early enough — and perhaps this is the reason why the phenomenon observed in double ventricular parasystole is unlikely to occur in single parasystole.

In Steffens' case,<sup>6</sup> which was actually a double ventricular parasystole (one artificial), the interrupting beat leading to an intermittency of spontaneous ventricular parasystole was a sinus capture beat. In his figure 2 one can further see that the P wave of the sinus capture beat occurred early in diastole — the period we found most likely to coincide with supernormal phase of the preceding spontaneous parasystolic beat. However, it was the ventricular activation (QRS) of the sinus capture beat that caused a temporary loss of the entrance block as well as depolarization of the parasystolic focus. Hence, it is obvious that the moment at which the entrance block was lost did not correspond with the supernormal phase of the preceding parasystolic beat. A measurement of the time interval between the interrupting QRS (sinus capture beat) and the preceding parasystolic beat was 0.76 second — an interval corresponding to the "zone of susceptibility" which was clarified by Cohen, Langendorf and Pick as a period during which supraventricular beats can discharge the parasystolic focus.<sup>24</sup> In a strict sense, therefore, our case appears to be the first report, as far as we could ascertain from the literature, that can possibly establish the effect of supernormal phase of conduction as one mechanism of intermittent ventricular parasystole.

### Effect of Drugs

In ventricular parasystole, anticholinergics or carotid sinus stimulations can at times alter the rhythm or abolish protective mechanisms<sup>14, 35, 36</sup> No such changes were observed in our case during atropine administration or vagal stimulation. On the other hand, the effect of lidocaine was of interest. The first i.v. bolus injection of lidocaine, 100 mg, suppressed the appearance of R2 completely and there was a marked decrease in the appearance of R1. A discharge rate of R1 also decreased from 45 beats/min to 35 beats/min one minute after the injection. In addition, a rather marked variation of R1-R1 interval as demonstrated by an increase of standard deviation (table 2) accompanied the above changes. These changes were observed up to seven to ten minutes after the bolus injection, but once the i.v. drip infusion in the usual manner was established almost all the features of the pre-lidocaine stage were restored. The R2, after its reappearance, showed a slight increase in the discharging rate which was coincident with a slight increase of sinus rate. Implicit in these findings are 1) a therapeutic dose of lidocaine exhibited a depressant effect on parasystolic activities, 2) such a depressant effect was only confirmed during a short period of time after the injection, that is, when the plasma concentration of lidocaine was over 30 µg/ml (initial high plasma lidocaine level),<sup>36, 37</sup> but disappeared by

the time when the i.v. drip infusion was established (plasma concentration of lidocaine in a range of 2–5 µg/ml),<sup>38, 39</sup> and 3) one may therefore state that the depressant effect of lidocaine was concentration-dependent.

It appears that lidocaine exhibited a direct depressant effect<sup>38</sup> on parasystolic pacemakers. Although a concomitant effect on the conductivity of the myocardium surrounding the ectopic foci (increased degree of exit block) cannot be excluded, it was unlikely in our case since there had been no indication of exit block with the R2 throughout the period of observation.

Obviously, the R1 focus was more resistant to lidocaine than the R2. We believe that the R1 had been more stable than the R2 from the very outset. Probably, the R1 had been primarily better protected than the R2 or an idioventricular ectopic focus with a slow discharging rate such as R2 had been destined to be unstable.<sup>27</sup>

### Clinical Implication

Double or multiple ventricular parasystole is said to be usually associated with advanced organic heart disease.<sup>1, 2, 4, 16</sup> Our case also presented with a severe congestive heart failure throughout the period when double ventricular parasystole was manifest.

Because of the concurrent discharges of two or more independent ventricular ectopic pacemakers, the occurrence of dangerous ventricular arrhythmias is a theoretical possibility. The repeated occurrence of ventricular fibrillation as a result of the use of two artificial cardiac pacemakers gives us a serious warning.<sup>11</sup> In reality, however, there are now at least three survived cases,<sup>1, 3</sup> including the case presented here, in which no ventricular fibrillation was documented. Furthermore, El-Sherif and Samet observed no electrical death in their six patients with multiple ventricular parasystole.<sup>4</sup> These patients all succumbed to intractable congestive heart failure or cardiogenic shock. Perhaps by accumulation of more cases we will be able to testify whether or not an electrical death can occur in patients with multiple ventricular parasystole.

### Acknowledgment

The most valuable comments of Yoshio Watanabe, M.D., are greatly acknowledged.

### References

1. Chung EK, Walsh TJ, Massie E: Double ventricular parasystole. *Am Heart J* 67: 162, 1964
2. Chung EK: Principles of Cardiac Arrhythmias. Baltimore, Williams & Wilkins Co, 1971
3. Roelandt J, Pool J, Schamroth L: Double-bifocal ventricular parasystole. *J Electrocardiol* 5(1): 86, 1972
4. El-Sherif N, Samet P: Multiform ventricular rhythm — Evidence for multiple parasystolic activity. *Circulation* 51: 492, 1975
5. McDonald CD: Ventricular parasystole following implantation of an electronic pacemaker unit. *Chest* 57: 202, 1970
6. Steffens TG: Intermittent ventricular parasystole due to entrance block failure. *Circulation* 44: 442, 1971
7. El-Sherif N, Mascarenhas E, Zaron S, Samet P: Ventricular parasystolic rhythm masquerading as bilateral bundle branch block. *J Electrocardiol* 6(2): 171, 1973
8. Harris RSJ, Becker DJ, Rodensky PL, Wolcott MW, Dick MM, Wasserman F: Symptomatic paroxysmal pacemaker-induced ventricular tachycardia. *Am J Cardiol* 11: 403, 1963
9. Castellanos A, Lemberg L, Gosslin A: Double artificial ventricular parasystole. *Cardiologia* 47: 273, 1965



10. Langendorf R, Pick A: Parasystole with fixed coupling. *Circulation* 33: 304, 1967
11. Robinson DS, Falsetti HL, Wheeler DH, Miller DB, Amidon EL: Ventricular fibrillation associated with two functioning implanted cardiac pacemakers. *Am J Cardiol* 15: 397, 1965
12. Katz LN, Pick A: Clinical Electrocardiography. Part I: The Arrhythmias. Philadelphia, Lea & Febiger, 1956
13. Scherf D, Choi KH, Bahadori A: Parasystole. *Am J Cardiol* 12: 527, 1963
14. Schamroth L: The Disorders of Cardiac Rhythm. Oxford and Edinburgh, Blackwell Scientific Publications, 1971
15. Watanabe Y: Reassessment of parasystole. *Am Heart J* 81: 451, 1971
16. Chung EKY: Parasystole. *Prog Cardiovasc Dis* 11: 64, 1968
17. Scherf D, Schott A: Extrasystoles and Allied Arrhythmias. New York, Grune & Stratton, 1953
18. Langendorf R, Pick A: Mechanism of intermittent ventricular bigeminy; II. Parasystole, and Parasystole or reentry with conduction disturbance. *Circulation* 11: 431, 1955
19. Scherf D, Boyd LJ: Three unusual cases of parasystole. *Am Heart J* 39: 650, 1950
20. Scherf D, Schott E, Reid EC, Chamsai DG: Intermittent parasystole. *Cardiologia* 30: 217, 1957
21. Lazzara R, El-Sherif N, Scherlag BJ: Electrophysiological properties of canine Purkinje cells in one-day-old myocardial infarction. *Circ Res* 33: 722, 1973
22. Greenspan K, Anderson GJ, Fisch C: Electrophysiologic correlate of exit block. *Am J Cardiol* 28: 197, 1971
23. Pick A: Parasystole. *Circulation* 8: 243, 1953
24. Cohen H, Langendorf R, Pick A: Intermittent parasystole — Mechanism of protection. *Circulation* 48: 761, 1973
25. Kaufman R, Rothberger CJ: Beitrage zur Kenntniss der Entstehungsweise extrasystolischer Allorhythmien IV. *Z Ges Exp Med* 11: 40, 1920
26. Craneffeld PF, Klein HO, Hoffman BF: Conduction of the cardiac impulse. 1. Delay, block, and one way block in depressed Purkinje fibers. *Circ Res* 28: 199, 1971
27. Singer DH, Lazzara R, Hoffman BF: Interrelationships between automaticity and conduction in Purkinje fibers. *Circ Res* 21: 537, 1967
28. Schamroth L, Marriott HJL: Intermittent ventricular parasystole with observations on its relationship to extrasystolic bigeminy. *Am J Cardiol* 7: 799, 1961
29. McC Brooks C, Hoffman BF, Sucking EE, Oscar O: Excitability of the Heart. New York and London, Grune & Stratton, 1955
30. Hoffman BF, Craneffeld PF: Electrophysiology of the Heart. New York, Toronto & London, McGraw-Hill Book Co. Inc., 1960
31. Pick A, Langendorf R, Katz LN: The supernormal phase of atrio-ventricular conduction I. Fundamental mechanism. *Circulation* 26: 388, 1962
32. Massumi RA, Amsterdam EA, Mason DT: Phenomenon of supernormality in the human heart. *Circulation* 46: 264, 1972
33. Singer DH, Ten Eick RE: Aberrancy; Electrophysiologic aspects. Symposium on electrophysiologic correlates of clinical arrhythmias Part II. *Am J Cardiol* 28: 381, 1971
34. Scherf D, Boyd LG: Clinical Electrocardiography. Philadelphia, JB Lippincott, 1964
35. Mueller P, Baron B: Clinical studies on parasystole. *Am Heart J* 45: 441, 1953
36. Bigger JT Jr, Heissenbuttel RH: The use of procaine amide and lidocaine in the treatment of cardiac arrhythmias. In *Current Status of Drugs in Cardiovascular Disease*, edited by Friedberg, CK. New York, Grune & Stratton, 1969
37. Berowitz N, Forsyth RP, Melmon KL, Rowland M: Lidocaine disposition kinetics in monkey and man I. Prediction by a perfusion model. *Clin Pharmacol Ther* 16: 87, 1974
38. Rosen MR, Hoffman BF, Wit AL: Electrophysiology and pharmacology of cardiac arrhythmias. V. Cardiac antiarrhythmic effects of lidocaine. *Am Heart J* 89: 526, 1975

## Membranous Subaortic Stenosis Complicated by Aneurysm of the Membranous Septum and Mitral Valve Prolapse

CHRISTOPHER C. CAUDILL, M.D., STEVEN K. KRUEGER, B.S., CHARLES S. WILSON, M.D.,  
TERRY ROURKE, DAVID B. POLICKY, M.D., AND WALT F. WEAVER, M.D.

**SUMMARY** The clinical, echocardiographic, and catheterization findings in a patient with discrete subaortic stenosis, aneurysm of the membranous interventricular septum, and mitral valve prolapse are presented. Echocardiography showed a subaortic membrane, abnormal

aortic valve motion, accentuated systolic anterior motion of the membranous interventricular septum, and prolapsing mitral leaflets. Cardiac catheterization confirmed the diagnoses. The possible functional interrelationship of these lesions is discussed.

**DISCRETE MEMBRANOUS SUBAORTIC STENOSIS** is a rare cause of left ventricular outflow obstruction which may coexist with other congenital lesions such as membranous ventricular septal defect.<sup>1, 2</sup> A membranous ventricular septal defect may close spontaneously leaving a residual aneurysm of the membranous septum.<sup>3</sup> An association between discrete subaortic stenosis and aneurysm of the membranous septum therefore would not be surprising, and this association has been reported.<sup>4</sup> Further, an association between left ventricular outflow tract obstruction and

anomalies of the mitral valve is recognized, resulting either from the bulging of accessory valvular tissue into the left ventricular effluent or from the abnormal insertion of a normal or cleft mitral leaflet to the interventricular septum causing narrowing of the left ventricular outflow tract.<sup>5, 6</sup> In these instances, however, a discrete fibrous membrane would be absent.

The echocardiographic features of discrete subaortic stenosis are narrowing of the left ventricular outflow tract with premature systolic closure and systolic fluttering of the aortic valve cusps;<sup>7, 8</sup> echocardiographic recording of the subaortic membrane has also been reported.<sup>8, 9</sup> Demonstration of an aneurysm of the membranous septum by echocardiogram has likewise been reported, showing accentuated systolic anterior motion of the membranous septum.<sup>10</sup> This report describes the clinical, echocardiographic, and

From Bryan Memorial Hospital, Lincoln, Nebraska.  
Dr. Krueger's present address is University of Nebraska Medical Center, Omaha, Nebraska.

Address for reprints: C. C. Caudill, M.D., 1512 First National Bank Building, Lincoln, Nebraska 68508.

Received September 2, 1975; revision accepted for publication October 8, 1975.