

- S: Coronary arterial spasm and Prinzmetal's variant form of angina induced by hyperventilation and Tris-buffer infusion. *Circulation* 58: 56, 1978
27. Somlyo AP, Somlyo AV: Vascular smooth muscle. II. Pharmacology of normal and hypertensive vessels. *Pharmacol Rev* 22: 249, 1970
28. Bohr DF: Vascular smooth muscle updated. *Circ Res* 32: 665, 1973
29. van Breemen C, Farinas BR, Gerba P, McNaughton ED: Excitation-contraction coupling in rabbit aorta studied by the lanthanum method for measuring cellular calcium influx. *Circ Res* 30: 44, 1972
30. Mrwa U, Achtig I, Rüegg JC: Influences of calcium concentration and pH on the tension development and ATPase activity of the arterial actomyosin contractile system. *Blood Vessels* 11: 277, 1974

## Coronary Arterial Spasm as a Cause of Exercise-Induced ST-Segment Elevation in Patients with Variant Angina

GIUSEPPE SPECCHIA, M.D., STEFANO DE SERVI, M.D., COLOMBA FALCONE, M.D.,

EZIO BRAMUCCI, M.D., LUIGI ANGOLI, M.D., ANTONIO MUSSINI, M.D.,

G. PIERO MARINONI, M.D., CARLO MONTEMARTINI, M.D., AND PIERO BOBBA, M.D.

**SUMMARY** Four patients with variant angina pectoris exhibited reproducible exercise-induced chest pain and ST-segment elevation. Coronary arterial spasm was documented with arteriography during exercise-induced ST-segment elevation (three patients) or after intravenous administration of ergonovine maleate (one patient). Our observations show that in patients with variant angina exercise can trigger coronary arterial spasm, thus inducing anginal pain and ST-segment elevation.

**EXERCISE-INDUCED ST-segment elevation** is an abnormal response which appears in association with ventricular aneurysm,<sup>1, 2</sup> severe ischemic heart disease<sup>3, 4</sup> or variant angina.<sup>5-10</sup> In the variant form of angina pectoris<sup>11</sup> the role of coronary artery spasm is well established,<sup>5, 10, 12-16</sup> but it is not yet clear whether it may also play a role in exercise-induced angina and ST-segment elevation. In this paper we present four patients with spontaneous and exercise-induced ST-segment elevation. In these patients we demonstrated that spasm was the pathogenetic mechanism of exercise-induced angina and related electrocardiographic changes.

### Subjects and Methods

Four patients suffering from variant angina and no previous myocardial infarction had exercise-induced ST-segment elevation. The clinical history and the results of the exercise test and coronary angiography are briefly described (see Case Report section). The patients were asked to perform a multistage bicycle exercise test in the supine position with an initial work load of 50 watts and subsequent increments of 25 watts every 3 minutes. A 12-lead ECG was obtained

before and at termination of the exercise and at each minute during recovery. Leads V<sub>4</sub>, V<sub>5</sub>, V<sub>6</sub> were monitored during exercise and recorded on paper every 30 seconds. The patients were exercised to symptomatic end points: typical anginal pain, dyspnea or exhaustion. After premedication with 10 mg of diazepam, coronary arteriography was performed using the method of Sones. In three patients (cases 2, 3 and 4) the exercise test was repeated in the same way during coronary arteriography and arteriograms were obtained during pain and electrocardiographic changes. In the remaining patient (case 1) 0.2 mg of ergonovine maleate<sup>17-22</sup> was administered intravenously at 0.05 mg/min.<sup>19-21</sup> In this patient coronary arteriograms were also obtained during ergonovine-evoked chest pain. In all cases nitroglycerin, administered sublingually, relieved the pain within 3 minutes. Drug therapy was stopped 12 hours before angiography and exercise tests. No patient was receiving  $\beta$ -blocking drugs. Informed consent was obtained from each patient before the study. The procedures did not result in any complications.

### Case Reports

#### Case 1

A 51-year-old man presented with a 6-month history of spontaneous anginal attacks that occurred about once a month. He reported only one episode of chest pain during effort. The admitting physical examination was negative. The blood pressure was 130/80 mm Hg; the pulse rate was 76 beats/min and

From the Cattedra di Fisiopatologia Cardiorespiratoria dell'Università, Divisione di Cardiologia, Policlinico S. Matteo, Pavia, Italy.

Address for reprints: Stefano de Servi, M.D., Divisione di Cardiologia, Policlinico S. Matteo, 27100 Pavia, Italy.

Received July 31, 1978; accepted January 20, 1979.

*Circulation* 59, No. 5, 1979.

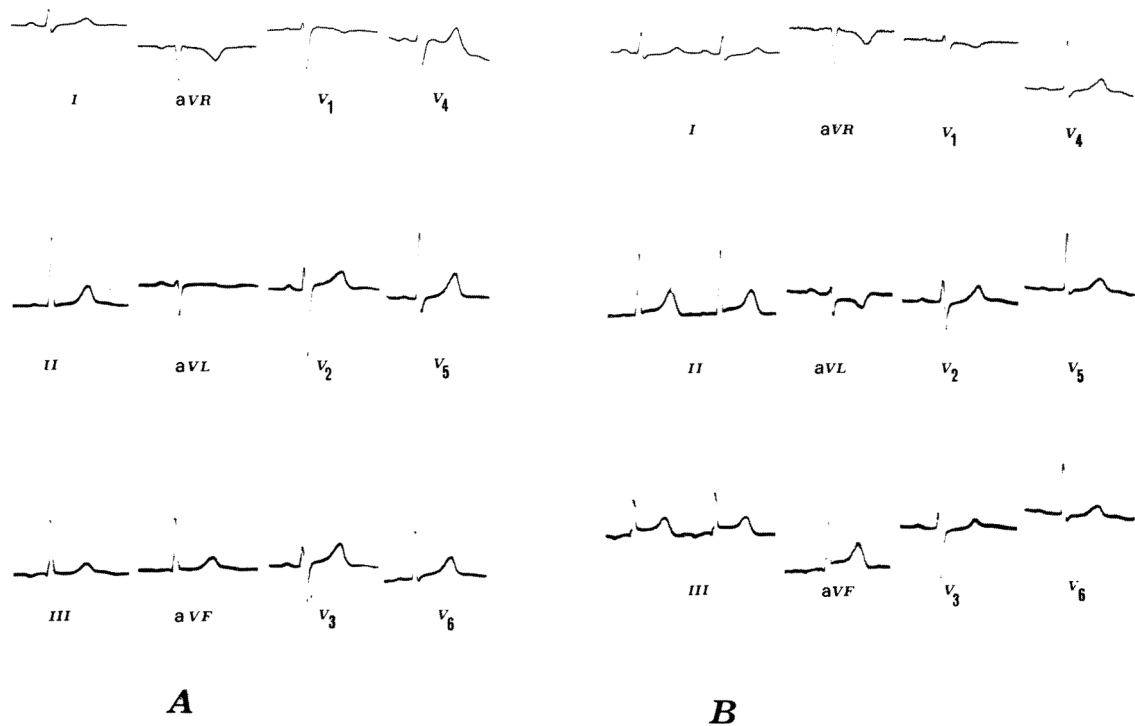


FIGURE 1. Case 1. A) Resting ECG is normal. B) One minute after termination of exercise, the ECG shows ST-segment elevation in leads II, III, aV<sub>F</sub>. C) The right coronary arteriogram after nitroglycerin shows only a mild stenosis in the midportion of the right coronary artery (arrow). D) Right coronary artery during ergonovine-induced pain and ST-segment elevation. Complete occlusion of the proximal right coronary artery is present.

regular. A resting ECG was normal. ECGs during the attacks of pain showed ST-segment elevation in leads II, III, aV<sub>F</sub>. The exercise test was interrupted at 150 W because of exhaustion (heart rate 149 beats/min). One minute later ST-segment elevation was observed in leads II, III, aV<sub>F</sub> without anginal pain. A second exercise test 3 days later revealed the same results. Coronary arteriography showed a normal left coronary artery and a minor atherosclerotic change

(30%) of the right coronary artery. Left ventriculogram did not reveal disorders of myocardial contractility. Intravenous administration of 0.2 mg of ergonovine maleate induced a vasospastic occlusion of the right coronary artery at the site of the minor stenosis, associated with ST-segment elevation in leads II, III and aV<sub>F</sub>. The ergonovine-induced spasm was reversed with sublingual administration of nitroglycerin (fig. 1).

### Case 2

A 43-year-old man complained of spontaneous substernal pain for 1 month. The anginal attacks were also related to exertion. The physical examination was negative. The blood pressure was 130/80 mm Hg. The heart rate was 64 beats/min, with regular rhythm. His ECG on admission was normal. ECGs during the anginal attacks showed ST-segment elevation in leads II, III, aV<sub>F</sub>. Similar episodes of ST-segment elevation unaccompanied by pain were also noted. The exercise test was interrupted at 150 W (heart rate 130 beats/min) for anginal pain and ST-segment elevation was recorded in leads II, III, aV<sub>F</sub>. Reciprocal ST-segment depression was noted from V<sub>2</sub> to V<sub>6</sub>. A second exercise test performed a few days later gave the same result. A third exercise test after sublingual nitroglycerin was negative. Selective coronary arteriography revealed a normal left coronary artery and 30% stenosis in the midsegment of the right coronary artery. Left ventriculogram revealed normal ventricular contractility. Coronary arteriogram recorded during the attack induced by exercise test showed two severe narrowings of the mid-right coronary artery. After taking sublingual nitroglycerin, chest pain subsided and the spasm was reversed (fig. 2).

### Case 3

A 45-year-old man had substernal pain that occurred at rest for a period of 1 year. He also mentioned a few episodes of exertional chest pain. The admitting physical examination revealed a blood pressure of 110/70 mm Hg and a pulse of 56. His ECG on admission was normal. ECGs taken during the spontaneous attacks revealed ST-segment elevation in leads II, III, aV<sub>F</sub>. A few episodes of painless attacks of ischemia with ST-segment elevation in the same leads were recorded. The exercise test was interrupted at 125 W because of exhaustion (heart rate 145 beats/min). Thirty seconds later the patient had minor chest discomfort accompanied by ST-segment elevation in leads II, III and aV<sub>F</sub>, with reciprocal ST-segment depression in V<sub>1</sub> to V<sub>6</sub>. Occasional premature beats were also noted. A second exercise test performed a few days later induced the same electrocardiographic changes. Coronary arteriography revealed a low-grade stenosis (50%) of the midportion of the right coronary artery and of the left anterior descending artery. Left ventriculogram showed normal myocardial contractility. Repeat angiograms taken when electrocardiographic changes induced by exercise test were present (ST-segment elevation in leads II, III and aV<sub>F</sub>) showed coronary arterial spasm occluding about 90% of cross-sectional diameter of the mid-right coronary artery. These alterations were rapidly reversed with the sublingual administration of nitroglycerin (fig. 3).

### Case 4

A 46-year-old man suffered from spontaneous at-

tacks of chest pain occurring when he awoke in the morning or when he was relaxing at night for a period of 1 week. He did not mention episodes of exertional chest pain. Physical examination revealed a blood pressure of 120/70 mm Hg. The heart rate was 68 beats/min, with regular rhythm; there were no abnormal cardiac findings. His ECG on admission was normal. During the spontaneous episodes the ECG showed ST-segment elevation from V<sub>2</sub> to V<sub>6</sub>. Episodes of ischemia unaccompanied by pain were also noted. The exercise test was interrupted at 150 W because of chest pain (heart rate 144 beats/min) and ST-segment elevation was observed in leads V<sub>2</sub> to V<sub>6</sub>. A second exercise test performed 3 days later caused the same electrocardiographic changes. Cinecoronary arteriography revealed a significant narrowing (75%) of the left anterior descending artery and a normal right coronary artery. Left ventriculogram showed normal myocardial contractility. Coronary arteriograms during exercise-induced pain with ST elevation in leads V<sub>2</sub> to V<sub>6</sub> revealed more severe narrowing (99%) of the left anterior descending artery with slow progression of the contrast medium and distal occlusion of the artery. The pain was relieved and the spasm subsided immediately after sublingual nitroglycerin (fig. 4).

### Discussion

The ST-segment elevation during the pain of variant angina has been observed to occur at rest<sup>5, 11</sup> and, less frequently, during effort.<sup>3, 4</sup> In 1972 we reported four cases of exercise-induced ST-segment elevation.<sup>4</sup> In those patients coronary arteriography revealed a high-grade stenosis in the artery supplying the area of the myocardium expected to be ischemic by the electrocardiographic alterations during effort. Severe atherosclerotic changes of the coronary arteries were also found by Fortuin and Friesinger<sup>8</sup> in 11 out of 12 patients in whom this abnormality was observed. Most of those patients did not present spontaneous attacks of pain associated with ST-segment elevation. This electrocardiographic abnormality triggered by exercise was regarded as a characteristic feature of severe ischemic heart disease. However, in the variant form of angina pectoris exercise-induced ST-segment elevation has been reported in patients with and in those without coronary atherosclerosis.<sup>6-10</sup> It is well-known that coronary arterial spasm is primarily responsible for the spontaneous attacks of pain associated with ST-segment elevation,<sup>5, 10, 12-16</sup> but it is not clear whether it can account for the electrocardiographic abnormality provoked by exercise.

In our patients exercise-induced ST-segment elevation occurred during (cases 2 and 4) or just after the exercise period (cases 1 and 3). In any case, our patients exhibited ST elevation repeatedly on subsequent exercise tests, demonstrating that the phenomenon was reproducible. In three patients we could perform coronary arteriography during electrocardiographic changes induced by the exercise test. In all cases we demonstrated a vasospastic occlusion of the lumen of a major coronary artery. We believe this is




FIGURE 2. Case 2. A) Resting ECG is normal. B) At the end of exercise, interrupted because of chest pain, ST-segment elevation is present in leads II, III, aVF. C) Control right coronary arteriogram. A mild stenosis is present in the midportion of the right coronary artery. D) During exercise-induced chest pain and ST-segment elevation two severe obstructions of the mid-right coronary artery are visible (arrows).

the first report directly demonstrating that coronary arterial spasm can be provoked by dynamic exercise. In the remaining patient ergonovine maleate evoked chest pain associated with ST-segment elevation, and angiography revealed a coronary arterial spasm com-

pletely occluding the right coronary artery. Since this patient had no significant fixed coronary lesions we suggest that exercise-induced electrocardiographic abnormalities imply the same pathogenetic mechanism. A similar case of variant angina pectoris with

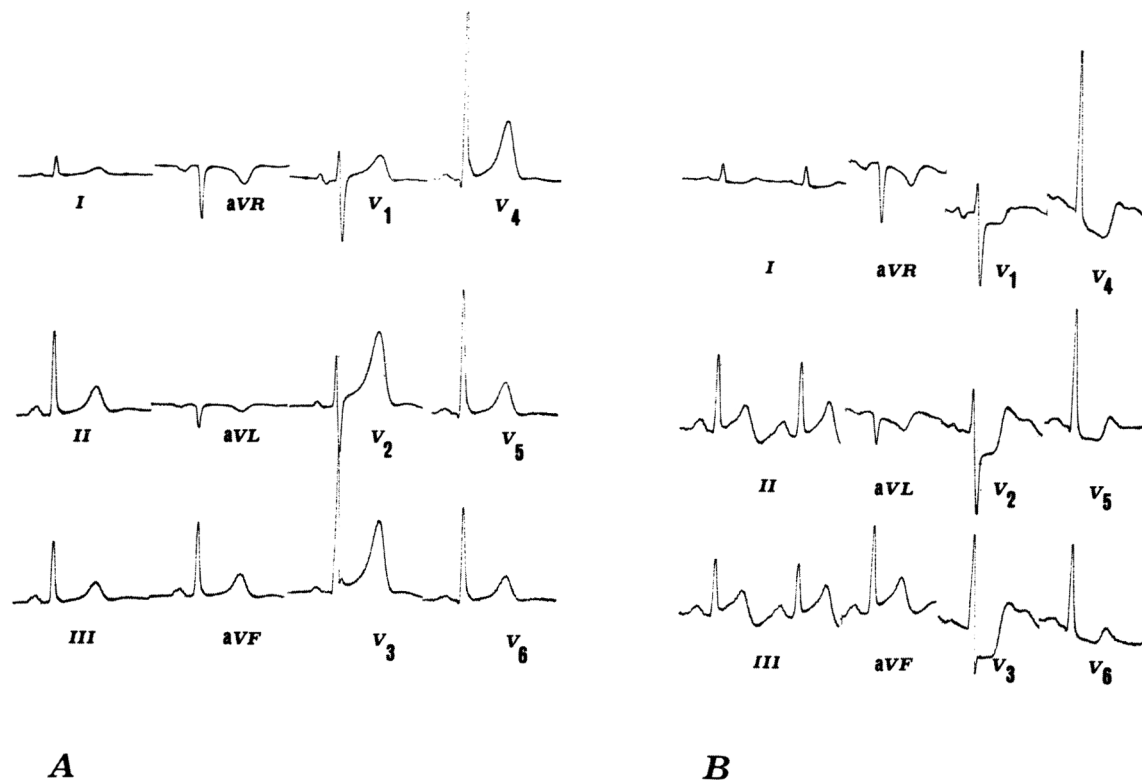


FIGURE 3. Case 3. A) ECG recorded at rest. B) Thirty seconds after termination of exercise, ST-segment elevation is present in leads II, III, aV<sub>F</sub> with reciprocal ST depression from V<sub>1</sub> to V<sub>6</sub>. C) Right coronary arteriogram with patient at rest and pain free shows only a mild stenosis (arrow) in the midportion of the right coronary artery. D) During exercise-induced ST-segment elevation, a 90% stenosis of the mid-right coronary artery is visible (arrow).

reproducible chest pain and ST-segment elevation in the immediate postexercise period in a patient with normal coronary arteries has been recently reported by McLaughlin et al.<sup>23</sup> These authors documented a coronary arterial spasm occluding approximately 60% of the lumen of the right coronary artery after in-

travenous administration of ergonovine maleate.

It is well established that coronary arterial spasm is the underlying pathogenetic mechanism of spontaneous chest pain and electrocardiographic changes in most of the patients with variant angina.<sup>5, 12-16</sup> Our observations show that in patients with this syndrome

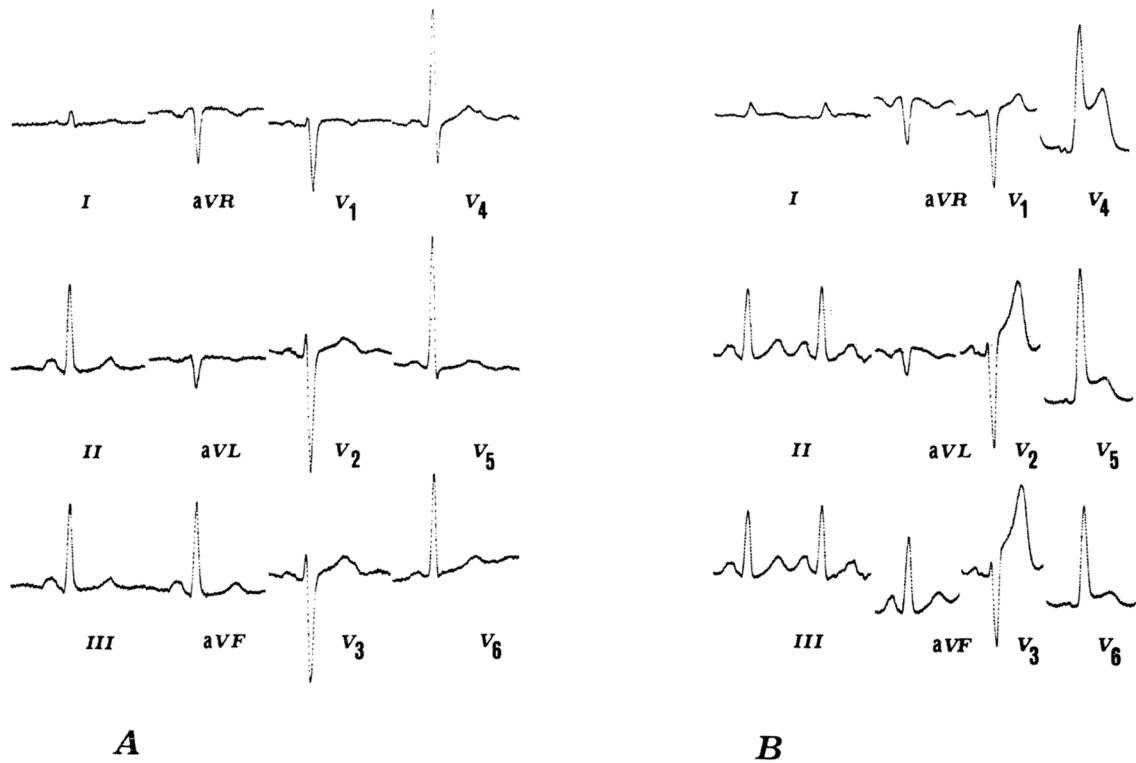


FIGURE 4. Case 4. A) ECG recorded at rest. B) At the end of exercise, interrupted because of chest pain, ST elevation is recorded from  $V_2$  to  $V_6$ . C) Left coronary arteriogram performed when pain and electrocardiographic abnormalities are absent, shows a left anterior descending artery filling rapidly and completely. A significant stenosis is present just past the origin of a diagonal branch (arrow). D) Left coronary arteriography performed during pain and ST changes shows a severe obstruction of the left anterior descending artery at the point of the organic stenosis (arrow). The vessel beyond the obstruction fills very slowly and only to the point indicated by the bottom arrow.

exercise can trigger a coronary arterial spasm thus inducing anginal pain and ST-segment elevation.

The mechanism whereby coronary arterial spasm is involved in the response to exercise is not clear. An ab-

normal reflex response in patients with altered activity of the autonomic nervous system<sup>14</sup> could be postulated; or spasm could result from direct effect of circulating metabolic factors.<sup>23</sup>



## References

1. Gorlin R, Klein MD, Sullivan JM: Prospective correlative study of ventricular aneurysm: mechanistic concept and clinical recognition. *Am J Med* 42: 512, 1967
2. Chahine RA, Raizner AE, Ishimori T: The clinical significance of exercise-induced ST-segment elevation. *Circulation* 54: 209, 1976
3. Fortuin NJ, Friesinger GC: Exercise-induced ST segment elevation. Clinical, electrocardiographic and arteriographic studies in twelve patients. *Am J Med* 49: 459, 1970
4. Bobba P, Vecchio C, Di Guglielmo L, Salerno J, Casari A, Montemartini C: Exercise-induced RS-T segment elevation. Electrocardiographic and angiographic observations. *Cardiology* 57: 162, 1972
5. MacAlpin RN, Kattus AA, Alvaro AG: Angina pectoris at rest with preservation of exercise capacity. Prinzmetal's variant angina. *Circulation* 47: 946, 1973
6. Detry JMR, Mengeot P, Rousseau MF, Cosyns J, Ponlot R, Brasseur LA: Maximal exercise testing in patients with spontaneous angina pectoris associated with transient ST segment elevation. Risks and electrocardiographic findings. *Br Heart J* 37: 897, 1975
7. Robinson JS: Prinzmetal's variant angina pectoris. Report of a case. *Am Heart J* 70: 797, 1965
8. Silverman ME, Flamm MD: Variant angina pectoris. Anatomic findings and prognostic implications. *Ann Intern Med* 75: 339, 1971
9. Cosby RS, Giddings JA, See JR, Mayo M: Variant angina. Case reports and critique. *Am J Med* 53: 739, 1972
10. Cheng TO, Bashour T, Kelser GA, Weiss L, Bacos J: Variant angina of Prinzmetal with normal coronary arteriograms. A variant of the variant. *Circulation* 47: 476, 1973
11. Prinzmetal M, Kenamer R, Merliss R, Wada T, Bor N: Angina pectoris I — a variant form of angina pectoris. Preliminary report. *Am J Med* 27: 375, 1959
12. Maseri A, Mimmo R, Chierchia S, Marchesi C, Pesola A, L'Abbate A: Coronary artery spasm as a cause of acute myocardial ischemia in man. *Chest* 68: 625, 1975
13. Higgins CB, Wexler L, Silverman JF, Schroeder JS: Clinical and arteriographic features of Prinzmetal's variant angina: documentation of etiologic factors. *Am J Cardiol* 37: 831, 1976
14. Yasue H, Touyama M, Shimamoto M, Kato H, Tanaka S, Akiyama F: Role of autonomic nervous system in the pathogenesis of Prinzmetal's variant form of angina. *Circulation* 50: 534, 1974
15. Maseri A, Parodi O, Severi S, Pesola A: Transient transmural reduction of myocardial blood flow, demonstrated by thallium-201 scintigraphy, as a cause of variant angina. *Circulation* 54: 280, 1976
16. Wiener L, Kasparian H, Duca P, Walinsky P, Gotblid RS, Hankel F, Brest AN: Spectrum of coronary arterial spasm. Clinical, angiographic and myocardial metabolic experience in 29 cases. *Am J Cardiol* 38: 945, 1976
17. Heupler F, Proudfit W, Siegel W, Shirey E, Razavi M, Sones FM: The ergonovine maleate test for the diagnosis of coronary arterial spasm. (abstr) *Circulation* 52 (suppl II): II-11, 1975
18. Schroeder JS, Bolen JL, Quint RA, Clark DA, Hayden WG, Higgins CB, Wexler L: Provocation of coronary spasm with ergonovine maleate. New test with results in 57 patients undergoing coronary arteriography. *Am J Cardiol* 40: 487, 1977
19. Specchia G, Angoli L, De Servi S, Bramucci E, Mussini A, Marinoni GP, Ray M, Montemartini C, Di Guglielmo L, Bobba P: Spasmo coronarico indotto dalla somministrazione di ergonovina maleato in soggetti affetti da angina spontanea. *G Ital Cardiol* 6: 1177, 1976
20. Specchia G, Bramucci E, Angoli L, De Servi S, Mussini A, Marinoni GP, Ray M, Bobba P: Spontaneous and provoked coronary artery spasm: are they the same? *Eur J Cardiol* 8/6: 581, 1978
21. Tavazzi L, Salerno JA, Ray M, Specchia G, Chimienti M, Angoli L, De Servi S, Mussini A, Bobba P: Acute myocardial ischemia induced by ergonovine maleate in patients with "primary" angina. In *Primary and Secondary Angina Pectoris*, edited by Maseri A, Klassen GA, Lesh M. New York, Grune & Stratton Inc, 1978, pp 247-263
22. Heupler FA Jr, Proudfit WL, Razavi M, Shirey EK, Greenstreet R, Sheldon WC: Ergonovine maleate provocative test for coronary arterial spasm. *Am J Cardiol* 41: 631, 1978
23. McLaughlin PR, Doherty PW, Martin RP, Goris ML, Harrison DC: Myocardial imaging in a patient with reproducible variant angina. *Am J Cardiol* 39: 127, 1977