

# Remote-Controlled Magnetic Pulmonary Vein Isolation Using a New Irrigated-Tip Catheter in Patients With Atrial Fibrillation

K.R. Julian Chun, MD; Erik Wissner, MD; Buelent Koektuerk, MD; Melanie Konstantinidou, MD; Boris Schmidt, MD; Thomas Zerm, MD; Andreas Metzner, MD; Roland Tilz, MD; Sigrid Boczor, BS; Alexander Fuernkranz, MD; Feifan Ouyang, MD; Karl-Heinz Kuck, MD, PHD

**Background**—Lack of an irrigated-tip magnetic catheter has limited the role of remote-controlled magnetic navigation (Niobe II, Stereotaxis) for catheter ablation of atrial fibrillation (AF).

**Methods and Results**—A novel 3.5-mm-tip irrigated magnetic catheter (group 1, Thermocool Navistar RMT, Biosense Webster) was used for 3D left atrial reconstruction (CARTO RMT) and remote-controlled magnetic pulmonary vein isolation. A redesigned catheter was used in group 2. The primary end point was wide area circumferential pulmonary vein isolation confirmed by spiral catheter recording during ablation; secondary end points included procedural data, complications, and AF recurrence. Fifty-six consecutive patients [group 1: 28 patients, 22 males, age 64 (38 to 78) years, left atrium: 47 (34 to 52) mm; paroxysmal AF: n=21, persistent AF: n=7; group 2: 28 patients, 20 males, age 60 (24 to 78) years, left atrium: 40 (35 to 53) mm; paroxysmal AF: n=18, persistent AF: n=10] were included. The primary end point was achieved in a total of 52 of 56 (93%) patients. Median procedure duration was 315 (125 to 550) minutes (group 1: 370 [230 to 550] minutes; group 2: 243 [125 to 450] minutes). Median fluoroscopy exposure to the investigator was reduced by 31%. Tip charring in 17 of 28 (61%) and complications in 3 of 28 (11%) patients in group 1 resulted in a catheter redesign. Sinus rhythm was maintained by 35 of 50 (70%) patients during a median follow-up period of 545 (100 to 683) days.

**Conclusions**—Remote-controlled magnetic AF ablation with real-time verification of pulmonary vein isolation is feasible with a comparable success rate to manual ablation. Safety improved after a redesign of the catheter. (*Circ Arrhythm Electrophysiol.* 2010;3:458-464.)

**Key Words:** atrial fibrillation ■ catheter ablation ■ pulmonary vein isolation ■ magnetic navigation

Catheter ablation using radiofrequency current (RFC) has become a successful treatment option for drug-refractory atrial fibrillation (AF) and is considered a second-line treatment option according to recent (ACC/AHA/ESC) guidelines.<sup>1,2-4</sup> Successful AF ablation relies on reproducible catheter positioning, access to all target regions and stable local catheter contact within a complex 3D left atrial (3D LA) anatomy. This is of particular importance if pulmonary vein isolation (PVI) serves as procedural end point. The magnetic navigation system (MNS) Niobe II (Stereotaxis, St Louis, Mo) allows safe navigation and ablation within the human heart using a solid-tip catheter.<sup>5,6</sup> Recently, a novel open-irrigated, magnetic catheter (Thermocool, Biosense Webster, Diamond Bar, Calif) was approved in Europe for catheter ablation of AF. This study reports on our results of PVI using a novel open-irrigated magnetic catheter in conjunction with the MNS Niobe II.

## Clinical Perspective on p 464

### Methods

#### Patient Selection

Patients with a history of highly symptomatic paroxysmal ( $\geq 1$  episode/wk) or persistent AF despite antiarrhythmic drug treatment with  $\geq 1$  agent were analyzed in this study.

Patients treated in group 1 (Thermocool Navistar RMT, Biosense Webster) were ablated between November 9, 2007, and February 2, 2008, and patients in group 2 underwent ablation between September 12, 2008, and August 31, 2009. Exclusion criteria were an LA diameter  $\geq 55$  mm, severe left ventricular hypertrophy (wall thickness  $\geq 15$  mm), LA thrombus, and prior stroke or decompensated congestive heart failure.

All patients underwent transesophageal echocardiography before ablation to rule out LA thrombus. No additional preprocedural imaging such as MRI or CT was performed.

Received February 3, 2010; accepted June 3, 2010.

From the Department of Cardiology, Asklepios Klinik St Georg, Hamburg, Germany.

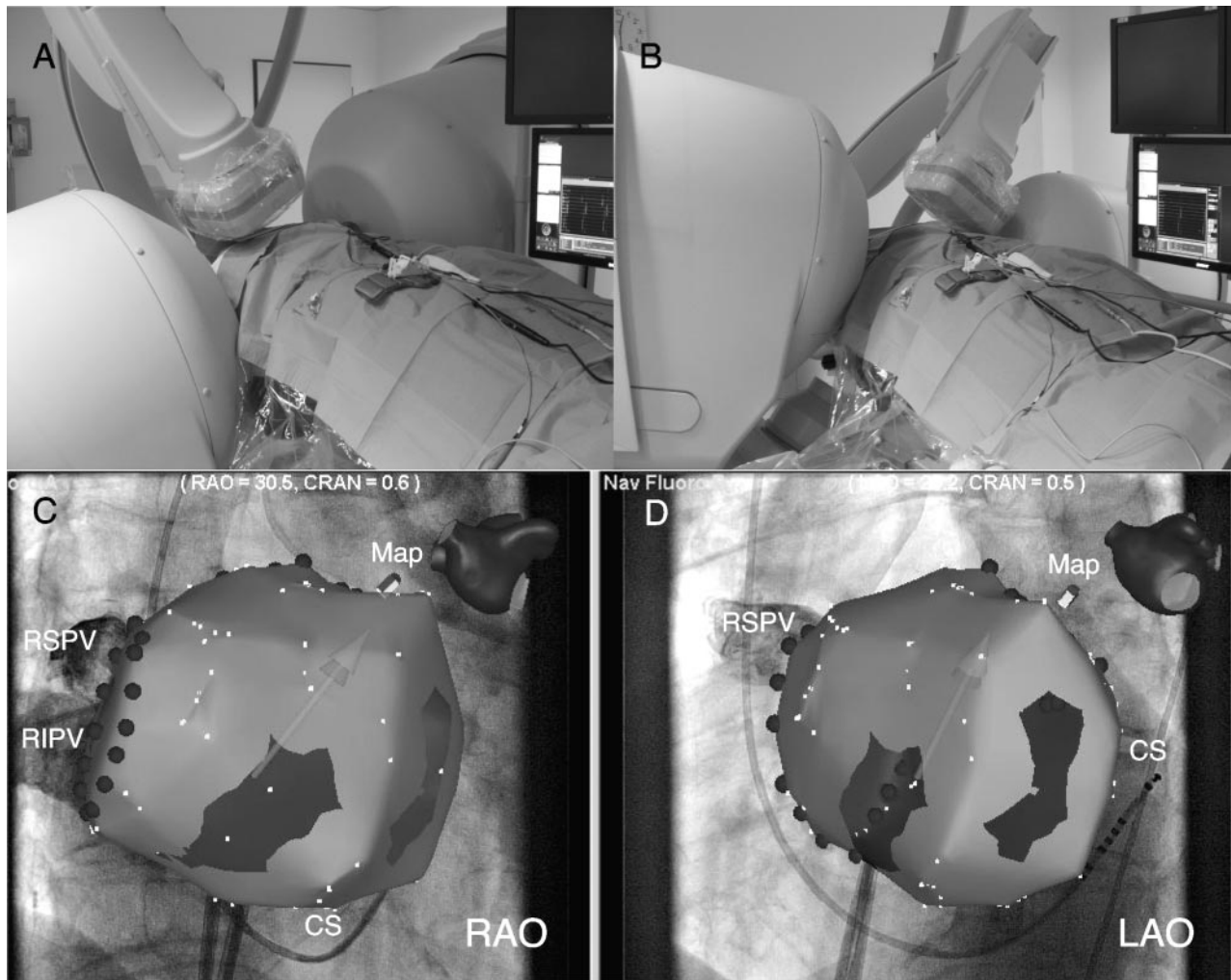
Drs Chun and Wissner contributed equally to this work.

Correspondence to K.R. Julian Chun, MD, Department of Cardiology, Asklepios Klinik St Georg, Lohmühlenstr 5, 20099 Hamburg, Germany. E-mail jongichun@t-online.de

© 2010 American Heart Association, Inc.

*Circ Arrhythm Electrophysiol* is available at <http://circep.ahajournals.org>

DOI: 10.1161/CIRCEP.110.942672



**Figure 1.** A and B, The magnetic navigation system Niobe II enables tilting of the permanent magnets thereby allowing increased C-arm angulations (RAO 30°, LAO 40°). C and D, Visualization of the 3D LA map interposed on the fluoroscopy screens using the Navigant 2.11 software. Red dots indicate ablation sites. RAO indicates right anterior oblique; LAO, left anterior oblique; RSPV, right inferior pulmonary vein; RIPV, right inferior pulmonary vein; and CS, coronary sinus.

### Basic Concept of Magnetic Navigation

The concept of magnetic navigation has recently been described.<sup>5</sup> Briefly, the MNS Niobe II incorporates 2 computer-controlled permanent magnets located in parallel to the fluoroscopy table, generating a magnetic field (0.08 T) allowing remote steerable mapping and ablation within the heart. The novel mapping and ablation catheter is equipped with 3 permanent magnets within its distal shaft aligning in parallel to the remotely controlled magnetic field. Altering the orientation of the outer magnets results in a magnetic field change and corresponding deflection of the catheter. Magnetic field vectors can be stored and, if necessary, recalled to facilitate automated navigation of the magnetic catheter. A computer-controlled catheter advancer system (Cardiodrive, Stereotaxis, Inc) and a video workstation (Navigant 2.11, Stereotaxis, Inc) are required to assist precise remote catheter manipulation. Compared with the first generation, the second-generation Niobe II MNS permits tilting of both magnets to RAO 30° and LAO 40° projections (Figure 1).

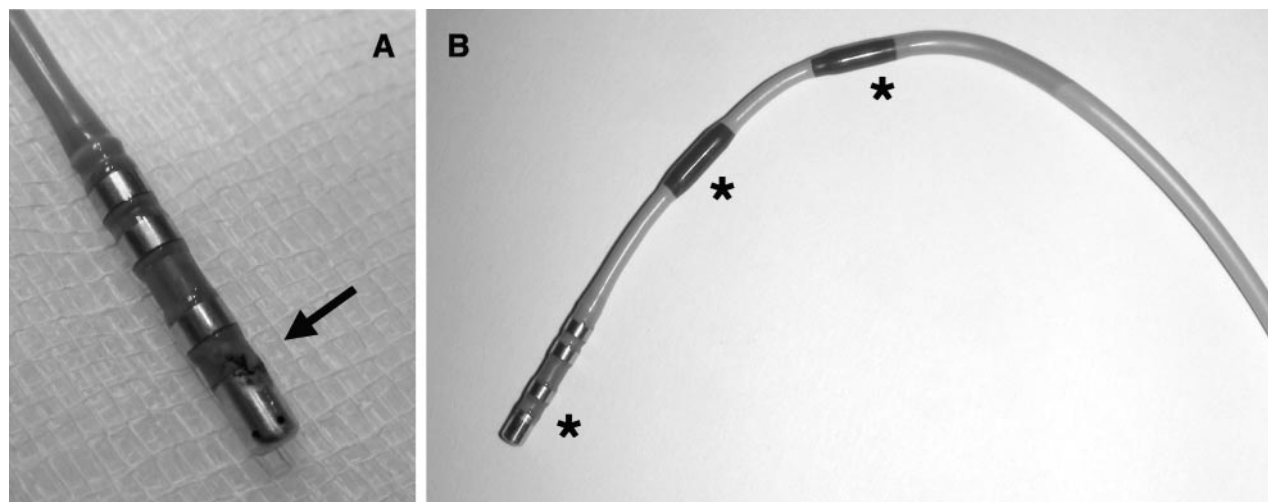
### Electrophysiology Study

All electrophysiology studies were performed during conscious sedation using fentanyl, midazolam, and continuous infusion of propofol. Vital parameters were continuously monitored. Two standard catheters were positioned at the His bundle region (6F Parahis, Biosense-Webster) via a femoral vein and within the coronary sinus (7F Parahis, Biosense Webster) via the left subclavian vein. An 8F and 8.5F SL1 sheath (SL1;

St Jude Medical, Daig Division, Minnetonka, Minn) was advanced to the LA using the Brockenbrough technique. In the first 3 patients in this series, the double lasso technique was used.<sup>7</sup> Three 8F sheaths (SL1, St Jude Medical Division) were advanced to the LA using the Brockenbrough technique. Two sheaths were placed over a single and a third sheath via a second puncture site. In the remaining patients, 2 sheaths were advanced through individual transseptal punctures. After transseptal catheterization intravenous heparin was administered to maintain an activated clotting time of 250 to 300 seconds.

### Remote-Controlled Magnetic LA Mapping

A novel 3.5-mm tip open-irrigated ablation catheter (Thermocool Navistar RMT, Biosense Webster) was used in conjunction with the CARTO RMT system (Biosense Webster) and the Niobe II MNS to perform stepwise remote-controlled magnetic (RCM) 3D LA electroanatomic mapping and ablation via joystick from the control room. No automated features were used. The CARTO RMT system transfers real-time catheter tip location and orientation to the Niobe II MNS. This information is rendered on the Navigant fluoroscopic reference screen, enabling continuous real-time monitoring of catheter tip position without the need to refresh the fluoroscopic images (Figure 1). Selective PV angiographies were performed to identify the PV ostia using standard projections (RAO 30°, LAO 40°). RCM LA reconstruction was performed from the control room as described in detail elsewhere.<sup>8,9</sup> The ipsilateral PV ostia were tagged on the 3D LA map according to



**Figure 2.** A, First-generation open-irrigated 3.5-mm-tip magnetic catheter demonstrating char formation at the proximal portion of the distal electrode. B, Second-generation open-irrigated 3.5-mm-tip magnetic catheter. Modifications included increasing the internal lumen diameter to improve uniformity of flow of irrigation fluid, adjusting the irrigation port location, and reducing internal clearances to maximize thermal conductivity; interelectrode spacing and radiofrequency current settings were identical to the original catheter. Asterisk indicates magnet positions.

fluoroscopic and electrophysiological criteria and transferred to the Navigant workstation superimposed on standard fluoroscopic projections.<sup>1</sup> A decapolar spiral mapping catheter (Lasso, Biosense Webster) was positioned within the PV ostium on the side of ablation.

### First-Generation Irrigated Magnetic Catheter

The novel, first-generation 3.5-mm-tip open-irrigated soft magnetic catheter (Thermocool Navistar RMT, Biosense Webster) incorporates 6 holes within its distal tip to allow open irrigation using 0.9% heparinized saline. The interelectrode spacing between the distal and proximal electrodes measures 2, 5, and 2 mm, respectively.

### Second-Generation Irrigated Magnetic Catheter

The revised second-generation 3.5-mm-tip open-irrigated magnetic catheter (Thermocool Navistar RMT, Biosense Webster) was used after a relaunch. Modifications included increasing the internal luminal diameter to improve uniformity of flow of irrigation fluid, adjusting the irrigation port location, and reducing internal clearances to maximize thermal conductivity, whereas interelectrode spacing and RF settings were identical to the original catheter (Figure 2).

### Manual Ablation

If RCM ipsilateral PVI was not achieved after 180 minutes, procedure time crossover to manual ablation (Thermocool Navistar, Biosense Webster) was allowed.

### Irrigated Magnetic Catheter-Guided Radiofrequency Ablation

Bilateral circumferential linear lesion (CCL) sets were deployed to achieve complete isolation of the ipsilateral PVs guided by 3D LA mapping as described previously in detail.<sup>1</sup> Target temperature was 43°C with maximal RFC application duration of 110 seconds. Maximal power was set at 40 W with a flush rate of 30 mL/min while ablating along the anterior aspect of the LA wall and 30 W with a flush rate of 17 mL/min at the posterior LA wall. Ablation sites were tagged on the reconstructed 3D LA map. Irrigated RFC was applied for up to 30 seconds or until the maximal local electrogram amplitude decreased by 80% or double potentials were noted. The end point for ablation was defined as PV isolation registered as loss of PV spike potentials recorded on the spiral-mapping catheter positioned within the ipsilateral PVs. Total procedure time was defined as skin-to-skin time including a 30-minute waiting period.

### Study End Points

The primary end point was defined as acute RCM PV isolation as documented by the spiral-mapping catheter.

Secondary end points included analysis of procedural parameters, complications, and AF recurrence off antiarrhythmic drugs, respectively.

### Postablation Protocol and Patient Follow-Up

Pericardial effusion and pneumothorax were ruled out in all patients postoperatively performing transthoracic echocardiography and chest radiography. Following ablation, patients were bridged using intravenous heparin targeting a PTT of 50 to 70 seconds, and oral anticoagulation was started the next day. All patients received phenprocoumon for at least 3 months, targeting an INR value of 2.0 to 3.0. Antiarrhythmic drug therapy was continued for at least 3 months and discontinued if the patients were free of AF relapse. Follow-up included weekly telephone interviews and outpatient clinic visits at 1, 3, 6, 9, 12, 18, and 24 months after ablation (interview, ECG, Holter ECG, transesophageal echocardiography).

### Statistical Analysis

We compared patients treated with the novel, first-generation 3.5-mm-tip open-irrigated soft magnetic catheter (Thermocool Navistar RMT, Biosense Webster) in group 1 with patients treated with the revised second-generation 3.5-mm-tip open-irrigated magnetic catheter (Thermocool Navistar RMT, Biosense Webster) in group 2. To describe continuous variables median, minimum and maximum were given. The Mann-Whitney *U* test was performed to compare groups.

Categorical data were presented with absolute and relative frequencies and compared with the Fisher exact test.

All statistical analysis used to compare measurements was performed at patient level between catheter group 1 and group 2.

Because of the small data set, the probability value computation was based on the exact method. A probability value <0.05 was considered statistically significant. Analysis was performed using SPSS for Windows 11.5.2.1, SPSS Inc.

## Results

### Patient Characteristics

Detailed patient characteristics are summarized in Table 1.

### Remote-Controlled Pulmonary Vein Isolation

#### Step 1: First-Generation Irrigated Magnetic Catheter

Successful RCM PVI using the first-generation Thermocool Navistar RMT catheter was achieved in 26 of 28 (93%) patients, including the initial 3 patients in whom the “double lasso technique” was used (Figure 3).



**Table 1. Patient Baseline Characteristics**

	Group 1 (n=28 Patients)	Group 2 (n=28 Patients)	P Value	Total (n=56 Patients)
Age, y	64 (38–78)	60 (24–78)	0.083	63 (24–78)
Type of AF				
Paroxysmal AF, n (%)	19 (68)	18 (64)	1.000	37 (66)
Persistent AF, n (%)	9 (32)	10 (36)	1.000	19 (34)
Male, n (%)	22 (79)	20 (71)	0.758	42 (75)
LA diameter, mm	47 (34–52)	40 (35–53)	0.015	43 (34–53)
Hypertension, n (%)	22 (79)	16 (57)	0.152	38 (68)
EF, %				
≤45%, n (%)	3 (11)	1 (4)	0.611	4 (7)
>45%/normal, n (%)	25 (89)	27 (96)		52 (93)
AAD, n (%)				
0	3 (11)	3 (11)	0.752	6 (11)
1	15 (54)	12 (43)		27 (48)
2	10 (36)	13 (46)		23 (41)

For age and LA diameter, median (range) values are given.

EF indicates ejection fraction; AAD, antiarrhythmic drugs; and n, frequency.

In 2 patients, crossover to manual ablation was necessary to complete PVI at the septal CCLs (anteroinferior) previously inaccessible with RCM navigation (Table 2).

Median total RFC time for septal and lateral CCL ablation was 39 (22 to 103) minutes and 42 (28 to 97) minutes, respectively.

#### Step 2: Second-Generation Irrigated Magnetic Catheter

Successful RCM PVI using the second-generation Thermocool Navistar RMT catheter was achieved in 26 of 28 (93%) patients.

In 2 patients, crossover to manual ablation was necessary to complete PVI at the septal CCL sites (anteroinferior) inaccessible with the magnetic catheter and at 1 lateral CCL site (anterior) where only transient PVI could be achieved (Table 2).

Median total RFC time for septal and lateral PV ablation was 34 (15 to 91) minutes and 26 (11 to 81) minutes, respectively.

#### RFC Ablation Time

The primary end point of acute ipsilateral PVI was achieved in a total of 52 of 56 (93%) patients.

Ninety-six percent (107/112) of CCLs were successfully ablated, that is, 96% in group 1 (54/56) and 95% (53/56) in group 2. Separate analysis of the septal CCLs in group 1 and 2 demonstrated similar radiofrequency ablation times (group 1: 39 [22 to 103] minutes versus group 2: 34 [15 to 91] minutes,  $P=0.144$ ), whereas with regard to the lateral CCLs, a marked reduction of RF ablation time was observed (group 1: 42 [28 to 97] minutes versus group 2: 26 [11 to 81] minutes,  $P<0.0001$ ) (Table 2).

#### Procedural Parameters

Total median procedure and fluoroscopy times were 315 (125 to 550) minutes and 19 (8 to 39) minutes, respectively. Both median procedure and fluoroscopy times significantly decreased from 370 (230 to 550) minutes and 24 (10 to 39) minutes in group 1 to 243 (125 to 450) minutes ( $P<0.0001$ ) and 16 (8 to 39) minutes ( $P=0.011$ ) in group 2. The total median fluoroscopy time of 19 (8 to 39) minutes included 6 (2 to 15) minutes of radiation used while the operator navigated the catheter from the control room, resulting in a 31% (15% to 83%) reduction in median fluoroscopy exposure to the investigator (Table 2).

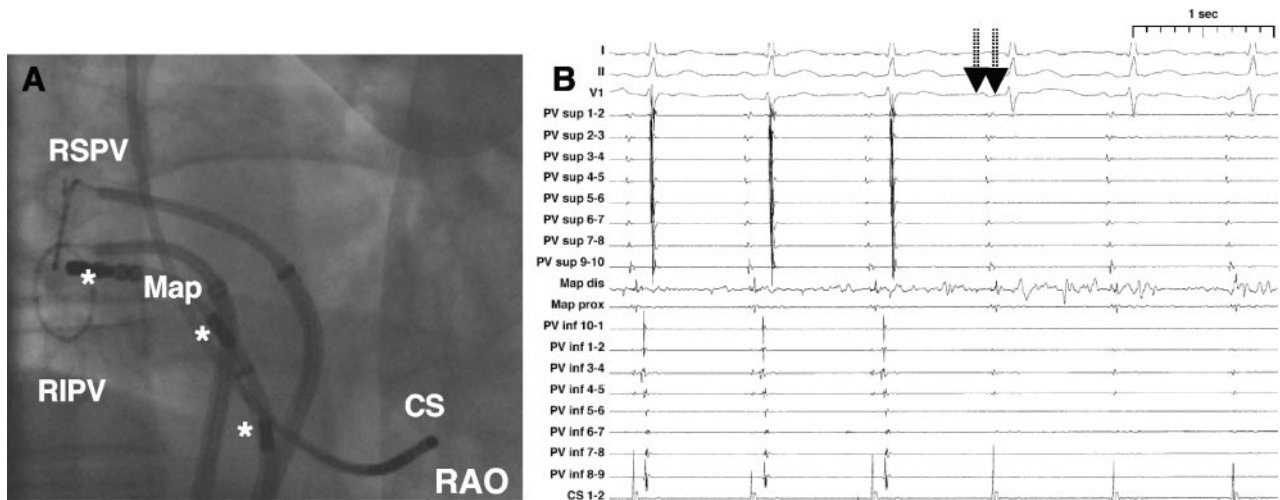
#### Follow-Up and Midterm Ablation Success Rate

Among 56 patients, 50 (89%) had completed the 3-month blanking period. After a mean follow-up period of  $426\pm 213$  days, 35 of 50 (70%) patients were in sinus rhythm (Table 3). Twelve of 50 (24%) patients underwent a redo ablation procedure.

#### Complications

##### Step 1: First-Generation Irrigated Magnetic Catheter

No acute complications were observed. However, char formation at the catheter tip after LA ablation was evident in 17 of 28 (61%) catheters in group 1, whereas no tip charring occurred in group 2 ( $P<0.0001$ ) (Figure 2). No embolic complications were noted during the ablation procedure. However, 1 patient dem-



**Figure 3.** A, Right anterior oblique projection of double-lasso approach using the magnetic ablation catheter. B, Gap closure (posteroinferior) results in simultaneous PV isolation (arrows). Note that the proximal magnet remains within the transseptal sheath. RAO indicates right anterior oblique; RSPV, right superior pulmonary vein; RIPV, right inferior pulmonary vein; and CS, coronary sinus. Asterisk indicates magnet positions.

**Table 2. Procedural Parameters for Patients Treated With the First- and Second-Generation Irrigated-Tip Magnetic Catheter**

	Group 1 (n=28 Patients)	Group 2 (n=28 Patients)	P Value	Total (n=56 Patients)
Total procedure time, min, Med (Min-Max)	370 (230–550)	243 (125–450)	<0.00001	315 (125–550)
Septal PV RFC time, min, Med (Min-Max)	39 (22–103)	34 (15–91)	0.144	35 (15–103)
RCM PVI septal [n]	26/28 [93%]	26/28 [93%]	1.000	52/56 (93%)
Lateral PV RFC time, min, Med (Min-Max)	42 (28–97)	26 (11–81)	0.00001	34 (11–97)
RCM PVI lateral [n]	28/28 [100%]	27/28 [96%]	1.000	55/56 (98%)
Total FT, min,	24	16	0.011	19
Med (Min-Max)	(10–39)	(8–39)		(8–39)
FT from CR, min,	7	5	0.022	6
Med (Min-Max)	(2–14)	(2–10)		(2–14)
FT reduction investigator, % Med (Min-Max)	30 (25–36)	32 (27–45)	0.205	31 (26–40)

Median (range) values are given.

Med indicates median; Min, minimum; Max, maximum; FT, fluoroscopy time; CR, control room; and n, frequency.

onstrated a non-ST-segment elevation myocardial infarction due to embolic occlusion of the distal left anterior descending artery on day 7 after PVI despite full dose of low-molecular-weight heparin. A second patient had a transient ischemic attack 14 days after PVI. At that time, the patient was in sinus rhythm, the INR value was 2.5, MRI and computed tomography scanning of the brain showed no thromboembolism, and neurological symptoms normalized within hours. Further analysis showed that tip charring on both ablation catheters was observed after ablation. Last, during a redo ablation procedure, 1 patient was noted to have an asymptomatic right inferior PV stenosis (Table 3).

### Step 2: Second-Generation Irrigated Magnetic Catheter

No intraprocedural or postprocedural complications were noted. In addition, there was no evidence of tip charring on the ablation catheter during any of the procedures.

## Discussion

We present our experience using both versions of a novel irrigated-tip magnetic catheter for RCM LA mapping and PVI.

**Table 3. Follow-Up Data**

	Group 1 (n=28)	Group 2 (n=28)	Total (n=56)
Single procedure success rate [n]	20/28 [71%]	15/22 [68%]*	35/50 [70%]†
Follow-up time, days, Med (Min-Max)	617 (514–683)	191 (100–374)*	545 (100–683)†
Complications			
Tip charring, n=17 (61%)		None	17/56 (30%)
NSTEMI, n=1 (4%)		None	1/56 (2%)
RIPV stenosis, n=1 (4%)		None	1/56 (2%)
TIA, n=1 (4%)		None	1/56 (2%)

n indicates frequency; Med, median; Min, minimum; Max, maximum; NSTEMI, non-ST-segment elevation myocardial infarction; and TIA, transient ischemic attack.

\*Follow-up in 22 of 28 patients who completed the 3-month blanking period.

†Follow-up in 50 of 56 patients who completed the 3-month blanking period.

Major findings are that (1) RCM LA mapping and PVI following our previously reported manual approach<sup>1</sup> is feasible but time-consuming, (2) the first-generation irrigated-tip magnetic catheter was associated with tip charring and complications while neither occurred using the second-generation catheter, (3) the operator's exposure to radiation is reduced, and (4) success rates are similar to previously reported manual RFC ablation data.

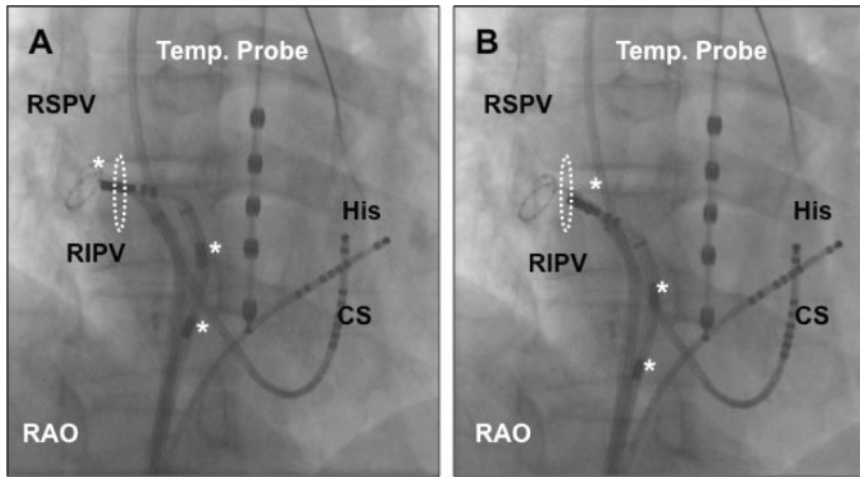
### Remote-Controlled Magnetic LA Mapping and PVI

Precise 3D LA reconstruction and tagging of PV ostia is essential for successful manual PVI, which has been established as the procedural end point of AF ablation.<sup>1,10</sup> The primary end point of real-time spiral-mapping catheter documented PVI could be achieved in the majority of patients but required at least double transseptal access to the LA. In the initial 3 patients, 3 transseptal LA sheaths were used to demonstrate feasibility of RCM wide area circumferential PVI as described previously.<sup>1</sup>

Initial experience with RCM mapping and circumferential PV ablation was recently reported utilizing a solid-tip magnetic ablation catheter.<sup>8</sup> However, circumferential PV ablation was not verified using real-time recordings from a spiral-mapping catheter during ablation. In their stepwise RCM AF ablation experience, Di Biase et al<sup>9</sup> reported a low rate (8%) of successful PVI if spiral-mapping catheter verification was used, necessitating manual completion of PVI in the majority of patients. However, the study provided no detailed information about RCM ablation failures.

According to our data, RCM real-time PVI with spiral-mapping catheter verification is a feasible end point but may be more time consuming compared with manual ablation.<sup>1</sup> Changes to the magnetic field through movement of both permanent magnets and time to transmit catheter advancement and retraction (Navigant 2.11 software, Cardiodyne motor unit) limit the overall speed of 3D RCM catheter movements. A software update (Navigant 3.0, Stereotaxis, Inc) to the Stereotaxis system after completion of the current study has addressed these issues and will need future assessment.

Comparing groups, we observed a significant reduction in ablation time along the lateral PVs in group 2. This finding



**Figure 4.** A, The right inferior pulmonary vein (RIPV) in a right anterior oblique (RAO) projection. Lasso positioned within the RIPV. Temperature probe inserted into the esophagus. Mapping catheter unable to reach an anteroinferior position. Two magnets remain within the transseptal sheath. White dots indicate the RIPV ostium. B, Withdrawal of the transseptal sheath allows access to an anteroinferior mapping position. LAO indicates left anterior oblique; RSPV, right superior pulmonary vein; CS, coronary sinus; and His, His bundle position.

may be explained by enhanced lesion formation facilitated by redesign of the catheter.

To reduce procedure time of RCM AF ablation, a better understanding of the duration of each procedural step (LA map, marking PV ostia, and ablation of septal and lateral PVs) comparing RCM and manual AF ablation is needed in the future. Furthermore, use of automated features allowing operator-independent LA reconstruction and/or ablation may direct future developments.

### Ablation Failures

To achieve circumferential PVI, crossover to manual ablation was necessary in 4 patients to complete 5 CCLs (4 septal, 1 lateral). In general, RCM ablation encircling the septal PVs required significantly longer RFC ablation times as compared with the lateral PVs (group 2). RCM septal ablation was associated with 4 of 5 failures caused by inaccessibility of septal inferior gaps. Notably, our data indicate that RCM navigation and ablation encircling the septal PVs is more complex and accounted for prolonged procedure times. Navigation to antero-inferior septal PV sites is hindered by the close anatomic relationship between the transseptal puncture site and ostium of the right inferior pulmonary vein (RIPV).<sup>11</sup> To allow full range of motion, all 3 magnets integrated within the catheter tip need to be advanced beyond the distal end of the transseptal sheath. Thus, when approaching the RIPV directly, the proximal magnets may still be withheld inside the transseptal sheath even if the transseptal sheath is withdrawn to the right atrial septum (Figure 4A and 4B). This in turn will affect accessibility to the RIPV 2-fold. First, only 1 or 2 magnets mediate the magnetic deflection. Second, the catheter may redirect superiorly by the magnetic force imposed on the magnet withheld inside the distal sheath. To overcome this limitation, it has been suggested to withdraw the transseptal sheath to the septum (Figure 4A and 4B), right atrium, or inferior caval vein.<sup>8</sup> However, catheter looping within the right atrium may lead to loss of LA access and contact force, thereby impairing transmural lesion formation.<sup>12</sup> This limitation may be overcome by special sheath designs or use of stronger magnetic forces.

### Complications and Follow-Up

Catheter ablation of AF can be associated with substantial complications.<sup>13</sup> Previously, it has been demonstrated that the

use of a solid-tip magnetic catheter for AF ablation resulted in thrombus formation resulting in embolic events.<sup>9</sup> In the current study, all complications occurred in group 1. Two complications potentially thromboembolic in nature (1 transient ischemic attack and 1 embolic non-ST-elevation myocardial infarction) were associated with catheter tip char formation. In group 1, a substantial number of catheters demonstrated tip charring, (Figure 2) despite the use of well-established energy/ablation settings culminating in a voluntary recall by the company. Catheter modifications included increasing the internal luminal diameter, adjusting the irrigation port location, and reducing internal clearances to maximize thermal conductivity. Subsequently, no further evidence of tip charring and/or embolic complications was noted in group 2.

A single asymptomatic RIPV narrowing in group 1 is probably due to ablation within the PV. If the catheter points directly toward the RIPV, inadvertent advancement to a more distal portion of the RIPV may occur.

Acute and midterm follow-up data after a single ablation procedure are in line with previously published reports using manual radiofrequency energy ablation and similar procedural end points.<sup>1,14</sup> In the current study, a substantial number of persistent AF patients were included in both groups. In patients with longstanding persistent AF the ideal procedural end point is still under debate; therefore these patients were not included.

### Radiation Exposure to the Operator

The current study demonstrates a 31% reduction in median fluoroscopy exposure to the investigator, which is in agreement with previous reports using remote-controlled ablation.<sup>6,15,16</sup> This is of particular importance since interventional electrophysiologists accumulate a significant amount of radiation exposure throughout their professional careers.

### Limitations

This study enrolled a limited number of patients and is not a randomized trial. Operators gained longitudinal experience and thus our results may not reflect those of less experienced centers. Procedure times in group 1 may have been affected by the fact that in the initial 3 patients the double-lasso technique was used. Furthermore, operator experience increased over time, thus influencing procedure duration.



Char formation occurred only in patients treated with the first-generation irrigated magnetic catheter. However, the study group represented a relatively small sample size. Although no further tip charring was noted using the second-generation ablation catheter, a larger number of patients must be treated to assess the true prevalence of char formation.

The cause-effect relationship between tip charring and thromboembolic complications observed in group 1 remains speculative.

## Conclusion

Remote-controlled magnetic AF ablation with real-time verification of PVI is feasible with a comparable acute and midterm success rate to conventional manual catheter ablation. Safety improved after a redesign of the magnetic ablation catheter.

## Disclosures

Dr Chun received an educational and travel grant from Stereotaxis; Dr Wissner received a travel grant from Stereotaxis; Dr Kuck received an educational and travel grant from Stereotaxis and a research grant from Stereotaxis Inc (St Louis, Mo) to PRO Research (Research Organization of the Asklepios LBK Group).

## References

- Ouyang F, Bansch D, Ernst S, Schaumann A, Hachiya H, Chen M, Chun J, Falk P, Khanedani A, Antz M, Kuck KH. Complete isolation of left atrium surrounding the pulmonary veins: new insights from the double-lasso technique in paroxysmal atrial fibrillation. *Circulation*. 2004;110:2090–2096.
- Ouyang F, Ernst S, Chun J, Bansch D, Li Y, Schaumann A, Mavrakis H, Liu X, Deger FT, Schmidt B, Xue Y, Cao J, Hennig D, Huang H, Kuck KH, Antz M. Electrophysiological findings during ablation of persistent atrial fibrillation with electroanatomic mapping and double lasso catheter technique. *Circulation*. 2005;112:3038–3048.
- Natale A, Raviele A, Arentz T, Calkins H, Chen SA, Haissaguerre M, Hindricks G, Ho Y, Kuck KH, Marchlinski F, Napolitano C, Packer D, Pappone C, Prystowsky EN, Schilling R, Shah D, Themistoclakis S, Verma A. Venice chart international consensus document on atrial fibrillation ablation. *J Cardiovasc Electrophysiol*. 2007;18:560–580.
- Fuster V, Ryden LE, Cannom DS, Crijns HJ, Curtis AB, Ellenbogen KA, Halperin JL, Le Heuzey JY, Kay GN, Lowe JE, Olsson SB, Prystowsky EN, Tamargo JL, Wann S, Smith SC Jr, Jacobs AK, Adams CD, Anderson JL, Antman EM, Halperin JL, Hunt SA, Nishimura R, Ornato JP, Page RL, Riegel B, Priori SG, Blanc JJ, Budaj A, Camm AJ, Dean V, Deckers JW, Despres C, Dickstein K, Lekakis J, McGregor K, Metra M, Morais J, Osterspey A, Tamargo JL, Zamorano JL. ACC/AHA/ESC 2006 guidelines for the management of patients with atrial fibrillation: A report of the American college of Cardiology/American Heart Association Task Force on practice guidelines and the European Society of Cardiology Committee for practice guidelines (writing committee to revise the 2001 guidelines for the management of patients with atrial fibrillation): Developed in collaboration with the European Heart Rhythm Association and the Heart Rhythm Society. *Circulation*. 2006;114:e257–e354.
- Ernst S, Ouyang F, Linder C, Hertting K, Stahl F, Chun J, Hachiya H, Bansch D, Antz M, Kuck KH. Initial experience with remote catheter ablation using a novel magnetic navigation system: magnetic remote catheter ablation. *Circulation*. 2004;109:1472–1475.
- Chun JK, Ernst S, Matthews S, Schmidt B, Bansch D, Boczor S, Ujeyl A, Antz M, Ouyang F, Kuck KH. Remote-controlled catheter ablation of accessory pathways: results from the magnetic laboratory. *Eur Heart J*. 2007;28:190–195.
- Ernst S, Ouyang F, Linder C, Hertting K, Stahl F, Chun J, Hachiya H, Krumdordf U, Antz M, Kuck KH. Modulation of the slow pathway in the presence of a persistent left superior caval vein using the novel magnetic navigation system Niobe. *Europace*. 2004;6:10–14.
- Pappone C, Vicedomini G, Manguso F, Gugliotta F, Mazzone P, Gulletta S, Sora N, Sala S, Marzi A, Augello G, Livolsi L, Santagostino A, Santinelli V. Robotic magnetic navigation for atrial fibrillation ablation. *J Am Coll Cardiol*. 2006;47:1390–1400.
- Di Biase L, Fahmy TS, Patel D, Bai R, Civello K, Wazni OM, Kanj M, Elayi CS, Ching CK, Khan M, Popova L, Schweikert RA, Cummings JE, Burkhardt JD, Martin DO, Bhargava M, Dresing T, Saliba W, Arruda M, Natale A. Remote magnetic navigation: human experience in pulmonary vein ablation. *J Am Coll Cardiol*. 2007;50:868–874.
- Calkins H, Brugada J, Packer DL, Cappato R, Chen SA, Crijns HJ, Damiano RJ Jr, Davies DW, Haines DE, Haissaguerre M, Iesaka Y, Jackman W, Jais P, Kottkamp H, Kuck KH, Lindsay BD, Marchlinski FE, McCarthy PM, Mont JL, Morady F, Nademanee K, Natale A, Pappone C, Prystowsky E, Raviele A, Ruskin JN, Shemin RJ. HRS/EHRA/ECAS expert consensus statement on catheter and surgical ablation of atrial fibrillation: recommendations for personnel, policy, procedures and follow-up: a report of the Heart Rhythm Society (HRS) Task Force on catheter and surgical ablation of atrial fibrillation. *Heart Rhythm*. 2007;4:816–861.
- Schmidt B, Ernst S, Ouyang F, Chun KR, Broemel T, Bansch D, Kuck KH, Antz M. External and endoluminal analysis of left atrial anatomy and the pulmonary veins in three-dimensional reconstructions of magnetic resonance angiography: the full insight from inside. *J Cardiovasc Electrophysiol*. 2006;17:957–964.
- Yokoyama K, Nakagawa H, Shah DC, Lambert H, Leo G, Aebly N, Ikeda A, Pitha JV, Sharma T, Lazzara R, Jackman WM. Novel contact force sensor incorporated in irrigated radiofrequency ablation catheter predicts lesion size and incidence of steam pop and thrombus. *Circ Arrhythm Electrophysiol*. 2008;1:354–362.
- Cappato R, Calkins H, Chen SA, Davies W, Iesaka Y, Kalman J, Kim YH, Klein G, Natale A, Packer D, Skanes A. Prevalence and causes of fatal outcome in catheter ablation of atrial fibrillation. *J Am Coll Cardiol*. 2009;53:1798–1803.
- Arentz T, Weber R, Burkle G, Herrera C, Blum T, Stockinger J, Minners J, Neumann FJ, Kalusche D. Small or large isolation areas around the pulmonary veins for the treatment of atrial fibrillation? Results from a prospective randomized study. *Circulation*. 2007;115:3057–3063.
- Saliba W, Reddy VY, Wazni O, Cummings JE, Burkhardt JD, Haissaguerre M, Kautzner J, Peichl P, Neuzil P, Schibgilla V, Noelker G, Brachmann J, Di Biase L, Barrett C, Jais P, Natale A. Atrial fibrillation ablation using a robotic catheter remote control system: Initial human experience and long-term follow-up results. *J Am Coll Cardiol*. 2008;51:2407–2411.
- Schmidt B, Tilz R, Neven K, Chun K, Fürnkranz A, Ouyang F. Remote robotic navigation and electroanatomical mapping for ablation of atrial fibrillation. *Circ Arrhythmia Electrophysiol*. 2009;2:120–128.

## CLINICAL PERSPECTIVE

Conventional radiofrequency catheter ablation of atrial fibrillation requires significant manual skill for reproducible catheter positioning within the complex 3D left atrial anatomy to achieve pulmonary vein isolation. This study evaluated the Niobe II (Stereotaxis, St Louis, Mo) navigation system that incorporates two computer-controlled permanent magnets to allow remote steering and navigation of a mapping and ablation catheter. Recently, a novel open-irrigated, magnetic catheter (Thermocool, Biosense Webster, Diamond Bar, Calif) was approved in Europe for catheter ablation of atrial fibrillation. The current study reports on the results of pulmonary vein isolation using this novel open-irrigated magnetic catheter in conjunction with the magnetic navigation system Niobe II. Char formation with the initial catheter design was eliminated with design modifications. The study shows that remote controlled magnetic catheter ablation of atrial fibrillation with real-time verification of pulmonary vein isolation is feasible with a comparable success rate to manual ablation while decreasing operator fluoroscopy exposure.