Advanced Cardiovascular Magnetic Resonance Myocardial Perfusion Imaging

High-Spatial Resolution Versus 3-Dimensional Whole-Heart Coverage

Manish Motwani, BSc, MB ChB; Roy Jogiya BSc, MBBS; Sebastian Kozerke, PhD; John P. Greenwood, MB ChB, PhD; Sven Plein, MD, PhD

Myocardial perfusion imaging with cardiovascular magnetic resonance (CMR) has been established as an accurate method for the detection of coronary artery disease (CAD) in single- and multicenter studies.[1–4] In most previous studies, myocardial perfusion CMR data have been acquired in 3 left ventricular short-axis slices with an in-plane spatial resolution of 2.5 to 3 mm.[1–4] In recent years, an array of techniques that can achieve faster scan speed by using spatial, temporal, or spatiotemporal redundancy of the data have been proposed.[5–7] Applied to myocardial perfusion CMR, the faster data acquisition afforded by these methods has been used in different ways. Some authors have invested the speed-up to improve the in-plane spatial resolution of myocardial perfusion CMR to below 2 mm.[8–12] The main benefits of such high-resolution acquisition include a reduction in dark-rim artifact and better detection of subendocardial ischemia leading to improved diagnostic performance.[8,12,13] Other authors have used faster data acquisition to develop 3-dimensional (3D) myocardial perfusion CMR methods that provide whole-heart coverage.[14–17] The main motivation for these developments is to overcome the limited cardiac coverage of standard perfusion CMR and to allow more accurate quantification of total myocardial ischemic burden.[16] Furthermore, 3D perfusion CMR allows the acquisition of all slices at the same, optimized time point in the cardiac cycle, for example, the mid-diastolic or end-systolic phase, so that motion artifacts can be reduced and registration between slices improved.[18]

However, both high-resolution and 3D whole-heart perfusion CMR have specific limitations, mostly related to the high-temporal undersampling that is used, and their potential clinical role remains undefined. This article gives a brief overview of the principles of advanced acceleration and compares the current evidence for both high-spatial resolution and 3D whole-heart acquisition in myocardial perfusion CMR.

Advanced Acceleration Methods

Accelerating data acquisition with parallel imaging or echo-planar imaging methods has been standard practice in perfusion CMR for more than a decade, but tradeoffs in signal-to-noise ratio (SNR) and artifacts limit the achievable acceleration to 2- to 3-fold. In a typical stress perfusion study, these methods permit the acquisition of 3 to 4 myocardial slices with an in-plane spatial resolution of 2 to 3 mm. More recently proposed prior-knowledge–based techniques allow much higher acceleration factors for data acquisition.[5,7] The prior-knowledge principle is not limited to CMR or even MRI, per se, and has also been applied to computed tomography and positron emission tomography.[19,20] Technical details of current acceleration methods are beyond the scope of this article but can be found in recent technical reviews.[5,7] Prior-knowledge methods are based on the observation that image data sets exhibit considerable correlation in space and time. Perfusion CMR data sets in particular contain a high degree of temporal redundancy, because data are acquired at a single time point in the cardiac cycle using ECG-gating and during breath-holding, so that most of the image is static and the predominant change between neighboring time frames is related to the relatively slow contrast passage. This image redundancy can be exploited by undersampling data in the time (t) domain in addition to the more conventional undersampling in the spatial (k-space) domain.[5–7]

Examples of these spatiotemporal (or *k-t*) undersampling techniques are *k-t* broad linear acquisition speed-up technique (*k-t* BLAST), *k-t* sensitivity encoding (*k-t* SENSE), and *k-t* principal component analysis. In *k-t* BLAST, *k-t* SENSE, and *k-t* principal component analysis perfusion CMR sequences, undersampling is applied along k-space and time while a low-spatial resolution image (training data) is obtained in an interleaved fashion during the acquisition.[21] A nonaliased, full image series is then reconstructed using prior-knowledge derived from the training data (Figure I in the online-only Data Supplement). In *k-t* SENSE and *k-t* principal component analysis, receiver coil sensitivity information is also used to facilitate image reconstruction. Other related methods have been proposed, such as the highly constrained back-projection reconstruction (HYPR)

Received June 26, 2012; accepted February 20, 2013.

From the Multidisciplinary Cardiovascular Research Centre and Leeds Institute of Genetics, Health and Therapeutics, University of Leeds, Leeds, UK (M.M., J.P.G., S.P.); Division of Imaging Sciences, The Rayne Institute, King's College London, London, UK (R.J., S.P.); and Institute for Biomedical Engineering, University and ETH Zurich, Zurich, Switzerland (S.K.).

The online-only Data Supplement is available at http://circimaging.ahajournals.org/lookup/suppl/doi:10.1161/CIRCIMAGING.112.000193/-/DC1.

Correspondence to Sven Plein, MD, PhD, Multidisciplinary Cardiovascular Research Centre and Leeds Institute of Genetics, Health and Therapeutics, University of Leeds, Leeds LS2 9JT, UK. E-mail s.plein@leeds.ac.uk

(*Circ Cardiovasc Imaging*. 2013;6:339-348.)

© 2013 American Heart Association, Inc.

***Circ Cardiovasc Imaging* is available at http://circimaging.ahajournals.org** **DOI: 10.1161/CIRCIMAGING.112.000193**

Downloaded from http://ahajournals.org by on February 24, 2022

method, in which spatial and temporal redundancy are exploited serially.[5,22,23] In HYPR and its variants, k-space data are acquired with undersampled radial projections and overall rotation of the undersampling pattern at different time points.[23–25] In image reconstruction, a fully sampled composite image is formed by populating missing data from neighboring time frames. This very low-temporal resolution composite is then used to constrain back-projection of the undersampled data acquired for each individual time frame.[23,25] Other promising acceleration techniques, such as spiral imaging, are in early development, but their clinical utility has yet to be assessed.[26–28]

With the techniques listed above, it is possible to accelerate image acquisition up to a factor of ≥10 times. This speed-up has been used to improve spatial resolution (high-resolution perfusion CMR) or to acquire 3D myocardial perfusion data within a single acquisition shot facilitating greater spatial coverage.[8,10,13,14,16,17]

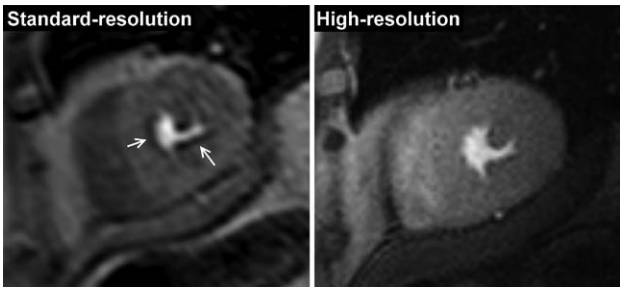

Figure 1. Dark-rim artifact. A 60-year-old man with suspected angina underwent stress perfusion cardiovascular magnetic resonance at 1.5 T with both standard-resolution (2.5 mm in-plane) and high-resolution (1.5 mm in-plane) acquisition. High-resolution acquisition was facilitated by 8-fold *k-t* broad linear speed-up technique acceleration. There were no significant stress-induced perfusion defects seen with either acquisition (mid-ventricular slices shown), but there was significant dark-rim artifact on the standard-resolution images (**arrows**). Subsequent x-ray angiography confirmed normal coronary arteries.

High-Resolution Perfusion CMR

Although no accepted definition exists, perfusion CMR is considered as high-spatial resolution when the in-plane resolution is better than 2 mm, making the resolution comparable to that of other common CMR methods. The first feasibility study of high-resolution perfusion CMR used 5-fold *k-t* SENSE to achieve an in-plane spatial resolution of 1.5 mm in a group of 10 volunteers.[21] Image quality was similar to that from a standard-resolution sequence (in-plane spatial resolution of 2.6 mm), but there was a significant reduction in the extent of dark-rim artifact (mean thickness: 1.7 versus 2.4 mm; $P<0.01$). Images acquired with high-resolution perfusion CMR also displayed an increased SNR compared with the standard-resolution technique when corrected for pixel size, facilitated by constraining the reconstruction with the low-resolution, high-SNR training data. In 3 of the volunteers, higher *k-t* SENSE acceleration factors of 8 and 10 were successfully used, without compromise in image quality or temporal signal intensity profiles.

The reduction of dark-rim artifact with high-resolution acquisition was confirmed in another volunteer study (n=10) by Maredia et al.[13] In this study, mean artifact thickness was 3.4 mm with standard-resolution acquisition compared with only 1.1 mm with a *k-t* SENSE high-resolution acquisition ($P<0.001$). Dark-rim artifacts are a common finding in conventional perfusion CMR and are thought to be caused by magnetic susceptibility effects, Gibbs ringing, and cardiac motion during acquisition.[29] Because these artifacts are directly proportional to voxel size, the use of high-resolution perfusion CMR offers a significant advantage (Figure 1).

Following the feasibility studies in volunteers, high-resolution perfusion CMR has been validated in several patient studies (Table 1).[8–10,13] In the first of these, Plein et al[8] used an identical sequence to their previous volunteer study (1.5 T, 5-fold *k-t* SENSE, in-plane resolution 1.4 mm) in 51 patients with known or suspected CAD. High-resolution acquisition was found to have a high-image quality and high-diagnostic accuracy (area under the curve [AUC] = 0.85) against quantitative coronary angiography. Notably, the diagnostic accuracy in single-vessel disease and multivessel disease was similar (AUC: 0.87 versus 0.82, respectively), suggesting that sufficient spatial resolution to resolve a transmural ischemic gradient can overcome one of the major limitations of perfusion imaging in multivessel disease, that is, its dependence on a reference area of normal perfusion (Figure 2). Other benefits of high-resolution acquisition noted in the study were better integration with cine and late-gadolinium enhancement data and minimal dark-rim artifact. A subsequent study demonstrated the clinical feasibility of high-resolution perfusion CMR at 3.0 T and confirmed the expected improvement in image quality and SNR compared with 1.5 T (Table 1).[9]

Manka et al[10] followed with an extension of the *k-t* SENSE technique at 3.0 T to achieve 8-fold acceleration and an in-plane spatial resolution of 1.1 mm, which was then evaluated in 20 patients with suspected CAD. The combined benefits of higher field strength and greater acceleration led to an incremental improvement in spatial resolution and an even greater AUC of 0.94 (95% confidence interval, 0.74–0.99).

Most recently, in the only study to offer a direct comparison to date, high-resolution perfusion CMR (8-fold *k-t* BLAST, in-plane spatial resolution 1.6 mm) was found to have a significantly greater overall diagnostic accuracy compared with standard-resolution technique in 100 patients with suspected CAD (AUC, 0.93 versus 0.83; $P<0.001$). The improved diagnostic performance was attributed to better detection of subendocardial ischemia (Figure 2).[12] Because the endocardial layer is the most vulnerable to ischemia, the ability to detect subendocardial perfusion deficits confidently can be expected to improve the detection of CAD in a perfusion study.[30] Furthermore, a recent study by Hautvast et al[31] showed that high-resolution perfusion CMR data can be used to quantify transmural perfusion gradients accurately, and these new measurements may serve as diagnostic markers for the detection and characterization of epicardial coronary disease as well as microvascular disease.

The HYPR method was used in 1 recent single-center study, in a variant known as sliding-window conjugate-gradient HYPR (6 contiguous slices, 1.6 mm in-plane

Downloaded from http://ahajournals.org by on February 24, 2022

Table 1. Diagnostic Performance of Advanced Accelerated Perfusion CMR Techniques

	N		Acceleration Method	In-Plane Resolution	Spatial Coverage	Reference Standard	Diagnostic Accuracy
High-Resolution							
Plein 2008[8]	51	1.5 T	5× *k-t* SENSE	1.4 mm	4 slices (NC)*	QCA>50%	0.85†
Plein 2008[9]	33	1.5 T	5× *k-t* SENSE	1.5 mm	4 slices (NC)*	QCA>50%	0.80†
Plein 2008[9]	33	3.0 T	5× *k-t* SENSE	1.3 mm	4 slices (NC)*	QCA>50%	0.89†
Manka 2010[10]	20	3.0 T	8× *k-t* SENSE	1.1 mm	3 slices (NC)	QCA>50%	0.94†
Motwani 2012[12]	100	1.5 T	8× *k-t* BLAST	1.6 mm	3 slices (NC)	QCA≥50%	0.93†
Lockie 2011[11]	42	3.0 T	5× *k-t* BLAST	1.2 mm	3 slices (NC)	FFR<0.75	0.92†
3-Dimensional							
Manka 2011[15]	146	3.0 T	6× *k-t* SENSE	2.3 mm	16 slices (WH)	QCA≥50%	0.83‡
Manka 2012[16]	120	1.5 T	10× *k-t* PCA	2.0 mm	16 slices (WH)	FFR<0.75	0.87‡
Jogiya 2012[17]	53	3.0 T	10× *k-t* PCA	2.3 mm	12 slices (WH)	FFR<0.75	0.91‡
HYPR							
Ma 2012[25]	50	3.0 T	SW-CG-HYPR	1.6 mm	6 slices (WH)	QCA≥50%	0.90‡

BLAST indicates broad linear speed-up technique; CMR, cardiovascular magnetic resonance; FFR, fractional flow reserve; HYPR, highly constrained back-projection reconstruction; NC, noncontiguous; PCA, principal component analysis; QCA, quantitative coronary angiography; SENSE, sensitivity encoding; SW-CG-HYPR, sliding-window conjugate-gradient HYPR; T, Tesla; and WH, whole-heart.

*In these studies, temporal resolution was 2 R-R intervals, whereas in all others, it was 1 R-R interval.

†In these studies, diagnostic accuracy was calculated by receiver operating characteristic analysis and expressed as area under the curve.

‡In these studies, diagnostic accuracy was expressed as the proportion of correctly classified subjects (true positives+true negatives) among all subjects.

spatial resolution). The study demonstrated clinical feasibility and a high-diagnostic accuracy in 50 patients with suspected CAD.[25]

Whereas the previous studies have all used quantitative coronary angiography as their reference standard, Lockie et al[11] validated high-resolution perfusion CMR against invasive pressure-wire–derived fractional flow reserve (FFR). In the 42 patients studied, high-resolution perfusion CMR (5-fold *k-t* BLAST, in-plane resolution 1.2 mm) had a high diagnostic accuracy (AUC=0.92) for the detection of hemodynamically significant lesions (FFR<0.75). To have a noninvasive method that so closely correlates with FFR is highly attractive, and more widespread use could have a significant impact on clinical pathways, especially in patients with anatomically complex and multivessel disease.[32] However, whether high-resolution perfusion CMR conveys a diagnostic increment against FFR is not certain, and notably in a previous study using FFR<0.75 as the reference standard, Watkins et al[33] found a high level of diagnostic performance with a standard-resolution acquisition (sensitivity 91%, specificity 94%), comparable with the high-resolution method used by Lockie et al.[11]

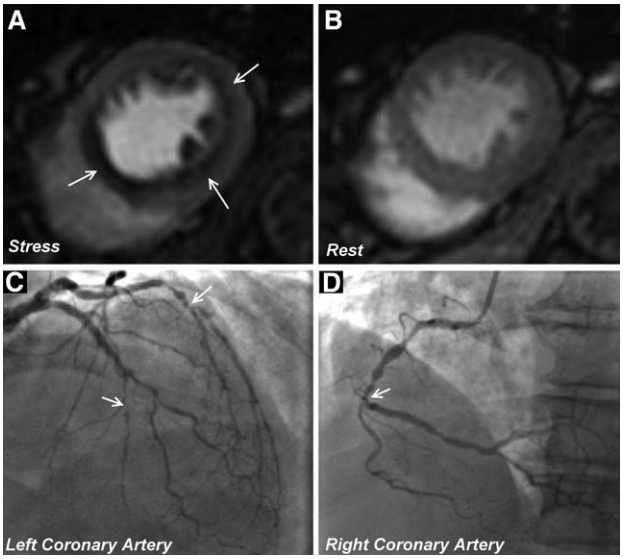

Figure 2. High-resolution perfusion cardiovascular magnetic resonance (CMR) in multivessel disease. A 48-year-old woman with suspected angina underwent stress perfusion CMR at 1.5 T using a high-resolution (1.4 mm in-plane) technique facilitated by 5-fold *k-t* broad linear speed-up technique. Stress-induced perfusion defects were seen in all 3 territories (**arrows**; **A** and **B**) and are clearly demarcated as subendocardial. Subsequent x-ray angiography revealed significant 3-vessel disease (**arrows**; **C** and **D**). This case highlights the ability of high-resolution acquisition to overcome the potential effects of balanced ischemia in multivessel disease by detecting transmural perfusion gradients and subendocardial ischemia.

Three-Dimensional Whole-Heart Perfusion CMR

Conventionally, cardiac coverage with perfusion CMR is limited to 3 to 4 noncontiguous slices through the left ventricle. However, nuclear perfusion studies have demonstrated that the extent of hypoperfusion and overall ischemic burden is a strong marker of clinical outcome.[34,35] It is unknown how accurately ischemic burden can be measured from noncontiguous image sections. Therefore, despite the demonstrated high diagnostic accuracy of conventional 2D perfusion CMR, the lack of complete myocardial coverage remains a potential limitation of the method.

The same speed-up methods that permit high-resolution myocardial perfusion CMR can also be used to acquire a single 3D stack, covering all or a large proportion of the heart while preserving adequate temporal and spatial resolution (Figure 3).[2] Advanced acceleration methods allow the acquisition of 3D data covering the whole heart in up to

Downloaded from http://ahajournals.org by on February 24, 2022

16 contiguous slices within an acquisition duration of <200 ms.[15] The most significant advantage of 3D acquisition is that contiguous spatial coverage allows the true extent of perfusion defects to be visualized.[14] Furthermore, although data in the literature regarding the incidence of pure apical ischemia are lacking and they are presumed to be rare, the inability of 2D perfusion CMR to image the apical cap is sometimes stated as a limitation, and this is overcome by 3D acquisition.[36,2] Another limitation of conventional 2D-myocardial perfusion CMR is that each slice is acquired in a different phase of the cardiac cycle (Figure 3). In practice, this means that the acquisition cannot be optimized for all slices and may coincide with rapid cardiac motion in some slices, leading to motion artifacts in the images. In 3D acquisition, all data are acquired in the same cardiac phase, and the time point for acquisition in the cardiac cycle can be optimized to minimize artifact. Furthermore, the cardiac phase can be matched with other acquired data, such as late-gadolinium enhancement imaging for improved coregistration. As a related benefit, 3D acquisition also permits the optimal choice of the saturation recovery time and the ability to scan at high-heart rates, because only 1 preparation pulse and 1 readout per heart beat are applied.[14,37] The optimal phase within the cardiac cycle for 3D acquisition is the subject of ongoing research, with end-systole and mid-diastole being the favored options.[37] In mid-diastole, the heart is usually at its most stationary, but the relatively thin myocardium can compound the effect of dark-rim artifact and limit the assessment of the transmurality perfusion defects. End-systole, on the other hand, has a shorter quiescent period, but the thicker myocardium reduces the effect of dark-rim artifact and facilitates the grading of defect transmurality. Systolic acquisition is also less sensitive to R-R variability and arrhythmia, which is relevant to the increasing burden of patients with atrial fibrillation.[37] Notably, recent studies have found significant differences between systolic and diastolic myocardial blood flow estimates with perfusion CMR,[18,38] and the choice of either cardiac phase for 3D myocardial perfusion may, therefore, be of physiological interest or relevant to certain disease processes, such as hypertrophic cardiomyopathy.[37,39]

Therefore, 3D myocardial perfusion CMR is a highly promising development, and recent studies have shown it to be clinically feasible, highly accurate, and to have a potential role in the assessment and follow-up of ischemic burden.[14–17] In the first clinical study of 3D perfusion CMR, Manka et al[15] evaluated 146 patients with suspected CAD using *k-t* acceleration to achieve 16-slice coverage and an

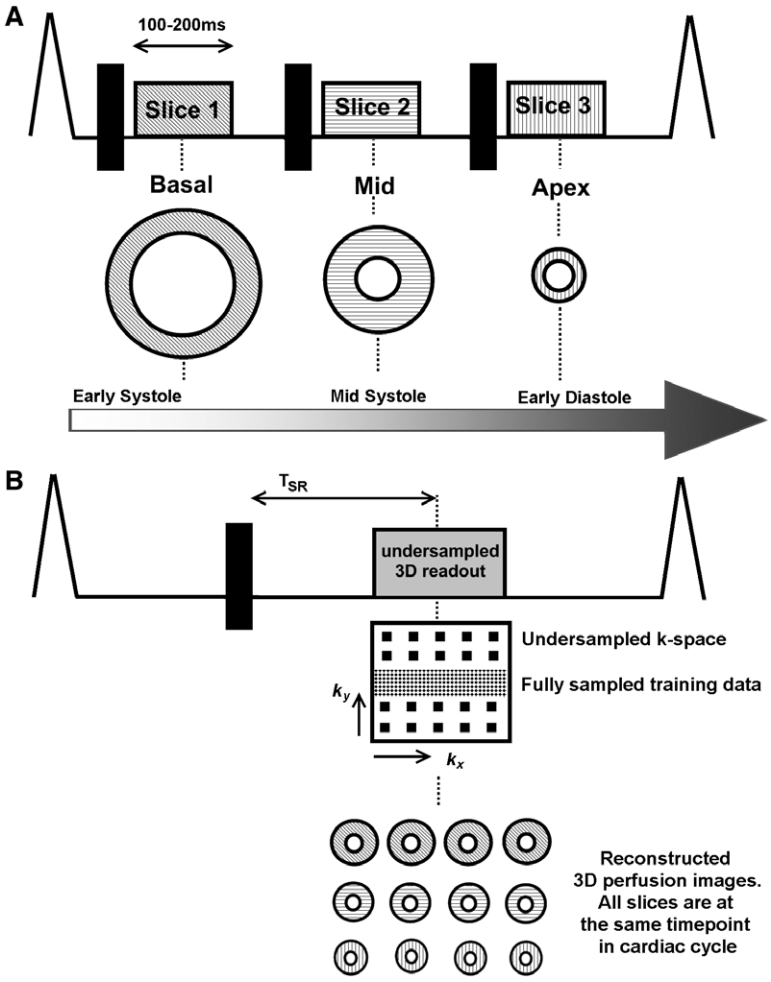

Figure 3. Pulse sequence diagrams for 2-dimensional (2D) and 3D perfusion cardiovascular magnetic resonance (CMR). In 2D perfusion CMR (**A**), 3 to 4 noncontiguous slices are acquired in different phases of the cardiac cycle to maximize spatial coverage. Each slice is acquired after a saturation prepulse (black bar). A shared prepulse can be used to save time but results in different contrast characteristics for each slice. In 3D perfusion CMR (**B**), a single saturation prepulse is followed by a saturation recovery time (T_{SR}) and undersampled 3D perfusion data readout. The use of advanced spatiotemporal undersampling allows sufficient data acquisition to reconstruct 12 to 16 contiguous slices, that is, whole-heart coverage. The training data are acquired with the undersampled data in an interleaved fashion. Because all perfusion data in the 3D technique are acquired at the same point in the cardiac cycle, the reconstructed slices all appear in the same cardiac phase.

Downloaded from http://ahajournals.org by on February 24, 2022

in-plane spatial resolution of 2.3 mm. Image quality was consistently high, and the overall sensitivity, specificity, and diagnostic accuracy to detect significant CAD (quantitative coronary angiography ≥50%) were 92%, 74%, and 83%, respectively, comparable with conventional 2D perfusion CMR.[1] Furthermore, myocardial ischemic burden (expressed as a percentage of left ventricle myocardial hypoenhancement to total left ventricle myocardium) was calculated from 3D perfusion CMR data (Figure 4). In 48 patients who had a repeat scan after PCI, there was a relative reduction in myocardial ischemic burden of 79±25%, highlighting the potential role of 3D perfusion CMR to monitor the response to anti-ischemic therapies serially.[15] In addition, the quantification of ischemic burden using myocardial hypoenhancement volumetry (with an arbitrary signal intensity threshold of 2 standard deviations below remote myocardium) was found to be highly reproducible on intrareader and inter-reader assessment.

Although the previous study used quantitative coronary angiography ≥50% as the reference standard for CAD, 2 recent studies (1 at 1.5 T and 1 at 3.0 T) have validated 3D perfusion CMR against FFR and shown high-diagnostic accuracy of the method.[16,17] In a study by Manka et al,[16] 3D perfusion CMR at 1.5 T was found to have a sensitivity, specificity, and diagnostic accuracy of 90%, 82%, and 87%, respectively. At 3.0 T, a study by Jogiya et al[17] found similar figures of 91%, 90%, and 91%, respectively. Both of these studies further verified the feasibility and reproducibility of ischemic burden quantification using volumetry of myocardial hypoenhancement. In addition, Manka et al also found that the quantified myocardial ischemic burden had a high-diagnostic accuracy (AUC=0.90) for identifying FFR-defined CAD, with an optimal cutoff value of >4.4%.[16]

Although FFR is widely considered the invasive reference standard for determining the hemodynamic significance of a coronary stenosis, it does not provide any information about the magnitude of consequent ischemia. This deficiency highlights a potential role for 3D perfusion CMR, and in both of the validation studies against FFR, it demonstrated a higher ischemic burden with proximal lesions compared with distal lesions.[16,17] Furthermore, Jogiya et al[17] found a strong correlation (r=0.82; 95% confidence interval, 0.70–0.89; P<0.0001) between the myocardial ischemic burden on 3D perfusion CMR and the Duke Jeopardy score, which is a validated invasive assessment of ischemic burden based on lesion severity and location.

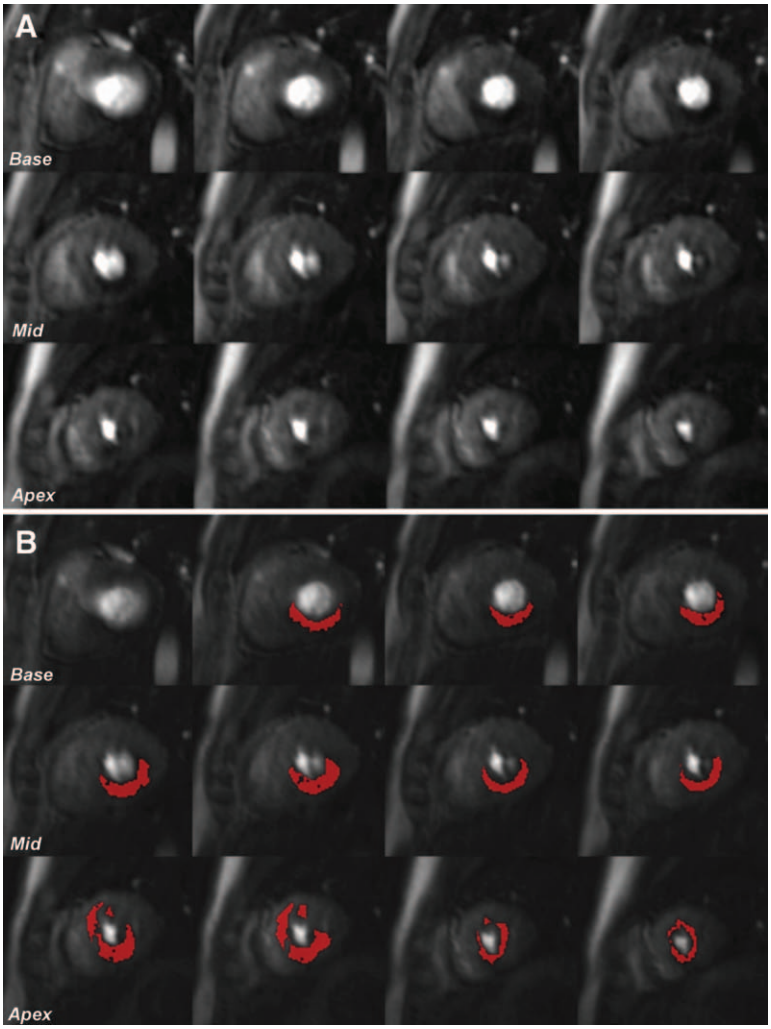

Figure 4. Myocardial ischemic burden quantification with 3-dimensional (3D) perfusion cardiovascular magnetic resonance (CMR). **A**, Shows consecutive slices of a 3D perfusion CMR scan during adenosine stress in a patient with significant stenoses in the proximal right coronary artery and distal left anterior descending coronary artery. **B**, Shows identical images illustrating volumetry of myocardial hypoenhancement using a signal intensity threshold of 2 SDs below remote myocardium (red areas). The volume of myocardial hypoenhancement was 20.4% of total myocardium.

Downloaded from http://ahajournals.org by on February 24, 2022

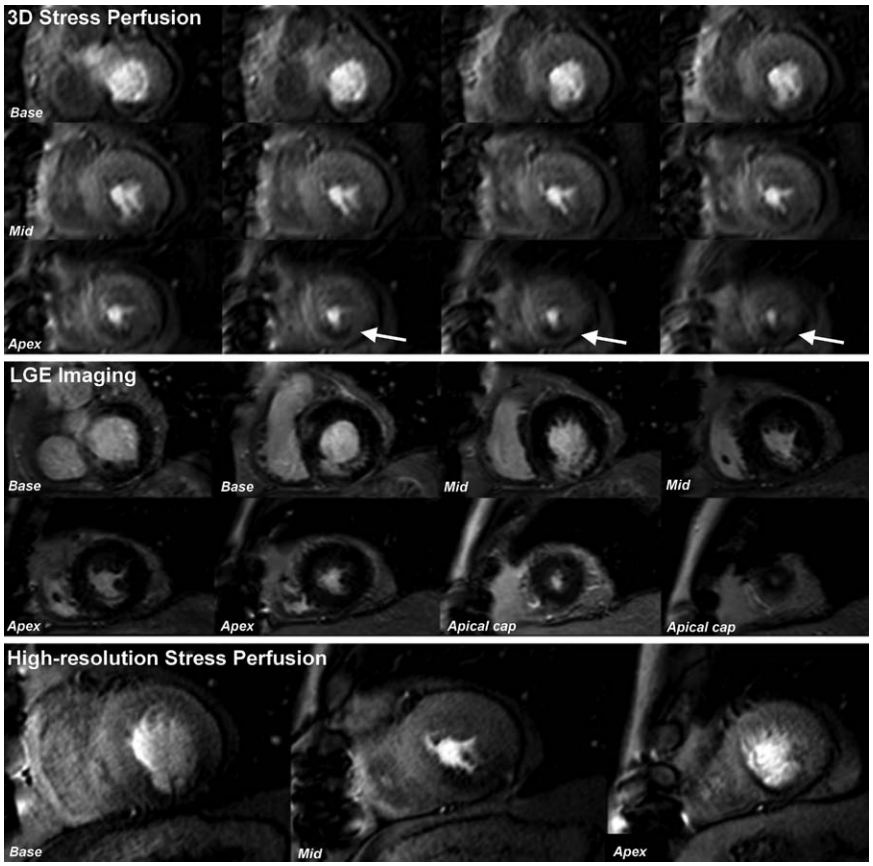

Figure 5. Case example 1. A 62-year-old man with a history of previous bypass surgery 10 years ago, presented with increasing angina. The **top** panel dimensional shows 3-dimensional (3D) perfusion cardiovascular magnetic resonance (CMR) at stress (2.5 mm in-plane resolution, 12 slices); the **middle** panel shows late-gadolinium enhancement (LGE) imaging (1.5 mm in-plane resolution); and the **bottom** panel shows high-resolution stress perfusion CMR (1.1 mm in-plane resolution, 3 slices), all performed on the same patient at 3.0 T. Both 3D perfusion and high-resolution techniques show inferior perfusion defects from base to apex. The benefit of whole-heart coverage with the 3D technique is demonstrated in this case, because hypoperfusion is seen to extend beyond the scar into the apical cap (**top**, **arrows**), which is not covered by the 3-slice high-resolution technique. On the other hand, the perfusion defects and their transmural extent are better delineated with the high-resolution technique, particularly at the mid-ventricular level. By virtue of their similar in-plane spatial resolution, it is easier to correlate LGE images with high-resolution perfusion CMR on a per slice basis compared with the 3D technique.

Downloaded from http://ahajournals.org by on February 24, 2022

Limitations of Highly Accelerated Perfusion CMR

k-t techniques add complexity to the acquisition of perfusion CMR, and they are sensitive to respiratory motion and cardiac arrhythmias. To reduce respiration-related artifacts when using these techniques, fewer dynamic images tend to be acquired compared with conventional methods, and more emphasis is placed on respiratory coaching.[8] The acquisition of fewer dynamic images does, however, confer a risk of inadequate temporal sampling of myocardial contrast passage, particularly if there is significant arrhythmia, and therefore patients with arrhythmia may not be ideal for these techniques. In practice, the breath-hold capacity of patients can be maximized by clear breathing instructions, trial runs, and acquisition in inspiration. Alternative strategies are shallow respiration throughout the acquisition or a more focused breath-hold during myocardial contrast passage.[10] Previous studies have shown that in compliant patients, respiratory artifacts are rare and tend to occur at the end of a breath-hold; if the timing of the acquisition is correctly synchronized to the breath-hold command, such artifacts rarely interfere with image interpretation.[8,12,13] Furthermore, recent improvements, such as *k-t* principal component analysis, are less sensitive to respiratory motion and improve temporal fidelity (compared with *k-t* SENSE and *k-t* BLAST reconstructions that can suffer from temporal blurring), because image reconstruction is constrained using temporal basis functions derived from the low-resolution training data acquired in every heartbeat.[40] Advanced motion correction techniques that allow free-breathing throughout acquisition are also in development.[41]

A further limitation is that the described reconstruction techniques all assume the heart remains entirely static, but there are of course small movements throughout the cardiac cycle that can cause motion-related artifacts, including dark-rim artifact. 3D acquisition is more vulnerable to motion-related artifact than 2D acquisition, as well as respiratory artifact, because of its larger temporal footprint (length of acquisition is ≈200 ms for 3D compared with <100 ms for most 2D acquisitions).

Finally, and this applies to all undersampling methods, reducing the number of sampled data points leads to an SNR reduction that is proportional to $1/\sqrt{R}$, where R is the acceleration factor.[5] In *k-t* methods, the actual SNR reduction may, however, be much less if the dynamics of the object are highly correlated in successive time frames.[42]

High-Spatial Resolution or Full Cardiac Coverage?

Whether the benefits of high-spatial resolution, such as detection of subendocardial ischemia and reduction of dark-rim artifact, outweigh the potential benefits of whole-heart coverage, including more reliable ischemia quantification, is a complex and as yet unanswered question. Initial studies, albeit in selected and small patient populations, suggest that the diagnostic accuracy of the 2 approaches is similar, but there has not yet been a direct head-to-head comparison, and further large-scale studies are required.[10,12,16,17] In clinical practice,

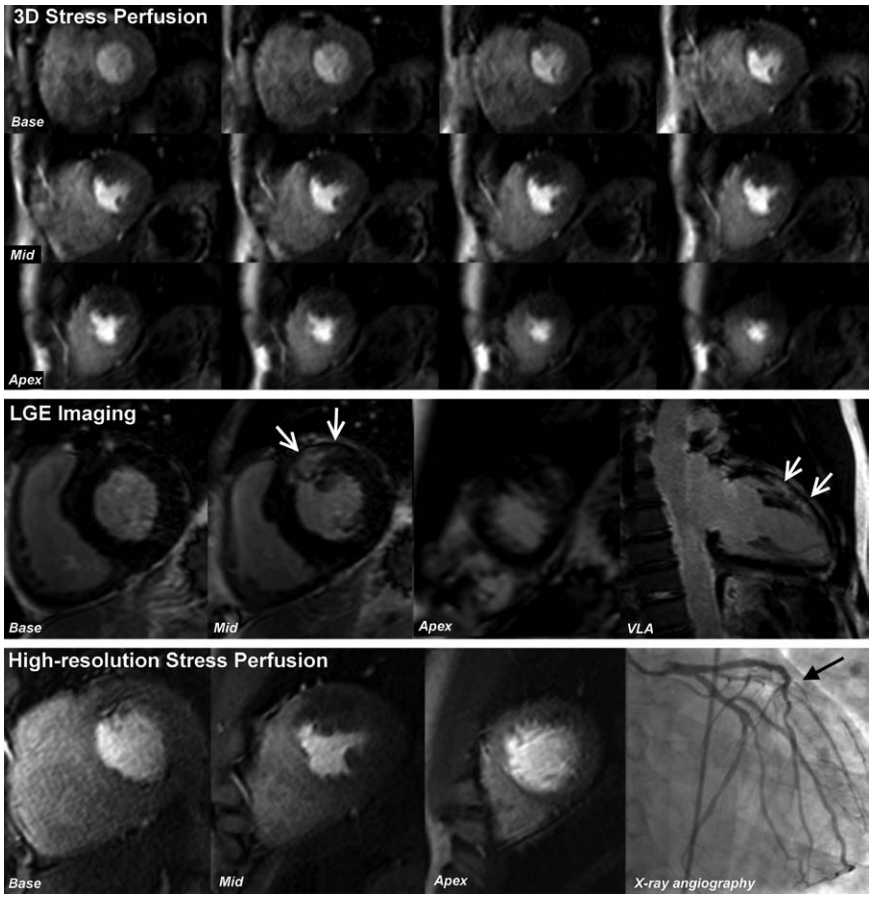

Figure 6. Case example 2. A 45-year-old man with previous PCI to the LAD represented with significant angina. The **top** panel dimensional shows 3-dimensional (3D) perfusion cardiovascular magnetic resonance (CMR; 12 slices) at stress; the **middle** panel shows late-gadolinium enhancement (LGE) imaging; and the **bottom** panel shows high-resolution (1.1 mm in-plane) stress perfusion CMR, all performed at 3.0 T. 3D perfusion CMR shows stress-induced hypoperfusion throughout the anterior wall from base to apex, that is, well beyond the area of scar seen in the mid-anterior wall on LGE imaging. This example shows the benefit of whole-heart coverage with the 3D acquisition, because the 3-slice high-resolution techniques did not demonstrate any significant ischemia beyond the established scar in the mid-ventricle. X-ray angiography confirmed a subtotal occlusion of a large diagonal branch, accounting for the anterior ischemia (black **arrow**). LAD indicates left anterior descending artery; PCI, percutaneous coronary intervention; and VLA, vertical long axis.

Downloaded from http://ahajournals.org by on February 24, 2022

the 2 different approaches may have specific benefits for individual patients. In a patient with a de novo suspicion of CAD, the available limited data on diagnostic accuracy suggest that either technique, or indeed standard-resolution perfusion CMR, would be appropriate choices. However, in a patient who has already undergone angiography and is found to have diffuse multivessel disease with possible PCI targets, high-resolution acquisition might be favorable on account of its ability to detect subendocardial ischemia in the presence of balanced ischemia (Figure 2). In patients with a history of myocardial infarction and suspected peri-infarct ischemia, a 3D perfusion scan may better allow matching of late-gadolinium enhancement and perfusion images over the entire heart with more reliable quantification of peri-infarct ischemia, rather than an assumption based on 3 sparse slices. Figures 5–8 show examples of patients undergoing both acquisitions, and the relative merits (Table 2) of both techniques are discussed in each case.

An alternative strategy to either high-resolution or whole-heart coverage would be to divide the speed-up afforded by acceleration techniques between spatial resolution and cardiac coverage. However, at present, there is insufficient data to define the optimal compromise between these parameters adequately. The subendocardial layer is the most vulnerable to ischemia, and therefore sufficient spatial resolution to resolve a transmural perfusion gradient is preferable, and this remains a significant advantage of CMR over single-photon emission computed tomography (SPECT).[1] However, it is unclear how far this notion needs to be taken or whether the spatial resolution used in recent large-scale studies is sufficient, particularly given the high levels of diagnostic performance. Only a large-scale clinical study comparing acquisitions of varying spatial resolution and differing degrees of cardiac coverage can answer this question. Furthermore, whether an optimal compromise is best acquired throughout the cardiac cycle with a multislice 2D approach, en bloc with a 3D approach or with newer techniques, such as HYPR, would also have to be determined. Finally, beyond studies of diagnostic accuracy, we also need to evaluate whether the various approaches differ in their quantification of ischemic burden, particularly given the increasing use of CMR for this purpose in clinical studies and for accurate prognostic information.[43]

In this review, we have deliberately focused on the visual analysis of perfusion CMR, because it remains the most common method of interpretation in clinical practice. However, quantitative methods for the estimation of myocardial blood flow from conventional myocardial perfusion CMR data have been clinically validated.[44] We have shown in previous studies that quantitative analysis of high-resolution perfusion data acquired with high spatiotemporal undersampling methods is also feasible and offers additional intriguing opportunities, such as quantitation of transmural perfusion gradients.[11,31] However, the algorithms applied for the reconstruction of high-resolution and 3D perfusion CMR data acquired with spatiotemporal undersampling methods give rise to a degree of low-pass temporal filtering, posing additional challenges for quantitative assessment. Quantitative analysis of 3D perfusion

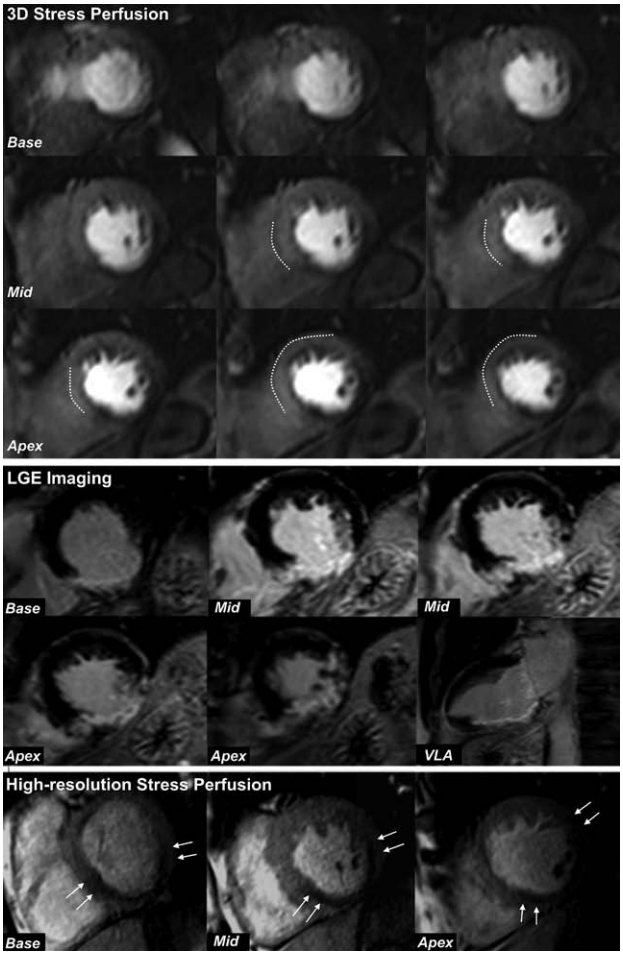

Figure 7. Case Example 3. A 57-year-old man presented with worsening angina after a myocardial infarction 6 months ago. The **top** panel shows stress 3-dimensional (3D) perfusion cardiovascular magnetic resonance (CMR; 12 slices); the **middle** panel shows late-gadolinium enhancement (LGE) imaging; and the **bottom** panel shows high-resolution (1.1 mm in-plane) stress perfusion CMR, all performed at 3.0 T. Both 3D perfusion and high-resolution perfusion techniques show an inferior perfusion defect from base to apex consistent with the infarction seen on LGE imaging. However, the perfusion defects are better delineated at high-resolution and a small amount of peri-infarct ischemia can be seen in each of the 3 slices (**arrows**) beyond the established scar on corresponding LGE images. With 3D acquisition, the lower spatial resolution (2.5 mm in-plane) means that the borders of the perfusion defect within each slice are less distinct and are more difficult to distinguish from dark-rim artifact in the mid-to-apical anteroseptal regions (endocardial border opposite dashed lines). VLA indicates vertical long axis.

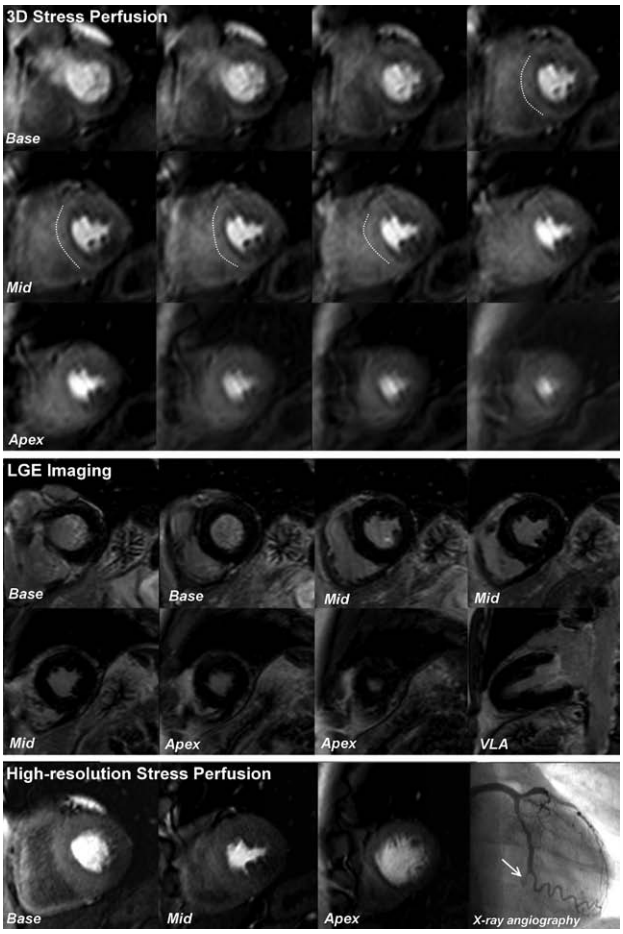

Figure 8. Case example 4. The **top** panel dimensional shows stress 3-dimensional (3D) perfusion cardiovascular magnetic resonance (CMR; 12 slices); the **middle** panel shows late-gadolinium enhancement imaging; and the **bottom** panel shows high-resolution (1.1 mm in-plane) stress perfusion CMR, all performed at 3.0 T. The 3D technique demonstrated significant stress-induced hypoperfusion in the inferior wall from base to apex and extending into the basal inferolateral segments; but there was also significant dark-rim artifact in the septum (endocardial border opposite dashed lines). X-ray angiography confirmed total occlusion of the mid left circumflex artery (**arrow**). Because of the sparsity of coverage, the 3-slice high-resolution technique only detected a significant perfusion defect at the mid-ventricular level, and therefore significantly underestimated the ischemic burden in this case compared with the 3D technique. Additionally, interpretation of the apical high-resolution slice is difficult because it is significantly more diastolic than the other slices, which is a disadvantage of all 2D acquisitions that use a single-shot technique. By comparison, with 3D perfusion CMR, all slices are acquired at the same point in the cardiac cycle, which makes it easier to determine the extent of perfusion defects across different myocardial sections. VLA indicates vertical long axis.

Downloaded from http://ahajournals.org by on February 24, 2022

data has not yet been reported, and therefore a comparison of myocardial blood flow estimates from standard-resolution, high-resolution, and 3D whole-heart perfusion data must be reserved for a future discussion.

Conclusion

The application of advanced acceleration techniques in perfusion CMR has led to 2 highly accurate alternative strategies with distinct advantages. Based on current evidence, it is not clear whether high-resolution or 3D whole-heart coverage offers greater clinical benefit, and large comparative studies are needed to address this question. However, where expertise in both exist, the choice between high-resolution and 3D perfusion CMR already gives us the opportunity to tailor the type of perfusion sequence used to an individual patient to best answer specific clinical questions. Finally, future developments may lead to an acquisition with the optimal balance of spatial resolution and cardiac coverage, but further research is first needed to determine the minimum number of slices required for accurate estimation of ischemic burden and the

Table 2. Relative Merits of High-Resolution and 3D Whole-Heart Perfusion CMR

High-Resolution Perfusion CMR	3D Whole-Heart Perfusion CMR
Greater detection of subendocardial ischemia[12]	Assesses true extent of perfusion defects[14]
Less dark-rim artifact[12,13]	High SNR[14]
Similar spatial resolution to LGE imaging	Single selected phase for all slices
Quantitative analysis of TPG[31]	Quantitative assessment of MIB[16,17]

3D indicates 3-dimensional; CMR, cardiovascular magnetic resonance; LGE, late-gadolinium enhancement; MIB, myocardial ischemic burden; SNR, signal-to-noise ratio; and TPG, transmural perfusion gradient.

level of spatial resolution required to optimally detect clinically significant ischemia.

Acknowledgments

We thank Gavin Bainbridge, Margaret Saysell, and Caroline Richmond (radiographers) for their technical assistance; and Petra Bijsterveld and Fiona Richards (research nurses) for their assistance with patient recruitment.

Sources of Funding

Dr Plein is funded by a British Heart Foundation fellowship (FS/10/62/28409).

Disclosures

Drs Plein and Greenwood receive an educational research grant from Philips Healthcare.

References

1. Greenwood JP, Maredia N, Younger JF, Brown JM, Nixon J, Everett CC, Bijsterveld P, Ridgway JP, Radjenovic A, Dickinson CJ, Ball SG, Plein S. Cardiovascular magnetic resonance and single-photon emission computed tomography for diagnosis of coronary heart disease (CE-MARC): a prospective trial. *Lancet*. 2012;379:453–460.
2. Schwitter J, Wacker CM, van Rossum AC, Lombardi M, Al-Saadi N, Ahlstrom H, Dill T, Larsson HB, Flamm SD, Marquardt M, Johansson L. MR-IMPACT: comparison of perfusion-cardiac magnetic resonance with single-photon emission computed tomography for the detection of coronary artery disease in a multicentre, multivendor, randomized trial. *Eur Heart J*. 2008;29:480–489.
3. Schwitter J, Wacker CM, Wilke N, Al-Saadi N, Sauer E, Huettle K, Schönberg SO, Luchner A, Strohm O, Ahlstrom H, Dill T, Hoebel N, Simor T. MR-IMPACT II: Magnetic Resonance Imaging for Myocardial Perfusion Assessment in Coronary artery disease Trial: perfusion-cardiac magnetic resonance vs. single-photon emission computed tomography for the detection of coronary artery disease: a comparative multicentre, multivendor trial. *Eur Heart J*. March 4, 2012. doi:10.1093/eurheartj/ehs022: http://eurheartj.oxfordjournals.org. Accessed February 10, 2013.
4. Hamon M, Fau G, Née G, Ehtisham J, Morello R, Hamon M. Meta-analysis of the diagnostic performance of stress perfusion cardiovascular magnetic resonance for detection of coronary artery disease. *J Cardiovasc Magn Reson*. 2010;12:29.
5. Kozerke S, Plein S. Journal of Cardiovascular Magnetic Accelerated CMR using zonal, parallel and prior knowledge driven imaging methods. *J Cardiovasc Magn Reson*. 2008;18:1–18.
6. Motwani M, Lockie T, Greenwood JP, Plein S. Accelerated, high spatial resolution cardiovascular magnetic resonance myocardial perfusion imaging. *J Nucl Cardiol*. 2011;18:952–958.
7. Tsao J, Kozerke S. MRI temporal acceleration techniques. *J Magn Reson Imaging*. 2012;36:543–560.
8. Plein S, Kozerke S, Suerder D, Luescher TF, Greenwood JP, Boesiger P, Schwitter J. High spatial resolution myocardial perfusion cardiac magnetic resonance for the detection of coronary artery disease. *Eur Heart J*. 2008;29:2148–2155.
9. Plein S, Schwitter J, Suerder D, Greenwood JP, Boesiger P, Kozerke S. k-Space and time sensitivity encoding-accelerated myocardial perfusion MR imaging at 3.0 T: comparison with 1.5 T. *Radiology*. 2008;249:493–500.
10. Manka R, Vitanis V, Boesiger P, Flammer AJ, Plein S, Kozerke S. Clinical feasibility of accelerated, high spatial resolution myocardial perfusion imaging. *J Am Coll Cardiol Cardiovasc Imaging*. 2010;3:710–717.
11. Lockie T, Ishida M, Perera D, Chiribiri A, De Silva K, Kozerke S, Marber M, Nagel E, Rezavi R, Redwood S, Plein S. High-resolution magnetic resonance myocardial perfusion imaging at 3.0-Tesla to detect hemodynamically significant coronary stenoses as determined by fractional flow reserve. *J Am Coll Cardiol*. 2011;57:70–75.
12. Motwani M, Maredia N, Fairbairn TA, Kozerke S, Radjenovic A, Greenwood JP, Plein S. High-resolution versus standard-resolution cardiovascular magnetic resonance myocardial perfusion imaging for the detection of coronary artery disease. *Circ Cardiovasc Imaging*. 2012;5:306–313.
13. Maredia N, Radjenovic A, Kozerke S, Larghat A, Greenwood JP, Plein S. Effect of improving spatial or temporal resolution on image quality and quantitative perfusion assessment with k-t SENSE acceleration in first-pass CMR myocardial perfusion imaging. *Magn Reson Med*. 2010;64:1616–1624.
14. Shin T, Hu HH, Pohost GM, Nayak KS. Three dimensional first-pass myocardial perfusion imaging at 3T: feasibility study. *J Cardiovasc Magn Reson*. 2008;10:57.
15. Manka R, Jahnke C, Kozerke S, Vitanis V, Crelier G, Gebker R, Schnackenburg B, Boesiger P, Fleck E, Paetsch I. Dynamic 3-dimensional stress cardiac magnetic resonance perfusion imaging: detection of coronary artery disease and volumetry of myocardial hypoenhancement before and after coronary stenting. *J Am Coll Cardiol*. 2011;57:437–444.
16. Manka R, Paetsch I, Kozerke S, Moccetti M, Hoffmann R, Schroeder J, Reith S, Schnackenburg B, Gaemperli O, Wissmann L, Wyss CA, Kaufmann PA, Corti R, Boesiger P, Marx N, Lüscher TF, Jahnke C. Whole-heart dynamic three-dimensional magnetic resonance perfusion imaging for the detection of coronary artery disease defined by fractional flow reserve: determination of volumetric myocardial ischaemic burden and coronary lesion location. *Eur Heart J*. 2012;33:2016–2024.
17. Jogiya R, Kozerke S, Morton G, De Silva K, Redwood S, Perera D, Nagel E, Plein S. Validation of dynamic 3-dimensional whole heart magnetic resonance myocardial perfusion imaging against fractional flow reserve for the detection of significant coronary artery disease. *J Am Coll Cardiol*. 2012;60:756–765.
18. Motwani M, Fairbairn TA, Larghat A, Mather AN, Biglands JD, Radjenovic A, Greenwood JP, Plein S. Systolic versus diastolic acquisition in myocardial perfusion MR imaging. *Radiology*. 2012;262:816–823.
19. Chen GH, Tang J, Leng S. Prior image constrained compressed sensing (PICCS): a method to accurately reconstruct dynamic CT images from highly undersampled projection data sets. *Med Phys*. 2008;35:660–663.
20. Christian BT, Vandehey NT, Floberg JM, Mistretta CA. Dynamic PET denoising with HYPR processing. *J Nucl Med*. 2010;51:1147–1154.
21. Plein S, Ryf S, Schwitter J, Radjenovic A, Boesiger P, Kozerke S. Dynamic contrast-enhanced myocardial perfusion MRI accelerated with k-t sense. *Magn Reson Med*. 2007;58:777–785.
22. Tsao J, Boesiger P, Pruessmann KP. k-t BLAST and k-t SENSE: dynamic MRI with high frame rate exploiting spatiotemporal correlations. *Magn Reson Med*. 2003;50:1031–1042.
23. Ge L, Kino A, Griswold M, Mistretta C, Carr JC, Li D. Myocardial perfusion MRI with sliding-window conjugate-gradient HYPR. *Magn Reson Med*. 2009;62:835–839.
24. Mistretta CA, Wieben O, Velikina J, Block W, Perry J, Wu Y, Johnson K, Wu Y. Highly constrained backprojection for time-resolved MRI. *Magn Reson Med*. 2006;55:30–40.
25. Ma H, Yang J, Liu J, Ge L, An J, Tang Q, Li H, Zhang Y, Chen D, Wang Y, Liu J, Liang Z, Lin K, Jin L, Bi X, Li K, Li D. Myocardial perfusion magnetic resonance imaging using sliding-window conjugate-gradient highly constrained back-projection reconstruction for detection of coronary artery disease. *Am J Cardiol*. 2012;109:1137–1141.
26. Salerno M, Sica CT, Kramer CM, Meyer CH. Optimization of spiral-based pulse sequences for first-pass myocardial perfusion imaging. *Magn Reson Med*. 2011;65:1602–1610.
27. Shin T, Nayak KS, Santos JM, Nishimura DG, Hu BS, McConnell MV. Three-dimensional first-pass myocardial perfusion MRI using a stack-of-spirals acquisition. *Magn Reson Med*. May 3, 2012. doi:10.1002/mrm.24303.

Downloaded from http://ahajournals.org by on February 24, 2022

28. Chen L, Adluru G, Schabel MC, McGann CJ, Dibella EV. Myocardial perfusion MRI with an undersampled 3D stack-of-stars sequence. *Med Phys*. 2012;39:5204–5211.
29. Di Bella EV, Parker DL, Sinusas AJ. On the dark rim artifact in dynamic contrast-enhanced MRI myocardial perfusion studies. *Magn Reson Med*. 2005;54:1295–1299.
30. Bache RJ, Schwartz JS. Effect of perfusion pressure distal to a coronary stenosis on transmural myocardial blood flow. *Circulation*. 1982;65:928–935.
31. Hautvast GL, Chiribiri A, Lockie T, Breeuwer M, Nagel E, Plein S. Quantitative analysis of transmural gradients in myocardial perfusion magnetic resonance images. *Magn Reson Med*. 2011;66:1477–1487.
32. Tonino PA, Fearon WF, De Bruyne B, Oldroyd KG, Leesar MA, Ver Lee PN, Maccarthy PA, Van't Veer M, Pijls NH. Angiographic versus functional severity of coronary artery stenoses in the FAME study fractional flow reserve versus angiography in multivessel evaluation. *J Am Coll Cardiol*. 2010;55:2816–2821.
33. Watkins S, McGeoch R, Lyne J, Steedman T, Good R, McLaughlin MJ, Cunningham T, Bezlyak V, Ford I, Dargie HJ, Oldroyd KG. Validation of magnetic resonance myocardial perfusion imaging with fractional flow reserve for the detection of significant coronary heart disease. *Circulation*. 2009;120:2207–2213.
34. Brown KA, Boucher CA, Okada RD, Guiney TE, Newell JB, Strauss HW, Pohost GM. Prognostic value of exercise thallium-201 imaging in patients presenting for evaluation of chest pain. *J Am Coll Cardiol*. 1983;1:994–1001.
35. Hachamovitch R, Berman DS, Shaw LJ, Kiat H, Cohen I, Cabico JA, Friedman J, Diamond GA. Incremental prognostic value of myocardial perfusion single photon emission computed tomography for the prediction of cardiac death: differential stratification for risk of cardiac death and myocardial infarction. *Circulation*. 1998;97:535–543.
36. Elkington AG, Gatehouse PD, Prasad SK, Moon JC, Firmin DN, Pennell DJ. Combined long- and short-axis myocardial perfusion cardiovascular magnetic resonance. *J Cardiovasc Magn Reson*. 2004;6: 811–816.
37. Shin T, Pohost GM, Nayak KS. Systolic 3D first-pass myocardial perfusion MRI: comparison with diastolic imaging in healthy subjects. *Magn Reson Med*. 2010;63:858–864.
38. Radjenovic A, Biglands JD, Larghat A, Ridgway JP, Ball SG, Greenwood JP, Jerosch-Herold M, Plein S. Estimates of systolic and diastolic myocardial blood flow by dynamic contrast-enhanced MRI. *Magn Reson Med*. 2010;64:1696–1703.
39. Rakowski H, Carasso S. Quantifying diastolic function in hypertrophic cardiomyopathy: the ongoing search for the holy grail. *Circulation*. 2007;116:2662–2665.
40. Pedersen H, Kozerke S, Ringgaard S, Nehrke K, Kim WY. k-t PCA: temporally constrained k-t BLAST reconstruction using principal component analysis. *Magn Reson Med*. 2009;62:706–716.
41. Pedersen H, Kelle S, Ringgaard S, Schnackenburg B, Nagel E, Nehrke K, Kim WY. Quantification of myocardial perfusion using free-breathing MRI and prospective slice tracking. *Magn Reson Med*. 2009;61: 734–738.
42. Gebker R, Jahnke C, Paetsch I, Schnackenburg B, Kozerke S, Bornstedt A, Fleck E, Nagel E. MR myocardial perfusion imaging with k-space and time broad-use linear acquisition speed-up technique: feasibility study. *Radiology*. 2007;245:863–871.
43. Bingham SE, Hachamovitch R. Incremental prognostic significance of combined cardiac magnetic resonance imaging, adenosine stress perfusion, delayed enhancement, and left ventricular function over preimaging information for the prediction of adverse events. *Circulation*. 2011;123:1509–1518.
44. Costa MA, Shoemaker S, Futamatsu H, Klassen C, Angiolillo DJ, Nguyen M, Siuciak A, Gilmore P, Zenni MM, Guzman L, Bass TA, Wilke N. Quantitative magnetic resonance perfusion imaging detects anatomic and physiologic coronary artery disease as measured by coronary angiography and fractional flow reserve. *J Am Coll Cardiol*. 2007;50:514–522.

KEY WORDS: cardiac magnetic resonance imaging ■ ischemic heart disease ■ perfusion imaging

Downloaded from http://ahajournals.org by on February 24, 2022