

## Cardiac Paraganglioma

Pradeep K. Yadav, MD; Giselle A. Baquero, MD; Jozef Malysz, MD; John Kelleman, MD;  
Ian C. Gilchrist, MD

**P**aragangliomas are extraadrenal tumors that arise from chromaffin cells of the sympathetic ganglia. Cardiac paraganglia are exceptionally rare and because of paucity of cohort data, raises dilemmas about management when encountered. Some of them are metabolically active and may present with symptoms of catecholamine excess, whereas some may be incidentally diagnosed. In this report, we discuss the challenges surrounding the diagnosis and management of a cardiac paraganglioma at each stage.

### Case Presentation

A 73-year-old woman is referred by her cardiologist for an elective coronary angiography because of an abnormal stress test in the setting of dyspnea on exertion. The dyspnea started ≈6 months ago and has been slowly progressive. She continues to try to exercise through this and is currently able to walk 1 mile in 30 minutes, a pace that is slower than usual. The medical history is significant for mild edema (hydrochlorothiazide 25 mg/d), dyslipidemia (diet controlled); there is no history of smoking, hypertension, diabetes mellitus, coronary artery disease, or peripheral atherosclerosis. Her family history is notable for coronary artery disease.

On physical examination, the patient's body mass index is 35 (5 ft 0 in; 81.6 kg), blood pressure is 140/70 mmHg with a pulse of 60 bpm. Jugular venous pulse is normal. Carotid upstroke is brisk, and there are no bruits. Lungs are clear to auscultation. The first and the second heart sounds are normal; there are no murmurs, rubs, or gallops. There is no lower extremity edema, and rest of the examination is unremarkable. An ECG demonstrates normal sinus rhythm with possible anteroseptal infarct. A chest radiograph is normal.

The stress echocardiography report shows that the patient exercised for 7:30 minutes on a Bruce protocol achieving a peak heart rate of 146 bpm (99% maximum predicted heart rate) and blood pressure of 180/60 mmHg. The resting heart rate and blood pressure were 71 bpm and 118/60 mm, respectively. The resting ECG showed normal sinus rhythm with possible anteroseptal infarct, and the stress ECG showed sinus tachycardia with nonspecific ST-T wave changes. The resting part of stress echocardiography

showed normal wall motion, and with exercise, the left ventricle became smaller and more vigorous, but the anterior septum and septum failed to become hyperkinetic, and therefore the study was read as an abnormal study. The patient was then referred to a cardiologist for further evaluation. Certainly, the stress test abnormality was not high risk, and a trial of medical therapy with investigation of alternate pathogenesis for dyspnea versus diagnostic coronary angiography was discussed. However, the patient's symptoms were out of proportion to the degree of stress test abnormality, with no other obvious pathogenesis. The patient was concerned about ischemic heart disease in light of not a normal stress test, and decision was made to proceed with a diagnostic coronary angiography.

At this time, the patient undergoes coronary angiography via transradial access using 5F catheters. The coronary arteries are relatively smooth in nature with no angiographic evidence of atherosclerosis. Incidentally, the dominant proximal right coronary artery gives off a large atrial branch, which seems to fill a vascular structure (2×2 cm) near the atrium (Figures 1 and 2). The left ventricular end-diastolic pressure is mildly elevated at 18 mm Hg, and the left ventriculography is essentially normal. No significant mitral regurgitation or aortic stenosis is present.

### Discussion

*Dr Yadav:* A branch of the proximal right coronary artery seems to supply a suspicious structure. What differentials are to be considered at this stage?

*Dr Gilchrist:* In this patient, the atrial branch of the right coronary artery seems larger than one usually expects to see and it seems to feed a well-defined spherical mass, raising the suspicion of a cardiac tumor. About 75% of all cardiac tumors are benign of which about half are myxomas.<sup>1</sup> The other half of benign tumors include lipomas and lipomatous hypertrophy, valvular fibroelastic papillomas, fibromas, hamartomas, and rhabdomyomas.<sup>2</sup> The remaining 25% of cardiac tumors are considered malignant and includes a group comprising various types of sarcomas (angiosarcoma, rhabdomyosarcoma, and leiomyosarcomas) lymphomas, pericardial mesotheliomas, and paragangliomas.<sup>3</sup> Paragangliomas in particular are known for their rich vascular supply.<sup>4</sup> Cardiac masses are

Received July 29, 2014; accepted September 24, 2014.

From the Division of Cardiology, Heart and Vascular Institute (P.K.Y., G.A.B., J.K., I.C.G.) and Department of Anatomic Clinical Pathology and Hematopathology (J.M.), Pennsylvania State University/Milton S Hershey Medical Center, Hershey.

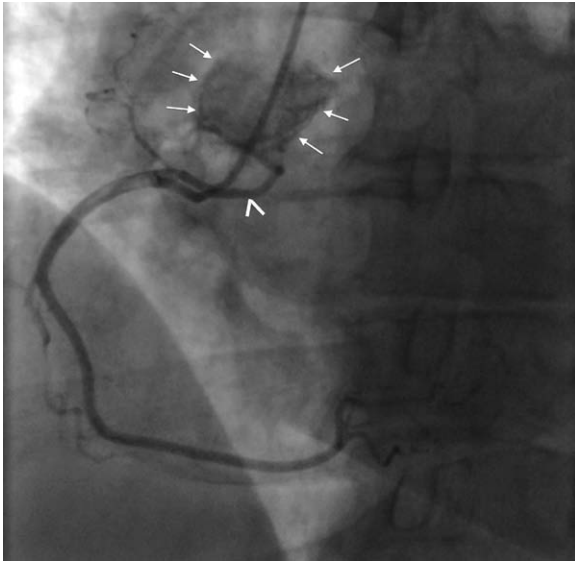
Correspondence to Pradeep K. Yadav, MD, Pennsylvania State University/Milton S Hershey Medical Center, 500 University Dr, C1517, Hershey, PA 17033. E-mail drpyadav@gmail.com

(*Circ Cardiovasc Interv.* 2014;7:851-856.)

© 2014 American Heart Association, Inc.

*Circ Cardiovasc Interv* is available at <http://circinterventions.ahajournals.org>

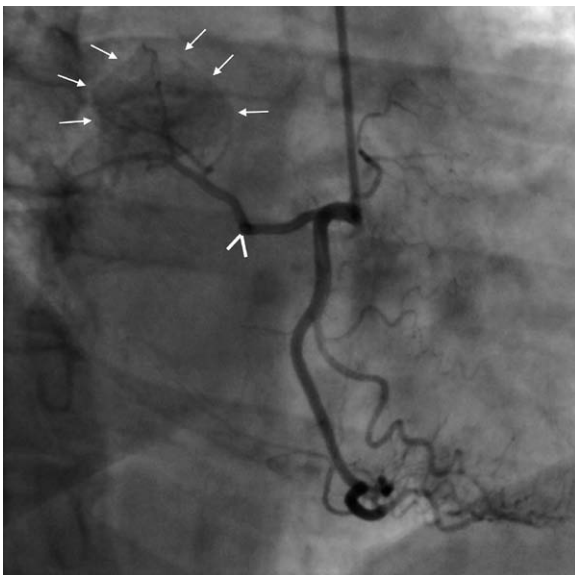
DOI: 10.1161/CIRCINTERVENTIONS.114.001856



**Figure 1.** Left anterior oblique view of the right coronary artery on angiography, atrial branch (arrowhead) supplying a well-circumscribed mass (arrows).

typically picked up by noninvasive imaging studies, and coronary angiography is being done more for operative planning. However, in this case, the initial findings are noted by angiography and not suspected from the preoperative stress echocardiography (however, it was not a complete echocardiographic study and focused only on the wall motion abnormalities for the stress test). At this juncture, we can say from the angiographic images that the patient likely has a tumor in or around the atria with a prominent vascular supply.

*Dr Yadav:* The patient presented with dyspnea on exertion, and we have ruled out coronary artery disease. Do you think this mass is contributing to the patient's presenting complaint or is more of an incidental finding?



**Figure 2.** Right anterior oblique view of the right coronary artery on angiography, atrial branch (arrowhead) supplying a well-circumscribed mass (arrows).

*Dr Gilchrist:* One of the challenges in diagnosing cardiac tumors is their presentation with vague nonspecific symptoms, which can broadly be categorized as systemic manifestations, embolic with intracavitary friable tumors, cardiac (as a result of direct mechanical interference), and metastatic. The systemic manifestations classically are associated with myxomas and maybe associated with frequently elevated levels of serum interleukin-6.<sup>5</sup> These symptoms may include fever, chills, fatigue, and malaise. Hormonally active primary cardiac paragangliomas can present with systemic symptoms of catecholamine excess like hypertension, palpitations, and diaphoresis. Friable, intracardiac tumors may present as an embolic event remote from the heart such as a cerebrovascular accident or peripheral vascular event, and a cardiac pathogenesis might be missed. Hormonally inactive paraganglioma may present with symptoms because of localized mechanical compression of a cardiac chamber<sup>6</sup> or obstruction to normal cardiac flow from within the cardiac chamber. This patient did not offer constitutional symptoms other than dyspnea. Some of the bulky mural tumors can compress coronary arteries and produce ischemia, but this does not seem to be the case here because the mass is high up in the atrium away from the primary epicardial coronary arteries. Further imaging studies will help clarify whether there is compression of other cardiovascular structures or interference with hemodynamics. Catecholamine excess with paragangliomas, causing hypertension and resultant diastolic dysfunction is a possibility with elevated left ventricular end-diastolic pressure on left heart catheterization, however hypertension has not been documented in her outpatient history. We could have investigated further in the catheterization laboratory with a right heart catheterization or right-sided angiograms, but we felt other diagnostic modalities were available and would be more appropriate.

*Dr Yadav:* This mass may or may not be associated with her symptoms, but the differential is broad at this time, ranging from benign to malignant diseases. Therefore, further investigation is necessary. There can be different imaging options ranging from echocardiography, computed tomography (CT), MRI, or nuclear scan. Which one did you choose?

*Dr Gilchrist:* Each of these imaging studies has its own advantages and disadvantages. Echocardiography is universally available, portable, gives an understanding of the physiology but has limited field of view, limited tissue characterization, and the images depend on the acoustic window. In comparison, CT has high resolution, a dynamic display, can differentiate fat versus calcium in tissues, but it comes with the risk of ionizing radiation and iodinated contrast. Nuclear scans may give information regarding biologically active tumors but has poor spatial resolution and also comes with ionizing radiation. MRI has excellent temporal and spatial resolution, tissue characterization, helps understand hemodynamic effects, and has limitless angles with no radiation. However, it is a lengthy examination, may not be available at every facility, and gadolinium use may be a problem in renal failure patients. The diagnostic sensitivity of transthoracic and transesophageal echocardiography for cardiac tumors is 93.3% and 96.8%, respectively,<sup>7</sup> and when combined with ease of availability, may be considered as the initial test. MRI at our institution is not performed every day of the week. This

patient's renal function was within normal limits, and therefore, either CT or transesophageal echocardiography would have been appropriate. This patient underwent transesophageal echocardiography the same day.

**Dr Yadav:** The transesophageal echo shows normal left ventricular size and function, normal left ventricular thickness, mild left atrial dilation, normal right atrium, normal right ventricle, and no significant valvular abnormalities. No intracardiac masses are visualized, and there is no pericardial effusion. Where do we stand now?

**Dr Kelleman:** Based on the location, primary cardiac tumors can be classified into intracavitary, mural, or intrapericardial.<sup>8</sup> The transesophageal echo has ruled out the most common of all tumors, myxoma, other intracavitary, and mural tumors. Now we are most likely left with pericardial tumors; primary pericardial tumors are 40× less common than metastatic tumors.<sup>9</sup> Primary pericardial tumors include malignant tumors like mesotheliomas, sarcomas (fibrosarcomas, liposarcomas, and angiosarcomas), and lymphomas and benign tumors like lipomas, lymphangiomas, hemangiomas, teratomas, fibromas, neurofibromas, and paragangliomas (10% of all paragangliomas can be malignant).<sup>4,10</sup>

**Dr Yadav:** At this point, we still need further imaging to better understand the localization of the tumor, extent of spread, and surrounding structures. This might not only help in shortening the differential list but also in surgical planning if we are going that route. Which modality did you choose and what key things the imager should try to keep in mind?

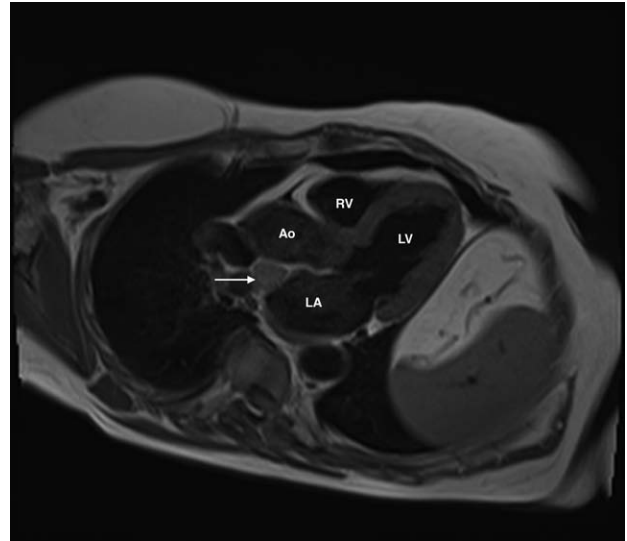
**Dr Kelleman:** Both CT and MRI are useful for further evaluation of these masses. Attenuation on CT, tissue characteristics of MRI, degree of contrast enhancement, and presence or absence of blood flow on cine MRI images can help differentiate among pericardial masses.<sup>11</sup> MRI was chosen for this patient. The key questions while performing MRI for cardiac masses are which sequence to use, which tumors are benign, which tumors are malignant, and differentiation of the mass from normal anatomic variants those mimic tumors.

**Dr Yadav:** What was the sequence of your MRI?

**Dr Kelleman:** Scout imaging in axial, sagittal, and coronal planes were obtained. Axial, sagittal, and coronal static steady state free precession imaging was done. Two-chamber, short axis, 3-chamber, and 4-chamber steady state free precession cine images were subsequently obtained. Cine steady state free precession, T1 and T2 turbo spin echo (with and without fat suppressed) imaging was performed through the mass in multiple planes. Perfusion imaging was performed. Delayed enhancement images were then obtained using 2-dimensional segmented inversion recovery Gradient Echo Sequence (*gradient recalled echo*) imaging in multiple planes.

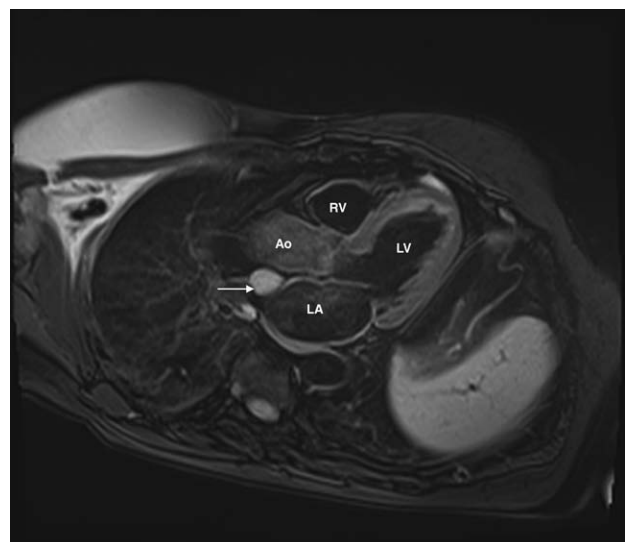
**Dr Yadav:** The MRI showed a well-circumscribed, homogenous mass adjacent to and immediately above the left atrium, below the right pulmonary artery, and posterior to the ascending aorta. It was 20×19×14 mm in size, slightly hyperintense on T1 imaging (Figure 3), hyperintense on T2 imaging (Figures 4 and 5), perfused on first pass imaging, and there was no delayed hyperenhancement (Figure 6). Help us navigate through the differentials.

**Dr Kelleman:** The brisk perfusion on first pass imaging suggests tumor rich in vascular supply, and this further narrows



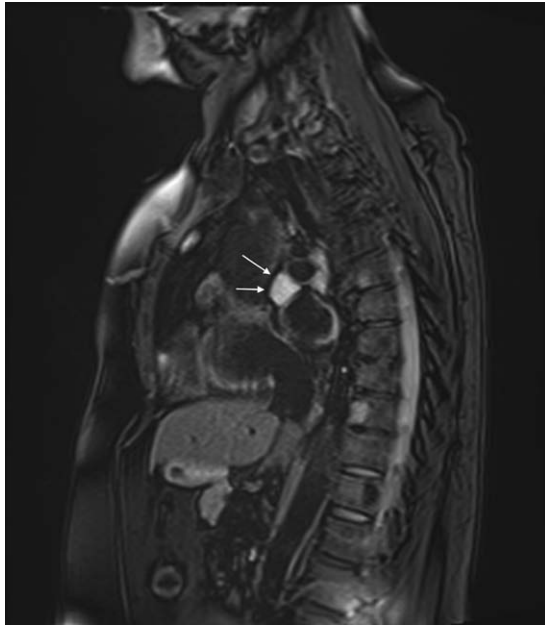**Figure 3.** T1 3-chamber image showing slightly hyperintense mass (arrow). Ao indicates aorta; LA, left atrium; LV, left ventricle; and RV, right ventricle.

the differential to hemangioma, angiosarcoma, or paraganglioma. The hemangiomas are typically intermediate intensity on T1, hyperintense on T2 imaging while the angiosarcomas seem as low-attenuation, invasive, irregular nodular masses.<sup>12</sup> Paragangliomas typically are hyperintense on T2 imaging and most commonly are located on the roof of left atrium like this patient. They can originate from the visceral autonomic (atrium or interatrial septum) paraganglia or the branchiomeric (coronary, pulmonary, and aorticopulmonary) paraganglia. They are found under the aorta and the pulmonary artery in association with the left atrium but can extend into the atrioventricular groove, involve the coronaries and rarely into the ventricles.<sup>13</sup> Based on the MRI findings, Paraganglioma is likely the diagnosis here, but tissue confirmation remains.



**Figure 4.** T2 fat saturated 3-chamber image showing hyperintense mass (arrow). Ao indicates aorta; LA, left atrium; LV, left ventricle; and RV, right ventricle.

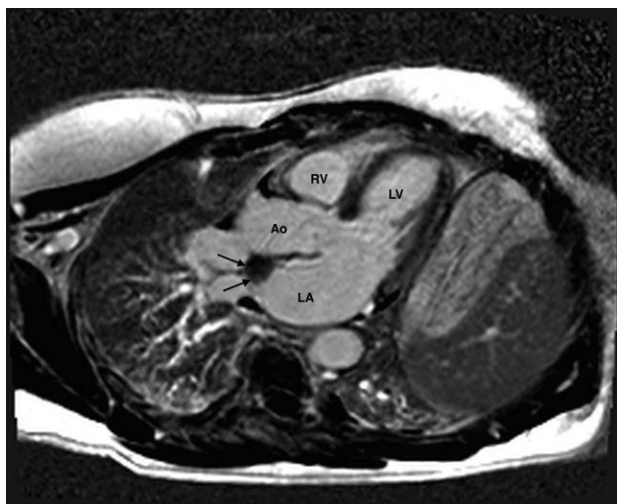



**Figure 5.** T2 fat saturated (sagittal view) image showing hyperintense mass (arrow).

*Dr Yadav:* Should biochemical testing be performed if paraganglioma is suspected?

*Dr Baquero:* In the available literature on cardiac paragangliomas, the percentage of functionally active tumors is extremely variable and ranges between 17% and 79%. In a recent analytic review of 82 case reports, 79% of the cases had elevated levels of serum or urinary catecholamines.<sup>14</sup> In Mayo Clinic's experience of 236 patients with benign paragangliomas, 31% of those screened were biochemically active.<sup>15</sup> Existing screening tests are highly sensitive and specific for the detection of hyper functional tumors and include plasma metanephrine testing (sensitivity 96%, specificity 85%) and 24-hour urinary catecholamines (sensitivity 88%, specificity of 99.7%).<sup>16</sup> Hence, routine levels may be considered checking in cardiac tumor patients with the understanding that



**Figure 6.** No delayed enhancement of the mass (arrow) in a 3-chamber view. Ao indicates aorta; LA, left atrium; LV, left ventricle; and RV, right ventricle.

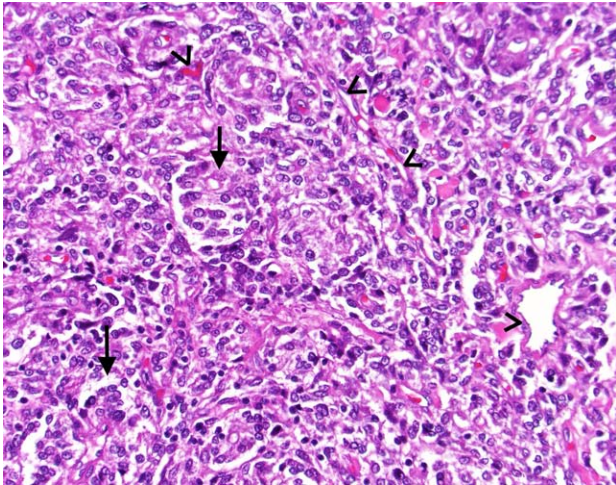
elevated levels may suggest chromaffin cell pathogenesis, but normal levels may not rule it out. Our patient's levels were all within the normal range. Radioactive iodine-labeled metaiodobenzylguanidine scintigraphy has also been used to diagnose these active tumors with reported elevated sensitivities >85% and specificity of 100% as reported by several authors,<sup>17</sup> but in this above mentioned study from Mayo, the false negative rates for metaiodobenzylguanidine was 39%.<sup>15</sup> There have also been some reports of localization of hyper functional paragangliomas with 18F fluorodeoxyglucose, fluorodeoxyglucose-positron emission tomography, and Tc-99m Octreotide scans.<sup>18</sup>

*Dr Yadav:* After all this testing, the diagnosis of this highly vascular intrapericardial mass was still uncertain. How was the decision to proceed with surgery made?

*Dr Gilchrist:* We were inclined that this tumor was probably benign, however, the diagnosis was yet not conclusive, and as referenced above,  $\approx 10\%$  of the paragangliomas could be malignant. Surgical resection is the most effective treatment for paragangliomas and pheochromocytomas.<sup>19</sup> However, a careful decision has to be made, as the resection of paragangliomas can be associated with significant morbidity and mortality. In a large case series, the intraoperative mortality rate was 20% because of hemorrhage as these tumors are highly vascular in nature, and another 16% of the patients experienced a significant complication, such as sepsis or myocardial infarction as a result of close proximity and sometimes encasement of the coronary arteries within the tumor mass.<sup>13</sup> Our patient was introduced to a cardiothoracic surgeon to discuss the risks and benefits of an open resection. After careful discussion, and understandably so, the patient did not want the risk of undiagnosed malignancy and, therefore, opted for surgical resection.

*Dr Yadav:* The Endocrine Society practice guidelines recommend preoperative  $\alpha$ - and  $\beta$ -blockade of hormonally functional pheochromocytomas and paragangliomas. Although biochemical testing is not 100% sensitive in detecting functional tumors, there are no clear guidelines on preoperative management of hormonally inactive normotensive patients (like ours) and therefore the practice varies. The preoperative  $\alpha$ - and  $\beta$ -blockade was not performed in our patient. Intraoperative, after the pericardium was opened, the mass was seen on the roof of the left atrium, anterior and inferior to the right main pulmonary artery between the aorta and superior vena cava. The cardiopulmonary bypass was not required, and the mass was resected with ligation of the coronary artery branch, achieving excellent hemostasis. Let's discuss the pathological analysis.

*Dr Malysz:* The specimen was a 2.4×1.7×1.3 cm rubbery nodule surrounded by a pink-red thin intact capsule. Serial sectioning revealed a homogeneous pink-gray glistening parenchyma without any evidence of necrosis, hemorrhage, or calcifications. Microscopic sections demonstrated well-circumscribed, encapsulated mass composed of uniform cells with fine stippled chromatin pattern and pale eosinophilic cytoplasm arranged in trabecular and organoid growth (Figure 7; hematoxylin and eosin stain). There was no significant pleomorphism and no mitotic or apoptotic activity. Background

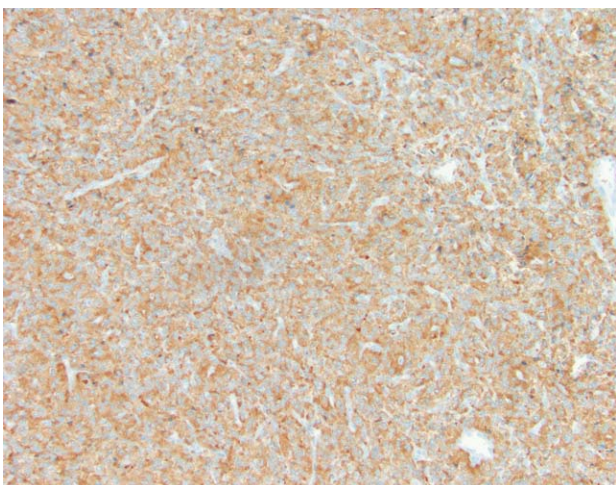


**Figure 7.** Hematoxylin and eosin micrograph showing uniform cells with fine stippled chromatin pattern and pale eosinophilic cytoplasm arranged in trabecular and organoid growth. Arrows point to nests of polygonal tumor cells. Arrowheads point to high vascularity of the tumor.

prominent vascular network separated tumor cells. These morphological features are characteristic of paraganglioma.

*Dr Yadav:* Any specific stains that should be used for these suspected paragangliomas?

*Dr Malysz:* There are number of immunohistochemical stains that can be used to highlight various components of such lesions. Predominant tumor cell is of neuroendocrine origin and stains positive with chromogranin (Figure 8) and synaptophysin, positive in our patient. Second cell types in these lesions are sustentacular cells, which can be highlighted by S-100 immunostains (positive in our patient). CD31 and CD34 may be used to accentuate delicate vascular framework separating tumor nests.<sup>20</sup> Combination of morphology and appropriate staining patterns essentially makes the diagnosis. In our patient, mitoses was not readily seen, and the neoplastic cells were negative for melanocytic antigen recognized by cytotoxic T lymphocytes 1, human melanoma black-45, leukocyte common antigen, CD99, AE1/AE3, desmin, smooth



**Figure 8.** Chromogranin stain: brown pigment highlights chromogranin positive tumor cells.

muscle actin, and CD34. The Ki67 proliferation index was low (<1%).

*Dr Yadav:* Can you comment on benign versus malignant and risk of metastasis based on the pathological analysis?

*Dr Malysz:* It is generally considered a benign tumor and in most instances cured by complete excision. The only sure and undeniable sign of malignant behavior is demonstration of metastases. Screening for localized spread is evaluated on CT or MRI done for understanding tumor anatomy and preoperative planning. Screening for distant metastasis is achievable by full body positron emission tomography or iodine-metaiodobenzylguanidine scans (iodine-metaiodobenzylguanidine scans in biochemically active tumors), but their routine use in preoperative period in every patient is not recommended, unless indicated by patients localizing symptoms. After the surgical resection, screening for metastasis is indicated if the biochemical tests are positive again or if patient develops localizing signs and symptoms. The risk of metastases is low with incidence of malignant transformation at  $\approx 10\%$ .<sup>20</sup> Different outcomes may be expected with familial forms of paraganglioma and when tumor is associated with other abnormalities such as in multiple endocrine neoplasia syndrome, von Hippel-Lindau disease, or as a part of Carney triad.<sup>21</sup>

*Dr Yadav:* What is the survival after surgery and the risk of recurrence in these patients? Do they need to be followed by some sort of imaging or biochemical testing?

*Dr Baquero:* After surgical resection, patients with benign paraganglioma/pheochromocytoma have an overall survival equal to an age-matched normal population. However, patients with malignant pheochromocytoma/paraganglioma have a 5-year survival <50% that of age-matched controls.<sup>22</sup> Metastatic paraganglioma have high rate of recurrence. In a study on abdominal extra adrenal paragangliomas, mean incidence of recurrence was 15% after 5 years and 23% after 10 years.<sup>23</sup> Therefore, annual biochemical testing for  $\geq 10$  years is recommended for functioning (catecholamine producing) paragangliomas that are surgically treated and periodic imaging (CT or MRI or positron emission tomography) for nonfunctioning paragangliomas (like our patient) that are surgically treated.<sup>15,24</sup>

*Dr Yadav:* Are there any other treatment options like chemo/radiation for paragangliomas that are malignant?

*Dr Baquero:* There are no clear guidelines, but combination chemotherapy with cyclophosphamide, vincristine, and dacarbazine has been tried in patients with advanced malignant pheochromocytoma/paraganglioma. Results from a 22-year follow-up study of 18 patients showed significant improvement in blood pressure and tumor shrinkage but no overall survival benefit. The authors of this particular study suggested that cyclophosphamide, vincristine, and dacarbazine therapy should not be indicated in all patients with metastatic pheochromocytoma/paraganglioma but certainly considered in the management of symptomatic patients and patients that may benefit from tumor shrinkage.<sup>25</sup>

*Dr Yadav:* What is the role of genetic testing and should the family members be screened?

*Dr Baquero:* Paragangliomas can be sporadic or familial. The familial paragangliomas have been associated with



various gene mutations, most commonly the succinate dehydrogenase (SDH) complex of the electron transport chain (*SDHB*, *SDHC*, and *SDHD* genes).<sup>26</sup> The mutation carrier has higher risk of malignant disease, and therefore, genetic screening of paraganglioma patients is recommended.<sup>27</sup> If such a mutation is discovered, genetic counseling and testing in family members is advised.<sup>24</sup>

## Clinical Outcome

In our patient, the presenting complaint of dyspnea was not cardiac in pathogenesis, and the diagnosis of paraganglioma was more of an incidental finding. As expected and as explained to the patient in advance (prior to surgery), there was no significant improvement in dyspnea postsurgical resection of the tumor. She recovered well from the surgery and was enrolled in a cardiac rehab program with further evaluation in the outpatient setting. No follow-up surveillance testing for the tumor was available because she was still within the first year of surgery at the time of this report submission.

## Disclosures

None.

## References

- Burke A, Virmani R; Armed Forces Institute of Pathology (U.S.) and Universities Associated for Research and Education in Pathology. *Tumors of the Heart and Great Vessels*. Washington, DC: American Registry of Pathology; 1996.
- Tazelaar HD, Locke TJ, McGregor CG. Pathology of surgically excised primary cardiac tumors. *Mayo Clin Proc*. 1992;67:957–965.
- Vander Salm TJ. Unusual primary tumors of the heart. *Semin Thorac Cardiovasc Surg*. 2000;12:89–100.
- Ramlawi B, David EA, Kim MP, Garcia-Morales LJ, Blackmon SH, Rice DC, Vaporciyan AA, Reardon MJ. Contemporary surgical management of cardiac paragangliomas. *Ann of Thorac Surg*. 2012;93:1972–1976.
- Mendoza CE, Rosado MF, Bernal L. The role of interleukin-6 in cases of cardiac myxoma. Clinical features, immunologic abnormalities, and a possible role in recurrence. *Tex Heart Inst*. 2001;28:3–7.
- Huo JL, Choi JC, DeLuna A, Lee D, Fleischmann D, Berry GJ, Deuse T, Haddad F. Cardiac paraganglioma: diagnostic and surgical challenges. *J Card Surg*. 2012;27:178–182.
- Meng Q, Lai H, Lima J, Tong W, Qian Y, Lai S. Echocardiographic and pathologic characteristics of primary cardiac tumors: a study of 149 cases. *Int J Cardiol*. 2002;84:69–75.
- Goldberg HP, Steinberg I. Primary tumors of the heart. *Circulation*. 1955;11:963–970.
- Maisch B, Seferović PM, Ristić AD, Erbel R, Rienmüller R, Adler Y, Tomkowski WZ, Thiene G, Yacoub MH; Task Force on the Diagnosis and Management of Pericardial Diseases of the European Society of Cardiology. Guidelines on the diagnosis and management of pericardial diseases executive summary; The Task force on the diagnosis and management of pericardial diseases of the European Society of Cardiology. *Eur Heart J*. 2004;25:587–610.
- LeWinter MM, Tischler MD. Pericardial diseases. In: Bonow RO, Mann DL, Zipes DP, Libby P. *Braunwalds Heart Disease*. 9th ed. Philadelphia, PA: Elsevier Saunders; 2012:1651–1671.
- Wang ZJ, Reddy GP, Gotway MB, Yeh BM, Hetts SW, Higgins CB. CT and MR imaging of pericardial disease. *Radiographics*. 2003;23 Spec No:S167–S180.
- Grebenc ML, Rosado de Christenson ML, Burke AP, Green CE, Galvin JR. Primary cardiac and pericardial neoplasms: radiologic-pathologic correlation. *Radiographics*. 2000;20:1073–1103, quiz 1110–1111, 1112.
- Jeevanandam V, Oz MC, Shapiro B, Barr ML, Marboe C, Rose EA. Surgical management of cardiac pheochromocytoma. Resection versus transplantation. *Ann Surg*. 1995;221:415–419.
- Khan MF, Datta S, Chisti MM, Movahed MR. Cardiac paraganglioma: clinical presentation, diagnostic approach and factors affecting short and long-term outcomes. *Int J Cardiology*. 2013;166:315–320.
- Erickson D, Kudva YC, Ebersold MJ, Thompson GB, Grant CS, van Heerden JA, Young WF Jr. Benign paragangliomas: clinical presentation and treatment outcomes in 236 patients. *J Clin Endocrinol Metab*. 2001;86:5210–5216.
- Lenders JW, Pacak K, Walther MM, Linehan WM, Mannelli M, Friberg P, Keiser HR, Goldstein DS, Eisenhofer G. Biochemical diagnosis of pheochromocytoma: which test is best? *JAMA*. 2002;287:1427–1434.
- Hamilton BH, Francis IR, Gross BH, Korobkin M, Shapiro B, Shulkin BL, Deeb CM, Orringer MB. Intrapericardial paragangliomas (pheochromocytomas): imaging features. *AJR Am J Roentgenol*. 1997;168:109–113.
- Thomas D, Grant FD, Kwong R, Nose V, Di Carli MF, Dorbala S. Multimodality imaging of an unusual case of cardiac paraganglioma. *J Nucl Cardiol*. 2009;16:644–647.
- Plouin PF, Duclos JM, Soppelsa F, Boulblil G, Chatellier G. Factors associated with perioperative morbidity and mortality in patients with pheochromocytoma: analysis of 165 operations at a single center. *J Clin Endocrinol Metab*. 2001;86:1480–1486.
- Kimura N, Chetty R, Capella C, Young WF Jr, Koch CA, Lam Alfred DeLellis RA, Kawashima A, Komminoth P, Tischler AS. Extra-adrenal paraganglioma: carotid body, jugulotympanic, vagal, laryngeal, aorticopulmonary. In: *Pathology and Genetics of Tumors of Endocrine Organs*. Lyon, France: IARC Press; 2004.
- Linnola RI, Keiser HR, Steinberg SM, Lack EE. Histopathology of benign versus malignant sympathoadrenal paragangliomas: clinicopathologic study of 120 cases including unusual histologic features. *Hum Pathol*. 1990;21:1168–1180.
- Bravo EL, Tagle R. Pheochromocytoma: state-of-the-art and future prospects. *Endocr Rev*. 2003;24:539–553.
- Van Slycke S, Caiazzo R, Pigny P, Cardot-Bauters C, Arnalsteen L, D'Herbomez M, Leteurtre E, Rouaix-Emery N, Ernst O, Huglo D, Vantghem MC, Wemeau JL, Carnaille B, Pattou F. Local-regional recurrence of sporadic or syndromic abdominal extra-adrenal paraganglioma: incidence, characteristics, and outcome. *Surgery*. 2009;146:986–992.
- Hardegree EL, Patel SM, Maleszewski JJ, Nishimura RA, Dean DS. The heart of the matter. *Am J Med*. 2012;125:873–875.
- Huang H, Abraham J, Hung E, Averbuch S, Merino M, Steinberg SM, Pacak K, Fojo T. Treatment of malignant pheochromocytoma/paraganglioma with cyclophosphamide, vincristine, and dacarbazine: recommendation from a 22-year follow-up of 18 patients. *Cancer*. 2008;113:2020–2028.
- Ghoury MA, Krishnan E, Singh A, Zaman T, Hallman CH. Mediastinal paraganglioma between the great vessels in an 81-year-old woman. *Tex Heart Inst J*. 2013;40:189–192.
- Neumann HP, Pawlu C, Peczkowska M, Bausch B, McWhinney SR, Muresan M, Buchta M, Franke G, Klisch J, Bley TA, Hoegerle S, Boedeker CC, Opocher G, Schipper J, Januszewicz A, Eng C; European-American Paraganglioma Study Group. Distinct clinical features of paraganglioma syndromes associated with SDHB and SDHD gene mutations. *JAMA*. 2004;292:943–951.

KEY WORDS: heart neoplasms ■ magnetic resonance imaging ■ paraganglioma