

# Electrophysiological Characteristics of Septal Hypertrophy in Patients With Hypertrophic Obstructive Cardiomyopathy and Moderate to Severe Symptoms

Burghard Schumacher, MD; Frank H. Gietzen, MD; Hans Neuser, MD; Joachim Schümmelfeder, MD; Michael Schneider, MD; Sebastian Kerber, MD; Rainer Schimpf, MD; Christian Wolpert, MD; Martin Borggreffe, MD

**Background**—In hypertrophic obstructive cardiomyopathy, regional hypertrophy, myocardial replacement scarring, expanded interstitial fibrosis, and myocardial disarray can be found. The electrophysiological consequences of this substrate have not yet been investigated. Thus, the aim of this study was to assess the local electrophysiological characteristics of regional left ventricular (LV) septal hypertrophy.

**Methods and Results**—In 9 patients with hypertrophic obstructive cardiomyopathy, electroanatomic voltage mapping of the LV was performed during sinus rhythm to determine the regional voltage amplitude. In addition, the morphology of the regional bipolar endocardial electrogram was assessed. During multisite LV stimulation, the stimulus-to-V intervals in both septal hypertrophy and the lateral LV myocardium were determined. Bipolar electroanatomic voltage mapping revealed a significant reduction in regional voltage amplitude in septal hypertrophic areas compared with lateral LV areas without evidence of hypertrophy ( $0.41 \pm 0.24$  versus  $13.5 \pm 1.85$  mV;  $P < 0.001$ ). Local bipolar electrogram analysis demonstrated fractionated and prolonged endocardial potentials in septal hypertrophic areas (with split potentials present in 6 patients) that were not revealed at lateral myocardial sites ( $110.1 \pm 24.6$  versus  $80.1 \pm 6.6$  ms;  $P = 0.005$ ). The stimulus-to-V interval was significantly longer ( $62.9 \pm 10.3$  versus  $24.1 \pm 9.1$  ms;  $P = 0.005$ ) in septal hypertrophic areas compared with the lateral LV.

**Conclusions**—In LV regions with extensive hypertrophy, a marked reduction of bipolar voltage amplitude can be found, as well as local conduction delay and conduction block. This result is consistent with the findings of regional myocardial scarring and may contribute to the increased incidence of ventricular tachyarrhythmias in patients with hypertrophic obstructive cardiomyopathy. (*Circulation*. 2005;112:2096-2101.)

**Key Words:** arrhythmia ■ cardiomyopathy ■ electrophysiology ■ hypertrophy

Hypertrophic obstructive cardiomyopathy (HOCM) is the most common cause of sudden cardiac death (SCD) in otherwise healthy young individuals.<sup>1,2</sup> The available data suggest that ventricular tachyarrhythmias emanating from an electrically unstable myocardial substrate is the leading mechanism by which SCD occurs in patients with HOCM.<sup>3,4</sup> Programmed right ventricular stimulation has a low predictive accuracy.<sup>5</sup> The highest risk for SCD seems to be associated with prior cardiac arrest, spontaneously occurring sustained ventricular tachycardia, family history of a premature HOCM-related SCD, unexplained syncope, nonsustained ventricular tachycardia, abnormal blood pressure response during upright exercise, and an extreme left ventricular (LV) hypertrophy with maximum wall thickness of  $\geq 30$  mm.<sup>6,7</sup> Recently, noninvasive imaging with gadolinium-enhanced magnetic resonance tomography demonstrated zones of hy-

perenhancement, indicating local microinfarction and association to the risk of SCD.<sup>8-10</sup> This finding is consistent with postmortem autopsy data revealing replacement scarring, expanded interstitial fibrosis, and myocardial disarray.<sup>11-13</sup> However, the electrophysiological characteristics of regional LV hypertrophy have not been defined yet.

We hypothesized that replacement scarring, expanded interstitial fibrosis, and myocardial disarray demonstrated in hypertrophic myocardium result in major conduction abnormalities. Thus, the aim of this study was to assess the electrophysiological characteristics of regional LV hypertrophy in patients with HOCM. Therefore, we analyzed the local bipolar voltage amplitude, morphology of the local endocardial bipolar potentials, LV activation pattern during sinus rhythm, and stimulus-to-V interval during LV stimulation in both septal hypertrophic areas and lateral LV areas without evidence of hypertrophy.

Received October 25, 2004; revision received June 1, 2005; accepted July 18, 2005.

From the Department of Cardiology, Center of Cardiovascular Medicine, Bad Neustadt/Saale (B.S., F.H.G., H.N., J.S., M.S., S.K.), and Department of Medicine-Cardiology, University Hospital Mannheim, Mannheim (R.S., C.W., M.B.), Germany.

Correspondence to Burghard Schumacher, MD, Department of Cardiology, Center of Cardiovascular Medicine, Salzburger Leite 1, D-97688 Bad Neustadt/Saale, Germany. E-mail Schumacher@kardiologie-bad-neustadt.de

© 2005 American Heart Association, Inc.

*Circulation* is available at <http://www.circulationaha.org>

DOI: 10.1161/CIRCULATIONAHA.104.515643

## Methods

### Patients

The study group consisted of 9 consecutive patients (5 women, 4 men; mean age,  $57.7 \pm 13.2$  years) with HOCM and moderate to severe symptoms referred for transcatheter ablation of septal hypertrophy. All patients had HOCM with subaortic obstruction based on typical clinical, echocardiographic, and angiographic findings. Entry criteria included asymmetrical septal hypertrophy  $\geq 15$  mm, systolic anterior motion of the mitral valve, and an intraventricular pressure gradient of  $\geq 30$  mm Hg after provocation by a single premature ventricular beat ( $\geq 50$  mm Hg after 2 premature ventricular beats) or during basal conditions. The invasively measured mean resting gradient was  $56 \pm 50$  mm Hg, and the mean postextrasystolic gradient was  $124 \pm 21$  mm Hg. The mean septal thickness was  $22 \pm 3$  mm. Five patients were in NYHA functional class III, 3 patients were in class II, and 1 patient was in class I despite maximally tolerated doses of medical treatment with verapamil or  $\beta$ -blockers for at least 3 months. Syncope had occurred in 1 patient. None of the study group patients had a history of ventricular fibrillation or cardiac arrest (Table 1).

### Electrophysiological Study

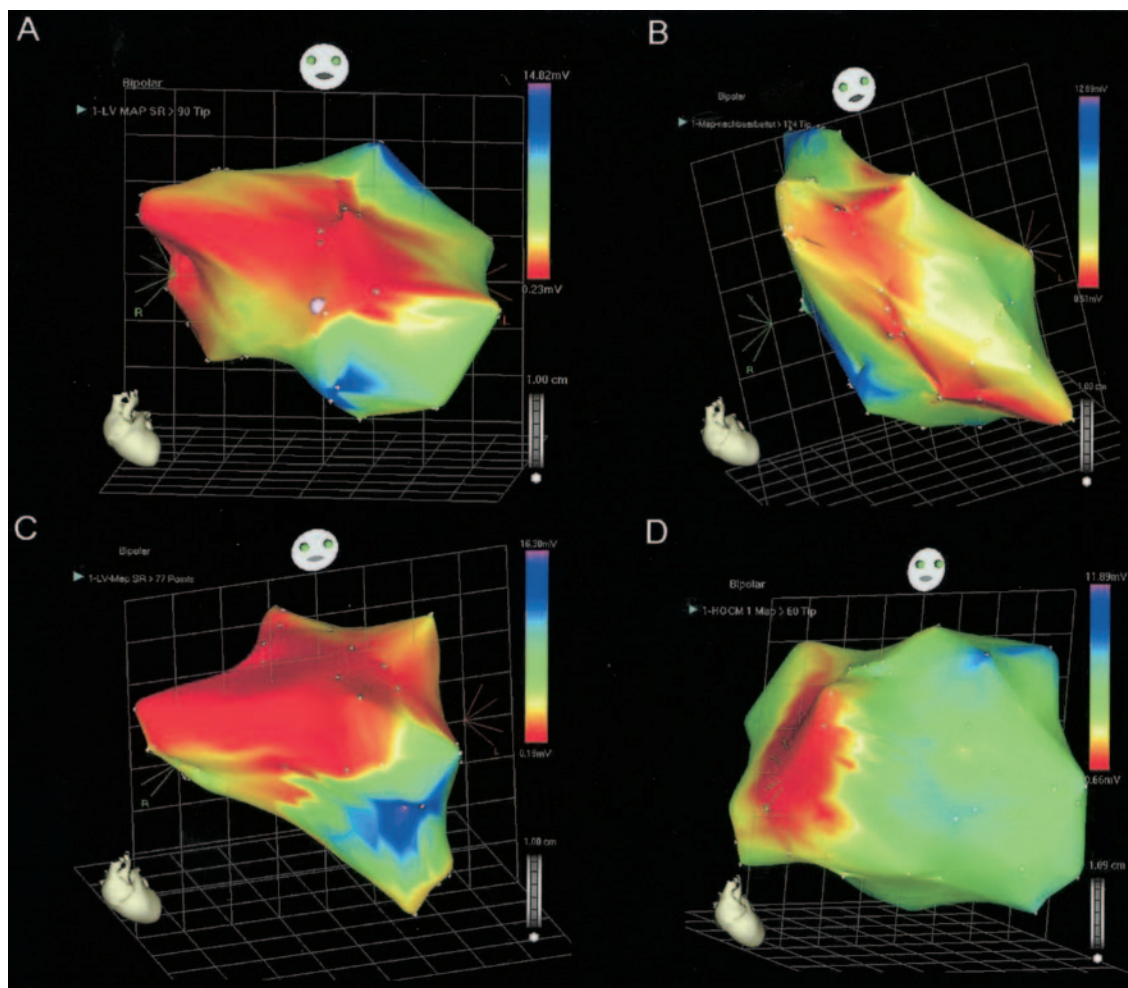
The study was reviewed by a local institutional board, with all patients giving informed written consent for the investigational nature of the examination. Antiarrhythmic drugs were withdrawn.

TABLE 1. Patient Characteristics

Patient	Age, y	NYHA	Syncope	PP at Rest, bpm	PPmax, bpm	IVS, mm
G.S.	47	3	—	100	120	26
A.C.	40	2	—	0	120	23
E.K.	72	2	—	32	140	22
J.S.	55	1	—	68	160	21
H.J.	76	3	—	0	120	18
J.K.	42	3	—	33	95	26
I.W.	69	3	+	122	135	22
C.S.	54	2	—	22	95	20
W.S.	64	3	—	125	135	20
Mean	57.67			55.78	124.44	22.0
SD	13.24			49.66	20.98	2.69

PP indicates pressure gradient; IVS, intraventricular septum diameter.

Two multielectrode catheters were advanced to the right ventricular apex (5F, 4-polar diagnostic electrode) and to the LV using the retrograde transaortic root (7F, 4-polar electrode with 4-mm tip, Navistar, Biosense Webster). Surface ECGs and bipolar endocardial



**Figure 1.** Four representative LV electroanatomic voltage maps from 4 different patients with HOCM. Colors represent the amplitude of the local electrogram. Range scale of color coding is depicted on each figure in the right upper corner. Note that in all patients, an extensive area of low voltage was found at the hypertrophic LV septum that was not found at any other area of the LV. However, the distribution of low voltage areas differed among individual patients, reflecting various regional patterns of hypertrophy.

**TABLE 2. Mapping Results**

Patient	Voltage at Septal Sites, mV	Voltage at Lateral Sites, mV	Potential at Septal Sites, ms	Potential at Lateral Sites, ms	SV at Septal Sites, ms	SV at Lateral Sites, ms	Split Potential
G.S.	0.23±0.13 (0.1–0.5)	15.01±7.87 (7.4–28.7)	95	78	65	27	+
A.C.	0.92±0.34 (0.6–1.4)	10.37±0.66 (9.2–10.9)	85	85	55	31	–
E.K.	0.33±0.09 (0.2–0.5)	12.77±2.21 (9.2–14.8)	105	75	52	35	–
J.S.	0.12±0.03 (0.1–0.2)	13.82±5.81 (6.7–21.2)	143	78	60	25	+
H.J.	0.40±0.01 (0.2–0.6)	14.20±2.95 (9.3–16.3)	155	85	65	30	+
J.K.	0.26±0.20 (0.1–0.7)	16.80±8.51 (8.3–34.2)	82	68	80	25	–
I.W.	0.42±0.11 (0.1–0.6)	12.53±2.64 (9.0–15.5)	104	90	78	15	+
C.S.	0.38±0.16 (0.1–0.6)	13.87±1.71 (12.4–16.9)	114	84	52	5	+
W.S.	0.60±0.10 (0.5–0.8)	12.01±0.07 (12.1–11.9)	108	78	59	24	+
Mean	0.41	13.49	110.11	80.11	62.89	24.11	
SD	0.24	1.85	24.57	6.58	10.33	9.08	

Values are mean±SD when appropriate; values in parentheses are ranges. Potential indicates the duration of the local endocardial potential; SV indicates interval between the stimulus spike and the earliest ventricular deflection of surface ECG.

electrograms were filtered at 30 to 500 Hz and recorded, displayed, and stored on an electrophysiological recording system (Prucka, Inc).

For 3D electroanatomic mapping of the LV, bipolar (filtered at 30 to 400 Hz) electrograms were recorded simultaneously on an electroanatomic mapping system (CARTO, Biosense Webster). The technique of electroanatomic mapping with the CARTO system has been described and validated elsewhere for the LV.<sup>14,15</sup> Electroanatomic mapping was performed in the LV by systematic sampling of the entire ventricular endocardial surface during normal sinus rhythm. We ensured that all LV maps were of high density, consisting of at least 60 acquired points. Of these 60 points, at least 10 to 20 points were acquired at both the hypertrophic septal area and the nonhypertrophic lateral LV. Acquisition of electroanatomic data was done exclusively if a stable catheter position and an adequate catheter-tissue contact were ensured by end-diastolic beat-to-beat location stability  $\leq 3$  mm and a local beat-to-beat activation time stability  $\leq 3$  ms.

Pacing was performed at twice the diastolic threshold via the mapping catheter with a pacing cycle length of 600 ms at the septal and lateral areas of the LV to determine the local interval between the stimulus spike and the earliest onset of ventricular activation at the surface ECG.

Postprocedural analysis included measurement of the maximum bipolar voltage amplitude, local bipolar electrogram duration, interval between the stimulus spike and the onset of the local endocardial ventricular activation, and assessment of fractionated or split potentials. For the purposes of this study, the LV was divided into 5 areas: septal, apical, lateral, anterior, and inferior. Separate analysis was performed at all 5 areas, although special attention was given to the hypertrophic septal area and the nonhypertrophic lateral area. Analysis of the local voltage amplitude was performed by the computerized mapping system. For each defined area, the mean voltage was calculated from the acquired points. The local bipolar electrogram duration and the stimulus-to-V interval were measured independently by 2 investigators in a blinded fashion. In the event of discrepancies, ie,  $\geq 5$ -ms difference between both measurements, the electrograms were reanalyzed by a separate observer, and consensus was reached.

### Statistical Analysis

Data are expressed as mean±SD. A 2-sample *t* test assuming unequal variances and a Wilcoxon rank-sum test were used to assess for possible differences in the electrophysiological properties (local electrogram voltage amplitude, local endocardial potential duration, SV interval) of the hypertrophic septum and the lateral LV. A 2-sided value (*t* test) of  $P<0.05$  was considered significant. To account for a potential correlation among the multiple sampled sites

within a single heart, the difference in the voltage amplitudes was estimated by generalized estimating equations. The working correlation of the generalized estimating equations was 0.021, which indicates only a small individual correlation of measures from different sites.

## Results

### Electroanatomic Voltage Mapping

In all patients, a high-density electroanatomic map of the LV was achieved. The mean number of analyzed points was  $94\pm 20$  (range, 60 to 124). In all patients, septal sites with massive LV hypertrophy were characterized by significantly lower bipolar voltage amplitudes compared with the lateral LV (Figure 1). The mean voltage amplitude was  $0.41\pm 0.24$  mV at the septum and  $13.49\pm 1.85$  mV at the lateral wall ( $P<0.001$ ) (Table 2). At the lateral LV, the lowest voltage amplitude found was 10.4 mV; it was 0.12 mV at the septal sites. In all patients, the minimum voltage amplitude at the septum was  $<1.0$  mV, which reflects a common definition for myocardial scarring.<sup>15</sup> In all patients, the hypertrophic regions were identified by spatial association of the abnormally low-amplitude intracardiac electrograms. However, the distribution of low-amplitude areas showed a broad variation among individual patients, reflecting different patterns of regional hypertrophy (Figure 1).

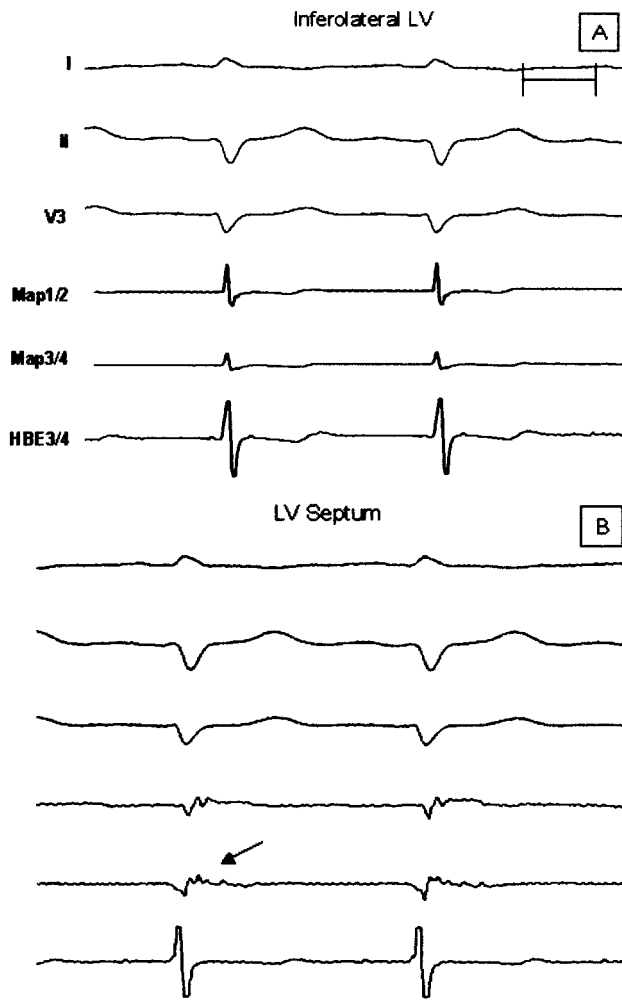
### Electroanatomic Activation Mapping

Electroanatomic activation mapping did not show a common pattern in all patients. However, 4 patients were identified with activation of the lateral LV before activation of the septal endocardium despite the absence of a bundle-branch block, suggesting septal conduction delay.

### Regional Potential Analysis

Significant differences were also found with regard to the characteristics of the local electrograms. Hypertrophic septal areas displayed significantly ( $P<0.005$ ) longer potential durations compared with the lateral areas ( $110.11\pm 24.57$  versus  $80.11\pm 6.58$  ms) (Table 2). Fractionated potentials were found exclusively at septal areas; they were absent at the





**Figure 2.** Surface leads I, II, and V3; the endocardial bipolar recordings from a His bundle catheter (HBE3/4); and the endocardial bipolar recordings from the distal (Map1/2) and proximal (Map3/4) mapping bipole placed at the inferolateral LV (A) and hypertrophic LV septum (B) during normal sinus rhythm. Note that during sinus rhythm, the local endocardial bipolar potential was short at the inferolateral LV (A) and fractionated at the hypertrophic LV septum (arrow; B) (patient G. S.). Each recording has the same amplification in A compared with the correspondent recording in B.

lateral wall (Figure 2). In 6 patients, fractionated potentials were identified at septal sites during sinus rhythm.

### Regional SV Interval

The local stimulus-to-V intervals were significantly longer at septal areas compared with the lateral LV ( $62.89 \pm 10.33$  versus  $24.11 \pm 9.08$  ms;  $P < 0.005$ ) (Table 2 and Figure 3).

### Discussion

A substantial minority of patients with HOCM are at high risk of SCD.<sup>6</sup> Ventricular tachyarrhythmias have been recognized as the leading mechanism by which premature death may occur in patients with HOCM.<sup>3</sup> Important anatomic components of the postulated arrhythmogenic substrate are major degrees of LV hypertrophy, replacement scarring, myocardial disarray, and abnormal microvasculature with muscle mass–

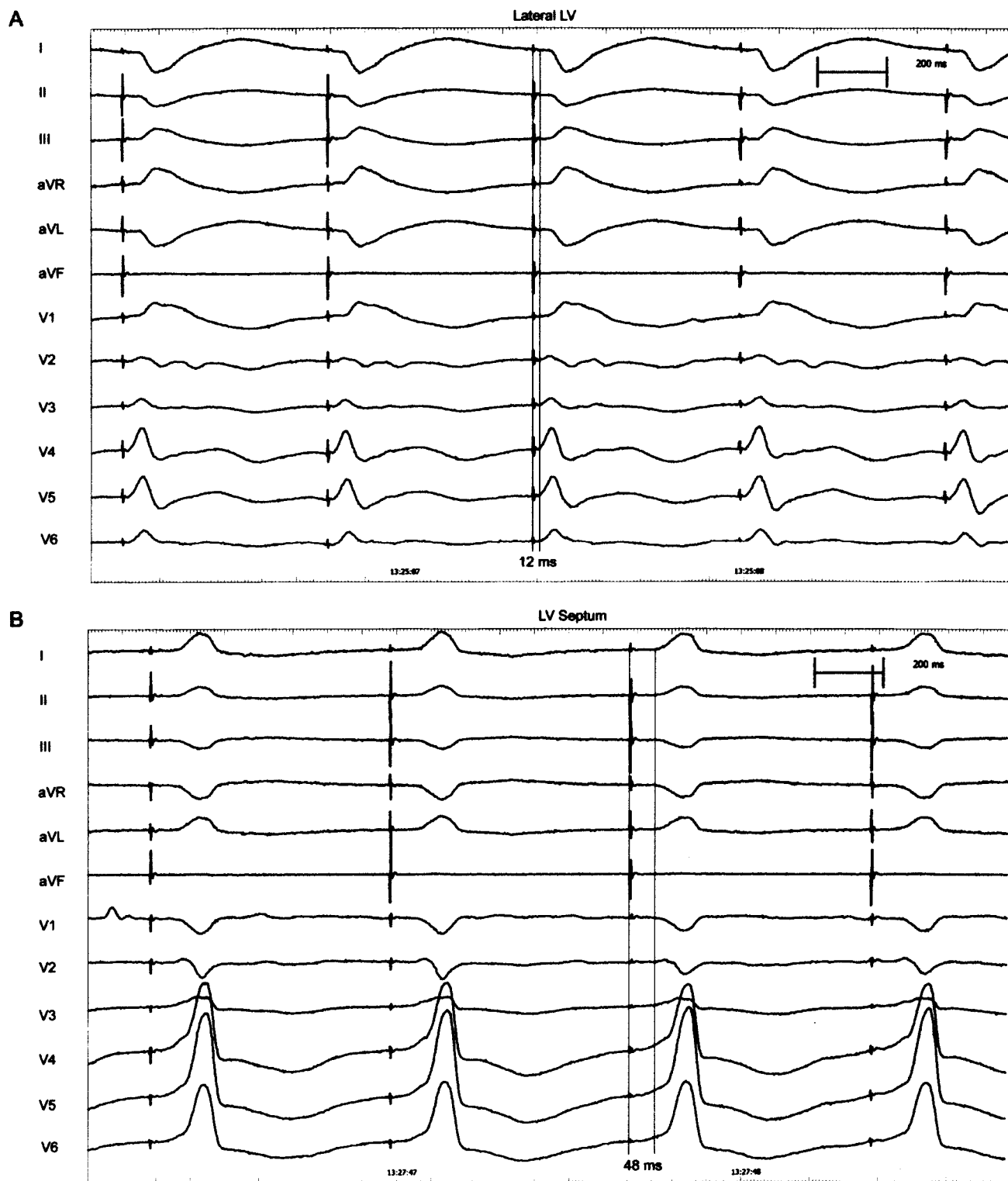to–coronary flow mismatch.<sup>1</sup> Alternatively, it has been suggested that electric instability and life-threatening ventricular tachyarrhythmias are triggered by a vicious cycle of increasing myocardial ischemia, diastolic LV dysfunction, outflow obstruction, and systemic arterial hypotension, which lead to decreased stroke volume and coronary perfusion.<sup>1</sup>

Spirito et al<sup>7</sup> reported that LV hypertrophy of  $\geq 30$  mm is a strong risk factor for premature SCD (annual mortality  $\approx 2\%$ ). Basso et al<sup>12</sup> reported a positive correlation between the magnitude of septal hypertrophy and the extent of replacement scarring in young patients with HOCM experiencing sudden death. Tanaka et al<sup>13</sup> quantified the amount of myocardial scarring in a necropsy study of 10 patients with HOCM. They found that all 7 patients who died suddenly had a larger amount of scarring ( $13 \pm 3\%$  of total area) than the 3 patients who died of noncardiac causes ( $6 \pm 3\%$ ;  $P < 0.05$ ). In asymptomatic or mildly symptomatic patients with HCM, Choudhury et al,<sup>8</sup> using gadolinium contrast-enhanced MRI, found that the extent of scar increased significantly and progressively in relation to wall thickness on a regional basis. None of the segments that were  $< 10$  mm thick had any scarring.<sup>8</sup> Choudhury et al suggested that scarring is a potential link between LV hypertrophy and SCD.<sup>8</sup> Whether extreme myocardial scarring is an independent predictor of SCD is unclear at this point.<sup>8</sup> However, that patients with significant scarring may not have extreme hypertrophy might explain the finding of Elliott et al<sup>6</sup> that most sudden deaths in HCM occur in patients with a wall thickness  $< 30$  mm.

In view of this discussion on morphological abnormalities and MRI findings in patients with HCM, we hypothesized that septal thickening is accompanied by major conduction abnormalities (probably reflecting replacement scarring and myocardial disarray as described by Basso et al<sup>12</sup> and Tanaka et al<sup>13</sup>).

Indeed, major conduction abnormalities are a potential link between LV hypertrophy, scarring, and SCD. Saumarez et al<sup>16</sup> showed sophisticatedly that patients with HCM who are at risk of sudden death develop an increased dispersion and inhomogeneity of intraventricular conduction when paced in the right ventricle with decreasing pacing cycle lengths. However, these authors recorded endocardial electrograms exclusively from the right ventricle. Thus, it seems to be important to assess the electrophysiological characteristics of regional LV hypertrophy also. Therefore, we analyzed the local bipolar voltage amplitude, morphology of the local endocardial bipolar potential, LV activation pattern in sinus rhythm, local stimulation threshold, and SV interval during LV stimulation at septal compared with lateral sites.

In patients with HOCM, the hypertrophic septal areas were characterized by a marked alteration of regional electrophysiological properties. The local bipolar potentials displayed a significantly lower voltage than potentials recorded at the lateral LV in the same patient. This finding is in concordance with the presence of myocardial replacement scarring, expanded interstitial fibrosis, and/or myocardial fiber disarray (preferentially in the thickest part of the interventricular septum) described in patients with HOCM by Basso et al<sup>12</sup>, Tanaka et al,<sup>13</sup> and Choudhury et al.<sup>8</sup>



**Figure 3.** Surface ECG leads during LV stimulation (S1S1, 600 ms) at the lateral LV (A) and hypertrophic LV septum (B). Note that during LV pacing at the lateral LV, a short stimulus-to-V interval was found (12 ms; A), whereas the stimulus-to-V interval was significantly longer (48 ms) in the same patient during pacing at the LV septum (B).

Probably as a consequence of replacement scarring, expanded interstitial fibrosis, and myocardial disarray, the potential analysis of the present study revealed a marked prolongation of the bipolar endocardial potentials and the occurrence of fractionated and split potentials at hypertrophic areas. This finding is in perfect accor-

dance with the findings of Saumarez et al<sup>16</sup> at right ventricular septal sites. Local conduction disturbances are well-known prerequisites for the development of ventricular tachyarrhythmias and may contribute to the increased incidence of ventricular tachyarrhythmias in patients with HOCM.

### Study Limitations

Myocardial scarring and fiber disarray cannot be distinguished clearly by local bipolar voltage amplitude analysis because voltage amplitude depends not only on the amount of simultaneously depolarizing tissue but also on the orientation of pulse propagation. Furthermore, we restricted this study to patients with extensive septal hypertrophy. Therefore, the results of this study cannot be generalized to other subsets of patients with HOCM. The voltage amplitude analysis was performed in a bipolar fashion. Furthermore, we restricted this study to patients with moderate to severe symptoms referred to a tertiary care center for catheter interventional treatment of HOCM. Therefore, the results of this study cannot be generalized to other subsets of patients with HOCM.

### References

1. Maron BJ, McKenna WJ, Danielson GK, Kappenberger LJ, Kuhn HJ, Seidman CE, Shah PM, Spencer WH, Spirito P, Ten Cate FJ, Wigle ED. American College of Cardiology/European Society of Cardiology clinical expert consensus document on hypertrophic cardiomyopathy. *J Am Coll Cardiol*. 2003;42:1687–1713.
2. Maron BJ, Olivetto I, Spirito P, Casey SA, Bellone P, Gohman TE, Graham KJ, Burton DA, Cecchi F. Epidemiology of hypertrophic cardiomyopathy-related death: revisited in a large non-referral based patient population. *Circulation*. 2000;102:858–864.
3. Maron BJ, Shen WK, Link MS, Alquist AK, Daubert GP, Bardy GH, Favale S, Rea RF, Boriani G, Estes NA, Spirito P. Efficacy of implantable cardioverter-defibrillators for the prevention of sudden death in patients with hypertrophic cardiomyopathy. *N Engl J Med*. 2000;342:365–373.
4. Varnava AM, Elliott PM, Mahon N, Davies MJ, McKenna WJ. Relation between myocyte disarray and outcome in hypertrophic cardiomyopathy. *Am J Cardiol*. 2001;88:275–279.
5. Kuck KH, Kunze KP, Schluter M, Nienaber CA, Costard A. Programmed electrical stimulation in hypertrophic cardiomyopathy: results in patients with and without cardiac arrest or syncope. *Eur Heart J*. 1988;9:177–185.
6. Elliott PM, Poloniecki J, Dickie S, Sharma S, Monserrat L, Vanava A, Mahon NG, McKenna WG. Sudden death in hypertrophic cardiomyopathy: identification of high risk patients. *J Am Coll Cardiol*. 2000;36:2212–2218.
7. Spirito P, Bellone P, Harris KM, Bruzzi P, Maron BJ. Magnitude of left ventricular hypertrophy and risk of sudden death in hypertrophic cardiomyopathy. *N Engl J Med*. 2000;342:1778–1785.
8. Choudhury L, Mahrholdt H, Wagner A, Choi KM, Elliot MD, Klocke FJ, Bonow RO, Judd RM, Kim RJ. Myocardial scarring in asymptomatic or mildly symptomatic patients with hypertrophic cardiomyopathy. *J Am Coll Cardiol*. 2002;40:2156–2164.
9. Moon JCC, McKenna WJ, McCrohon JA, Elliott PM, Smith GC, Pennell DJ. Toward clinical risk assessment in hypertrophic cardiomyopathy with gadolinium cardiovascular magnetic resonance. *J Am Coll Cardiol*. 2003;41:1561–1567.
10. Kim RJ, Judd RM. Gadolinium-enhanced magnetic resonance imaging in hypertrophic cardiomyopathy: in vivo imaging of the pathologic substrate for premature cardiac death? *J Am Coll Cardiol*. 2003;41:1568–1572.
11. Ferrans VJ, Morrow AG, Roberts WC. Myocardial ultrastructure in idiopathic hypertrophic subaortic stenosis: a study of operatively excised left ventricular outflow tract muscle in 14 patients. *Circulation*. 1972;45:769–792.
12. Basso C, Thiene G, Corrado D, Buja G, Melacini P, Nava A. Hypertrophic cardiomyopathy and sudden death in the young: pathologic evidence of myocardial ischemia. *Hum Pathol*. 2000;31:988–998.
13. Tanaka M, Fujiwara H, Onodera T, Wu DJ, Hamashima Y, Kawai C. Quantitative analysis of myocardial fibrosis in normals, hypertensive hearts, and hypertrophic cardiomyopathy. *Br Heart J*. 1986;55:575–581.
14. Gepstein L, Hayam G, Ben-Haim SA. A novel method for nonfluoroscopic catheter-based electroanatomical mapping of the heart: in vitro and in vivo accuracy results. *Circulation*. 1997;95:1611–1622.
15. Marchlinski FE, Callans DJ, Gottlieb CD, Zado E. Linear ablation lesions for control of unmappable ventricular tachycardia in patients with ischemic and nonischemic cardiomyopathy. *Circulation*. 2000;101:1288–1296.
16. Saumarez RC, Camm AJ, Panagos A, Gill JS, Stewart JT, de Belder MA, Simpson IA, McKenna WJ. Ventricular fibrillation in hypertrophic cardiomyopathy is associated with increased fractionation of paced right ventricular electrograms. *Circulation*. 1992;86:467–474.