Malicious Licorice

Ivan Tancevski, MD; Philipp Eller, MD; Michael Spiegel, MD;
Rudolf Kirchmair, MD; Josef R. Patsch, MD

A 54-year–old white woman presented at the emergency department because of progressive tetraparesis, which had developed over the past few days. She was alert but unable to walk or to hold a cup of coffee. Neurological evaluation revealed flaccid paresis of all limbs, sonography showed acute urinary retention of 800 mL, and cranial computed tomography was normal. The ECG showed a prominent U-wave (the Figure), and laboratory examinations revealed a massive hypokalemia of 1.13 mmol/L. The transtubular potassium gradient was >4, and blood pH was 7.47. The patient was immediately admitted to the intensive care unit, and potassium was intravenously administered at a rate of 15 mmol/h. Electrocardiographic abnormalities as well as paralysis resolved in reverse order of appearance over the next several hours. The patient had no premedication. She had just stopped smoking and had therefore ingested excessive amounts of licorice (approximately 750 g/d) during the previous 2 weeks. Licorice contains the steroid-like glycoside glycyrrhizinic acid. Glycyrrhizinic acid can induce pseudohyperaldosteronism by inhibition of the 11β-hydroxysteroid dehydrogenase, which normally converts cortisol to cortisone in the distal nephron[1] and inhibits glucocorticoid-stimulated kaliuresis. An overdose of licorice can thus lead to an apparent mineralocorticoid excess and should be considered in the differential diagnosis of hypokalemic paresis and harmful cardiac arrhythmias.[2,3]

Disclosures

None.

References

1. Edwards CR, Stewart PM, Burt D, Brett L, McIntyre MA, Sutanto WS, de Kloet ER, Monder C. Localisation of 11 β-hydroxysteroid dehydrogenase–tissue specific protector of the mineralocorticoid receptor. *Lancet*. 1988;2:986–989.
2. Bauchart JJ, Loubeyre C, Asseman P, Thery C. Alcohol-free pastis and hypokalaemia. *Lancet*. 1995;346:1701.
3. Nielsen I, Pedersen RS. Life-threatening hypokalaemia caused by liquorice ingestion. *Lancet*. 1984;1:1305.

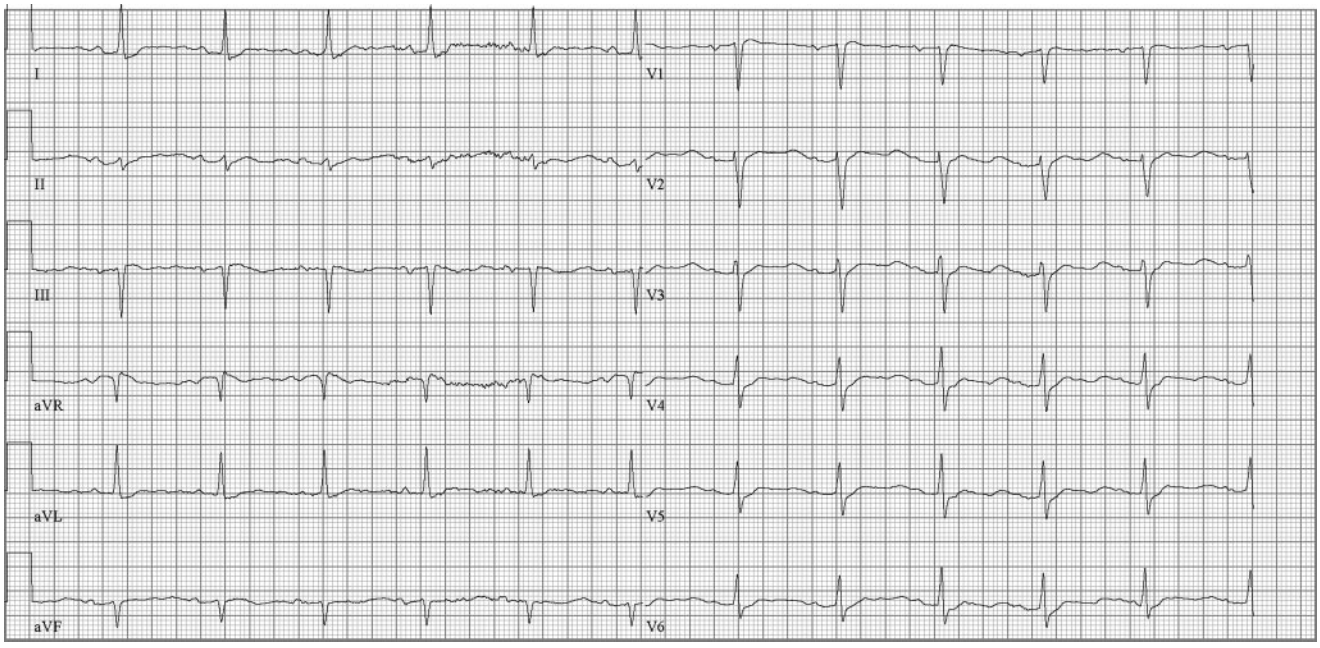

Figure. Twelve-lead ECG shows prominent U-waves due to hypokalemia of 1.13 mmol/L.

Downloaded from http://ahajournals.org by on March 4, 2022

From the Department of Internal Medicine (I.T., P.E., R.K., J.R.P.) and Department of Neurology (M.S.), Innsbruck Medical University, Innsbruck, Austria.
Correspondence to Ivan Tancevski, Department of Internal Medicine, Innsbruck Medical University, Anichstrasse 35, A-6020 Innsbruck, Austria. E-mail ivan.tancevski@i-med.ac.at

(*Circulation.* **2008;117:e299.**)
© 2008 American Heart Association, Inc.

Circulation **is available at http://circ.ahajournals.org** **DOI: 10.1161/CIRCULATIONAHA.107.733097**