

## Catheter-Assisted Pulmonary Embolectomy

Piotr Sobieszczyk, MD

**C**ase presentation: A 65-year-old man presented to the emergency department after a fall and was diagnosed with a fracture of the right femoral neck. He was scheduled for surgical repair the following day. During positioning for arthroplasty, he developed hypotension, tachycardia, and hypoxia, followed by pulseless electric activity. He was resuscitated and maintained on epinephrine and norepinephrine infusions. A transesophageal echocardiogram revealed a dilated and hypokinetic right ventricle with preserved apical contractility (Figure 1). Massive pulmonary embolism (PE) was suspected. What are the therapeutic options for this critically ill patient?

Patients afflicted with massive PE have 90-day mortality rates approaching 50%.<sup>1</sup> Massive PE is defined by sustained hypotension (systolic blood pressure <90 mm Hg for a minimum of 15 minutes, or requirement for inotropic support), pulselessness, or bradycardia with signs of shock.<sup>2</sup> As many as 10% of patients with submassive PE can develop hemodynamically significant and life-threatening right ventricular failure.<sup>3</sup> In such cases, supportive care and anticoagulation must be accompanied by rapid reduction of right ventricular (RV) afterload and restoration of adequate cardiac output.

Many patients with submassive PE and stable blood pressure develop residual RV dysfunction and experience a decline in functional status at 6-month follow-up. Acute relief of RV strain and reduction of thrombotic burden in the pulmonary arteries could yield long-term benefit in this group.<sup>4</sup>

Pharmacological and invasive strategies for reduction of thrombotic burden in the pulmonary arteries have been used for many decades with variable success.

Systemic intravenous thrombolysis has been shown to be of benefit in small trials of patients with massive PE, but it failed to reduce short-term mortality and morbidity in a wide range of patients with submassive PE.<sup>5</sup> Thrombolytic therapy is widely available and easy to administer, but these attributes are offset by the obligatory 2-hour infusion, a costly delay when immediate effect is required. Contraindications to systemic thrombolysis are present in as many as 50% of patients,<sup>6</sup> and major bleeding complications can occur in 20% of patients,<sup>5</sup> further limiting the utility of this therapy. Surgical embolectomy, first conceived by Trendelenburg in 1908 and performed by Kirschner in 1924,<sup>7</sup> can be life saving in patients with clot burden in the proximal pulmonary artery (PA). Advances in surgical and anesthesiology

techniques have reduced perioperative mortality to 20%,<sup>8</sup> but the best outcomes are achieved in a few selected centers with dedicated, rapid-response embolectomy programs.

Percutaneous strategies for treatment of massive and submassive PE date back to the development of the Greenfield suction catheter in the 1960s.<sup>9</sup> Technical advances in endovascular devices now allow for combining mechanical thrombus disruption and aspiration with pharmacological thrombolysis. This is called pharmacomechanical therapy. Pharmacological therapy allows rapid reduction in RV afterload in patients with hemodynamic instability, whereas mechanical therapy reduces thrombus burden via longer, catheter-directed infusion of a low-dose thrombolytic. There is a growing interest in clinical applications and large-scale investigations of these pharmacomechanical therapies in patients with massive PE and selected patients with submassive PE. This Clinician Update will examine the rationale for catheter-based pulmonary embolectomy and describe endovascular techniques commonly used today.

### Rationale for Catheter-Assisted Pulmonary Embolectomy

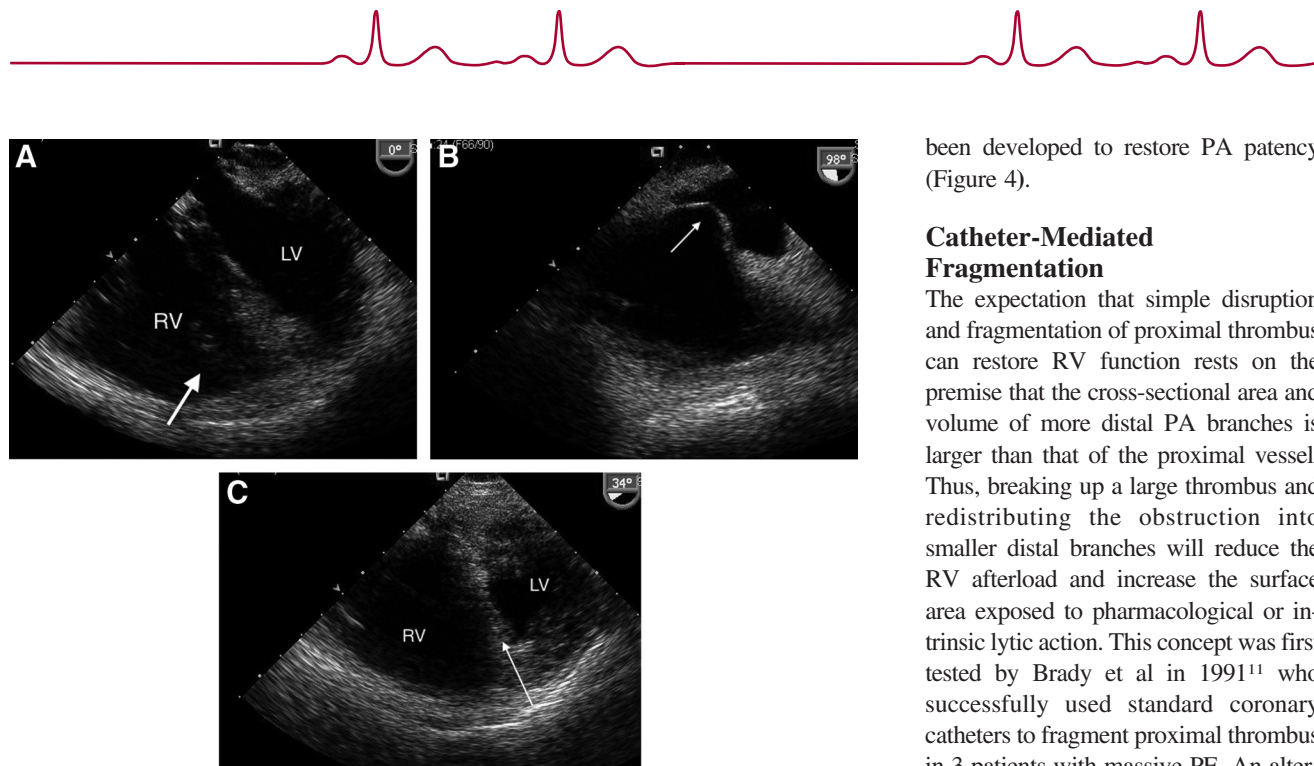
Catheter-based therapies can be rapidly instituted in most medical centers

From the Cardiovascular Division, Vascular Medicine Section and Cardiac Catheterization Laboratory, Brigham and Women's Hospital, Boston, MA. Correspondence to Piotr Sobieszczyk, MD, Cardiovascular Division, Vascular Medicine Section and Cardiac Catheterization Laboratory, Brigham and Women's Hospital, 75 Francis St, Boston, MA 02115. E-mail psobieszczyk@partners.org (*Circulation*. 2012;126:1917-1922.)

© 2012 American Heart Association, Inc.

*Circulation* is available at <http://circ.ahajournals.org>

DOI: 10.1161/CIRCULATIONAHA.110.963041



**Figure 1.** **A**, A dilated and hypokinetic right ventricle (arrow) is seen on a transesophageal echocardiogram. **B**, The interatrial septum (arrow) is bulging into the left atrium, suggesting increased right atrial pressure. **C**, A D-shaped interventricular septum (arrow) is caused by pressure and volume overload of the failing right ventricle. RV indicates right ventricle; LV, left ventricle.

equipped with cardiac and interventional radiology suites in a system akin to one used for treatment of ST-elevation myocardial infarction. Less invasive percutaneous procedures are better tolerated in tenuous patients whose comorbidities frequently preclude consideration of surgical embolectomy. Although many patients cannot tolerate large doses of systemic thrombolysis, catheter-based interventions allow administration of significantly reduced thrombolytic doses directly into the PA. Thrombolytics can be directly infused into the pulmonary circulation at doses that are a fraction of those used for systemic thrombolysis. Tenecteplase and tissue plasminogen activator (tPA) have replaced streptokinase and urokinase as thrombolytics of choice. Over 60% of catheter-assisted interventions include local administration of thrombolytics, which increase clinical success rates.<sup>10</sup>

The disadvantage of endovascular therapies lies in the size mismatch between the caliber of the proximal pulmonary arteries and the size of endovascular devices designed for thrombus removal from much smaller coronary or

peripheral vessels or dialysis fistulas. In addition, to be accessible to catheter-assisted embolectomy, the PE has to be located in the main PAs or in the proximal segmental branches. The organized thrombotic cast of a femoral vein lodged in the PA (Figure 2) can be resistant to mechanical techniques developed to deal with fresh and soft thrombus formed on a ruptured atherosclerotic plaque. The addition of prolonged direct infusion of thrombolytic agents is a critical component of these procedures. Even partial mechanical removal and fragmentation of thrombus, however, can be sufficient to restore RV function and reverse circulatory collapse, especially when accompanied by an additional infusion of low dose thrombolytic into the PA (Figure 3).

### Catheter-Assisted Embolectomy Techniques

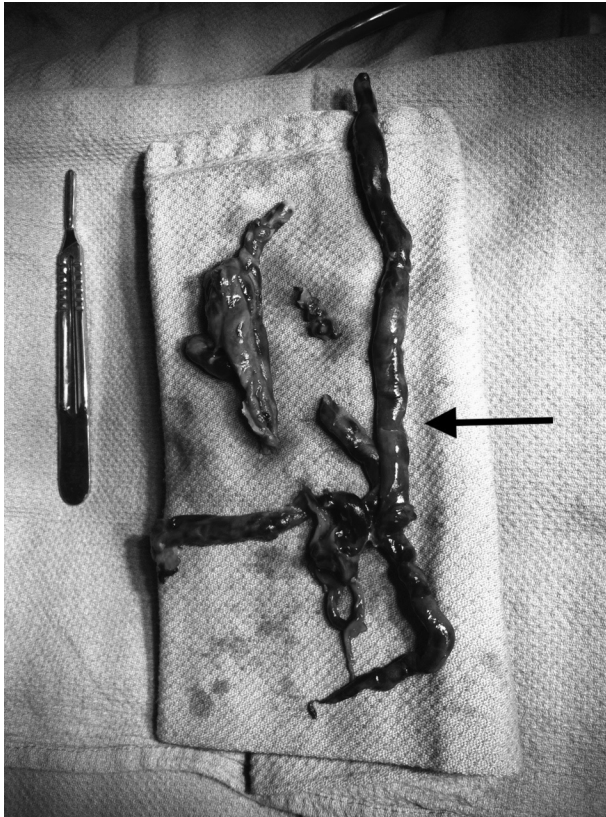
The ideal pulmonary embolectomy device would facilitate removal of a large volume of thrombus through small-caliber venous access with exposure to small doses of thrombolytic agents. Because such a device does not exist at present, several hybrid techniques have

been developed to restore PA patency (Figure 4).

### Catheter-Mediated Fragmentation

The expectation that simple disruption and fragmentation of proximal thrombus can restore RV function rests on the premise that the cross-sectional area and volume of more distal PA branches is larger than that of the proximal vessel. Thus, breaking up a large thrombus and redistributing the obstruction into smaller distal branches will reduce the RV afterload and increase the surface area exposed to pharmacological or intrinsic lytic action. This concept was first tested by Brady et al in 1991<sup>11</sup> who successfully used standard coronary catheters to fragment proximal thrombus in 3 patients with massive PE. An alternative technique described by Schmitz-Rode et al<sup>12</sup> involves manual spinning of an angiographic pigtail catheter in the main PA. A long, 80- to 90 cm sheath resting in the proximal PA facilitates advancement of a 100- to 125-cm pigtail catheter over a wire exiting through its proximal side-hole. The shape of the curly pigtail is thus retained as the catheter rotates on a wire like a propeller, churning the thrombus into smaller pieces. Several series have described clinical success with the use of this approach, reporting both angiographic reductions in the degree of obstruction, and hemodynamic improvement, as well.<sup>13</sup>

Fragmentation strategies are particularly effective when combined with thrombolytic infusion directly into the PA.<sup>14</sup> Most frequently, fragmentation of the thrombus is accomplished by combining several techniques such as balloon angioplasty, rotational fragmentation, and aspiration of smaller distal fragments with 8F coronary catheters. In clinical practice, delivery of thrombolytic agents can be accomplished by placing multiholed infusion catheters in each affected PA and infusing tPA at 1 to 2 mg/h over a period of 12 to 18 hours. Combined pharmacological and mechanical techniques account for 69% of all catheter-



**Figure 2.** A surgical pulmonary embolectomy specimen shows an organized cast of a femoral vein (arrow) that may be resistant to treatment with a single catheter-based technique.

assisted procedures reported over the past decade.<sup>10</sup>

### Catheter-Based Thrombectomy

Several devices designed to macerate and simultaneously aspirate thrombus from smaller vessels have been used in the pulmonary arteries. The Aspirex thrombectomy catheter available outside the United States (Straub Medical AG) uses a spiral rotating at 40 000 rpm to fragment the thrombus into smaller particles, which are then aspirated through an adjacent port as the device is advanced and withdrawn through the thrombus. The rotational speed can be adjusted to prevent excessive suction and collapse of the vessel wall around the rotating spiral. Pulmonary application of this device was first described by Kucher et al<sup>15</sup> and subsequently shown to be safe and effective in a small clinical series.<sup>16</sup> The Amplatz-Helix thrombectomy catheter (eV3, Inc, MN) and the Hydrolyzer cath-

eter (Cordis, NJ) were designed for treatment of thrombosed hemodialysis fistulas. The Helix device uses an impeller spinning at 150 000 rpm to suck in the thrombus, fragment the clot into smaller pieces, and expel the pieces through the side-holes without aspirating them. The device cannot be advanced over a wire, and the clinical experience is quite limited with case series reporting primarily angiographic improvements.<sup>17</sup> The Hydrolyzer device uses the Venturi effect to create a vacuum by infusing saline at high pressure as the catheter advances and retreats through the thrombus. This pigtail-tipped catheter is manually rotated and the thrombus fragmented and aspirated. Clinical experience is limited to a few small series.<sup>18</sup>

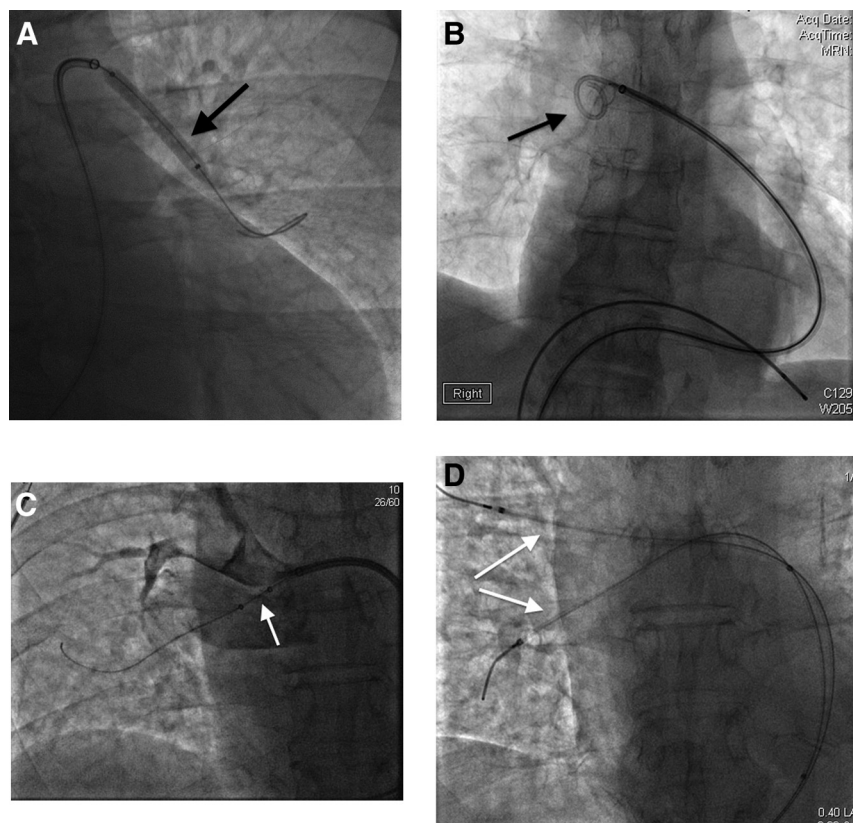
The largest clinical experience in pulmonary thrombectomy procedures comes from applications of the Angiojet rheolytic thrombectomy catheter (Medrad Interventional, PA). This device relies on the Bernoulli principle to gen-

erate a vacuum in the low-pressure zone behind a series of high-pressure saline jets positioned at the tip of the catheter. The saline jets disrupt the thrombus, which is then aspirated in the vacuum zone. A unique feature of this catheter allows forceful spraying of a thrombolytic agent instead of saline without simultaneous aspiration. In this mode, the catheter is advanced through the thrombus, lacing it with 5 to 10 mg of tPA. This pulse-spray treatment facilitates standard thrombectomy performed after a pause of 15 to 30 minutes to allow the thrombolytic agent to take effect. Since the initial description of this device used or treatment of PE by Koning et al in 1997,<sup>19</sup> the published experience comprises >140 patients with massive and submassive PE. The largest series included 50 patients with combined catheter-directed thrombolysis used in 30% of treated patients.<sup>20</sup> Primary outcome measures have varied from series to series, with mortality ranging from 12% to 25% in a heterogeneous patient population. Its wide application in coronary and peripheral arterial and venous interventions fueled its popularity in PE interventions. When used in the pulmonary and coronary vessels, the release of adenosine from disrupted platelets can lead to bradycardia, pulmonary vasospasm, and worsening hypoxia. These concerns have led to an US Food and Drug Administration black-box warning regarding intrapulmonary interventions with this device. Temporary transvenous pacing and brief treatment runs, and aminophylline administration, as well, can effectively overcome these side effects, allowing successful use of this device with or without thrombolysis.

### Ultrasound-Assisted Therapies

Traditional catheter-based thrombolysis techniques used catheters with multiple side-holes passively infusing thrombolytic into the thrombosed arterial or venous segment. Ultrasound energy has been shown to disrupt the structure of the thrombus and render it more susceptible to thrombolytic agents. Although high-energy ultrasound can mechanically fragment the clot, lower-energy applica-

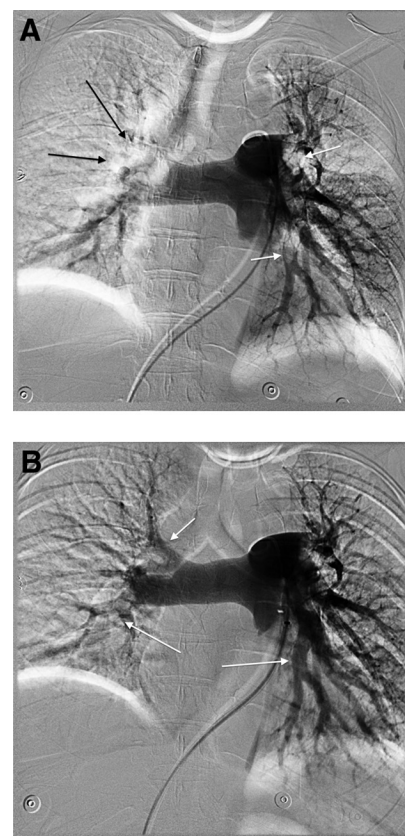




**Figure 3.** Multiple fragmentation techniques have been used in catheter-based embolectomy procedures. **A**, A rarely performed balloon angioplasty of venous thrombus in the left pulmonary artery (arrow). **B**, A pigtail catheter (arrow) manually rotated in the right main pulmonary artery to break up the thrombus. **C**, An Angiojet rheolytic catheter (arrow) is used to perform thrombectomy in the right pulmonary artery. **D**, After mechanical fragmentation, infusion catheters are placed in the upper and lower right pulmonary arteries (arrows) to perform catheter-based thrombolysis.

tion dissociates fibrin strands to allow more effective thrombolysis with shorter and lower-dose administration.<sup>21</sup> The latter strategy is used by the EKOS device (EkoSonic Endovascular), which combines a catheter with numerous side-holes infusing thrombolytic and a filament with multiple miniature ultrasound transducers. The filament is placed in the catheter's central lumen and emits ultrasound at 2.2 MHz along the treatment zone (Figure 5). This catheter can be used as adjunctive treatment after initial fragmentation or as a standalone strategy of ultrasound-assisted, catheter-directed thrombolysis in more stable patients. Initial experience suggests that 24-hour infusion of tPA at doses <1 mg/h can achieve complete thrombus resolution in 76% of patients and near-complete resolution in an additional 18%.<sup>22</sup> Even

shorter treatments of 17 hours with mean tPA doses of 0.86 mg/h effectively reduce the Miller score and result in larger thrombus resolution in comparison with higher rates and longer infusions via traditional, passive infusion catheters.<sup>23</sup> In a retrospective series of 24 patients with massive and submassive PE, a 12-hour treatment with the EKOS catheter infusing as little as 20 mg of tPA resulted in a statistically significant reduction in the RV to left ventricle ratio.<sup>24</sup> Early clinical experience has led to the approval of this device for treatment of PE in Europe where the ongoing randomized ULtrasound Accelerated Thrombolysis of PulMonAry Embolism (ULTIMA) trial (ClinicalTrials.gov Identifier: NCT01166997) will compare outcomes in patients with submassive PE who are treated with the EKOS

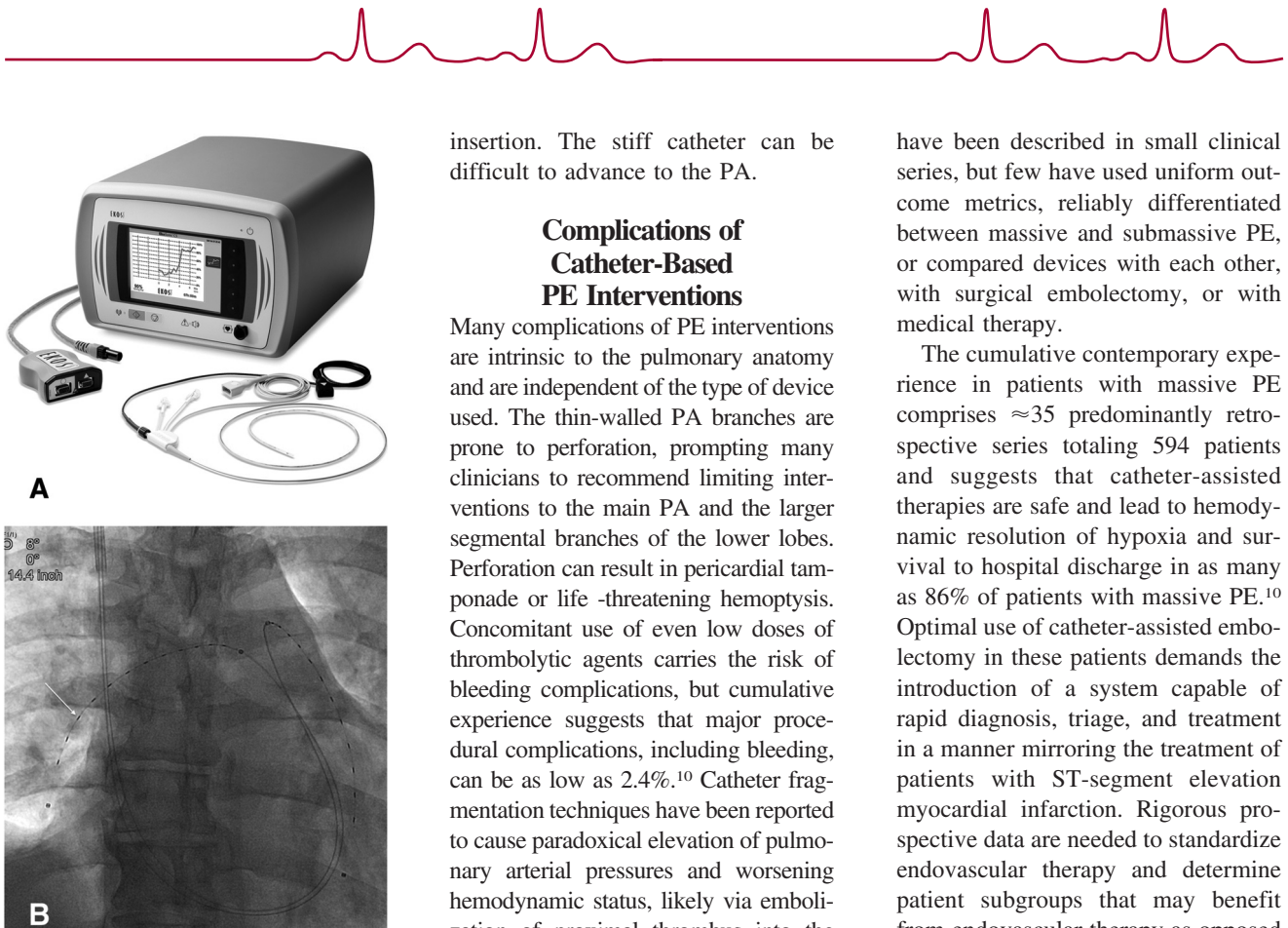


**Figure 4.** **A**, A pulmonary angiogram in a patient with massive bilateral PE and multiple filling defects (arrows). **B**, Repeat angiography after mechanical rheolytic thrombectomy shows improvement in pulmonary perfusion. Restoration of hemodynamic stability allowed additional catheter-directed thrombolysis and further clinical improvement.

system versus standard anticoagulation. In the United States, the efficacy of the device will be studied in an industry-sponsored retrospective registry of patients with submassive PE and RV enlargement, and a prospective single-arm trial, as well.

### Suction Embolectomy

The optimal endovascular intervention would succeed in near-complete removal of pulmonary arterial thrombus without the risk of hemolysis, release of vasoactive agents, or distal embolization. The Greenfield embolectomy catheter aspired to achieve this goal by combining a large-caliber catheter with a suction cup at its end and a syringe to generate suction. Green-



**Figure 5.** Ultrasound-assisted catheter-directed thrombolysis is administered with the aide of the EKOS catheter. **A**, The console, the catheter with multiple side-holes, and the ultrasound-emitting fiber. **B**, The catheter is placed in the right and left lung. Note the multiple ultrasound emitters along the length of the catheter (arrow).

field's early experience showed significant reductions in PA pressures and increase in cardiac output,<sup>25</sup> but, despite technical improvements, the catheter remained difficult to use, and its early success could not be replicated. The Angiovac catheter (Vortex Medical) is a modern reiteration of suction embolectomy. The device is approved by US Food and Drug Administration for removal of undesirable vascular debris and consists of a large-caliber catheter with an expandable funnel at its tip that is connected to a circuit resembling a cardiopulmonary bypass system, where a pump generates suction of 3 L/min, filters the blood, and returns it via another catheter. The large caliber size requires either surgical cut-down or a large-bore sheath

insertion. The stiff catheter can be difficult to advance to the PA.

### Complications of Catheter-Based PE Interventions

Many complications of PE interventions are intrinsic to the pulmonary anatomy and are independent of the type of device used. The thin-walled PA branches are prone to perforation, prompting many clinicians to recommend limiting interventions to the main PA and the larger segmental branches of the lower lobes. Perforation can result in pericardial tamponade or life-threatening hemoptysis. Concomitant use of even low doses of thrombolytic agents carries the risk of bleeding complications, but cumulative experience suggests that major procedural complications, including bleeding, can be as low as 2.4%.<sup>10</sup> Catheter fragmentation techniques have been reported to cause paradoxical elevation of pulmonary arterial pressures and worsening hemodynamic status, likely via embolization of proximal thrombus into the distal branches.<sup>26,27</sup> Some of the complications are device specific. The Angiojet device may be associated with higher rates of periprocedural complications, particularly bradycardia and hemoglobinuria.<sup>10</sup> There is, however, no head-to-head comparison of the various endovascular techniques to assess their relative safety.

### Challenges and Future Directions

Catheter-assisted, pharmacomechanical pulmonary thrombectomy has not been rigorously studied as a viable treatment strategy. This is largely because of low interest in treating venous thromboembolic disease among cardiovascular specialists, complex and heterogeneous patient groups who experience PE, and lack of an optimal percutaneous device to treat the large volume of organized thrombus in the pulmonary arteries. None of the devices or catheters commonly used today are approved by the US Food and Drug Administration. Numerous combinations of endovascular techniques

have been described in small clinical series, but few have used uniform outcome metrics, reliably differentiated between massive and submassive PE, or compared devices with each other, with surgical embolectomy, or with medical therapy.

The cumulative contemporary experience in patients with massive PE comprises  $\approx 35$  predominantly retrospective series totaling 594 patients and suggests that catheter-assisted therapies are safe and lead to hemodynamic resolution of hypoxia and survival to hospital discharge in as many as 86% of patients with massive PE.<sup>10</sup> Optimal use of catheter-assisted embolectomy in these patients demands the introduction of a system capable of rapid diagnosis, triage, and treatment in a manner mirroring the treatment of patients with ST-segment elevation myocardial infarction. Rigorous prospective data are needed to standardize endovascular therapy and determine patient subgroups that may benefit from endovascular therapy as opposed to systemic thrombolysis.

The growing experience in the endovascular treatment of PE demands a concerted effort toward a systematic and prospective evaluation of these therapies to determine which strategies are most beneficial and which patients benefit the most.

### Case Resolution

This patient was immediately transferred to the cardiac catheterization laboratory. Pulmonary angiography revealed thrombus occluding the right and left lower lobe pulmonary arteries. Pulmonary artery pressure was elevated at 47/13 mm Hg. Pulse-spray thrombectomy with the use of the Angiojet catheter resulted in significant resolution of the thrombus. Pulmonary artery pressure decreased to 30/15 mm Hg, and inotropic support was discontinued. Additional catheter-directed thrombolysis was performed in each lung with a low dose of tPA over the course of 18 hours. A retrievable inferior vena cava filter was placed in anticipation of hip surgery. He was extubated the following day. Suc-

cessful open reduction and internal fixation of the hip was performed 6 days later. He was discharged to a rehabilitation facility on warfarin therapy without the need for supplemental oxygen.

Endovascular therapy was chosen over surgical embolectomy because it could be rapidly implemented in this patient in extremis. Systemic thrombolysis was deemed to be relatively contraindicated because of the risk of bleeding at the site of hip fracture. This clinical case highlights some of the advantages of catheter-based interventions: rapid initiation of therapy, very low doses of adjunctive thrombolytic therapy, and the expectation of rapid hemodynamic improvement in patients with an acute thrombotic event. The choice among the 3 treatment modalities should depend on local expertise, patient characteristics, and the speed with which they can be applied.

## Disclosures

None.

## References

- Kucher N, Rossi E, De Rosa M, Goldhaber SZ. Massive pulmonary embolism. *Circulation*. 2006;113:577–582.
- Jaff MR, McMurry MS, Archer SL, Cushman M, Goldenberg N, Goldhaber SZ, Jenkins JS, Kline JA, Michaels AD, Thistlethwaite P, Vedantham S, White RJ, Zierler BK; American Heart Association Council on Cardiopulmonary, Critical Care, Perioperative and Resuscitation; American Heart Association Council on Peripheral Vascular Disease; American Heart Association Council on Arteriosclerosis, Thrombosis and Vascular Biology. Management of massive and submassive pulmonary embolism, iliofemoral deep vein thrombosis, and chronic thromboembolic pulmonary hypertension: a scientific statement from the American Heart Association. *Circulation*. 2011;123:1788–1830.
- Stein PD, Matta F, Janjua M, Yaekoub AY, Jaweesh F, Alrifai A. Outcome in stable patients with acute pulmonary embolism who had right ventricular enlargement and/or elevated levels of troponin I. *Am J Cardiol*. 2010;106:558–563.
- Kline JA, Steuerwald MT, Marchick MR, Hernandez-Nino J, Rose GA. Prospective evaluation of right ventricular function and functional status 6 months after acute submassive pulmonary embolism: frequency of persistent or subsequent elevation in estimated pulmonary artery pressure. *Chest*. 2009;136:1202–1210.
- Konstantinides S, Geibel A, Heusel G, Heinrich F, Kasper W. Heparin plus alteplase compared with heparin alone in patients with submassive pulmonary embolism. *N Engl J Med*. 2002;347:1143–1150.
- Kasper W, Konstantinides S, Geibel A, Olschewski M, Heinrich F, Grosser KD, Rauber K, Iversen S, Redecker M, Kienast J. Management strategies and determinants of outcome in acute major pulmonary embolism: results of a multicenter registry. *J Am Coll Cardiol*. 1997;30:1165–1171.
- Kirschner M. Ein durch die Trendelenburgsche Operation Geheilte Fall von Embolie der Art. *Pulmonalis Arch Klin Chir*. 1924;133:312–359.
- Stein PD, Alnas M, Beemath A, Patel NR. Outcome of pulmonary embolism. *Am J Cardiol*. 2007;99:421–423.
- Greenfield LJ, Kimmell GO, McCurdy WC 3rd. Transvenous removal of pulmonary emboli by vacuum-cup catheter technique. *J Surg Res*. 1969;9:347–52.
- Kuo WT, Gould MK, Louie JD, Rosenberg JK, Sze DY, Hofmann LV. Catheter-directed therapy for the treatment of massive pulmonary embolism: systematic review and meta-analysis of modern techniques. *J Vasc Interv Radiol*. 2009;20:1431–1440.
- Brady AJ, Crake T, Oakley CM. Percutaneous catheter fragmentation and distal dispersion of proximal pulmonary embolus. *Lancet*. 1991;338:1186–1189.
- Schmitz-Rode T, Gunther RW, Pfeffer JG, Neuerburg JM, Geuting B, Biesterfeld S. Acute massive pulmonary embolism: use of a rotatable pigtail catheter for diagnosis and fragmentation therapy. *Radiology*. 1995;197:157–162.
- Schmitz-Rode T, Janssens U, Schild HH, Basche S, Hanrath P, Gunther RW. Fragmentation of massive pulmonary embolism using a pigtail rotation catheter. *Chest*. 1998;114:1427–1436.
- Schmitz-Rode T, Janssens U, Duda SH, Erley CM, Gunther RW. Massive pulmonary embolism: percutaneous emergency treatment by pigtail rotation catheter. *J Am Coll Cardiol*. 2000;36:375–380.
- Kucher N, Windecker S, Banz Y, Schmitz-Rode T, Mettler D, Meier B, Hess OM. Percutaneous catheter thrombectomy device for acute pulmonary embolism: in vitro and in vivo testing. *Radiology*. 2005;236:852–858.
- Popovic P, Bunc M. Massive pulmonary embolism: percutaneous emergency treatment using an Aspirex thrombectomy catheter. *Cardiovasc Interv Radiol*. 2010;33:1052–1055.
- Müller-Hülsbeck S, Brossmann J, Jahnke T, Grimm J, Reuter M, Bewig B, Heller M. Mechanical thrombectomy of major and massive pulmonary embolism with use of the Amplatz thrombectomy device. *Invest Radiol*. 2001;36:317–322.
- Reekers JA, Baarslag HJ, Koolen MG, Van Delden O, van Beek EJ. Mechanical thrombectomy for early treatment of massive pulmonary embolism. *Cardiovasc Interv Radiol*. 2003;26:246–250.
- Koning R, Cribier A, Gerber L, Eltchaninoff H, Tron C, Gupta V, Soyler R, Letac B. A new treatment for severe pulmonary embolism: percutaneous rheolytic thrombectomy. *Circulation*. 1997;96:2498–2500.
- Chechi T, Vecchio S, Spaziani G, Giuliani G, Giannotti F, Arcangeli C, Rubboli A, Margheri M. Rheolytic thrombectomy in patients with massive and submassive acute pulmonary embolism. *Catheter Cardiovasc Interv*. 2009;73:506–513.
- Braaten JV, Goss RA, Francis CW. Ultrasound reversibly disaggregates fibrin fibers. *Thromb Haemost*. 1997;78:1063–1068.
- Chamsuddin A, Nazzal L, Kang B, Best I, Peters G, Panah S, Martin L, Lewis C, Zeinati C, Ho JW, Venbrux AC. Catheter-directed thrombolysis with the Endowave system in the treatment of acute massive pulmonary embolism: a retrospective multicenter case series. *J Vasc Interv Radiol*. 2008;19:372–376.
- Lin PH AS, Bechara CF, Athamneh H, Weakley SM, Kobayashi K, Kougiass P. Comparison of percutaneous ultrasound-accelerated thrombolysis versus catheter-directed thrombolysis in patients with acute massive pulmonary embolism. *Vascular*. 2009;17:S137.
- Engelhardt TC, Taylor AJ, Simprini LA, Kucher N. Catheter-directed ultrasound-accelerated thrombolysis for the treatment of acute pulmonary embolism. *Thromb Res*. 2011;128:149–154.
- Greenfield LJ, Proctor MC, Williams DM, Wakefield TW. Long-term experience with transvenous catheter pulmonary embolism. *J Vasc Surg*. 1993;18:450–458.
- Nakazawa K, Tajima H, Murata S, Kumita SI, Yamamoto T, Tanaka K. Catheter fragmentation of acute massive pulmonary thromboembolism: distal embolisation and pulmonary arterial pressure elevation. *Br J Radiol*. 2008;81:848–854.
- Kumar N, Janjigian Y, Schwartz DR. Paradoxical worsening of shock after the use of a percutaneous mechanical thrombectomy device in a postpartum patient with a massive pulmonary embolism. *Chest*. 2007;132:677–679.

KEY WORDS: pulmonary embolism ■ thromboembolism ■ thrombolysis ■ thrombus aspiration