

## RESEARCH LETTER

# Mavacamten Favorably Impacts Cardiac Structure in Obstructive Hypertrophic Cardiomyopathy

## EXPLORER-HCM Cardiac Magnetic Resonance Substudy Analysis

**N**o medical therapy for obstructive hypertrophic cardiomyopathy modifies disease expression or outcomes.<sup>1,2</sup> Mavacamten, a cardiac myosin inhibitor that reduces actin–myosin cross-bridge formation, improved exercise capacity, left ventricular outflow tract gradients, symptoms, and health status in patients with symptomatic obstructive hypertrophic cardiomyopathy in the phase 3 EXPLORER-HCM (Clinical Study to Evaluate Mavacamten [MYK-461] in Adults with Symptomatic Obstructive Hypertrophic Cardiomyopathy) trial.<sup>3,4</sup> The cardiac magnetic resonance (CMR) imaging substudy examined the effect of mavacamten versus placebo on cardiac structure and function.

The EXPLORER-HCM trial has been described previously.<sup>3,4</sup> Each site's institutional review board/independent ethics committee approved the study protocol. All participants provided written informed consent. In this substudy, the primary end point was the change in left ventricular (LV) mass index from baseline to week 30; exploratory end points included change in cellular hypertrophy, left atrial volume index, LV function, myocardial fibrosis measured by extracellular volume fraction and late gadolinium enhancement, NT-proBNP (N-terminal pro-B-type natriuretic peptide), and hs-cTnI (high-sensitivity cardiac troponin I). CMR imaging was performed using 1.5 or 3.0T systems (Philips Medical Systems or Siemens Healthcare) and included in the following order: (1) steady-state, free-precession breath-hold cine of a LV short-axis stack; (2) native T1 mapping with Modified Look-Locker Inversion Recovery in 3 equally spaced short-axis cuts (base, mid, apical) covering 16 of the 17 American Heart Association segments; (3) intravenous gadolinium contrast injection at 0.15 mmol/kg; (4) long-axis cine (2-, 3-, 4-chamber); (5) repeat T1 mapping in matching locations at 3, 10, and 25 minutes postcontrast; and (6) late gadolinium enhancement short-axis stack matching cine locations started at 15 minutes postcontrast. Between-group differences of those changes were evaluated using Wilcoxon–Mann-Whitney tests, and 95% CIs were based on normal approximation. All statistical tests were conducted as 2-sided tests with a significance level of 0.05; *P* values were not adjusted for multiplicity. Missing data were sparse and not imputed. The data that support the findings of this study are available from the corresponding author on reasonable request.

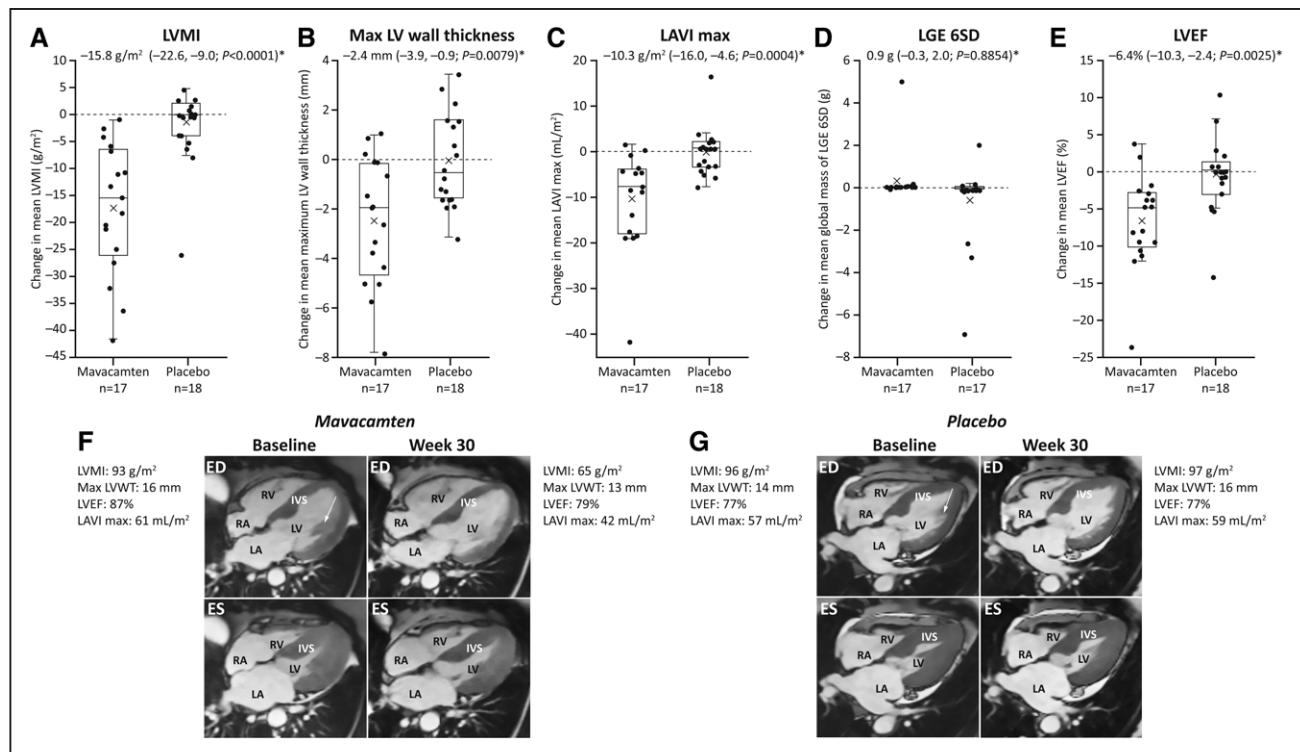
Thirty-five patients were randomized (mavacamten, *n*=17; placebo, *n*=18). Mean age was 60.3 years, and 42.9% were female. Demographics/baseline characteristics were balanced between groups. Patients receiving mavacamten experienced a greater reduction in mean (SD) LV mass index, the primary end point, from baseline to week 30 versus patients in the placebo group (–17.4 [12.1] g/m<sup>2</sup> and –1.6 [7.4] g/m<sup>2</sup>, respectively; mean between-group difference, –15.8 g/m<sup>2</sup> [95% CI, –22.6 to –9.0]; *P*<0.0001; Figure). LV mass decreased in the mavacamten group compared with placebo group (between-group difference, –30.0 g [95% CI, –43.3 to –16.7]; *P*<0.0001). The mean (SD) absolute intracellular myocardial mass

Sara Saberi<sup>1</sup> MD  
 Nuno Cardim, MD  
 Mohamad Yamani, MD  
 Jeanette Schulz-Menger  
 Wanying Li, PhD  
 Victoria Florea, MD  
 Amy J. Sehner, MD  
 Raymond Y. Kwong, MD,  
 MPH  
 Michael Jerosch-Herold,  
 PhD  
 Ahmad Masri<sup>2</sup> MD  
 Anjali Owens, MD  
 Neal K. Lakdawala<sup>3</sup> MD  
 Christopher M. Kramer<sup>4</sup>,  
 MD  
 Mark Sherrid<sup>5</sup> MD  
 Tim Seidler, MD  
 Andrew Wang<sup>6</sup> MD  
 Farbod Sedaghat-  
 Hamedani, MD  
 Benjamin Meder<sup>7</sup> MD  
 Ofer Havakuk, MD  
 Daniel Jacoby<sup>8</sup> MD

**Key Words:** antagonists & inhibitors  
 ■ cardiac myosins ■ cardiomyopathy,  
 hypertrophic ■ drug therapy  
 ■ magnetic resonance imaging  
 ■ physiopathology

© 2021 American Heart Association, Inc.

<https://www.ahajournals.org/journal/circ>



**Figure.** Effects of mavacamten on parameters of cardiac structure, function, and fibrosis assessed by cardiac magnetic resonance.

Treatment with mavacamten reduced LVMI (A), max LV wall thickness (B), LAVI max (C), and LVEF (E) in the obstructive hypertrophic cardiomyopathy patient vs no changes in the patient from the placebo group. No changes in fibrosis assessed by LGE were observed (D). F and G, Cardiac magnetic resonance 4-chamber long-axis images in ED and ES showing left ventricular basal septal hypertrophy and papillary muscle (white arrows) and enlarged LA at baseline. \*Data are mean (95% CI) between-group difference at week 30. The arrows indicate the papillary muscle. ED indicates end diastole; ES, end systole; IVS, interventricular septum; LA, left atrium; LAVI, left atrial volume index; LGE, late gadolinium enhancement; LV, left ventricle; LVEF, left ventricular ejection fraction; LVMI, left ventricle mass index; LVWT, left ventricle wall thickness; RA, right atrium; and RV, right ventricle.

index ( $[(1 - \text{global extracellular volume fraction}) \times \text{LV mass}] / \text{body surface index}$ ) decreased with mavacamten ( $-14.1 [9.5] \text{ g/m}^2$ ) versus no change in placebo ( $-1.0 [6.5] \text{ g/m}^2$ ; mean between-group difference,  $-13.1 \text{ g/m}^2$  [95% CI,  $-18.7$  to  $-7.5$ ];  $P = 0.0002$ ). Mavacamten was associated with a greater reduction in maximum LV wall thickness than placebo (Figure). In both groups, baseline mean LV ejection fraction was elevated and remained normal through week 30 despite a mild reduction observed with mavacamten (Figure). In the CMR substudy, LV ejection fraction reduction with mavacamten was similar to that assessed by echocardiogram in the EXPLORER-HCM population ( $-6.6\% [6.39\%]$  and  $-3.9\% [7.7\%]$ ). There was no LV ejection fraction of  $<50\%$  by CMR. Of the 9 patients in EXPLORER-HCM (7 mavacamten, 2 placebo) with a transient decrease in LV ejection fraction of  $<50\%$  (median 48%) by echocardiogram,<sup>4</sup> 2 were in the CMR substudy (1 mavacamten, 1 placebo) and both were asymptomatic at time of the measure. Myocardial contractile fraction ( $[\text{LV stroke volume} / \text{LV myocardial volume}] \times 100$ ; LV myocardial volume = LV mass  $[1.05 \text{ g/mL}]$ ), another parameter of LV systolic function, was similar in both groups at baseline (mavacamten,  $61.0\% [17.9\%]$ ; placebo,  $60.1\% [17.3\%]$ ) and remained unchanged at week 30 (mean between-group difference,  $2.4\% [95\% \text{ CI}, -4.5$

to  $9.3$ ];  $P = 0.7043$ ). A greater reduction in maximum left atrial volume index was observed with mavacamten versus placebo (mean between-group difference,  $-10.3 \text{ mL/m}^2$  [95% CI,  $-16.0$  to  $-4.6$ ];  $P = 0.0004$ ; Figure). There was little fibrosis at baseline with no notable within- or between-group changes in late gadolinium enhancement (Figure) and extracellular volume fraction (mean change [SD] global extracellular volume fraction,  $0.02 [0.07]$  in the mavacamten group;  $0.00 [0.03]$  in the placebo group). There was a 50% greater reduction in hs-cTnI and 80% greater reduction in NT-proBNP with mavacamten versus placebo ( $P < 0.01$ ). Change in LV mass index was positively correlated with change in hs-cTnI ( $n = 31$ ;  $\text{Rho} = 0.75$  [95% CI,  $0.53$ – $0.87$ ]).

The CMR substudy is the first to show favorable impact of a pharmacological agent on cardiac remodeling in HCM. Mavacamten was associated with significant reductions in absolute intracellular myocardial mass index as well as LV mass index, maximum LV wall thickness, and left atrial volume index—all predictors of poor prognosis in obstructive hypertrophic cardiomyopathy.<sup>5</sup> Importantly, there were no changes in fibrosis or myocardial contractile fraction observed during 30 weeks, and contractile function remained normal. Reductions in hypertrophy and left atrial volumes were observed concurrent with reductions in levels of plasma

biomarkers of myocardial stress and injury. These findings suggest that even short-term mavacamten treatment had a favorable effect on cardiac structure in patients with obstructive hypertrophic cardiomyopathy.

## ARTICLE INFORMATION

This work was presented as an abstract at the American Heart Association Scientific Sessions, November 13 to November 17, 2020.

Clinical Trial Registration URL: <https://www.clinicaltrials.gov>. Unique identifier: NCT03470545.

## Acknowledgments

The authors thank the patients, the study site coordinators, and the EXPLORER-HCM (Clinical Study to Evaluate Mavacamten [MYK-461] in Adults with Symptomatic Obstructive Hypertrophic Cardiomyopathy) study team members. Medical writing support was provided by Dr Nicolas Bertheleme of Oxford PharmaGenesis (Oxford, UK), with funding from MyoKardia.

## Correspondence

Sara Saberri, MD, MS, 1500 East Medical Center Dr, CVC, Suite 2364, SPC 5853, Ann Arbor, MI 48109-5853. Email [saberis@med.umich.edu](mailto:saberis@med.umich.edu)

## Affiliations

Department of Internal Medicine, Division of Cardiovascular Medicine, University of Michigan Medical School, Ann Arbor (S.S.). Department of Cardiology, Cardiovascular MR and CT unit (UNICA), Hospital da Luz, Lisbon, Portugal (N.C.). Mayo Clinic, Jacksonville, FL (M.Y.). Charité Medical University Berlin, ECRC and Department of Cardiology, HELIOS Klinik Berlin-Buch, Clinic for Cardiology and Nephrology, DZHK partnersite Berlin, Germany (J.S.-M.). MyoKardia, Brisbane, CA (W.L., V.F., A.J.S.). Cardiovascular Division, Department of Medicine (R.Y.K., M.J.-H.) and Department of Cardiovascular Medicine (N.K.L.), Brigham and Women's Hospital, Harvard Medical School, Boston, MA. Center for Hypertrophic Cardiomyopathy, Knight Cardiovascular Institute, Oregon Health & Science University, Portland (A.M.). Center for Inherited Cardiac Disease, Division of Cardiovascular Medicine, University of Pennsylvania Perelman School of Medicine, Philadelphia (A.O.). Cardiovascular Division, Department of Medicine, University of Virginia Health System, Charlottesville (C.M.K.). Hypertrophic Cardiomyopathy Program, NYU Langone Health, New York (M.S.). Department of Cardiology and Pulmonology, University Medical Center Göttingen, Germany (T.S.). Duke Cardiology, Duke Health Center at Southpoint, Durham, NC (A.W.). Department of Internal Medicine III, Institute for Cardiomyopathies, University of Heidelberg, Germany (F.S.-H., B.M.). Department of Cardiology, Tel Aviv Medical Center, affiliated to Sackler School of Medicine, Tel Aviv University, Israel (O.H.). Section of Cardiovascular Medicine, Yale School of Medicine, New Haven, CT (D.J.).

## Sources of Funding

The EXPLORER-HCM trial was funded by MyoKardia.

## Disclosures

Personal fees may include, but are not limited to, consulting fees, lecture fees, research funding, honoraria for steering committee activities, speaker fees or travel support. Dr Saberri received personal fees from MyoKardia. Dr Cardim received personal fees from MyoKardia. Dr Kwong received a research grant from MyoKardia and Dr Jerosch-Herold received funding support from this research grant. Dr Masri received personal fees from Akcea, Ionis, and Pfizer. Dr Owens received personal fees from Cytokinetics and MyoKardia. Dr Lakdawala received personal fees from Array BioPharma, MyoKardia, Pfizer, and Sarepta. Dr Kramer received personal fees from Bayer, Cytokinetics, and MyoKardia. Dr Wang received personal fees from Cytokinetics, Medscape, and MyoKardia. Dr Sedaghat-Hamedani received personal fees from MyoKardia. Drs Li, Florea, and Sehnert are employees of MyoKardia. The other authors report no conflicts.

## REFERENCES

- Gersh BJ, Maron BJ, Bonow RO, Dearani JA, Fifer MA, Link MS, Naidu SS, Nishimura RA, Ommen SR, Rakowski H, et al; American College of Cardiology Foundation/American Heart Association Task Force on Practice Guidelines. 2011 ACCF/AHA guideline for the diagnosis and treatment of hypertrophic cardiomyopathy: a report of the American College of Cardiology Foundation/American Heart Association task force on practice guidelines. Developed in collaboration with the American Association for Thoracic Surgery, American Society of Echocardiography, American Society of Nuclear Cardiology, Heart Failure Society of America, Heart Rhythm Society, Society for Cardiovascular Angiography and Interventions, and Society of Thoracic Surgeons. *J Am Coll Cardiol*. 2011;58:e212–260.
- Spoladore R, Maron MS, D'Amato R, Camici PG, Olivetto I. Pharmacological treatment options for hypertrophic cardiomyopathy: high time for evidence. *Eur Heart J*. 2012;33:1724–1733. doi: 10.1093/eurheartj/ehs150
- Ho CY, Olivetto I, Jacoby D, Lester SJ, Roe M, Wang A, Waldman CB, Zhang D, Sehnert AJ, Heitner SB. Study design and rationale of EXPLORER-HCM: evaluation of mavacamten in adults with symptomatic obstructive hypertrophic cardiomyopathy. *Circ Heart Fail*. 2020;13:e006853. doi: 10.1161/CIRCHEARTFAILURE.120.006853
- Olivetto I, Oreziak A, Barriales-Villa R, Abraham TP, Masri A, Garcia-Pavia P, Saberri S, Lakdawala NK, Wheeler MT, Owens A, et al; EXPLORER-HCM study investigators. Mavacamten for treatment of symptomatic obstructive hypertrophic cardiomyopathy (EXPLORER-HCM): a randomised, double-blind, placebo-controlled, phase 3 trial. *Lancet*. 2020;396:759–769. doi: 10.1016/S0140-6736(20)31792-X
- Marian AJ, Braunwald E. Hypertrophic cardiomyopathy: genetics, pathogenesis, clinical manifestations, diagnosis, and therapy. *Circ Res*. 2017;121:749–770.