Carotid Intraplaque Hemorrhage Predicts Recurrent Symptoms in Patients With High-Grade Carotid Stenosis

Nishath Altaf, MRCS(Ed); Shane T. MacSweeney, FRCS; John Gladman, FRCP; Dorothee P. Auer, PhD

Background and Purpose—Carotid intraplaque hemorrhage (IPH), known to be associated with plaque instability, may convey a higher stroke risk. The aim of this study was to assess whether the identification of IPH by MRI predicts recurrent clinical cerebrovascular events.

Methods—Sixty-six patients with high-grade symptomatic carotid stenosis underwent MRI of the carotid arteries and were followed until carotid endarterectomy or 30 days.

Results—Of the 66 patients with a median follow up of 33.5 days, 44 (66.7%) were found on MRI to have ipsilateral carotid IPH. Fifteen recurrent events were associated with ipsilateral carotid IPH. Only 2 recurrent events occurred in the absence of IPH. IPH increased the risk of recurrent ischemia (hazard ratio=4.8; 95% CI=1.1 to 20.9, $P<0.05$).

Conclusion—IPH as detected by MRI predicts recurrent cerebrovascular events in patients with symptomatic high-grade carotid stenosis. **(*Stroke*. 2007;38:1633-1635.)**

Key Words: carotid artery disease ■ ischemia ■ magnetic resonance imaging

Randomized, controlled trials have demonstrated the benefit of performing carotid endarterectomy (CEA) in patients with symptomatic high-grade carotid stenosis.[1] Although the degree of stenosis is a valid marker of stroke risk, it does not have a high predictive value. Therefore, identification of other high-risk plaque features may improve risk assessment and allow for targeted intervention.

Intraplaque hemorrhage (IPH) is a critical factor in the growth of atherosclerotic plaques and plaque destabilization[2] and can be detected using a T1-weighted fat-suppressed MRI.[3] Based on this technique, histological complex carotid plaques can be accurately predicted.[3] Recently, IPH was found to predict ischemic events in patients with asymptomatic carotid stenosis.[4]

We aimed to investigate the value of imaging IPH in patients with symptomatic high-grade carotid artery stenosis to predict short-term recurrent ischemic events.

Methods

Participants were consecutively recruited between January 2004 and April 2006 from the vascular clinic at the time CEA was offered. The inclusion criteria were carotid stenosis between 60% to 99% using established Duplex scanning criteria[5]; ipsilateral anterior circulation ischemic events (stroke, transient ischemic attack [TIA], and amaurosis fugax [AmF]) within the previous 6 months and within 1 month from February 2005 onward. Exclusion criteria were contraindication for MRI or CEA before scheduled MRI. Clinical patient management was not affected by this study. The study was approved by the local research ethics committee. Participants gave written informed consent.

All participants had a baseline clinical assessment during their first clinic attendance when MRI was scheduled. Participants were prospectively assessed (blind to MRI findings) by an experienced clinician for clinical evidence of a further vascular neurological outcome (stroke, AmF, or TIA) at the time of MRI, before CEA, or after 30 days in those no longer considered for CEA. Interim assessments were prompted by the participants' presentations. All strokes were confirmed to be ischemic by neuroimaging.

IPH was shown to be stable for some time after an event,[6] so we can safely assume the IPH status was the same at baseline and when measured a few days later (MRI).

Participants' MRI scans were performed on one of three 1.5-T scanners: Vision, (Siemens Medical), Intera (Philips), or Signa (General Electric) using standard receive-only quadrature neck array coils. As previously described,[3] a coronal T1-weighted 3-dimensional gradient echo sequence with effective blood nulling and fat suppression was deployed.

Presence of IPH was determined by consensus between two blinded experienced researchers. IPH was diagnosed if the signal intensity of the plaque exceeded that of adjacent skeletal muscle by more than 50% (Figure 1).

χ^2 and Mann–Whitney tests were used to compare categorical and continuous demographic and risk factors between patients with and without IPH.

The effect of IPH on the rate of recurrent cerebral ischemia (stroke, TIA, or AmF) was examined using Kaplan–Meier analysis and univariate Cox regression analyses. The follow-up period was the time from vascular clinic assessment to recurrent ischemia, CEA, or 30 days if CEA was cancelled. To explore whether IPH constitutes an independent risk factor, a multivariate Cox regression model was used adjusting for known risk factors (age, degree of stenosis, and the time between initial

Downloaded from http://ahajournals.org by on March 4, 2022

Received September 26, 2006; final revision received November 27, 2006; accepted December 11, 2006.

From the Department of Academic Radiology (N.A., D.P.A.), University of Nottingham, Queen's Medical Centre, Nottingham, UK; the Department of Vascular and Endovascular Surgery (N.A., S.T.M.), Queen's Medical Centre, Nottingham, UK; and the Division of Rehabilitation and Ageing (J.G.), University of Nottingham, Queen's Medical Centre, Nottingham, UK.

Correspondence to Nishath Altaf, MRCS(Ed), Department of Academic Radiology, University of Nottingham, Queen's Medical Centre, Nottingham, UK. E-mail nish.altaf@nottingham.ac.uk

© 2007 American Heart Association, Inc.

***Stroke* is available at http://www.strokeaha.org** **DOI: 10.1161/STROKEAHA.106.473066**

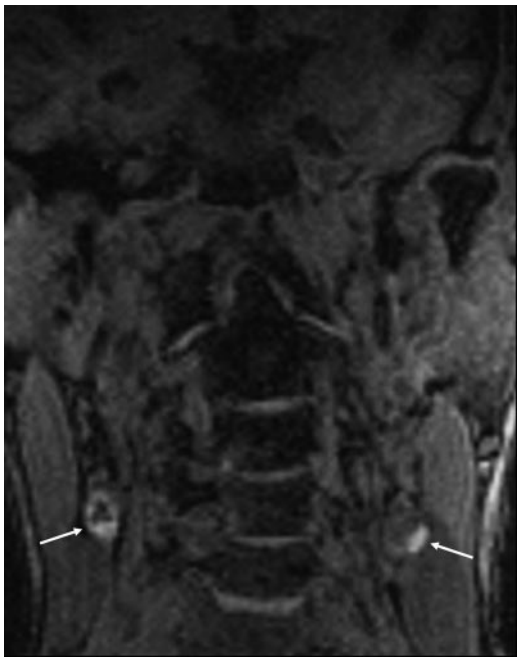

Figure 1. The presence of carotid IPH seen bilaterally in a coronal section (white arrows).

symptom and clinic) and additional factors based on results of univariate analysis (ischemic heart disease and myocardial infarction). Further corroboration was sought using Harrell's' c statistic and the Akaike information criterion. Hazard ratios (HR) and 95% CIs are given with statistical significance at $P<0.05$.

Results

Of the 76 participants recruited, 7 withdrew before or at MRI, 2 were excluded because of carotid artery occlusion, and one for being judged asymptomatic. Of the remaining 66 patients, 44 (66.7%) ipsilateral carotid arteries showed IPH. There were no differences in risk factors between the 2 groups (Table).

During a mean follow up of 33.5 days (interquartile range=17.8 to 60.3), 17 participants experienced recurrent ischemic events of which 15 (3 strokes, 8 TIA, 4 AmF) occurred in patients with ipsilateral IPH and 2 (one TIA, one AmF) without IPH. IPH decreased the event-free survival (log rank test=5.3, $P=0.02$, Figure 2) and univariate Cox analysis confirmed that ipsilateral IPH increased the risk of recurrent ischemic events (HR=4.8, 95% CI=1.1 to 20.9, $P<0.05$). There were also significant associations between recurrent ischemia and the presence of IHD (HR=2.6; 95% CI=1.0 to 6.6), myocardial infarction (HR=3.1; 95% CI=1.2 to 8.4), and the time interval between the presenting symptom and baseline assessment (HR=0.97; 95% CI=0.94 to 1.00).

The multivariate Cox regression model adjusting for age, degree of stenosis, IHD, myocardial infarction, and time between presenting symptoms and baseline shows an independent effect from IPH (HR=13.0, 95% CI=2.5 to 67.8, $P<0.005$). By adding IPH to the prediction model, Harrell's c increased from 0.80 to 0.85 and Akaike information criterion decreased from 125.11 to 113.45 suggesting a usefully improved model.

Risk Factors in Participants With and Without IPH on MRI

	IPH-Positive (n=44, 66.7%)	IPH-Negative (n=22, 33.3%)	*P* Value
Age, median years (interquartile range)	69.5 (65.0–77.8)	71.0 (61.0–77.0)	0.6
Sex—female, n (%)	10 (22.8)	10 (45.5)	0.1
Hypertension (%)	35 (79.5)	17 (77.3)	1.0
Ischemic heart disease, n (%)	12 (27.3)	9 (41.0)	0.3
Previous myocardial infarction, n (%)	7 (15.9)	4 (18.2)	1.0
Diabetes mellitus, n (%)	4 (9.1)	2 (9.1)	1.0
Smoking, n (%)	28 (54.5)	15 (68.2)	0.4
Statin use, n (%)	40 (84.1)	20 (90.9)	0.7
Stenosis (%)			
60–69	8 (18.2)	0	
70–95	32 (72.7)	20 (90.9)	0.1
95–99	4 (9.1)	2 (9.1)	
Antiplatelet agent (s) used, n (%)			
None	1 (2.3)	0	
Aspirin	38 (86.4)	18 (81.8)	0.5
Aspirin+dipyridamole	2 (4.6)	0	
Clopidogrel	2 (4.6)	3 (13.7)	
Heparin	1 (2.3)	1 (5.6)	
Type of symptom on presentation, n (%)			
Stroke	15 (34.1)	6 (27.3)	0.8
TIA	21 (47.7)	12 (54.5)	
AmF	8 (18.2)	4 (18.2)	
Time between symptom and clinic review, median days (interquartile range)	18.0 (8.0–34.0)	19.5 (11.0–36.8)	0.6
Time between symptom and MRI, median days (interquartile range)	27.5 (15.3–63.3)	41.0 (25.5–80.3)	0.1

Downloaded from http://ahajournals.org by on March 4, 2022

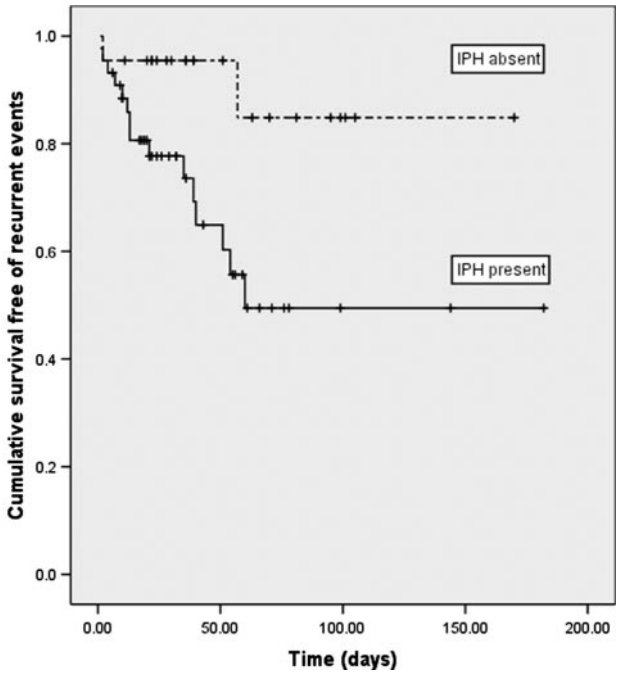

Figure 2. Estimation of event-free survival in a patient with ipsilateral IPH+ and IPH− as per Kaplan–Meier survival plots.

Discussion

This study is the first to demonstrate the clinical significance of MRI detection of intraplaque hemorrhage in patients with symptomatic high-grade carotid stenosis. The presence of MRI IPH predicted the short-term combined risk of ipsilateral AmF, TIA, and stroke.

Our findings are in agreement with pathological studies suggesting that IPH is an important biological feature affecting the behavior of unstable atherosclerotic plaques[2] and their progression.[7] There is also excellent agreement with a recent MRI study showing that IPH predicts symptoms in patients with asymptomatic carotid disease with an HR of 5.2.[4]

We have furthermore shown that IPH can be considered as an independent risk factor. Although the multivariate testing was limited by the small sample size, IPH was found to improve the prediction model without any relevant penalties.

The high negative predictive value for recurrent ischemic events in the absence of IPH will reduce the expected benefit from CEA. If a low risk of stroke were to be confirmed in patients without IPH, up to one third of currently surgically treated patients may no longer require CEA. Targeting surgery to those who truly benefit would increase its efficiency and reduce adverse effects for those not needing the intervention.

The study was however limited by the small sample size and short observation period. The current recommendations forbid any delay in intervention for this group of patients.[1] Thus, the observations were only possible because in our center, as in much of the United Kingdom,[8] there is often a considerable waiting time between the decision to offer a CEA and the surgery itself.

In conclusion, this study shows a significant and strong association between recurrent clinical ischemia and intraplaque hemorrhage in patients with symptomatic high-grade carotid disease. If a similar effect were to be found for stroke prediction alone, carotid MRI could substantially change current clinical practice by facilitating improved clinical outcomes through targeted treatment.

Acknowledgments

We acknowledge the Stroke Association, UK; Special Trustees for Nottingham University Hospitals; and the Mason Medical Research Foundation for funding this study. We additionally thank Mr W.G. Tennant and Mrs S.N. Chandrasekar, Consultant Vascular Surgeons, Department of Vascular and Endovascular Surgery, Queen's Medical Centre, Nottingham, for providing patients to be recruited into this study; and to Dr Paul Silcocks, medical statistician, Trent Research and Development Support Unit, University of Nottingham, Queen's Medical Centre, Nottingham, for statistical advice.

Disclosures

None.

References

1. Rothwell PM, Eliasziw M, Gutnikov SA, Warlow CP, Barnett HJ, Carotid Endarterectomy Trialists Collaborators. Endarterectomy for symptomatic carotid stenosis in relation to clinical subgroups and timing of surgery. *Lancet*. 2004;363:915–924.
2. Virmani R, Kolodgie FD, Burke AP, Finn AV, Gold HK, Tulenko TN, Wrenn SP, Narula J. Atherosclerotic plaque progression and vulnerability to rupture: angiogenesis as a source of intraplaque hemorrhage. *Arterioscler Thromb Vasc Biol*. 2005;25:2054–2061.
3. Moody AR, Murphy RE, Morgan PS, Martel AL, Delay GS, Allder S, MacSweeney ST, Tennant WG, Gladman J, Lowe J, Hunt BJ. Characterization of complicated carotid plaque with magnetic resonance direct thrombus imaging in patients with cerebral ischemia. *Circulation*. 2003; 107:3047–3052.
4. Takaya N, Yuan C, Chu B, Saam T, Underhill H, Cai J, Tran N, Polissar NL, Isaac C, Ferguson MS, Garden GA, Cramer SC, Maravilla KR, Hashimoto B, Hatsukami TS. Association between carotid plaque characteristics and subsequent ischemic cerebrovascular events: a prospective assessment with MRI—initial results. *Stroke*. 2006;37:818–823.
5. Sidhu PS, Allan PL. Ultrasound assessment of internal carotid artery stenosis. *Clin Radiol*. 1997;52:654–658.
6. Daniels L, Altaf N, Morgan PS, MacSweeney ST, Moody A, Auer DP, Gladman J. Natural history of complex plaque in the carotid arteries of symptomatic plaques with moderate carotid stenosis. *Cerebrovasc Dis*. 2005;19:22.
7. Takaya N, Yuan C, Chu B, Saam T, Polissar NL, Jarvik GP, Isaac C, McDonough J, Natiello C, Small R, Ferguson MS, Hatsukami TS. Presence of intraplaque hemorrhage stimulates progression of carotid atherosclerotic plaques: a high-resolution magnetic resonance imaging study. *Circulation*. 2005;111:2768–2775.
8. Fairhead JF, Mehta Z, Rothwell PM. Population-based study of delays in carotid imaging and surgery and the risk of recurrent stroke. *Neurology*. 2005;65:371–375.

Downloaded from http://ahajournals.org by on March 4, 2022