

Therapeutic Modulation of Cerebral Microhemorrhage in a Mouse Model of Cerebral Amyloid Angiopathy

Mark Fisher, MD; Vitaly Vasilevko, PhD; Giselle F. Passos, PhD; Christopher Ventura; Daniel Quiring; David H. Cribbs, PhD

Background and Purpose—The aging brain demonstrates frequent MRI and pathological evidence of cerebral microbleeds, which are often associated with cerebral amyloid angiopathy. To develop new therapeutic strategies for this disorder, we studied cerebral microhemorrhage in a well-characterized mouse model of cerebral amyloid angiopathy.

Methods—Tg2576 mice were studied at ages ranging from 2 to 21 months. Spontaneous and induced microscopic bleeding was analyzed with and without a passive anti-amyloid immunization regimen and dietary supplementation of ischemic stroke prevention medication dipyridamole.

Results—Areas of microhemorrhage were easily demonstrated and were significantly more prominent in the oldest mice and in animals treated with anti-amyloid immunotherapy. Dipyridamole supplementation in the diet generated plasma levels >790 ng/mL within the range seen clinically. Dipyridamole treatment did not worsen frequency and size of cerebral microscopic bleeding.

Conclusions—The Tg2576 mouse is a useful model to study progression and modification of spontaneous and immunotherapy-induced cerebral microhemorrhage. Absence of microhemorrhage worsening with dipyridamole treatment suggests a potential therapeutic role of this agent when ischemic and microhemorrhagic lesions coexist. (*Stroke*. 2011;42:3300-3303.)

Key Words: Alzheimer ■ amyloid angiopathy ■ animal models ■ antiplatelet drugs ■ basic science ■ experimental ■ intracerebral hemorrhage ■ microcirculation

There is increasing recognition of the high prevalence of cerebral microbleeds in the aging population. Over the age of 60 years, MRI evidence of cerebral microbleeds is present in approximately 20% of the population; this number rises to nearly 40% for individuals aged >80 years.¹ Moreover, postmortem pathology studies demonstrate microscopic brain hemorrhages occurring at the capillary level in the vast majority of individuals aged >70 years.^{2,3}

There are at least two key issues that emanate from these microbleed observations. First, there is the necessity for establishing animal models of this disorder that will enable investigators to delineate pathophysiological mechanisms of microbleed formation. Second, new treatments and treatment modifications are needed to address the microbleeds themselves.

The issue of microbleeds treatment is of necessity complex. Microbleeds are not only common, but they do not occur in a neurovascular vacuum. Microbleeds may coexist with other forms of cerebrovascular disease. Cerebral white matter disease, which has at least a partial microvascular origin,⁴ has a strong association with cerebral microbleeds in the presence of cerebral amyloid angiopathy.⁵ Moreover,

ischemic stroke may coexist with cerebral microbleeds, leading to a profound challenge in stroke neurology: how to protect the patient against ischemic stroke at the same time as not worsening the brain hemorrhage potential of cerebral microbleeds. The concept of “mixed cerebrovascular disease” has thus been established to encompass the wide spectrum of ischemic and hemorrhagic cerebrovascular disease, both clinical and subclinical.⁶

It is against this background that we initiated the current study in which we analyzed microhemorrhage in a well-characterized mouse model of Alzheimer disease and cerebral amyloid angiopathy. The Tg2576 transgenic mouse has been extensively studied in the course of investigations of Alzheimer disease-like amyloid deposition.⁷ In the current study, we have used this mouse model to investigate the development of brain microhemorrhage as well as initiate new therapeutic strategies directed at the microhemorrhages themselves. We thus used the Tg2576 mouse model, alone and modified by passive immunization,^{8,9} with and without the ischemic stroke prevention medication dipyridamole.¹⁰ The establishment of reliable animal models of microhemorrhage and related therapeutic interventions should have translational

Received May 22, 2011; final revision received June 16, 2011; accepted June 22, 2011.

From the Departments of Neurology (M.F., D.H.C.), Anatomy & Neurobiology (M.F.), and Pathology & Laboratory Medicine (M.F.) and UCI MIND (V.V., G.F.P., C.V., D.Q., D.H.C.), University of California Irvine, Irvine, CA.

Correspondence to Mark Fisher, MD, Department of Neurology, UC Irvine Medical Center, 101 The City Drive South, Shanbrom Hall, Room 121, Orange, CA 92868. E-mail mfisher@uci.edu

© 2011 American Heart Association, Inc.

Stroke is available at <http://stroke.ahajournals.org>

DOI: 10.1161/STROKEAHA.111.626655

value in the clinical efforts directed against mixed cerebrovascular disease.

Methods

All animal studies were performed in accordance with Institutional Animal Care and Use Committee-approved protocols at the University of California Irvine.

Animals and Treatment Protocols

Experiment 1

To determine achievable plasma levels with dipyridamole supplementation, 2-month-old female Tg2576 mice ($n=6$; University of California Irvine, Irvine CA) were treated with a dipyridamole-supplemented high-fat diet (HFD, 40% fat, 40% carbohydrate, and 20% protein with dipyridamole 5 g/kg chow) for 2 weeks. Age-matched female wild-type littermates were used as controls. HFD was used due to poor oral intake by mice when bitter-tasting dipyridamole was incorporated into a standard diet.

Experiment 2

Twelve-month-old female Tg2576 mice were divided into 2 groups: (1) Tg2576-control (Control) mice ($n=9$) fed HFD; and (2) Tg2576+dipyridamole mice ($n=11$) fed HFD supplemented with dipyridamole (5 g/kg of chow). Animals were treated for 3 months.

Experiment 3

Twenty-one-month-old Tg2576 were divided into 4 groups: (1) Tg2576-control mice ($n=9$) fed HFD; (2) Tg2576+dipyridamole mice ($n=11$) fed HFD supplemented with dipyridamole (5 g/kg of chow); (3) Tg2576 mice ($n=9$) on HFD were treated with anti-A β 40 antibodies clone 1313 (10 mg/kg, intraperitoneally, weekly; Abody); and (4) Tg2576+dipyridamole mice ($n=9$) treated with anti-A β 40 antibodies clone 1313 (10 mg/kg, intraperitoneally, weekly; dipyridamole+Abody). There were 2 males with 7 or 9 female mice in each of the 4 groups. Mice were pretreated with the diets for 2 weeks before the antibody injections, which continued for 9 weeks together with the diet supplement.

Behavioral Test and Blood Pressure Monitoring

Cognition was assessed at end of treatment using the Novel Object Recognition task as described.¹¹ Blood pressure was assessed non-invasively in conscious restrained mice by the tail cuff technique using the CODA System (Kent Scientific) for 3 days at the end of the experiment.

Immunohistochemistry

Phosphate-buffered saline perfused 4% paraformaldehyde-fixed brain sections were immunostained for A β using 6E10 and 4G8 mouse monoclonal antibodies (Signet Laboratories, Dedham, MA) at 1:1000 dilution, as previously described.^{11,12}

Hemorrhage Detection

Determination of hemorrhages was performed using Prussian blue staining of ferric acid, as previously described.¹² Coronal sections of experimental and control mouse brains were collected from 3 different planes of the brain (approximately 2.5 mm apart). The sections were mounted on Superfrost Plus microscopic slides (Fisher Scientific, Pittsburgh, PA). Staining was performed using Prussian blue solution: freshly made 5% potassium hexacyanoferrate trihydrate and 5% hydrochloric acid (Sigma, St Louis, MO). Thirty minutes later, sections were rinsed in water and counterstained with Nuclear Fast Red (Sigma), dehydrated, and covered using DPX (BDH Laboratory Supplies). Hemorrhage profiles were counted by 3 independent observers using an Olympus BX40 microscope at 20 \times original magnification. For each brain section, the average number and size of Prussian blue-positive deposits were calculated. We used a scale of 1 to 4 to determine the size of microhemorrhage, in which 1 was 1 to 5 grains of iron or small microvessel involvement; 2 was multiple grains of iron and microvessel involvement; 3 was several

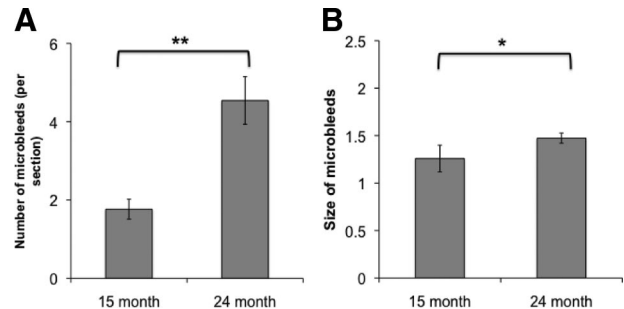


Figure 1. Tg2576 mice progressively accumulate microhemorrhages with aging. Number (A) and size (B) of microhemorrhages assessed in 15- and 24-month-old Tg2576 mice fed regular mouse chow (** $P < 0.01$; * $P < 0.05$).

positive microvessels in 1 area; and 4 was large blood vessel involvement. Results were averaged between investigators and presented as a mean \pm SEM.

Beta-Amyloid Enzyme-Linked Immunosorbent Assay

Enzyme-linked immunosorbent assay of detergent-soluble and 70% formic acid-soluble A β brain fractions was performed using our established assay, as previously described.^{11,12}

Statistical Analysis

All data are expressed as mean \pm SEM. The statistical evaluation was carried out using Student *t* test or analysis of variance. After significant analyses of variance, multiple post hoc comparisons were performed using the Bonferroni test.

Results

Tg2576 mice showed progressive accumulation of microhemorrhages with aging, which ranged from 1.76 ± 0.25 microhemorrhages per brain section in 15-month-old mice to 4.54 ± 0.6 microhemorrhages in 24-month old animals (Figure 1A). The average size of spontaneous microhemorrhage also significantly increased with age (Figure 1B). Dipyridamole supplementation in a HFD was well-tolerated by mice. After 2 weeks, plasma levels of dipyridamole reached 794 ± 246 ng/mL and 793 ± 97 ng/mL in wild-type and Tg2576 mice, respectively. We then studied the effects of 3 months of dipyridamole-supplemented diet on blood pressure, object recognition, and A β 40 and A β 42 in 15-month-old mice. In these studies, there were no effects of dipyridamole on novel object recognition, blood pressure, and A β 40 and A β 42 levels (data not shown). The latter were measured in both detergent-soluble and detergent-insoluble brain fractions. In addition, there was no significant difference in spontaneous microhemorrhage size or number observed in mice receiving a dipyridamole-supplemented diet (Figure 2). There was also no significant difference in microhemorrhage size and number between animals fed a HFD and animals ($N=9$) fed a standard (10% fat, 70% carbohydrate, and 20% protein) diet for 3 months (data not shown).

Finally, we studied the effects of 11 weeks of a dipyridamole-supplemented diet on aged (21 months old) mice with and without passive immunization to A β 40. The latter was achieved by 9 weekly injections beginning 2 weeks after the start of the experiments. There were no significant effects of

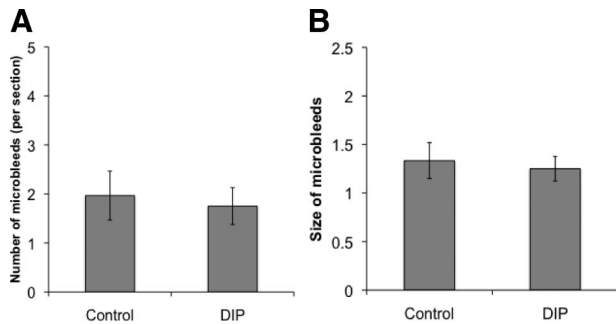


Figure 2. Dipyrindamole diet (5 g/kg of chow) does not affect the number (A) nor the size (B) of spontaneous microhemorrhages in 15-month-old Tg2576 mice receiving 3 months of dipyrindamole (DIP).

dipyrindamole on novel object recognition and biochemical levels of A β 40 and A β 42, and there were no significant male–female differences in dipyrindamole effects (data not shown). There was a significant increase in the number and size of microhemorrhages in antibody-treated mice on the control diet (Figure 3). Antibody-treated mice fed a dipyrindamole-supplemented diet demonstrated a significant increase in number, but not size, of microhemorrhages (Figure 3).

Discussion

Cerebral microscopic bleeding was easily demonstrable in this transgenic mouse model of cerebral amyloid angiopathy with microhemorrhages more than twice as frequent in elderly compared with younger adult mice. These microhemorrhages tended to be exacerbated by our passive immunotherapy regimen. Treatment with dipyrindamole did not worsen microhemorrhages, and the significantly increased

microhemorrhage size of immunized mice was not seen after dipyrindamole treatment. Plasma dipyrindamole levels achievable were within the range encountered clinically, 0.5 to 2.0 μ g/mL.¹³

The Tg2576 mouse expresses mutant amyloid precursor protein from which pathogenic β -amyloid fragments 1–40 and 1–42 are easily generated.⁷ Tg2576 is characterized by predictable progression of band-like vascular amyloid deposits in leptomeningeal and cortical arteries and arterioles, notable by age 12 months.^{14,15} Immunotherapy directed at β -amyloid fragments tends to lessen parenchymal β -amyloid but may worsen vascular amyloid deposition and exacerbate microhemorrhages, perhaps by direct antibody targeting of vascular wall.^{9,16}

The relative ease of demonstrating cerebral microhemorrhages makes the Tg2576 mouse an attractive model to study progression and treatment of these lesions. The latter issue is of particular importance where there is coexistence of ischemic and microhemorrhagic lesions, the typical picture of mixed cerebrovascular disease.⁶ Use of platelet agents, particularly aspirin, has been associated with a higher prevalence of microbleeds on MRI¹⁷ and increased risk of intracerebral hemorrhage in patients with cerebral amyloid angiopathy.¹⁸ Dipyrindamole, shown to be effective as monotherapy for prevention of ischemic stroke,¹⁰ has therapeutic actions largely directed at the vessel wall rather than platelets alone¹⁹; these vessel wall effects include vasodilation through cGMP potentiation, antioxidant and anti-inflammatory actions, and enhancement of endothelial nitric oxide.¹⁹ Moreover, acute treatment with dipyrindamole at the time of reperfusion tends to reduce hemorrhagic conversion of ischemic stroke in a rodent model of experimental stroke.²⁰ Findings of our study

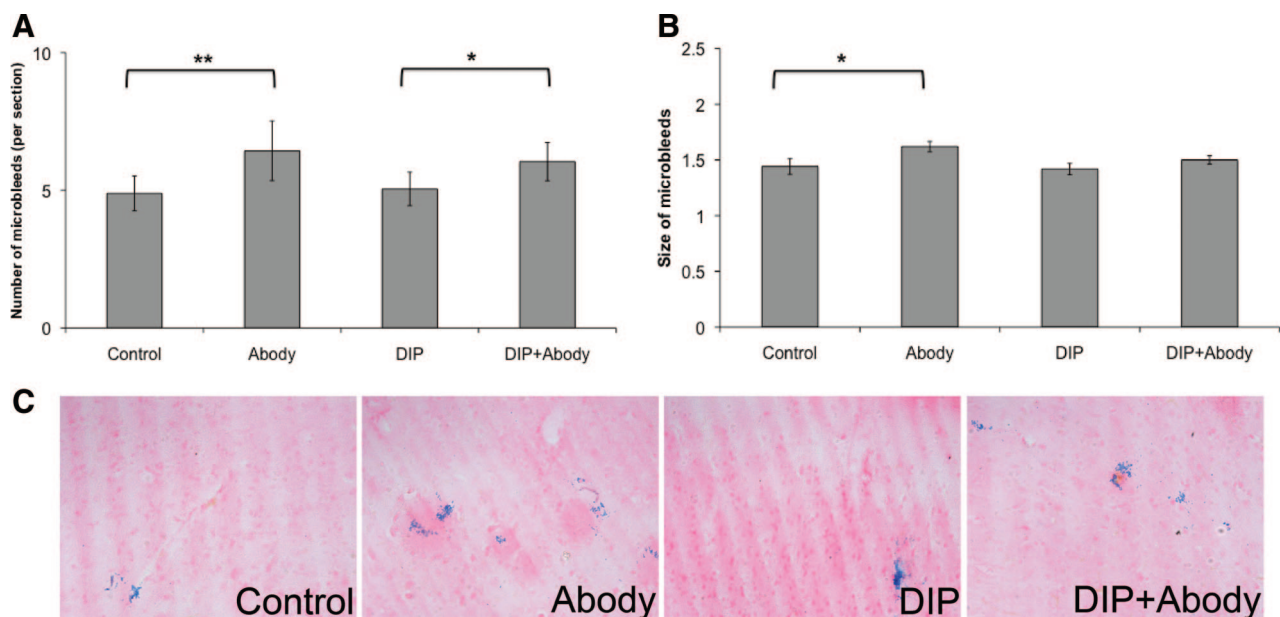


Figure 3. Immunotherapy effects on number (A) and size (B) of microhemorrhages. Twenty-one-month-old mice were treated for 11 weeks with a control (high fat) diet or with a diet supplemented with dipyrindamole (DIP; 5 g/kg chow). Two weeks after initiation of the diet, mice were given anti-A β 40 antibody (Abody, 10 mg/kg, intraperitoneally, weekly for 9 weeks). After immunotherapy, a significantly increased number of microhemorrhages was seen in both antibody-treated groups. Microhemorrhage size after immunotherapy was significantly increased with the control diet only. Representative photomicrographs were taken from the cortex (C). Magnification \times 100. ** P <0.01; * P <0.05.

are limited by a lack of aspirin treatment arm. Nevertheless, absence of microhemorrhage worsening with dipyridamole treatment in this model suggests a potential role for this agent in patients with coexisting ischemic and microhemorrhagic disease.

Acknowledgments

We thank Dr Wolfgang Eisert for assistance.

Sources of Funding

Supported by National Institutes of Health (NIH) NS20989 (M.F.), NIH AG020241 (D.H.C.), NIH AG00538 (D.H.C.), NIH NS050895 (D.H.C.), Alzheimer's Association grant IIRG 91822 (D.H.C.) NIH summer student fellowship GM-69337 (C.V.), and a research grant from Boehringer-Ingelheim (M.F., D.H.C.). A β peptides and anti-A β monoclonal antibodies were provided by the UCI Alzheimer's Disease Research Center funded by NIH P50AG16573.

Disclosures

M.F. has received support from Boehringer-Ingelheim (research grants, speakers' bureau, honoraria) and Otsuka Pharmaceutical Company (research grant and honoraria). D.H.C. has received support from Boehringer-Ingelheim (research grant).

References

- Vernooij MW, van der Lugt A, Ikram MA, Wielopolski PA, Niessen WJ, Hofman A, et al. Prevalence and risk factors of cerebral microbleeds: the Rotterdam Scan Study. *Neurology*. 2008;70:1208–1214.
- Cullen KM, Kocsi Z, Stone J. Pericapillary haem-rich deposits: evidence for microhaemorrhages in aging human cerebral cortex. *J Cereb Blood Flow Metab*. 2005;25:1656–1667.
- Fisher M, French S, Ji P, Kim RC. Cerebral microbleeds in the elderly: a pathological analysis. *Stroke*. 2010;41:2782–2785.
- Young VG, Halliday GM, Kril JJ. Neuropathologic correlates of white matter hyperintensities. *Neurology*. 2008;71:804–811.
- Chen YW, Gurol ME, Rosand J, Vismanathan A, Rakich SM, Groover TR, et al. Progression of white matter lesions and hemorrhages in cerebral amyloid angiopathy. *Neurology*. 2006;67:83–87.
- Fisher M. The challenge of mixed cerebrovascular disease. *Ann N Y Acad Sci*. 2010;1207:18–22.
- Kawarabayashi T, Younkin LH, Saido TC, Shoji M, Ashe KH, Younkin SG. Age-dependent changes in brain, CSF, and plasma amyloid (beta) protein in the Tg2576 transgenic mouse model of Alzheimer's disease. *J Neurosci*. 2001;21:372–381.
- Wilcock DM, Rojiani A, Rosenthal A, Subbarao S, Freeman MJ, Gordon MN, et al. Passive immunotherapy against Abeta in aged APP-transgenic mice reverses cognitive deficits and depletes parenchymal amyloid deposits in spite of increased vascular amyloid and microhemorrhage. *J Neuroinflammation*. 2004;1:24.
- Vasilevko V, Passos GF, Quiring D, Head E, Kim RC, Fisher M, et al. Aging and cerebrovascular dysfunction: contribution of hypertension, cerebral amyloid angiopathy, and immunotherapy. *Ann N Y Acad Sci*. 2010;1207:58–70.
- Diener HC, Cunha L, Forbes C, Sivenius J, Smets P, Lowenthal A. European Stroke Prevention Study 2. Dipyridamole and acetylsalicylic acid in the secondary prevention of stroke. *J Neurol Sci*. 1996;143:1–13.
- Parachikova A, Vasilevko V, Cribbs DH, LaFerla F, Green K. Reductions in amyloid-beta-derived neuroinflammation, with minocycline, restores cognition but not significantly affect tau hyperphosphorylation. *J Alzheimers Dis*. 2010;21:527–542.
- Kitazawa M, Vasilevko V, Cribbs DH, LaFerla FM. Immunization with amyloid-beta attenuates inclusion body myositis-like myopathology and motor impairment in a transgenic mouse model. *J Neurosci*. 2009;29:6132–6141.
- Derendorf H, VanderMaelen CP, Brickl R-S, MacGregor TR, Eisert W. Dipyridamole bioavailability in subjects with reduced gastric acidity. *J Clin Pharmacol*. 2005;45:845–850.
- Robbins EM, Betensky RA, Domnitz SB, Purcell SM, Garcia-Alloza M, Greenberg SM, et al. Kinetics of cerebral amyloid angiopathy progression in a transgenic mouse model of Alzheimer disease. *J Neurosci*. 2006;26:365–371.
- Han BH, Zhou M, Abousaleh F, Brendza RP, Dietrich HH, Koenigsnecht-Talboo J, et al. Cerebrovascular dysfunction in amyloid precursor protein transgenic mice: contribution of soluble and insoluble amyloid- β peptide, partial restoration via γ -secretase inhibition. *J Neurosci*. 2008;28:13542–13550.
- Petrushina I, Ghochikyan A, Mkrtichyan M, Mamikonyan G, Movsesyan N, Ajdari R, et al. Mannan-Abeta28 conjugate prevents A-beta-plaque deposition, but increases microhemorrhages in the brains of vaccinated Tg2576 (APPsw) mice. *J Neuroinflammation*. 2008;5:42.
- Vernooij MW, Haag MD, van der Lugt A, Hofman A, Krestin GP, Stricker BH, et al. Use of antithrombotic drugs and the presence of cerebral microbleeds: the Rotterdam Scan Study. *Arch Neurol*. 2009;66:714–720.
- Biffi A, Halpin A, Towfighi A, Gilson A, Busi K, Rost N, et al. Aspirin and recurrent intracerebral hemorrhage in cerebral amyloid angiopathy. *Neurology*. 2010;75:693–698.
- Kim HH, Liao JK. Translational therapeutics of dipyridamole. *Arterioscler Thromb Vasc Biol*. 2008;28:s39–s42.
- Garcia-Bonilla L, Sosti V, Campos M, Penalba A, Boada C, Sumalla M, et al. Effects of acute post-treatment with dipyridamole in a rat model of focal cerebral ischemia. *Brain Res*. 2011;1373:211–220.