

# Valvular Heart Disease

## New Locus for Autosomal Dominant Mitral Valve Prolapse on Chromosome 13

### Clinical Insights From Genetic Studies

Francesca Nesta, MD\*; Maire Leyne, MS\*; Chaim Yosefy, MD; Charles Simpson, BS; Daisy Dai, BS; Jane E. Marshall, RDCS; Judy Hung, MD; Susan A. Slaugenhaupt, PhD†; Robert A. Levine, MD†

**Background**—Mitral valve prolapse (MVP) is a common disorder associated with mitral regurgitation, endocarditis, heart failure, and sudden death. To date, 2 MVP loci have been described, but the defective genes have yet to be discovered. In the present study, we analyzed a large family segregating MVP, and identified a new locus, *MMVP3*. This study and others have enabled us to explore mitral valve morphological variations of currently uncertain clinical significance.

**Methods and Results**—Echocardiograms and blood samples were obtained from 43 individuals who were classified by the extent and pattern of displacement. Genotypic analyses were performed with polymorphic microsatellite markers. Evidence of linkage was obtained on chromosome 13q31.3–q32.1, with a peak nonparametric linkage score of 18.41 ( $P < 0.0007$ ). Multipoint parametric analysis gave a logarithm of odds score of 3.17 at marker *D13S132*. Of the 6 related individuals with mitral valve morphologies not meeting diagnostic criteria but resembling fully developed forms, 5 carried all or part of the haplotype linked to MVP.

**Conclusions**—The mapping of a new MVP locus to chromosome 13 confirms the observed genetic heterogeneity and represents an important step toward gene identification. Furthermore, the genetic analysis provides clinical lessons with regard to previously nondiagnostic morphologies. In the familial context, these may represent early expression in gene carriers. Early recognition of gene carriers could potentially enhance the clinical evaluation of patients at risk of full expression, with the ultimate aim of developing interventions to reduce progression. (*Circulation*. 2005;112:2022–2030.)

**Key Words:** echocardiography ■ genetics ■ mitral valve

Mitral valve prolapse (MVP) is a common disorder that exhibits a strong hereditary component. It occurs in  $\approx 2.4\%$  of the general population.<sup>1,2</sup> Patients exhibit fibromyxomatous changes in the mitral leaflet tissue that cause superior displacement of the leaflets into the left atrium.<sup>2–4</sup> MVP can be associated with significant mitral regurgitation (MR), bacterial endocarditis, congestive heart failure, and even sudden death,<sup>5–8</sup> and it is the most common primary cause of isolated MR requiring surgical repair.<sup>9</sup>

#### See p 1924

Although autosomal dominant inheritance has been described for MVP<sup>10,11</sup> and MVP occurs in connective tissue disorders such as Marfan syndrome,<sup>12,13</sup> previous studies have failed to establish linkage of familial MVP with fibrillar collagen genes.<sup>14,15</sup> Prior negative linkage results may have

been related to lack of systematic examination of the entire human genome and uncertainty of phenotypic diagnosis. More recently, understanding of mitral valve shape has improved specificity of echocardiographic diagnosis<sup>16–20</sup> as the basis for genetic studies.

Accordingly, linkage of myxomatous MVP to chromosome 16 (*MMVP1*) was reported in 2 of 4 families studied through the use of current diagnostic criteria and a conservative model of disease inheritance.<sup>21</sup> We have also previously reported linkage of an MVP locus, *MMVP2*, on chromosome 11p15.4 in a single large pedigree.<sup>22</sup> The current diagnostic approach has also revealed a X-linked form of MVP.<sup>23</sup> Together, these studies demonstrate the power of the phenotyping and confirm the genetic heterogeneity of this common disorder.

These findings suggest the hypothesis that MVP may be the final common outcome resulting from one of multiple

Received October 26, 2004; revision received June 3, 2005; accepted June 14, 2005.

From the Cardiac Ultrasound Laboratory, Massachusetts General Hospital, Department of Medicine, Harvard Medical School (F.N., C.Y., J.E.M., J.H., R.A.L.), and Center for Human Genetic Research, Massachusetts General Hospital, Harvard Medical School (M.L., C.S., D.D., S.A.S.), Boston, Mass.

\*Authors Nesta and Leyne contributed equally to the work.

†Senior authorship is acknowledged for Drs Levine and Slaugenhaupt to reflect this cross-disciplinary collaboration.

This work was presented at the 2004 American Heart Association Scientific Sessions, New Orleans, La, November 7–10, 2004, as a finalist for the Samuel A. Levine Young Clinical Investigator Award, and published in abstract form (*Circulation*. 2004;110[suppl III]:III-335).

Correspondence to Robert A. Levine, MD, Massachusetts General Hospital, Cardiac Ultrasound Laboratory, 55 Fruit St YWK5068, Boston, MA 02114. E-mail rlevine@partners.org

© 2005 American Heart Association, Inc.

*Circulation* is available at <http://www.circulationaha.org>

DOI: 10.1161/CIRCULATIONAHA.104.516930

genetic defects, analogous to familial hypertrophic cardiomyopathy.<sup>24,25</sup> Finding additional loci containing diverse but functionally related genes could provide helpful clues for gene identification and increase our understanding of the pathogenesis, with the ultimate goal of developing targeted therapies. Therefore, the aim of the present study was to search for a new MVP locus by genome-wide scanning in a single large pedigree. Studying familial MVP can also provide unique insights into clinical findings of currently uncertain significance by testing for genetic linkage of individuals with variations of mitral valve morphology that do not meet standard criteria but resemble those in fully affected family members—possible early forms that could ultimately guide interventions to limit progression.

## Methods

### Pedigree Collection

This study was carried out on a pedigree of 46 individuals with living members in 3 generations. Echocardiograms and blood samples were obtained on 43 members of the pedigree. The proband was a physician self-referred for family analysis of MVP. This family was selected because of its substantial size, the number of members with fully diagnostic MVP, and the absence of Marfan features.

### Clinical Evaluation

A detailed medical history was obtained from each family member to address the following: (1) evidence of Marfan syndrome or other connective tissue disorders; (2) history of panic attacks with anticipatory anxiety or fear of additional attacks; (3) thoracic cage deformities; (4) symptoms of chest pain, shortness of breath, and palpitations; (5) progression of MR, rupture of chordae tendineae, and surgical valve repair; (6) history of sudden death, with or without resuscitation; and (7) history of congenital heart disease, cardiomyopathy, or coronary heart disease. Marfan syndrome was defined by the presence of joint laxity, tall body habitus with long limbs relative to torso, aortic dissection and aneurysm, scoliosis, and ocular abnormalities and was excluded by detailed history, visual assessment of body habitus, and echocardiographic evaluation of the aorta.

### Data Acquisition

Blood samples were collected on 43 of the 46 family members at the time of echocardiography. Transformed lymphoblast cell lines were established for those with confirmed MVP, and DNA was extracted directly from blood for all others. Complete 2D and Doppler echocardiograms were recorded with a 2.5- to 5.0-MHz transducer to optimize resolution. MVP was diagnosed in long-axis views that contain the highest annular points,<sup>16–20,26</sup> and the medial, central, and lateral valve scallops were scanned systematically to measure maximal systolic leaflet displacement beyond the annulus. Subjects with both thickened (>5 mm) and relatively thinner leaflets were considered to have fully diagnostic MVP because both occur within the same pedigrees.<sup>21,27</sup> Because the lateral scallop is difficult to evaluate from long-axis views, its displacement was measured in the apical 4-chamber view but always confirmed in the long-axis scans.<sup>17,28</sup> Thickness of the leaflet midportion was examined during diastasis, excluding focal thickening and chordae.<sup>17,29</sup> All studies had Institutional Review Board approval with written informed consent.

### Echocardiographic Classification

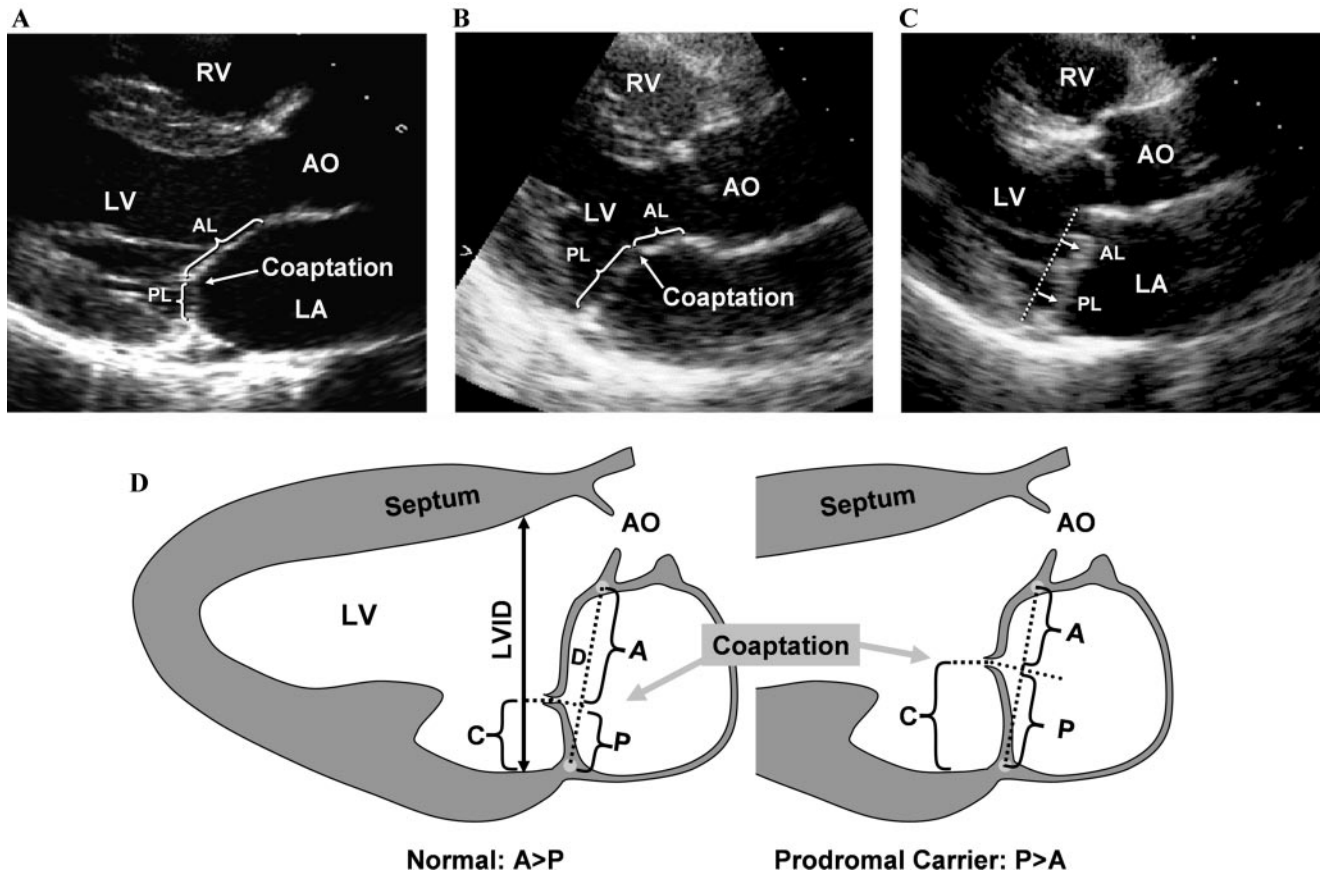
Echocardiographic classification was performed before any genetic analysis. On the basis of prior clinical and prognostic studies, classic MVP is diagnosed if leaflet displacement exceeds 2 mm and maximal thickness is  $\geq 5$  mm; MVP is considered nonclassic if displacement exceeds 2 mm but maximal thickness is <5 mm.<sup>17,19,20,26,30</sup> In the genetic studies, both of these fully diagnostic forms of MVP (classic and nonclassic) were considered

affected. Nondiagnostic forms of uncertain clinical importance were described from the common feature of posterior leaflet asymmetry, which is frequent in fully diagnostic MVP members. Subjects with borderline degrees of displacement ( $\leq 2$  mm involving the posterior leaflet and not associated in a prior preliminary report with increased leaflet thickness, MR, left atrial enlargement, or valve-related complications)<sup>31</sup> were designated as having “minimal systolic displacement,” and these 6 individuals (12769, 12277, 12188, 13549, 12270, and 12191) were considered unknown rather than unaffected for the genetic analysis. This method allows for the possibility that in some instances minimal displacement may represent a mild form of expression as opposed to a physiological variant of leaflet position.

We also recognized an interesting prodromal morphology after reviewing this and other families collected as part of our ongoing genetic studies of MVP. These subjects do not have diagnostic leaflet displacement beyond the annulus, but their pattern of leaflet closure or coaptation resembles that of other family members with fully expressed MVP. Normally, the leaflets meet posteriorly within the LV cavity because the posterior leaflet is shorter than the anterior (Figure 1A). In patients with MVP, coaptation is typically displaced anteriorly, consistent with elongation of the posterior leaflet, which can produce excessive leaflet motion not only into the left atrium but also toward the aortic root. Compare Figure 1C, in which classic MVP leaflets meet halfway up the dotted annular line, with Figure 1B, which shows a subject with no displacement of leaflets into the left atrium beyond the annulus but with an anterior shift of the coaptation point. This shift has been correlated quantitatively with posterior leaflet length (see Discussion). We therefore suggest that this pattern may represent an early or prodromal manifestation of familial MVP without diagnostic leaflet displacement into the atrium but with 2 salient features: anterior displacement of the coaptation point >40% anteriorly along the mitral annulus (P/D; Figure 1; normally within the posterior 25% to 30% of the mitral annulus; see Discussion)<sup>32</sup> and a leaflet coaptation pattern similar to that seen in fully expressing family members. This pattern of bulging of the posterior leaflet relative to the anterior, which is seen in all patients with posterior leaflet prolapse and many with bileaflet MVP (Figure 2), was seen in 2 members of this pedigree. Because of the striking similarity with fully diagnostic MVP, the prodromal individuals (12768 and 12278) were coded as affected for the genetic analysis.

### Genome Scan and Linkage Analysis

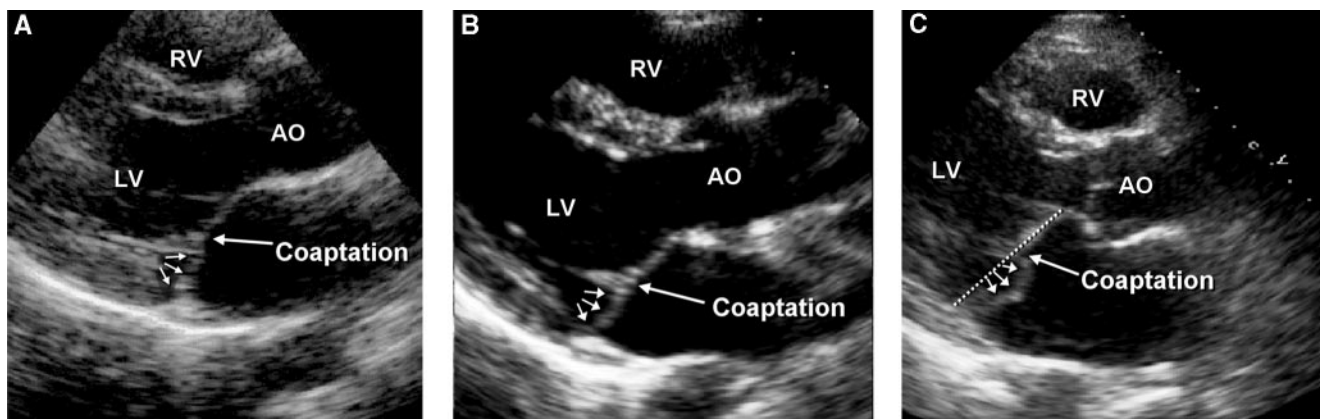
Before beginning the genome scan, we used the SLINK<sup>33,34</sup> program to verify that the pedigree had sufficient power to detect linkage. To determine whether the family was linked to the previously described *MMVP1* or *MMVP2* loci, we genotyped a subset of the family for the following markers: *MMVP1*, *D16S404-D16S3103-D16S420-D16S3133-D16S3068-D16S3080-D16S515*; and *MMVP2*, *D11S4046-D11S4124-D11S2349-D11S1338-D11S1331-D11S932-D11S4465-D11S1349-D11S902-D11S1359-D11S904-D11S914-D11S935-D11S905*. Because no evidence for linkage was discovered, the genome scan was performed on 14 family members (identified in Figure 3) using a panel of 382 genetic markers that span the entire human genome at approximately 10-cM intervals. The markers make up the MGH Genomics Core Facility linkage panel, the majority of which are from the ABI Prism Linkage Mapping set, version 2.5 (Perkin-Elmer, Applied Biosystems). The average heterozygosity of these markers is 0.79. Specific allele frequencies are available at <http://www.appliedbiosystems.com>. When additional map resolution was needed, markers were added from the Cooperative Human Linkage Center Weber Human Screening Set, version 8 (Research Genetics). When available, marker distances were obtained from the Marshfield sex-averaged genetic map (<http://research.marshfieldclinic.org>). Physical location was used to estimate close genetic distances when markers were not on the available linkage map. In most instances other than an X-linked form,<sup>23</sup> familial MVP appears to segregate as an autosomal dominant trait with decreased penetrance.<sup>10,11,21,22</sup> However, we acknowledge that the true genetic model of MVP is unknown; therefore, we initially performed nonparametric linkage (NPL) analysis using the GENEHUNTER program ( $S_{all}$  scoring function).<sup>35,36</sup> This type of analysis examines allele sharing among



**Figure 1.** Echo examples of posteriorly coapting leaflets (anterior leaflet [AL]; posterior leaflet [PL]) in a normal subject (A) vs increased coaptation height in a family member with a prodromal form and an elongated posterior leaflet (B) and in another family member with classic MVP of both leaflets into the left atrium (LA) (C). D, Schematics showing projections of anterior (A) and posterior (P) leaflets onto the mitral annular diameter (D). C indicates projection of the coaptation point onto the LV internal diameter [LVID]; AO, aorta; and RV, right ventricle.

affected individuals and does not require specification of a genetic model. Therefore, NPL analysis can demonstrate phenotype-allele associations that may be missed by parametric analysis performed with an incorrect model. The GENEHUNTER program limits the pedigree size by using a specific formula whereby  $2n - f$  must be  $\leq 20$  (n is nonfounders and f is founders). GENEHUNTER performs trimming of pedigrees exceeding this size as described in the program documentation. After analyzing the genome scan data, we

genotyped all individuals for markers on chromosome 13 (Figure 3). To perform genetic analysis on the entire family, we also calculated 2-point parametric logarithm of odds (LOD) scores between the disease and individual markers using the MLINK program of FASTLINK 3.0, a faster version of the original LINKAGE package.<sup>37-41</sup> In addition, multipoint parametric LOD scores for the entire family were calculated with LINKMAP.<sup>42</sup> Because MVP has been associated with both sex- and age-dependent penetrance,<sup>10,11</sup> our



**Figure 2.** Examples of 2 individuals with prodromal morphology (A, B) and of an individual with posterior leaflet MVP (C). All show increased coaptation heights and posterior leaflet bulging (arrows) relative to the anterior leaflet, but only the third example (C) shows fully expressed superior leaflet displacement relative to the mitral annulus (dotted line) into the left atrium.



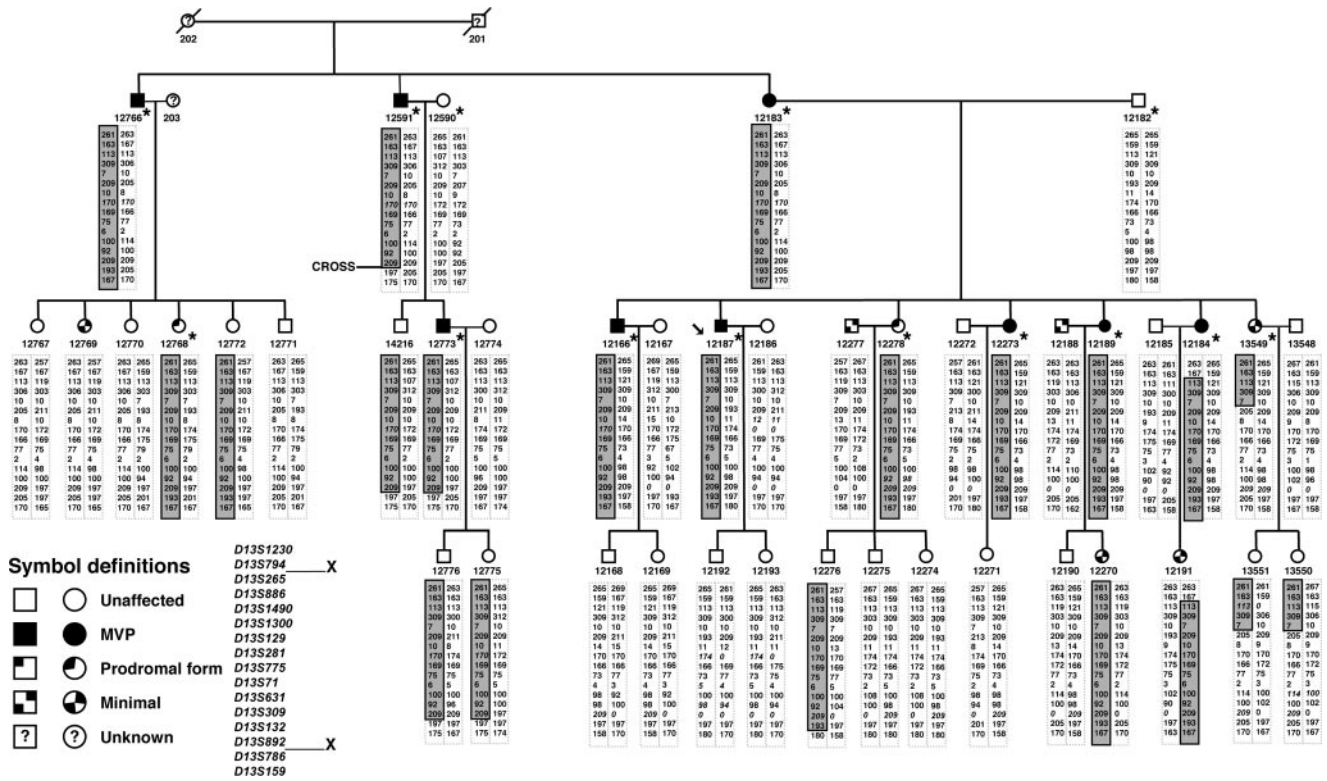


Figure 3. MVP pedigree showing chromosome 13 haplotypes. \*Individuals used for the genome scan and the GENEHUNTER analysis.

analysis was performed with the model described in the previous linkage reports.<sup>21,22</sup> Briefly, we assumed an autosomal dominant mode of inheritance with incomplete penetrance and a disease gene frequency of 0.005, with a phenocopy rate of 1% to account for the high incidence of sporadic MVP. Penetrance for adults >15 years of age was set at 95% for female subjects and 63% for male subjects and at 32% and 21%, respectively, for those <15 years of age. To prove that our linkage findings were robust given the assumed genetic model, we also used a stringent model in which we excluded all unaffected subjects <40 years of age and assumed complete penetrance of the disease with no phenocopies. Finally, to overcome the limitations on family size in GENEHUNTER and on the number of markers used in LINKMAP, we performed SIMWALK analysis, which permitted evaluation of the entire pedigree using all 31 markers on chromosome 13. Haplotypes across the linked region were constructed manually and confirmed with both GENEHUNTER and SIMWALK.

**Physical and Transcript Maps**

We constructed a physical and transcript map for the new *MMVP3* locus using data from the UCSC Human Genome Browser (May 2004 freeze) (<http://genome.ucsc.edu/cgi-bin/hgGateway>).

**Results**

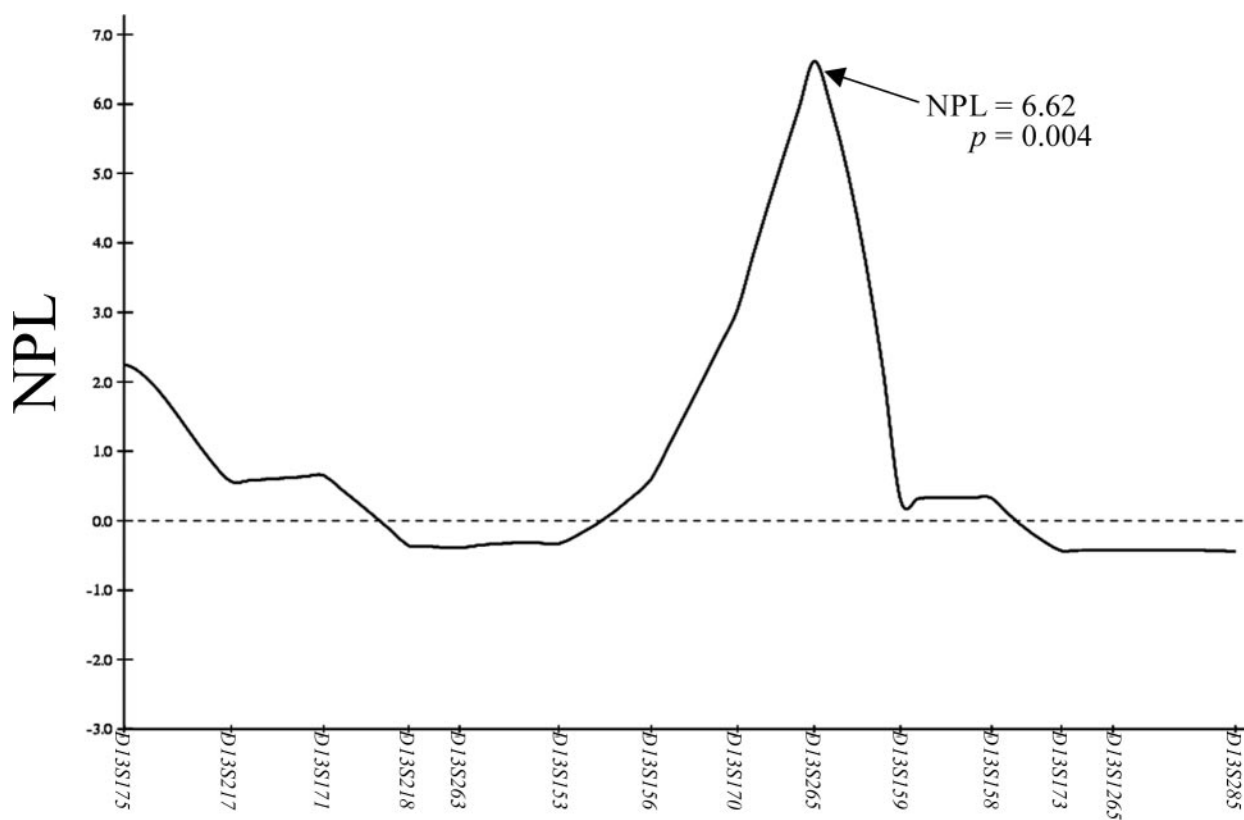
The complete pedigree used in the present study is shown in Figure 3. Both founders were of Western European descent. Blood and echocardiograms were obtained in 43 of 46 subjects (19 male and 24 female subjects; age, 7 to 75 years); the 2 founders were deceased, and subject 203 did not participate. The echocardiographic characteristics of the 9 patients meeting full clinical diagnostic criteria for MVP are provided in the Table. Two of these 9 individuals had

**Echocardiogram Characteristics of Pedigree Members With Fully Diagnostic MVP**

ID	Age, y	Sex	MVP	Leaflet Thickening	LA, mm	LVIDd, mm	EF, %	MR
12183	77	F	Bileaflet (p>a)	Yes	40	46	53	Moderate
12591	75	M	Bileaflet (p>a)	Yes	43*	50*	54*	Severe
12766	69	M	Bileaflet (p>a)	Yes	35	42	64	Mild
12187	53	M	Bileaflet	Yes	42	46	65	Mild
12189	50	F	Posterior	No	35	36	74	Mild
12166	45	M	Bileaflet	Yes	33	47	60	Mild
12773	43	M	Bileaflet	Yes	35	43	64	Trace
12273	41	F	Bileaflet	Yes	38	46	66	Mild
12184	39	F	Bileaflet (p>a)	Yes	33	49	73	Trace

LA indicates left atrial diameter; LVIDd, left ventricular internal diameter (diastolic); EF, ejection fraction; and p>a, asymmetric posterior greater than anterior leaflet displacement. Subject 12591 had mitral valve replacement for bileaflet MVP with severe MR.

\*Values are postoperative.



**Figure 4.** Nonparametric GENEHUNTER analysis of chromosome 13 after the genome scan.

moderate to severe MR, 1 had ruptured chordae tendineae requiring surgical intervention, and 0 had a history of endocarditis or sudden death. In the entire pedigree, no extracardiac manifestations of connective tissue abnormalities or Marfan syndrome were present in any family member. Four subjects, 2 with MVP and 2 without, had a history of panic attacks. Three members with fully diagnostic MVP had a combination of chest pain, shortness of breath, and palpitations; of these, only 1 had an ECG diagnosis of atrial fibrillation. No individuals had thoracic cage deformities. One unaffected individual had a bicuspid aortic valve, and no family member had a history of cardiomyopathy or coronary heart disease.

### Morphological Heterogeneity

Review and comparison of echo images from multiple family members revealed a wide spectrum of phenotypic morphologies. Of the 43 individuals in our pedigree, 9 had fully diagnostic MVP but had varying leaflet involvement, with 5 of the 9 having asymmetric prolapse of the posterior leaflet beyond the anterior, a common pattern in MVP.<sup>17,20,43–45</sup> Leaflet thickening and degree of MR varied, as first described within families by Zuppiroli et al.<sup>27</sup> Six related individuals were designated as having forms not meeting current diagnostic criteria: 2 with the prodromal morphology and 4 with minimal displacement. In addition, 2 spouses in the second generation also had minimal displacement. All of these individuals shared an asymmetry of coaptation (posterior leaflet beyond anterior), as did most of the fully diagnostic subjects. This asymmetry was often reflected in an eccentric,

anteriorly directed MR jet,<sup>43</sup> strikingly similar, for example, in a fully diagnostic mother (12184) and her daughter (12191) who had minimal displacement and trace but atypically eccentric MR. In the prodromals, coaptation was displaced anteriorly to a point 50% up the annular diameter (versus the normal posterior location, only 25% up the annulus).

### Genome Scan and Linkage Analysis

SLINK analysis performed with our previously described model<sup>22</sup> predicted that the pedigree had  $\approx 50\%$  power to detect an LOD score of 2.0, which would provide evidence suggestive of linkage. The maximum predicted LOD score obtained in a sample of 500 replicates was 4.62; the average LOD score was 2.09. Therefore, we performed a genome scan using 14 individuals, including 9 with fully diagnostic MVPs, 2 prodromals, 1 with minimal systolic displacement, and 2 unaffected individuals (parents of generation 3) (identified in Figure 3). Inspection of the GENEHUNTER results of the initial genome scan yielded 4 regions with NPL scores  $>2.0$  and values of  $P < 0.05$  on chromosomes 4, 11 (58 cM from *MMVP2*), 13, and 18. The highest scores were obtained on chromosome 13 with *D13S170* (NPL=3.04;  $P < 0.01$ ) and *D13S265* (NPL, 6.62;  $P < 0.004$ ) (Figure 4). Given that the best evidence for linkage was on chromosome 13, we searched the genetic marker maps and genotyped the entire family using several markers surrounding *D13S265*. GENEHUNTER analysis of the 14-member pedigree using the additional markers yielded a peak NPL score of 18.41 ( $P < 0.0007$ ) across a 5.0-cM region between *D13S886* and *D13S309* (Figure 5), with a corresponding parametric LOD

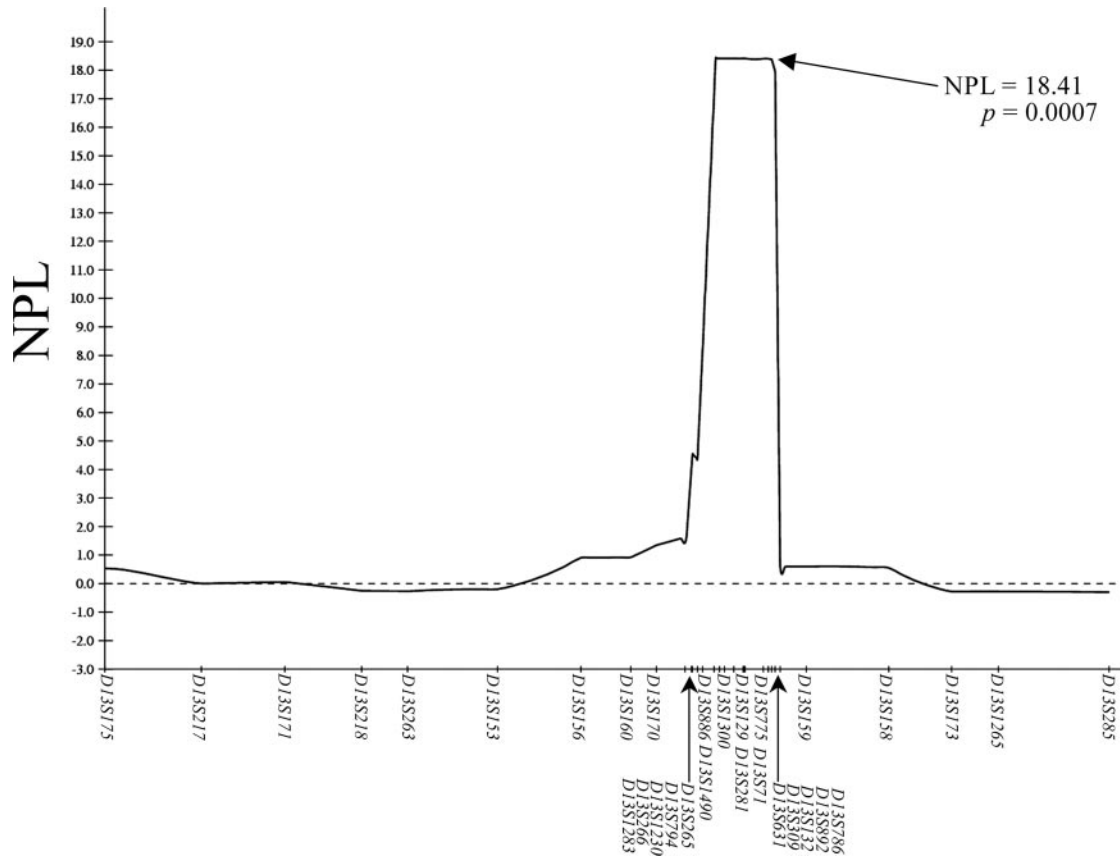


Figure 5. NPL scores on chromosome 13 after the addition of several markers to the linked interval.

score of 2.44. The maximum 2-point parametric LOD score obtained with FASTLINK on the entire family was 2.81 with the marker *D13S1490*, and the parametric multipoint LOD score of 3.17 on the entire family was achieved with LINK-MAP with the markers *D13S886*, *D13S129*, and *D13S132*. To fully use all family and marker information, we then performed SIMWALK analysis for all 31 markers on chromosome 13. This analysis confirms the significance of the GENEHUNTER and FASTLINK results. The NPL peaks at the same location as GENEHUNTER, with nearly identical probability values ( $P=0.0006$  versus  $0.0007$ ). Similarly, good agreement was observed in the parametric analysis, with a FASTLINK score of 3.17 and a SIMWALK score of 2.996. To confirm that our linkage findings were robust to model assumptions, we performed parametric and nonparametric analysis using a stringent model of the disease, as described in Methods. The maximum 2-point parametric LOD score obtained with FASTLINK was 2.22 at marker *D13S132*. GENEHUNTER analysis of the stringent pedigree yielded an identical NPL score of 18.41 ( $P<0.0007$ ).

These results, combined with haplotype analysis in this family, confirm linkage of *MMVP3* to an 8.61-cM region on the long arm of chromosome 13 (Figure 3). All of the fully diagnostic MVP and prodromal members in this family share a 12-allele core haplotype for the markers *D13S265* through *D13S892*. Five unaffected individuals (12772, 14216, 12776, 12775, and 12276) were nonexpressing carriers of the haplotype, 3 of whom were <15 years of age and the other 2

were 30 and 36 years of age. This is consistent with a model of age-dependent penetrance as observed in the previous family studies.<sup>21,22</sup> Of the 4 related individuals with minimal systolic displacement, 2 had the complete haplotype (12270 and 12191), and 1 (13549) carried the disease haplotype for the proximal 3 markers.

A recombination event in individual 12184 between markers *D13S794* and *D13S265* defines the proximal boundary of the linked region, whereas a recombination event in individual 12591 between markers *D13S892* and *D13S786* defines the distal boundary. The complete disease haplotype and the locations of the proximal and distal crosses that define the 8.2-Mb candidate interval are shown in Figure 6. Our results confirm that a third MVP locus, *MMVP3*, maps between *D13S794* and *D13S786* on chromosome 13q31.3-q32.1. The current transcript map for the 8.2-Mb candidate region contains 16 genes and shows synteny to mouse chromosome 14 (Figure 7).

### Discussion

This analysis demonstrates that a new locus for autosomal dominant MVP (*MMVP3*) maps to the long arm of chromosome 13. This finding further confirms the genetic heterogeneity of MVP, previously linked to chromosomes 11 and 16 and the X chromosome.<sup>23</sup> In contrast with prior negative studies, identifying loci on 3 chromosomes demonstrates the strength of the present approach, combining current diagnostic criteria with systematic genome scanning. Genetic hetero-

Marker	Disease	Proximal	Distal
D13S1230	261	263	261
D13S794	163	167	163
D13S265	113*	113*	113
D13S886	309	309	309
D13S1490	7	7	7
D13S1300	209	209	209
D13S129	10	10	10
D13S281	170	170	170
D13S775	169	169	169
D13S71	75	75	75
D13S631	6	6	6
D13S309	100	100	100
D13S132	92	92	92
D13S892	209	209	209
D13S786	193	193	197
D13S159	167	167	175

**Figure 6.** *MMVP3* haplotype. All nine fully diagnostic MVP individuals shared the interval between *D13S794* and *D13S786*. \*Noninformative.

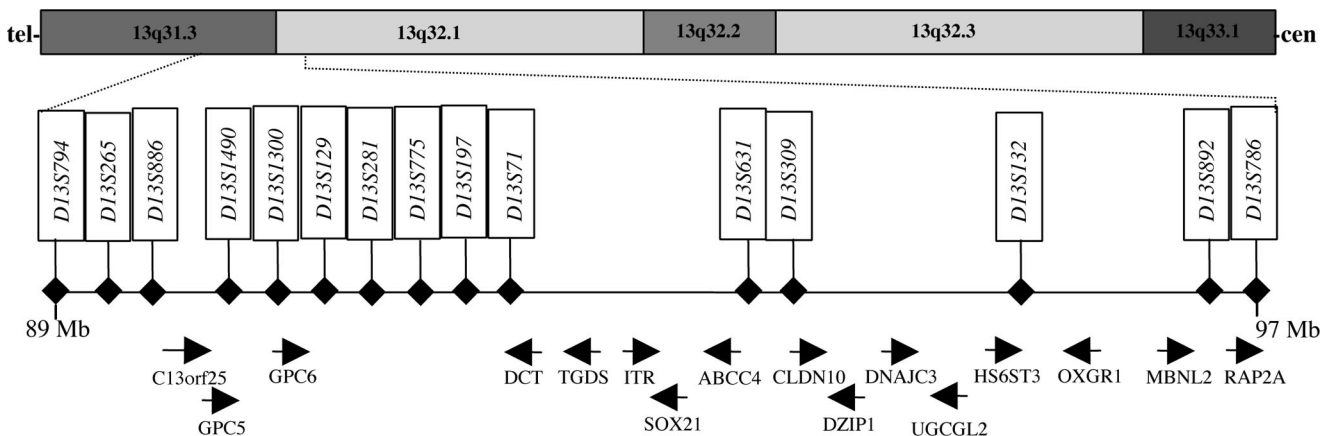
genetics provides opportunities to explore relationships between genetic defects and differences in disease expression and natural history,<sup>24,25,46–48</sup> as well as providing helpful clues for gene searches. The genetic analysis has, in turn, provided important clinical insights, revealing a spectrum of expression that included valve morphologies previously considered normal variants but now for the first time recognized as having the same genetic substrate in the familial context.

The clinical lessons learned during this and other recent genetic studies challenge the concept that MVP has a consis-

tent expression and leaflet thickness within families.<sup>21,22,27</sup> Although thick leaflets and MR are associated in individual patients,<sup>20,26</sup> a spectrum of valvular abnormalities, which may represent variations in disease expression, stage of progression, or modifying factors, occurs within families. This spectrum also includes family members with minimal displacement or the described prodromal morphology who were frequently found in this study to carry all or part of the MVP haplotype (5 of 6 individuals). These may represent either mild or early gene expression, a distinction that requires follow-up studies. Recognizing early forms is important because the disease often manifests clinically in the fifth or sixth decade of life as a severe cardiac event. Earlier targeted intervention to reduce leaflet stresses in genetically susceptible individuals,<sup>49</sup> as in Marfan syndrome with aortic dilatation,<sup>50</sup> could potentially prevent progression to complications and heart failure.

The recognized prodromal morphology, previously unreported, was also observed in the family linked to the *MMVP2* locus on chromosome 11.<sup>22</sup> When we reviewed all echocardiograms in that family blinded to haplotype, we discovered 5 individuals with a prodromal morphology who turned out to be carriers of the haplotype, as did another with minimal systolic displacement. In the familial context, therefore, the prodromal finding could acquire diagnostic power. This is reasonable because the salient feature of this morphology, anteriorly shifted coaptation, has been associated with increased posterior leaflet length. This association has been recognized during surgical repair of MVP patients with long posterior leaflets who are more prone to having their coapted leaflets shift anteriorly and obstruct the LV outflow tract,<sup>51</sup> reducible by Carpentier’s “sliding” of the posterior leaflet downward.<sup>52</sup> Quantitatively, we have found that the height of coaptation relative to the annulus or LV diameter (P/D or C/LVID in Figure 1; see legend for abbreviation expansion) correlated well with the ratio of anterior to posterior leaflet length ( $r=0.83$  to  $0.85$ ) in the chromosome 11 family.<sup>32</sup>

From these findings, minimal displacement can no longer simply be considered a normal variant in the familial context. It shares posterior leaflet asymmetry with the prodromal form and many of those with fully expressed MVP. Posterior



**Figure 7.** Human transcript map of the *MMVP3* candidate region on chromosome 13. The candidate region is within 13q31.3–q32.1, and all RefSeq genes and their orientation are shown within the 8.2-Mb interval.



leaflet asymmetry has a recognized role in the mechanism of MR<sup>20,43,44</sup> and the definition of MVP.<sup>45</sup> These considerations support our retention of such individuals as indeterminate as opposed to unaffected for the genetic analysis. The genetic studies will therefore be important to provide insights into the best clinical approach to individuals with such previously nondiagnostic features.

The association between nondiagnostic forms and MVP loci cannot be extrapolated beyond the context of familial MVP, eg, 2 individuals with minimal displacement who married into the family. However, as in hypertrophic cardiomyopathy where the distinction between normal variation and pathological hypertrophy must be made in genetic studies, the familial context permits the use of more sensitive criteria without sacrificing specificity.<sup>25,48</sup> Follow-up studies are required to determine whether these nondiagnostic forms progress and what factors correlate with progression.

The current transcript map for the 8.2-Mb *MMVP3* candidate region on chromosome 13q31.3-q32.1 contains 16 genes and shows synteny to mouse chromosome 14. Although we have only recently started investigating the potential function of the genes in the region, a few merit consideration as potential candidates. Intimal thickness-related receptor (*ITR*) has been isolated from a heart cDNA library. It contains an N-terminal signal sequence, 7 transmembrane domains, and a signature motif found in members of the rhodopsin-like G protein-coupled receptor superfamily. *ITR*-null mice suggest that this gene plays an important role in the regulation of vascular remodeling.<sup>53</sup> Glypican 5 and glypican 6 (*GPC5* and *GPC6*) are members of a family of cell surface heparan sulfate proteoglycans that appear to play an important role in cellular growth control and differentiation. *GPC6* has been localized to mesenchymal tissues in the developing mouse embryo.<sup>54–56</sup> Interestingly, myxomatous valves are known to contain significantly more glycosaminoglycans than control valves.<sup>57</sup> These data suggest that these genes should be given high priority for screening.

In summary, this analysis demonstrates that a third locus for autosomal dominant MVP maps to an 8.2-Mb region on chromosome 13. It further confirms the genetic heterogeneity of MVP and represents an important step toward the identification of MVP genes. Furthermore, in the familial context, the genetic analysis shows that previously nondiagnostic morphologies often represent mild or early stages of expression in gene carriers; this early recognition could potentially enhance our clinical evaluation, with the ultimate aim of developing interventions to limit progression.

### Acknowledgments

This work was funded by grants from the Doris Duke Foundation and the Aetna Foundation, by an American Heart Association Postdoctoral Research Fellowship (Dr Nesta), and by NIH grants R01-HL-38176 and K24-HL-67434. We thank Dr Emelia Benjamin for referring the proband.

### References

- Freed LA, Benjamin EJ, Levy D, Larson MG, Evans JC, Fuller DL, Lehman B, Levine RA. Mitral valve prolapse in the general population: the benign nature of echocardiographic features in the Framingham Heart Study. *J Am Coll Cardiol*. 2002;40:1298–1304.
- Freed LA, Levy D, Levine RA, Larson MG, Evans JC, Fuller DL, Lehman B, Benjamin EJ. Prevalence and clinical outcome of mitral-valve prolapse. *N Engl J Med*. 1999;341:1–7.
- Tamura K, Fukuda Y, Ishizaki M, Masuda Y, Yamanaka N, Ferrans VJ. Abnormalities in elastic fibers and other connective-tissue components of floppy mitral valve. *Am Heart J*. 1995;129:1149–1158.
- Rabkin E, Aikawa M, Stone JR, Fukumoto Y, Libby P, Schoen FJ. Activated interstitial myofibroblasts express catabolic enzymes and mediate matrix remodeling in myxomatous heart valves. *Circulation*. 2001;104:2525–2532.
- Devereux RB, Kramer-Fox R, Shear MK, Kligfield P, Pini R, Savage DD. Diagnosis and classification of severity of mitral valve prolapse: methodologic, biologic, and prognostic considerations. *Am Heart J*. 1987;113:1265–1280.
- Braunwald E. *Heart Disease: A Textbook of Cardiovascular Medicine*. Philadelphia, Pa: WB Saunders Co; 1992.
- Avierinos JF, Gersh BJ, Melton LJ 3rd, Bailey KR, Shub C, Nishimura RA, Tajik AJ, Enriquez-Sarano M. Natural history of asymptomatic mitral valve prolapse in the community. *Circulation*. 2002;106:1355–1361.
- Perloff JK, Child JS. Clinical and epidemiologic issues in mitral valve prolapse: overview and perspective. *Am Heart J*. 1987;113:1324–1332.
- Waller BF, Morrow AG, Maron BJ, Del Negro AA, Kent KM, McGrath FJ, Wallace RB, McIntosh CL, Roberts WC. Etiology of clinically isolated, severe, chronic, pure mitral regurgitation: analysis of 97 patients over 30 years of age having mitral valve replacement. *Am Heart J*. 1982;104:276–288.
- Devereux RB, Brown WT, Kramer-Fox R, Sachs I. Inheritance of mitral valve prolapse: effect of age and sex on gene expression. *Ann Intern Med*. 1982;97:826–832.
- Strahan NV, Murphy EA, Fortuin NJ, Come PC, Humphries JO. Inheritance of the mitral valve prolapse syndrome: discussion of a three-dimensional penetrance model. *Am J Med*. 1983;74:967–972.
- Glesby MJ, Pyeritz RE. Association of mitral valve prolapse and systemic abnormalities of connective tissue: a phenotypic continuum. *JAMA*. 1989;262:523–528.
- Roman MJ, Devereux RB, Kramer-Fox R, Spitzer MC. Comparison of cardiovascular and skeletal features of primary mitral valve prolapse and Marfan syndrome. *Am J Cardiol*. 1989;63:317–321.
- Henney AM, Tsiouras P, Schwartz RC, Child AH, Devereux RB, Leech GJ. Genetic evidence that mutations in the COL1A1, COL1A2, COL3A1, or COL5A2 collagen genes are not responsible for mitral valve prolapse. *Br Heart J*. 1989;61:292–299.
- Wordsworth P, Ogilvie D, Akhras F, Jackson G, Sykes B. Genetic segregation analysis of familial mitral valve prolapse shows no linkage to fibrillar collagen genes. *Br Heart J*. 1989;61:300–306.
- Levine RA, Triulzi MO, Harrigan P, Weyman AE. The relationship of mitral annular shape to the diagnosis of mitral valve prolapse. *Circulation*. 1987;75:756–767.
- Levine RA, Stathogiannis E, Newell JB, Harrigan P, Weyman AE. Reconsideration of echocardiographic standards for mitral valve prolapse: lack of association between leaflet displacement isolated to the apical four chamber view and independent echocardiographic evidence of abnormality. *J Am Coll Cardiol*. 1988;11:1010–1019.
- Levine RA, Handschumacher MD, Sanfilippo AJ, Hagege AA, Harrigan P, Marshall JE, Weyman AE. Three-dimensional echocardiographic reconstruction of the mitral valve, with implications for the diagnosis of mitral valve prolapse. *Circulation*. 1989;80:589–598.
- Perloff JK, Child JS. Mitral valve prolapse: evolution and refinement of diagnostic techniques. *Circulation*. 1989;80:710–711.
- Nidorf SM, Weyman AE, Hennessey R, Newell JB, Levine AB. The relationship between mitral valve morphology and prognosis in patients with mitral valve prolapse: a prospective echocardiographic study of 568 patients. *J Am Soc Echocardiogr*. 1993;6:S8. Abstract.
- Disse S, Abergel E, Berrebi A, Houot AM, Le Heuzey JY, Diebold B, Guize L, Carpentier A, Corvol P, Jeunemaitre X. Mapping of a first locus for autosomal dominant myxomatous mitral-valve prolapse to chromosome 16p11.2-p12.1. *Am J Hum Genet*. 1999;65:1242–1251.
- Freed LA, Acierno JS Jr, Dai D, Leyne M, Marshall JE, Nesta F, Levine RA, Slangenaupt SA. A locus for autosomal dominant mitral valve prolapse on chromosome 11p15.4. *Am J Hum Genet*. 2003;72:1551–1559.
- Kyndt F, Schott JJ, Trochu JN, Baranger F, Herbert O, Scott V, Fressinaud E, David A, Moisan JP, Bouhour JB, Le Marec H, Benichou



- B. Mapping of X-linked myxomatous valvular dystrophy to chromosome Xq28. *Am J Hum Genet.* 1998;62:627–632.
24. Solomon SD, Jarcho JA, McKenna W, Geisterfer-Lowrance A, Germain R, Salerni R, Seidman JG, Seidman CE. Familial hypertrophic cardiomyopathy is a genetically heterogeneous disease. *J Clin Invest.* 1990;86:993–999.
  25. Maron BJ, Moller JH, Seidman CE, Vincent GM, Dietz HC, Moss AJ, Towbin JA, Sondheimer HM, Pyeritz RE, McGee G, Epstein AE. Impact of laboratory molecular diagnosis on contemporary diagnostic criteria for genetically transmitted cardiovascular diseases: hypertrophic cardiomyopathy, long-QT syndrome, and Marfan syndrome: a statement for healthcare professionals from the Councils on Clinical Cardiology, Cardiovascular Disease in the Young, and Basic Science, American Heart Association. *Circulation.* 1998;98:1460–1471.
  26. Marks AR, Choong CY, Sanfilippo AJ, Ferre M, Weyman AE. Identification of high-risk and low-risk subgroups of patients with mitral-valve prolapse. *N Engl J Med.* 1989;320:1031–1036.
  27. Zuppiroli A, Roman MJ, O'Grady M, Devereux RB. A family study of anterior mitral leaflet thickness and mitral valve prolapse. *Am J Cardiol.* 1998;82:823–826, A10.
  28. Shah PM. Echocardiographic diagnosis of mitral valve prolapse. *J Am Soc Echocardiogr.* 1994;7:286–293.
  29. Weissman NJ, Pini R, Roman MJ, Kramer-Fox R, Andersen HS, Devereux RB. In vivo mitral valve morphology and motion in mitral valve prolapse. *Am J Cardiol.* 1994;73:1080–1088.
  30. Nishimura RA, McGoon MD, Shub C, Miller FA Jr, Ilstrup DM, Tajik AJ. Echocardiographically documented mitral-valve prolapse: long-term follow-up of 237 patients. *N Engl J Med.* 1985;313:1305–1309.
  31. Vivaldi MT, Sagie A, Adams MS, Levine RA. 10-Year echocardiographic and clinical follow-up of patients with nonclassic mitral valve prolapse: does it progress? *Circulation.* 1994;90(suppl I):I-222. Abstract.
  32. Nesta F, Freed L, Leyne M, Marshall J, Slagenhaupt S, Levine R. Coaptation height: a new marker of mitral leaflet redundancy. *J Am Soc Echocardiogr.* 2003;16:538. Abstract.
  33. Ott J. Computer-simulation methods in human linkage analysis. *Proc Natl Acad Sci U S A.* 1989;86:4175–4178.
  34. Weeks DE, Ott J, Lathrop GM. SLINK: a general simulation program for linkage analysis. *Am J Hum Genet.* 1990;47(suppl):A204. Abstract.
  35. Kruglyak L, Daly MJ, Reeve-Daly MP, Lander ES. Parametric and nonparametric linkage analysis: a unified multipoint approach. *Am J Hum Genet.* 1996;58:1347–1363.
  36. Kong A, Cox NJ. Allele-sharing models: LOD scores and accurate linkage tests. *Am J Hum Genet.* 1997;61:1179–1188.
  37. Cottingham RW Jr, Idury RM, Schaffer AA. Faster sequential genetic linkage computations. *Am J Hum Genet.* 1993;53:252–263.
  38. Lathrop GM, Lalouel JM, White RL. Construction of human linkage maps: likelihood calculations for multilocus linkage analysis. *Genet Epidemiol.* 1986;3:39–52.
  39. Shaffer AA, Gupta SK, Shriram K, Cottingham RW Jr. Avoiding recomputation in linkage analysis. *Hum Hered.* 1994;44:225–237.
  40. Lathrop GM, Lalouel JM, Julier C, Ott J. Strategies for multilocus linkage analysis in humans. *Proc Natl Acad Sci U S A.* 1984;81:3443–3446.
  41. Lathrop GM, Lalouel JM. Easy calculations of LOD scores and genetic risks on small computers. *Am J Hum Genet.* 1984;36:460–465.
  42. Lathrop GM, Lalouel JM, Julier C, Ott J. Multilocus linkage analysis in humans: detection of linkage and estimation of recombination. *Am J Hum Genet.* 1985;37:482–498.
  43. Grayburn PA, Berk MR, Spain MG, Harrison MR, Smith MD, DeMaria AN. Relation of echocardiographic morphology of the mitral apparatus to mitral regurgitation in mitral valve prolapse: assessment by Doppler color flow imaging. *Am Heart J.* 1990;119:1095–1102.
  44. Schwammenthal E, He S, Fontaine AA, Nidorf SM, Vlahakes GJ, Yoganathan AP, Weyman AE, Levine RA. Impact of leaflet geometry on the severity of mitral regurgitation in mitral valve prolapse: insights from an in vitro model. *J Am Coll Cardiol.* 1994;23:32A. Abstract.
  45. Jyo Y, Yoshikawa J, Yoshida K, Kato H, Shakudo M. A new diagnostic criteria of mitral valve prolapse syndrome. *J Cardiol Suppl.* 1988;18:29–41.
  46. Coonar AS, McKenna WJ. Molecular genetics of familial cardiomyopathies. *Adv Genet.* 1997;35:285–324.
  47. Seidman CE, Seidman JG. Molecular genetic studies of familial hypertrophic cardiomyopathy. *Basic Res Cardiol.* 1998;93(suppl 3):13–16.
  48. Tesson F, Richard P, Charron P, Mathieu B, Cruaud C, Carrier L, Dubourg O, Lautie N, Desnos M, Millaire A, Isnard R, Hagege AA, Bouhour JB, Bennaceur M, Hainque B, Guicheney P, Schwartz K, Komajda M. Genotype-phenotype analysis in four families with mutations in beta-myosin heavy chain gene responsible for familial hypertrophic cardiomyopathy. *Hum Mutat.* 1998;12:385–392.
  49. Durbin AD, Gotlieb AI. Advances towards understanding heart valve response to injury. *Cardiovasc Pathol.* 2002;11:69–77.
  50. Shores J, Berger KR, Murphy EA, Pyeritz RE. Progression of aortic dilatation and the benefit of long-term beta-adrenergic blockade in Marfan's syndrome. *N Engl J Med.* 1994;330:1335–1341.
  51. Maslow AD, Regan MM, Haering JM, Johnson RG, Levine RA. Echocardiographic predictors of left ventricular outflow tract obstruction and systolic anterior motion of the mitral valve after mitral valve reconstruction for myxomatous valve disease. *J Am Coll Cardiol.* 1999;34:2096–2104.
  52. Jebara VA, Dervanian P, Acar C, Grare P, Mihaileanu S, Chauvaud S, Fabiani JN, Deloche A, Carpentier A. Mitral valve repair using Carpentier techniques in patients more than 70 years old: early and late results. *Circulation.* 1992;86(suppl II):II-53–II-59.
  53. Tsukada S, Iwai M, Nishiu J, Itoh M, Tomoike H, Horiuchi M, Nakamura Y, Tanaka T. Inhibition of experimental intimal thickening in mice lacking a novel G-protein-coupled receptor. *Circulation.* 2003;107:313–319.
  54. Paine-Saunders S, Viviano BL, Saunders S. GPC6, a novel member of the glypican gene family, encodes a product structurally related to GPC4 and is colocalized with GPC5 on human chromosome 13. *Genomics.* 1999;57:455–458.
  55. Veugelers M, Vermeesch J, Reekmans G, Steinfeld R, Marynen P, David G. Characterization of glypican-5 and chromosomal localization of human GPC5, a new member of the glypican gene family. *Genomics.* 1997;40:24–30.
  56. Veugelers M, De Cat B, Ceulemans H, Bruystens AM, Coomans C, Durr J, Vermeesch J, Marynen P, David G. Glypican-6, a new member of the glypican family of cell surface heparan sulfate proteoglycans. *J Biol Chem.* 1999;274:26968–26977.
  57. Grande-Allen KJ, Griffin BP, Calabro A, Ratliff NB, Cosgrove DM 3rd, Vesely I. Myxomatous mitral valve chordae, II: selective elevation of glycosaminoglycan content. *J Heart Valve Dis.* 2001;10:325–332; discussion 332–333.