Dysphagia in Lateral Medullary Infarction (Wallenberg's Syndrome)

An Acute Disconnection Syndrome in Premotor Neurons Related to Swallowing Activity?

Ibrahim Aydogdu, MD; Cumhur Ertekin, MD; Sultan Tarlaci, MD; Bulent Turman, MD, PhD; Nefati Kiylioglu, MD; Yaprak Secil, MD

Background and Purpose—We have investigated the pathophysiological mechanisms of dysphagia in Wallenberg's syndrome (WS) that are due to lateral medullary infarction (LMI).

Methods—Twenty patients with WS were evaluated by means of clinical and electrophysiological methods that measured the oropharyngeal phase of voluntarily initiated swallowing. For comparison, 22 patients with unilateral hemispheric infarction were investigated during the acute stage of stroke, and 4 patients with unilateral peripheral 9th and 10th cranial nerve palsies were studied. Age-matched 30 healthy control subjects were also included in the study.

Results—It was found that dysphagia was clinically more severe in WS patients than in the patients in the other groups. The pharyngeal phase of swallowing was predominantly impaired, whereas in patients with hemispheric stroke, dysphagia was related only to the delay of triggering of the voluntarily induced swallowing. In WS patients, the swallowing reflex was extremely slow in spite of the unilateral involvement due to LMI, whereas the pharyngeal phase of reflex swallowing remained within normal limits in patients with unilateral hemispheric stroke and patients with unilateral peripheral 9th and 10th cranial nerve palsies.

Conclusions—Although in WS the lesion due to LMI is unilateral, its effect on oropharyngeal swallowing is bilateral. In LMI, primarily the premotor neurons in the nucleus ambiguus and their connections seem to be affected. Consequently, a disruption and/or disconnection of their linkage to swallowing-related cranial motor neuron pools bilaterally and to the contralateral nucleus ambiguus could produce the swallowing disorders in WS. However, the remaining intact ipsilateral premotor neurons and the contralateral center in the medulla oblongata may eventually begin to operate and overcome the severity and long-term persistence of dysphagia. **(*Stroke*. 2001;32:2081-2087.)**

Key Words: dysphagia ■ electromyography ■ lateral medullary syndrome ■ motor neurons ■ Wallenberg's syndrome

Downloaded from http://ahajournals.org by on February 24, 2022

Wallenberg's syndrome (WS) is well defined clinically, and the lateral medullary infarction (LMI) is the most frequent cause, among others. The WS and LMI are easily diagnosed on the basis of the specific neurological findings, but pathological verification may usually be lacking because the LMI is rarely fatal. Although the combinations of the various signs and symptoms are helpful for the clinical diagnosis of WS, the presence of the different signs and symptoms may vary from patient to patient.[1,2] Among these symptoms and signs, dysphagia has been reported in 51% to 94% of the patients with WS.[1,2] It has been widely accepted that in most cases the dysphagia in WS is initially severe enough to require nonoral feeding but often improves rapidly, and the patient can return to oral feeding within 1 to 2 months after the stroke.[3,4] However, in some patients, dysphagia does not recover for many months, even years.[5,6] Thus, the problem of dysphagia in patients with WS is important from 2 perspectives. On one hand, some patients do not clinically demonstrate dysphagia and aspiration from the onset of stroke, although the major swallowing centers of the nucleus tractus solitarius (NTS) and nucleus ambiguus (NA) and the reticular formation around them are located in the dorsolateral medulla oblongata.[7,8] On the other hand, if they are dysphagic, the extent and severity of swallowing disorders can be considerably variable, ie, very mild and transient in some but extremely severe and prolonged in others.

Occurrences of dysphagia and aspiration have been reported to depend on the site of location of the LMI as detected and correlated by brain stem MRI,[4,9] although the clinical localization and the correlations with the finding on MRI may

Received February 21, 2001; final revision received May 22, 2001; accepted May 23, 2001.

From the Department of Neurology (C.E., S.T., I.A., N.K., Y.S.) and Clinical Neurophysiology (C.E., I.A.), Medical School Hospital, Ege University, Izmir, Turkey, and the Department of Biomedical Sciences (B.T.), University of Sydney, Sydney, Australia.

Correspondence to Prof Dr Cumhur Ertekin, Gönç Apt, No. 12, D:3, 35220, Alsancak, Izmir, Turkey. E-mail erteker@unimedya.net.tr

© 2001 American Heart Association, Inc.

Stroke **is available at http://www.strokeaha.org**

sometimes be inconsistent.[10,11] However, the MRI findings can demonstrate only the area of the infarct and whether or not the swallowing-related structures, such as NTS and/or NA, are included in the infarct region and, therefore, whether dysphagia would be expected or not. Nevertheless, MRI findings still cannot explain the variability of swallowing disorders among patients with WS.

We have investigated the swallowing disorders and the variability, severity, and duration of dysphagia by means of electrophysiological methods in 20 patients with WS and compared the electrophysiological results with those obtained from 22 patients with unilateral hemispheric stroke and 4 patients with unilateral peripheral 9th and 10th cranial nerve involvement.

Subjects and Methods

Throughout a period of 2 years, 3 groups of patients and a group of healthy control subjects were included in the study.

Patients With WS due to Acute LMI

Twenty patients (3 women and 17 men) with a mean age of 58.2 (range 37 to 75) years were investigated. The MRI findings supported the presence of LMI on 1 side in all except 2 patients, who exhibited claustrophobia for MRI, but their clinical pictures were typical for WS due to LMI. Clinical and electrophysiological examinations were performed within the first 2 weeks in 14 patients and within the first month in 4 patients. The remaining 2 patients with severe and prolonged dysphagia were clinically examined and followed up from the onset of the stroke, but their first electrophysiological investigation was carried out 52 days and 180 days after the stroke, respectively. Of the 20 WS patients included in the present study, 13 were reexamined electrophysiologically after a period of 1 to 12 months (average 107 days).

The degree of dysphagia (DD) was graded as follows[12]: for grade I (DD-I), there were no clinical signs and symptoms of dysphagia; for grade II (DD-II), very mild dysphagia was suspected by clinical examination, but the patient never complained of dysphagia; for grade III (DD-III), the patient complained of dysphagia, and other clinical signs supported this, but nonoral feeding was not necessary at the time of investigation; and for grade IV (DD-IV), the patient had obvious clinical signs and symptoms of dysphagia, including aspiration, and dysphagia was severe enough to necessitate nonoral feeding.

In the patients included in the present study, DD was severe enough to necessitate nonoral feeding in 9 WS patients. More moderate dysphagia was observed in 6 patients (DD-III), and mild dysphagia was observed in 4 patients (DD-II). There were no clinical signs and symptoms of dysphagia in only 1 patient (DD-I).

Patients With Acute Unilateral Hemispheric Stroke

Twenty-two patients (8 women and 14 men) were investigated clinically and by electrophysiological methods. Their mean age was 61.8 (range 44 to 78) years. In all patients, the unilateral hemispheric stroke was the result of infarction in the territory of the middle cerebral artery, and this was diagnosed clinically and confirmed radiologically (MRI and/or CT). They had no apraxia or/and aphasia. They were well coordinated and cooperated with our methods. The common finding was hemiparesis with different severity among patients. The mean electrophysiological examination time after the first day of the stroke was 17 days and ranged between 2 and 75 days. For this group of patients, the DD was also variable: 5 patients with DD-IV, 8 patients with DD-III, and 7 patients with DD-II. In only 2 patients with hemispheric stroke, clinical examination did not reveal any signs of dysphagia (DD-I). All hemispheric stroke patients were electrophysiologically examined only once. Some of the patients were found to have upper motor neuron–type paresis in facial and tongue muscles, but the symptoms were mild.

Patients With Unilateral and Peripheral 9th and 10th Cranial Nerve Involvement

Four adult patients who displayed a 9th and 10th unilateral cranial nerve involvement of a prominently motor type were also assessed by the use of similar electrophysiological methods. They all had unilateral pharyngeal and laryngeal palsies that resulted in dysphagia and dysphonia. In 2 patients, the peripheral lesion was acute and restricted only to disorders of the 9th and 10th cranial nerves. One of the these patients had additional involvement of the 6th, 7th, 8th, and 12th cranial nerves, and the other had 5th, 6th, and 7th nerve involvement.

The clinical and electrophysiological examination revealed that in all 4 patients the cranial nerve palsies were maximal in severity and that the unilateral pharyngeal and laryngeal palsies were complete. DD was severe enough to necessitate nonoral feeding in only 1 patient (DD-IV). Moderate dysphagia was observed in 2 patients (DD-III), and mild dysphagia was observed in 1 patient (DD-II). All patients had normal brain MRI findings. After the initial assessment, none of the patients with unilateral cranial nerve involvement was reexamined clinically or electrophysiologically.

Age-Matched Healthy Control Subjects

Thirty healthy control subjects (8 women and 22 men) were included in the present study to compare their results with those obtained from different groups of dysphagic patients. The mean age of subjects in this group was 61.5 (range 47 to 75) years.

Electrophysiological Recording Methods

The electrophysiological method used in the present study was previously described in detail.[13] In brief, during swallowing, the electromyographic (EMG) activity was recorded on an EMG apparatus (Medelec MS-20) by means of bipolar silver chloride EEG electrodes taped under the chin over the mylohyoid–geniohyoid–anterior digastric muscle complex (submental EMG [SM-EMG]). The EMG signals were filtered (band pass 100 Hz to 10 kHz), amplified, rectified, and integrated. For the detection of the laryngeal upward and downward movements, a mechanical sensor that consisted of a single piezoelectric wafer with a small rubber bulge affixed to it at its center was placed on the coniotomy region between the cricoid and thyroid cartilages on the midline.[14]

Each subject sat on an examination chair and was requested to hold his/her head in a natural upright position. The swallows were initiated by a 1- or 3-mL volume of tap water introduced through a disposable syringe. The water was positioned on the tongue, and the subject was requested to swallow. The recording time was set to 2 and/or 5 seconds with an 800-ms preswallowing time included in each sweep duration. Five successive recordings were collected for each type of swallow, and the signals on single, superimposed, and averaged traces were examined and analyzed.

The electrophysiological parameters associated with laryngeal sensor signals and the SM-EMG were measured and labeled. These parameters are defined as follows: (1) The onset of 2 deflections on the laryngeal sensor signal recordings are denoted as 0 and 2. The "0-2 interval" is a time variable that indicates the upward movement of the larynx plus the relocation time during the pharyngeal phase of swallowing.[13] (2) Because the submental muscles are laryngeal elevators, the SM-EMG is thought to provide information about the onset and duration of the oropharyngeal phase of swallowing within the period referred to as the "A-C interval."[13] (3) The third parameter, denoted as the "A-0 interval" is the period between the onset of SM-EMG (A) and the appearance of the upward deflection (0) of the laryngeal sensor. This interval reflects the initiation of the reflex phase of swallowing and, therefore, is presumably associated with the triggering of swallowing reflex.[12,15] (4) In some subjects, the onset of the second deflection of laryngeal sensor showed variability for bolus doses of the same volume. This variability in the laryngeal downward movement was measured at the peaks of the

Downloaded from http://ahajournals.org by on February 24, 2022

TABLE 1. Main Clinical Findings Associated With Swallowing Dysfunction

Clinical Findings	WS, n (%)	HS, n (%)	HS vs WS, *P* *
Dysphonia	17 (85)	14 (64)	...
Wet voice	7 (35)	2 (9)	0.041
Weak voluntary cough	16 (80)	10 (46)	0.021
Difficulty of bolus control	6 (30)	14 (64)	0.029
Palatal paresis	7 (35)	4 (17)	...
Facial weakness	3 (15)	12 (55)	0.008
Oropharyngeal sensory loss	13 (61)	7 (32)	0.032
Accumulation of saliva	12 (60)	13 (59)	...
Slow laryngeal elevation	12 (60)	11 (50)	...
Pneumonia	4 (20)	2 (9)	...
Vocal cord paresis	20 (100)	...	...
Tongue weakness	...	11 (50)	...

HS indicates hemispheric stroke.

*χ^2 test or Fisher exact test when appropriate.

second deflections. The interval between the earliest and latest peaks was called "swallowing jitter" and served as a measure of the variation in swallowing response.[13,16]

To investigate the "piecemeal deglutition" and dysphagia limit, an identical recording procedure was used[17] with the sweep duration set at 10 seconds and the delay line set at 2 seconds. All subjects were given 1, 3, 5, 10, 15, and 20 mL water, and for each volume, the oscilloscopic traces were initiated with the examiner's command to "swallow." During these long sweeps, the laryngeal sensor signals and the integrated SM-EMG activity were recorded immediately after the command to swallow. Normally, with volumes up to 20 mL, all material can be swallowed in 1 attempt. However, when the amount of the water is >20 mL, piecemeal deglutition is usually observed. Any duplication or multiplication of a swallowing attempt involving ≤20 mL water within the recording period after the first swallow was referred to as the "dysphagia limit" and was regarded as pathological.[17]

Statistical Analysis

Associations between categorical outcome events (such as wet voice, difficulty of bolus control, facial weakness, and slow laryngeal elevation) were determined with the use of the χ^2 test or Fisher exact test as appropriate. One-way ANOVA (Bonferroni test as multiple comparisons, post hoc analysis) was performed to assess the differences in swallowing-related variables (0-2, A-C, and A-0 time intervals and jitter) among the groups. Data are presented as mean±SEM. In all instances, a value of $P<0.05$ was regarded as significant. Statistical analysis was performed by using the statistical package SPSS for Windows (version 9.0.0, 1998, SPSS, Inc).

The Ethics Committee of our university hospital approved the present study, and informed consent was obtained from each patient.

Results

DD and Dysphagia Limit Among Patient Groups

The major clinical findings associated with swallowing dysfunction are documented in Table 1. The clinical presence of the swallowing disorder and of dysphagia was more prominent in patients with WS. In particular, the laryngeal elevation was very slow and delayed in WS patients compared with patients with unilateral 9th and 10th cranial nerve palsy (not shown in Tables). On the other hand, in patients with hemispheric stroke, the clinical finding associated with swallowing dysfunction mainly involved the oral phase of swallowing, such as the paresis of facial and tongue muscles, and the difficulty of bolus control in the mouth. Clinically, the initiation of the swallowing reflex in these patients was delayed, but when the swallowing reflex was initiated, the laryngeal elevation was normal and faster than that in WS patients. This clinical phenomenon was also substantiated by electrophysiological findings.

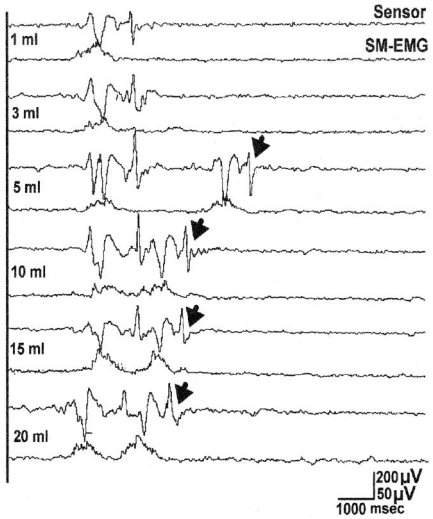

Figure 1. Dysphagia limit obtained from a patient with WS. Arrows indicate the second swallows for determining the dysphagia limit. For this patient, the dysphagia limit was 5 mL water. Calibration marks are as follows: pairs of traces indicate amplitudes for laryngeal sensor movements (upper traces) and submental muscles (lower traces) in this and all other figures. Time is in milliseconds.

Although the grading procedure for dysphagia was useful in the clinical evaluation of a patient, the method used to measure the dysphagia limit was more sensitive and objective in classifying the severity of clinical problems associated with swallowing. Parallel to clinical findings, the dysphagia limit was lower in patients with WS than in other groups. Figure 1 shows recordings of the dysphagia limit in 1 WS patient. For this patient, swallowing in a single attempt could take place with only ≤3 mL water. At higher volumes, there was duplication of the swallowing attempt (indicated by arrows).

The dysphagia limit was pathological (<20 mL water) in all patients with WS, whereas it was found to be pathological in ≈82% of patients with hemispheric stroke. For a substantial number of WS patients (40%), the limit was as low as 1 mL. In 4 patients with peripheral 9th and 10th cranial nerve palsies, the dysphagia limit in the upright posture of the head and neck was 10 mL in 2 patients with sole involvement of these nerves. The swallowing problem and the dysphagia limit could easily be improved with the head rotated to the paretic side in all 4 patients with unilateral cranial nerve palsies. Because they all had discovered this head posture, their swallowing problems were to a large extent solved.

The reexamination of 13 WS patients revealed that there was considerable improvement in 7 patients and complete recovery in 3 patients. However, in the remaining 3 patients, there was still severe dysphagia (DD-IV) at 47, 55, and 362

Downloaded from http://ahajournals.org by on February 24, 2022

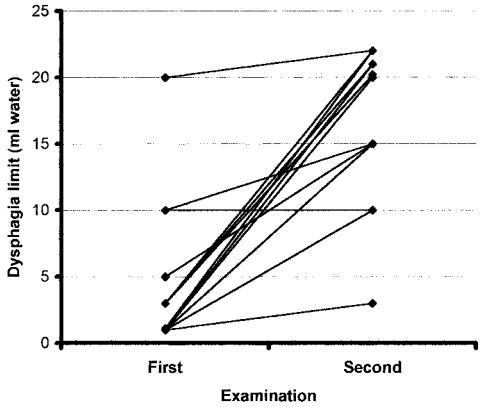

Figure 2. Dysphagia limits in the first and second examinations in 13 WS patients. Each line represents 1 patient. Note the tendency of improvement, but still the dysphagia limit was below the normal limit in the majority of WS patients.

days, respectively, after the first examination. In the remaining 3 patients, although there was an improvement in the dysphagia limit, this was not statistically significant (Figure 2).

Laryngeal Movements and SM-EMG During Swallowing

The laryngeal movements and SM-EMG were investigated and compared in the groups of patients and a group of healthy control subjects during the swallowing of 1 to 3 mL water. Recordings obtained from 1 subject in each group are shown in Figure 3, and the statistical analyses of swallowing parameters are summarized in Table 2. The most important finding in the study among the different groups was associated with the pharyngeal phase of the reflex swallow. In WS patients, this phase was extremely prolonged, as was demonstrated by the duration of the 0-2 and A-C time intervals.

As can be seen in Table 2, these interval values were significantly prolonged in WS patients compared with patients with hemispheric stroke ($P<0.001$ for 0-2 interval and $P<0.053$ for A-C interval) and healthy control subjects ($P<0.0001$ for 0-2 interval and $P<0.0001$ for A-C interval). Furthermore, the A-0 interval, which is the time associated with the triggering of the swallowing reflex, was increased in both groups of vascular patients compared with control subjects, although this did not reach the significance level (Table 2). The increase in the SM-EMG duration (A-C interval) in patients with hemispheric stroke compared with control subjects was partly due to the prolongation of the A-0 interval (see Figure 3). Therefore, in these patients, as demonstrated by the prolongation of the A-0 time interval, the triggering of a voluntarily initiated swallow was delayed. On the other hand, the pharyngeal phase of swallowing response was extremely slow in the WS group compared with other groups.

The variation in the swallowing response was determined by measuring the jitter that occurred on the peaks of second laryngeal deflections. In WS patients, there was a significant increase in the swallowing jitter compared with normal subjects ($P<0.0001$) (Table 2). Figure 4 shows the superimposed laryngeal sensor signals and SM-EMG traces obtained from a WS patient and a healthy control subject. It is clear

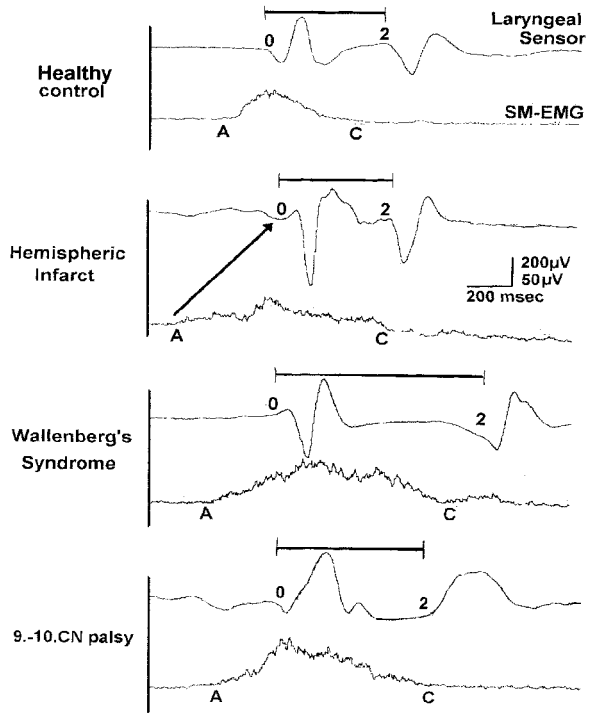

Figure 3. Laryngeal sensor signals and integrated SM-EMG obtained from a healthy control subject and 3 dysphagic patients with hemispheric stroke, WS, and unilateral 9th and 10th cranial nerve (9.-10.CN) palsy during swallowing of 3 mL water. The laryngeal relocation time (0-2 interval) of the swallowing reflex was extremely prolonged in the WS group, whereas it remained within normal limits in the other groups. The total duration of SM-EMG (A-C interval) was also significantly prolonged in the WS group. It was also increased in hemispheric stroke patients, probably because of delayed triggering of the swallowing reflex (A-0 interval, oblique arrow). All traces are average of 5 responses.

that the swallowing jitter was considerably longer in the WS patient. This finding is in parallel with the significant prolongation and variability in the duration of the laryngeal movements during swallowing, ie, the 0-2 interval. This may mean that the security in the neural mechanism of oropharyngeal swallowing has been mostly reduced[15,18] in the WS group compared with other groups studied.

Discussion

Compared with patients with hemispheric stroke, our group of patients with acute WS due to LMI was found to have clinically different problems associated with their swallowing. The first difference was the severity and the duration of the deglutition disorder. It is known that this disorder is more prominent and lasts longer in WS patients than in hemispheric stroke patients, unless the dysphagia is due to multiple cerebral infarctions.[16] This was also the case in the WS patients included in the present study. Furthermore, it is also a well-known fact that in the majority of patients with unilateral hemispheric stroke, dysphagia spontaneously recovers within the first 2 weeks.[19–21] Conversely, the recovery process from dysphagia in WS is rather slow, although steady, as was the case in our group of patients.

Downloaded from http://ahajournals.org by on February 24, 2022

TABLE 2. Summary of Statistical Analyses of Swallowing Parameters Obtained From Normal Subjects and Patient Groups During Swallowing of 3 mL Water

Group	Patients, n	0–2 Interval, ms	A–C Interval, ms	A-0 Interval, ms	Amplitude, μV	Jitter, ms
WS	17†	909.7	1495.9	444.6	58.8	208.9
		74.5	100.9	96.8	5.3	40.8
HS	22	670.2	1180.4	427.0	55.9	113.3
		29.8	116.2	83.0	5.6	14.7
Healthy control	30	573.3	930.0	300.9	57.3	93.3
P values*		13.4	26.2	23.2	4.1	7.9
WS vs HS		0.001	0.053	NS	NS	0.02
WS vs healthy control		0.0001	0.0001	NS	NS	0.001

Interval 0–2 indicates laryngeal relocation time and the time of pharyngeal phase during swallowing; interval A–C, total duration of SM-EMG; interval A-0, triggering time for the pharyngeal phase of swallowing; amplitude, from peak to baseline in SM-EMG; jitter, the variability of 5 consecutive swallows; and NS, not significant. Values are mean±SEM.

*Bonferroni test.

†Three patients could not perform swallowing of 3 mL water.

The second difference between WS and hemispheric stroke patients was related to the affected phase of the swallowing process. Although there was no specific clinical finding associated with oropharyngeal swallowing, a higher incidence of symptoms related to the oral phase of swallowing was found in hemispheric stroke, whereas symptoms associated with the pharyngeal phase of swallowing and laryngopharyngeal paresis were mostly encountered in patients with WS (see Table 1).

For these 2 groups of vascular pathologies, the clinical findings were also in correlation with the electrophysiological results. First, the DD was higher and the dysphagia limit was lower in WS patients. Second, the electrophysiological difference between the 2 groups was associated with the duration of swallowing phases. There was a significant prolongation of the pharyngeal phase of the swallowing in WS patients, whereas the triggering of the voluntarily initiated swallows was slow in the WS and hemispheric stroke patients. This finding may indicate that there is a different pathophysiological mechanism of dysphagia in WS and hemispheric stroke. In hemispheric stroke, the main abnormality should be in the delay of triggering of the swallowing reflex. It is well known experimentally that the cerebral cortex plays a role in the triggering of the swallowing reflex and that after the initiation of swallowing, the central pattern generator of the bulbar swallowing center generates and operates the coordinated sequential muscle activities in the pharynx and larynx.[7,8,22,23] It has been demonstrated that volitional swallowing in humans has multiregional cerebral representation that is strongest within the sensorimotor cortex and cerebellum,[24] and the pharyngeal and esophageal muscles related with swallowing are represented bilaterally but asymmetrically within the cerebral hemispheres.[25,26] Therefore, a benign and transient dysphagia would be expected in a unilateral hemispheric stroke due to bilateral cortical representation.[27]

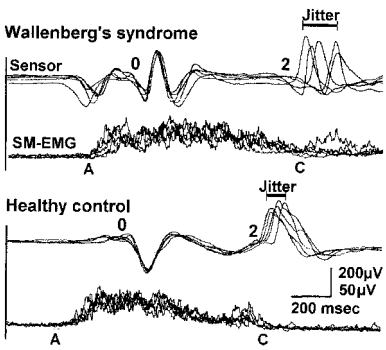

Figure 4. Superimposed laryngeal sensor signals (top traces in each pair) and SM-EMG traces (lower traces in each pair) recorded from a patient with WS and a healthy control subject during swallowing of 3 mL water. The 0-2 time interval and the swallowing jitter were increased in the WS patient.

However, in WS, the main abnormality was observed in the pharyngeal phase of the swallowing reflex, and this cannot be solely explained by the dysfunction of some of the corticobulbar fibers, because in such an anatomic involvement, the swallowing reflex would remain normal.[12,15,16] Therefore, in WS due to LMI, the main reason for an abnormal swallowing function should be sought within the neural structures located in the medulla oblongata.

Experimental studies have identified 2 anatomic regions within the medulla oblongata associated with the swallowing function: (1) a dorsal region consisting of the neurons within and around the NTS and (2) a ventral region corresponding to the reticular formation surrounding the NA.[7,28–30] These 2 regions are represented on both sides of the brain stem and are interconnected extensively so that either side can coordinate the pharyngeal and esophageal phases of swallowing.[31,32] Consequently, these dual swallowing centers on both sides of the medullary region and their extensive connections are important in understanding the nature of dysphagia in WS. LMI should primarily affect the NTS and, in particular, the NA and their vicinity in the medulla oblongata unilaterally. With the use of MRI, it has been demonstrated that in medullary infarction resulting in dysphagia and aspiration, the rostral and dorsolateral parts of the medulla are affected.[4,6,9] A transverse section through the medulla corresponding approximately to the rostral third to fourth of the principal (inferior) olivary nucleus contains the site at which the NTS

Downloaded from http://ahajournals.org by on February 24, 2022

and NA are almost equally affected by the occlusion of the posterior inferior cerebellar artery.[33]

A unilateral involvement of the swallowing center that can cause dysfunction would be expected in a very acute lesion, such as LMI. In this case, dysfunction will manifest itself even though the opposite half of the swallowing center remains intact. Presumably, this is the main reason for such a severe dysphagia that involves the pharyngeal muscles bilaterally for a period of time in WS. Therefore, we propose that such an acute unilateral stroke is capable of affecting the function of the pharynx and larynx bilaterally during swallowing. The evidence in support of this proposal comes from the electrophysiological results obtained from WS patients during swallowing. The extreme prolongation of the pharyngeal phase of oropharyngeal swallowing was the most significant electrophysiological finding of the present study.

Submental muscles are the laryngeal elevators pulling the larynx upward.[13,34,35] The complex includes the anterior digastricus and mylohyoideus muscles innervated by the trigeminal nerve and the geniohyoideus muscle innervated by the hypoglossal nerve.[34,35] In WS, the clinical involvement of the trigeminal and hypoglossal motor nuclei and their intramedullary axonal extensions should be very rare; we did not observe any such motor trigeminal and hypoglossal nerve disturbance in our group of WS patients. However, this raises the question of why submental muscles are contracting slowly during swallowing and prolonging the pharyngeal phase in WS, although they are bilaterally and clinically intact in other functions, such as jaw opening and chewing. The prolongation of the pharyngeal phase of swallowing reflex time has been described in our previous studies investigating various conditions with direct or indirect involvement of the submental muscles.[15,36] On the other hand, in corticobulbar involvement due to amyotrophic lateral sclerosis, there was a delay in the triggering of the swallowing reflex, but whenever the reflex was initiated, it was completely normal.[17]

Results of the present study also revealed that the unilateral pharyngeal and laryngeal paresis due to 9th and 10th cranial nerve involvement can produce a dysphagia, but this is quite mild and cannot be comparable to that in WS, in which both DD and the electrophysiological findings were severe enough to necessitate nonoral feeding in many patients. There were further similar symptoms in these 2 groups, including palatal and vocal cord paresis. Involvement of the NA has long been accepted to be responsible for the paralysis of the ipsilateral vocal cord and the weakness of the ipsilateral palate in WS. However, in nearly all cases, the patient's ability to swallow usually improves, despite the persistence of pharyngeal and palatal weakness.[37] Furthermore, food or secretions may have unusually free influx into the air passage, a phenomenon unusual in patients with peripheral 9th and 10th cranial nerve involvement at the jugular foramen.[37]

Although WS is the consequence of unilateral LMI, it produces bilateral dysfunction of the swallowing muscles, including the submental muscles, which are not innervated at the bulbar level. This may indicate that an acute disconnection syndrome between the 2 halves of swallowing centers and probably even between the NTS and the NA may be

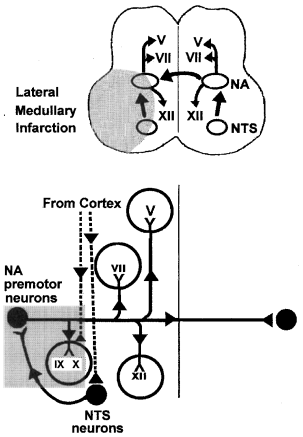

Figure 5. Swallowing-associated connectivity and the regions affected by LMI. Top, Area affected by LMI (shaded area) and the involvement of NTS and NA in this region. Bottom, Schematic representation of premotor neurons and their ipsilateral connections to V, VII, IX, X, and XII cranial motor neuron pools and the contralateral swallowing center.

important in producing the bilateral dysfunction in the pharyngeal phase of swallowing. Figure 5 summarizes the neuronal connectivity and the regions affected by LMI. Medullary premotor neurons with swallowing-related activity have been located in the NTS, the NA, and the surrounding reticular formation region.[28,30,32,38] The neurons that are involved in the reflex control of swallowing are linked synaptically with both peripheral afferents and cortical swallowing-associated areas.[28,30,39] Premotor neurons located in and around the NTS and the NA are connected with different cranial motor neuron pools associated with swallowing.[32,38,39,40] In LMI, primarily these premotor neurons and their connections appear to be affected. Consequently, an acute disconnection could occur between the ipsilateral dorsal swallowing center, ie, the NTS, and the contralateral side of the center of swallowing at the medulla oblongata. This disconnection may be predominantly responsible for the dysphagia encountered in WS. As a result, either the central pattern generator of deglutition could not operate the sequential muscle activity during oropharyngeal swallowing at the onset of stroke, or the sequential muscle activity along the oropharynx could be severely incoordinated and therefore prolonged. The extent to which the lesion involves the swallowing premotor neurons and/or their ipsilateral and contralateral connections, together with the degree of preservation of the dorsal swallowing center around the NTS, may be responsible in determining the severity and duration of dysphagia in WS. As time passes, the remaining intact ipsilateral premotor neurons and those contralateral centers at the medulla oblongata may eventually begin to operate and result in the improvement of the swallowing dysfunction. Therefore, in conclusion, in patients with WS, the dysfunction that clinically presents itself as dysphagia appears to be related to the disconnection and disruption of premotor neurons in and around the NA.

References

1. Norrving B, Cronqvist S. Lateral medullary infarction: prognosis in an unselected series. *Neurology*. 1991;41:244–248.

Downloaded from http://ahajournals.org by on February 24, 2022

2. Sacco RL, Freddo L, Bello JA, Odel JG, Onesti ST, Mohr JP. Wallenberg's lateral medullary syndrome. *Arch Neurol*. 1993;50:609–614.
3. Logemann JA. *Evaluation and Treatment of Swallowing Disorders*. 2nd ed. Austin, Tex: Pro-Ed Inc; 1998.
4. Kim H, Chung CS, Lee KH, Robbins J. Aspiration subsequent to a pure medullary infarction: lesion sites, clinical variables, and outcome. *Arch Neurol*. 2000;57:478–483.
5. Logemann JA, Kahrilas PJ. Relearning to swallow after stroke: application of maneuvers and indirect biofeedback: a case history. *Neurology*. 1990;40:1136–1138.
6. Vigderman AM, Chavin JM, Korosky C, Tahmoush AJ. Aphagia due to pharyngeal constrictor paresis from acute lateral medullary infarction. *J Neurol Sci*. 1998;155:208–210.
7. Jean A, Car A. Inputs to swallowing medullary neuron's from the peripheral afferent fibers and swallowing cortical area. *Brain Res*. 1979; 178:567–572.
8. Miller AJ. Deglutition. *Physiol Rev*. 1982;62:129–184.
9. Kim JS, Lee JH, Suh DC, Lee MC. Spectrum of lateral medullary syndrome: correlation between clinical findings and magnetic resonance imaging in 33 subjects. *Stroke*. 1994;24:1405–1407.
10. Kim WS, Bucholz D, Kumar AJ, Donner MV, Rosenbaum AE. Magnetic resonance imaging for evaluating neurogenic dysphagia. *Dysphagia*. 1987;2:40–45.
11. Taveras JM. Neuroradiology. In: *Brain Vascular Disorders*. 3rd ed. Philadelphia, Pa: Williams and Wilkins; 1996:chap 10.
12. Ertekin C, Aydogdu I, Yüceyar N, Kiylioglu N, Tarlaci S, Uludag B. Pathophysiological mechanisms of oropharyngeal dysphagia in amyotrophic lateral sclerosis. *Brain*. 2000;123:125–140.
13. Ertekin C, Pehlivan M, Aydogdu I, Ertas M, Uludag B, Celebi G, Colakoglu Z, Sagduyu A, Yüceyar N. An electrophysiological investigation of deglutition in man. *Muscle Nerve*. 1995;18:1177–1186.
14. Pehlivan M, Yüceyar N, Ertekin C, Çelebi G, Ertaş M, Kalayci T, Aydogdu I. An electronic technique measuring the frequency of spontaneous swallowing (digital phagometer) *Dysphagia*. 1996;11:259–264.
15. Ertekin C, Aydogdu I, Yüceyar N, Tarlaci S, Kiylioglu N, Pehlivan M, Celebi G. Electrodiagnostic methods for neurogenic dysphagia. *Electroencephalogr Clin Neurophysiol*. 1998;109:331–340.
16. Ertekin C, Aydogdu I, Tarlaci S, Turman AB, Kiylioglu N. Mechanisms of dysphagia in suprabulbar palsy with lacunar infarct. *Stroke*. 2000;31: 1370–1376.
17. Ertekin C, Aydogdu I, Yüceyar N. Piecemeal deglutition and dysphagia limit in normal subjects and in patients with swallowing disorders. *J Neurol Neurosurg Psychiatry*. 1996;61:491–496.
18. Ertekin C, Aydogdu I, Yüceyar N, Pehlivan M, Ertas M, Uludag B, Celebi G. Effects of bolus volumes on the oropharyngeal swallowing: an electrophysiological study in man. *Am J Gastroenterol*. 1997;11: 2049–2053.
19. Kidd D, Lawson J, Nesbitt R, MacMahon J. The natural history of clinical consequences of aspiration in acute stroke. *QJM*. 1995;88:409–413.
20. Smithard DG, O'Neill PA, Parks C, Morris J, Wyatt R, England R, Martin DF. Complications and outcome after acute stroke: does dysphagia matter? *Stroke*. 1996;27:1200–1204.
21. Mann G, Hankey GJ, Cameron D. Swallowing function after stroke: prognosis and prognostic factors at 6 months. *Stroke*. 1999;30:744–748.
22. Miller AJ. The search for the central swallowing pathway: the quest for clarity. *Dysphagia*. 1993;8:185–194.
23. Martin RE, Sessle BJ. The role of the cerebral cortex in swallowing. *Dysphagia*. 1993;8:195–202.
24. Hamdy S, Rothwell JC, David JB, Bailey D, Aziz Q, Thompson DG. Identification of the cerebral loci processing human swallowing with H15O PET activation. *J Neurophysiol*. 1999;81:1917–1926.
25. Aziz Q, Rothwell JC, Barlow J, Thompson DG. Modulation of oesophageal responses to magnetoelectric stimulation of human brain by swallowing and by vagal stimulation. *Gastroenterology*. 1995;109: 1437–1445.
26. Hamdy S, Aziz Q, Rothwell JC, Singh KD, Barlow J, Hughes DG, Tallis RC, Thompson DG. The cortical topography of human swallowing musculature in health and disease. *Nat Med*. 1996;2:1217–1224.
27. Hamdy S, Aziz Q, Rothwell JC, Power M, Singh KD, Nicholson DA, Tallis RC, Thompson DG. Recovery of swallowing after dysphagic stroke relates to functional reorganization in the intact motor cortex. *Gastroenterology*. 1998;115:1104–1112.
28. Jean A. Brainstem organization of the swallowing network. *Brain Behav Evol*. 1984;25:109–116.
29. Jean A. Control of the central swallowing program by inputs from the principal receptors. A review. *J Auton Nerv Syst*. 1986;10:225–233.
30. Kessler JP, Jean A. Identification of the medullary swallowing regions in the rat. *Exp Brain Res*. 1985;57:256–263.
31. Doty RW, Richmond WH, Storey AT. Effect of medullary lesions on coordination of deglutition. *Exp Neurol*. 1967;17:91–106.
32. Barrett RT, Bao X, Miselis RR, Altschuler AM. Brain stem localization of rodent esophageal premotor neurons revealed by transneural passage of pseudo-rabies virus. *Gastroenterology*. 1994;107:728–737.
33. Haines DE. *Neuroanatomy: An Atlas of Structures, Sections, Systems*. 3rd ed. Baltimore, Md/Munich, Germany: Urbane and Schwarzenberg; 1991.
34. Donner MW, Bosma JF, Robertson DL. Anatomy and physiology of the pharynx. *Gastrointest Radiol*. 1985;10:196–212.
35. Perlman AL, Christenson J. Topography and functional anatomy of the swallowing structures. In: Perlman AL, Schulze-Delrieu KS, ed. *Deglutition and Its Disorders*. San Diego, Calif: Singular Publication Group; 1997:15–42.
36. Ertekin C, Yüceyar N, Aydogdu I. Clinical and electrophysiological evaluation of dysphagia in myasthenia gravis. *J Neurol Neurosurg Psychiatry*. 1998;65:848–856.
37. Caplan LR, Pessin MS, Mohr JP. Vertebrobasilar occlusive disease. In: Barnett HJM, Mohr JP, Stein BM, Yatsu FM, eds. *Stroke: Pathophysiology, Diagnosis, and Management*. 2nd ed. New York, NY/Edinburg, UK/London, UK/Melbourne, Australia/Tokyo, Japan. Churchill-Livingstone; 1992:443–515.
38. Amri M, Car A, Jean A. Medullary control of the pontine swallowing neurons in sheep. *Exp Brain Res*. 1984;55:105–110.
39. Bieger D. Muscarinic activation of rhombencephalic neurons controlling oesophageal peristalsis in the rat. *Neuropharmacology*. 1984;23: 1451–1464.
40. Amri M, Car A, Roman C. Axonal branching of medullary swallowing neurons projecting on the trigeminal and hypoglossal motor nuclei: demonstration by electrophysiological and fluorescent double labeling techniques. *Exp Brain Res*. 1990;81:384–390.

Downloaded from http://ahajournals.org by on February 24, 2022